

# UCSF

## UC San Francisco Previously Published Works

### Title

Risk Stratification and Radiologic Evaluation of Central Venous Port Malfunction

### Permalink

<https://escholarship.org/uc/item/1n44v3zj>

### Journal

Journal of the Association for Vascular Access, 19(2)

### ISSN

1083-0081

### Authors

Kansagra, Akash P  
Yu, John-Paul J  
Naeger, David M  
et al.

### Publication Date

2014-06-01

### DOI

10.1016/j.java.2013.12.004

Peer reviewed

# Risk Stratification and Radiologic Evaluation of Central Venous Port Malfunction

Akash P. Kansagra, MD, MS

John-Paul J. Yu, MD, PhD

David M. Naeger, MD

Andrew S. Phelps, MD

Department of Radiology and Biomedical Imaging, University of California, San Francisco, San Francisco, CA

## Abstract

**Background:** Appropriate indications for radiologic evaluation of central venous ports are not fully understood. We aimed to quantitatively assess the utility of clinical history and imaging in the evaluation of malfunctioning central venous ports.

**Methods:** Clinical history, plain radiographs, and line injections intended to evaluate central venous port malfunction in 153 consecutive cases over a nearly 4-year period were retrospectively reviewed by 2 radiologists. Radiographs and line injections were separately categorized as normal or abnormal, and a consensus was reached on the final imaging diagnosis. The likelihood of a port-related abnormality necessitating immediate intervention was determined for all represented combinations of clinical history, radiographic findings, and line injection results.

**Results:** A radiologic diagnosis was made in 96.1% of cases; 19.7% of these diagnoses were classified as critical, requiring prompt intervention. Very low risk histories had a 0.0% incidence of critical port abnormalities in our cohort, regardless of imaging findings. Low risk histories had a 10.5% incidence of a critical abnormality and were best evaluated either by line injection, either directly or following an abnormal chest radiograph. Intermediate and high risk histories were associated with a 30.5% and 61.1% incidence of critical port abnormalities, respectively, and were best evaluated by line injection without preceding chest radiograph.

**Conclusions:** There are several scenarios in which imaging does not meaningfully affect management of malfunctioning central venous ports. Recognizing these inefficiencies may allow for more appropriate and cost-effective use of radiographs and line injections to evaluate the cause of port malfunction.

**Keywords:** central venous catheterization, indwelling catheters, interventional radiography, diagnostic imaging

## Background

Long-term central venous access is a vital component of treatment for a wide range of medical diseases, including hemodialysis for renal failure, chemotherapy for malignancy, and antibiotic infusion for chronic infections.<sup>1,2</sup> The proliferation of therapies that rely on the presence of indwelling central venous catheters has been bolstered by modern interventional radiology (IR) techniques that have rendered the placement of central venous catheters a relatively

straightforward procedure in most cases.<sup>3-7</sup> However, even expertly placed devices for long-term central venous access may occasionally malfunction for myriad reasons.<sup>3,8-10</sup>

When malfunction occurs, the optimal next steps in diagnosis and management are not clearly defined and vary widely among practitioners and catheter types.<sup>5,6,11-14</sup> For instance, when hemodialysis catheters cease to function in a manner compatible with hemodialysis, the typical next step is to empirically replace the catheter without targeted investigation into the specific cause of catheter malfunction.<sup>15</sup> Malfunction of a subcutaneous port, however, is likely to be followed by a chest radiograph and a so-called line injection (or, more colloquially, a dye study or port check), in which radiopaque contrast is injected through the port under continuous fluoroscopic visualization to determine the cause of device malfunction.<sup>1,3,8-11,13,14,16,17</sup> Some of these differences

Correspondence concerning this article should be addressed to [akash.kansagra@ucsf.edu](mailto:akash.kansagra@ucsf.edu)

<http://dx.doi.org/10.1016/j.java.2013.12.004>

Copyright © 2014, ASSOCIATION FOR VASCULAR ACCESS. Published by Elsevier Inc. All rights reserved.

are ostensibly due to the increased difficulty of replacing a subcutaneous port compared with catheters that can be exchanged over a wire, but the diagnostic benefit of an extensive radiographic workup of central venous port malfunctions nevertheless remain unclear.

We conducted a retrospective analysis to assess the diagnostic utility of imaging in the evaluation of malfunctioning central venous ports. Specifically, we investigated the predictive value of clinical history, chest radiography, and line injection for the presence of a critical port abnormality, with the overall goal of identifying instances in which radiologic evaluation may not meaningfully affect management of the port.

## Methods

### Data Collection

Following formal exemption from review by the local institutional review board, relevant radiology reports were identified via computerized search of the institutional radiology information system. Specific search terms were *chest port NOT placement and port OR hemodialysis OR central venous OR malfunction OR aspirate OR flush OR draw OR fibrin*; these search terms were applied to radiology reports for all radiography-based studies completed between January 1, 2009, and October 1, 2012. Search results were manually reviewed and only those studies performed for the primary purpose of port evaluation were included in the analysis. Exclusion criteria were known asymptomatic (incidental) catheter malpositioning, known hardware failure, vascular access catheters other than ports (eg, peripherally inserted central catheters), nonvascular ports (eg, peritoneal ports), port placement, and port removal or replacement without indication of port malfunction.

### History and Clinical Assessment

Pertinent clinical history was obtained from the radiology requisition. Clinical history was categorized as inability to access, inability to aspirate, inability to flush, pain or swelling related to infusion, pain or swelling not related to infusion, redness, bleeding/leaking, malfunction not otherwise specified (NOS), or none. Clinical history was categorized as “malfunction NOS” in cases in which the nature of the malfunction was not explicitly stated. The category “none” was reserved for those cases in which port evaluation was requested without history suggestive of a port abnormality, including, for example, cases in which there was intent to use a port after a prolonged period of disuse.

Clinical histories were further classified into very low risk, low risk, intermediate risk, and high risk groups based on intuitive association with a specific mode of port malfunction (Table 1). Histories of none, redness, bleeding/leaking, inability to access, and pain or swelling not related to infusion were not considered to implicate a priori a specific and worrisome cause of port malfunction, and were therefore classified as very low risk. A history of inability to aspirate, which conventionally suggests the specific but not inherently worrisome diagnosis of a fibrin sheath, was considered low risk. Histories of inability to flush or malfunction NOS that were

**Table 1. Risk Classification of Subcutaneous Ports Based on Clinical History**

Very low risk	None, redness, bleeding/leaking, inability to access, and pain or swelling not related to infusion
Low risk	Inability to aspirate
Intermediate risk	Inability to flush or malfunction not otherwise specified
High risk	Pain or swelling related to infusion

nonspecific or suggestive of a more significant form of malfunction such as port occlusion were considered intermediate risk. A history of pain or swelling related to infusion was a priori suggestive of an extremely dangerous port or catheter disruption and was therefore considered high risk.

Radiology reports often included the radiologists’ own clinical assessment of port function based on attempted aspiration and/or flushing of the port before or during the line injection. Ability to aspirate and/or flush the catheter was categorized as “No” if the radiologist reported any difficulty with these functions in the report, “Yes” if he/she reported no difficulty, or “Unknown” if no comment was made.

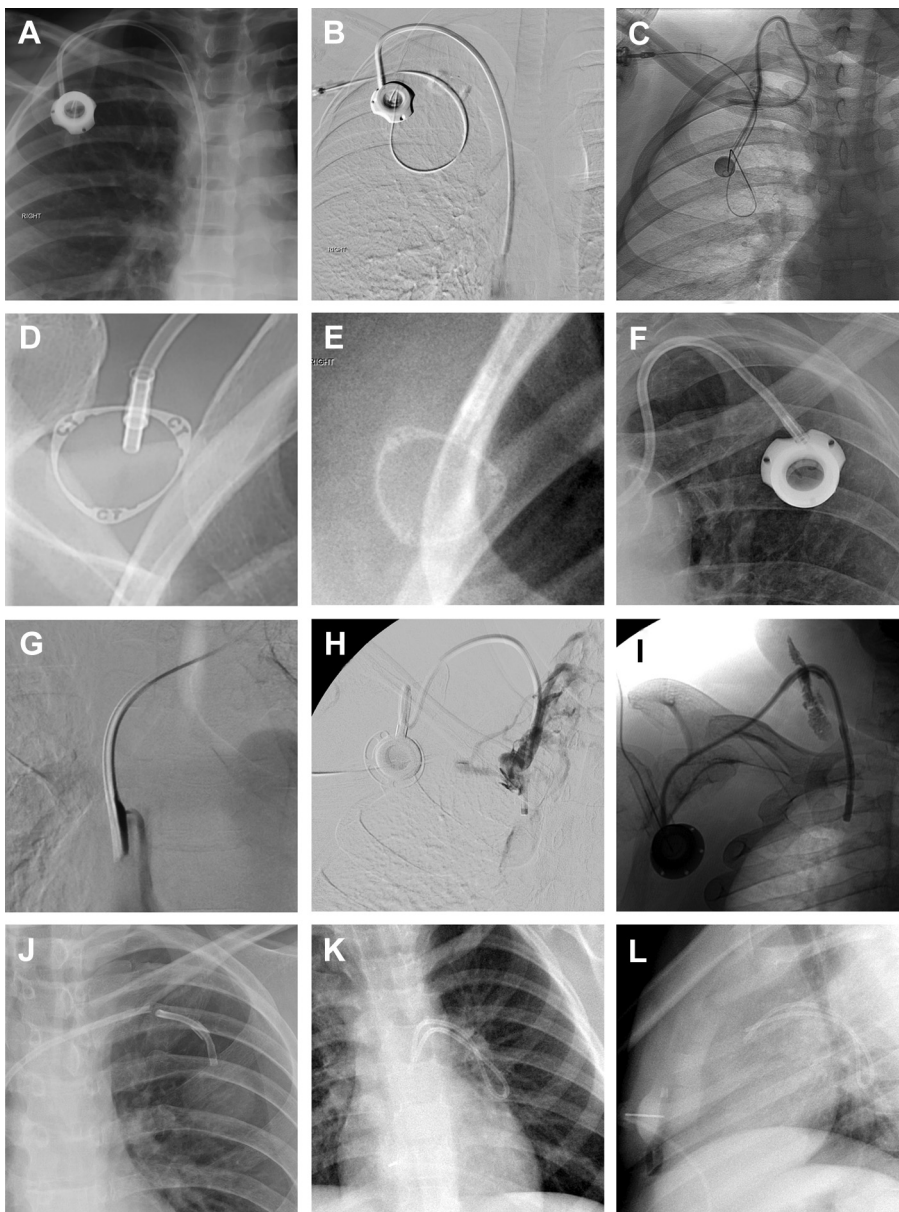
### Radiologic Assessment

Radiologic assessment was based on a noncontrast radiographic study (a chest or abdominal radiograph depending on the location of the port) as well as a dynamic fluoroscopic study done during contrast infusion through the catheter (line injection). Each of these studies was reviewed by 2 radiologists and separately categorized as normal or abnormal based on the presence of abnormalities implicating a specific cause of catheter malfunction. Findings of the chest radiograph and line injections were synthesized into a radiologic diagnosis (Figure 1) that did not take into account clinical history. Possible radiologic diagnoses were: normal, flipped hub, access needle malfunction, fibrin sheath, abutting vessel wall, catheter migration, venous stenosis or occlusion, port occlusion, port or catheter disruption, or unknown. In this context, radiologic diagnoses of port occlusion, port or catheter disruption, or catheter migration were classified as critical port abnormalities that would mandate prompt invasive intervention. Diagnoses of normal, flipped hub, access needle malfunction, fibrin sheath, abutting vessel wall, or venous stenosis or occlusion were not considered critical port abnormalities because immediate intervention was not needed on the basis of patient safety. Indeed, the port could often still be used for medication administration in many cases, even if aspiration of blood was not possible. Diagnoses that were not based on imaging, such as port or catheter infections, were not considered.

### Statistical Analysis

Comparison of frequencies between groups was performed using Fisher’s exact test within the MATLAB R2010a

**Figure 1.** Appearance of common port abnormalities on chest radiographs and line injections. (A) Normal appearance of a right internal jugular vein port on a chest radiograph. (B) Normal line injection with free flow of contrast through the length of the catheter and into the superior vena cava. (C) Malpositioned port catheter coursing into the right subclavian vein. (D) Normal appearance of port hub with normal orientation of imprinted text indicating compatibility of the port with power injection. (E) Flipped port hub with reversed orientation of imprinted text. (F) Flipped port hub from a different brand of power-injectable catheter, again demonstrating reversed orientation of imprinted text. (G) Fibrin sheath at the distal tip of port catheter resulting in reflux of contrast around the catheter and an obliquely oriented contrast jet through the fibrin sheath. (H) Occluded superior vena cava with retrograde flow of injected contrast into the right internal jugular vein and small venous collaterals. (I) Failure of catheter tubing resulting in extravasation of injected contrast into the neck soft tissues. (J) Fracture of a port catheter. (K) Fracture of a port catheter with embolization of the distal catheter fragment into the left pulmonary artery, as seen on frontal chest radiograph. (L) Fracture and embolization of a catheter fragment into the left pulmonary artery, as seen on lateral chest radiograph.



software package (Mathworks Inc, Natick, MA). The threshold of significance was set at  $\alpha = .050$ .

## Results

### Route of Access

A total of 153 studies during the review period met criteria for inclusion in our analysis. The point of vascular entry for these ports was varied, with 86 (56.2%) entering via the right internal jugular vein, 26 (17.0%) via the left internal jugular vein, 22 (14.4%) via the left subclavian vein, 17 (11.1%) via the right subclavian vein, 1 (0.7%) via the right common femoral vein, and 1 (0.7%) via the left basilic vein.

### Spectrum of History and Radiologic Diagnosis

Clinical histories and radiologic diagnoses for these subcutaneous ports are listed in Table 2. The most common indication for port evaluation was inability to aspirate (76 of 153; 49.7%), followed by pain or swelling related to infusion (20 of 153; 13.1%) and inability to flush (17 of 153; 11.1%). A radiologic diagnosis was made in 147 of 153 cases (96.1%). The most common radiologic diagnosis was normal (60 of 147; 40.8%), followed by fibrin sheath (39 of 147; 26.5%) and port or catheter disruption (20 of 147; 13.6%). The overall incidence of critical port abnormalities warranting prompt intervention was 19.7% (29 of 147).

### Detection of Critical Port Abnormalities

The relationship between critical port abnormalities and the risk classification of the associated clinical history is shown in Figure 2.

In the very low risk group, there were no critical port abnormalities (0 of 24). Further investigation with chest radiography or line injection in this group, even if abnormal, did not affect the likelihood of encountering a critical abnormality. Therefore, in our cohort, these ports were safe to use based on history alone.

The low risk group exhibited critical port abnormalities in only 10.5% of cases (8 of 76). This probability decreased to 3.1% (2 of 65) if there was a normal chest radiograph, and increased to 54.5% (6 of 11) in the setting of an abnormal chest radiograph; this difference was statistically significant ( $P < .001$ ). The negative predictive value of a normal chest radiograph in the low risk group was 96.9%.

The intermediate risk group demonstrated critical port abnormalities in 34.5% of cases (10 of 29). An abnormal chest radiograph in this group indicated the presence of a critical abnormality in all cases (3 of 3), whereas a normal chest radiograph corresponded to a 26.9% (7 of 26) probability that a critical port abnormality was present; this difference was also statistically significant ( $P = .036$ ). In the subgroup of cases with a normal chest radiograph, subsequent line injection was helpful in differentiating ports with critical abnormalities from those without ( $P = .010$ ).

In the high risk group, a critical port abnormality was present in 61.1% of cases (11 of 18). As with intermediate risk ports, an abnormal chest radiograph indicated the presence of a critical abnormality in all cases (3 of 3). If the chest

radiograph was normal, the likelihood of a critical port abnormality fell to 53.3% (8 of 15). The difference between these 2 groups was not demonstrably significant ( $P = .304$ ). In the subgroup of ports with a normal chest radiograph, line injection again proved useful in differentiating ports with critical abnormalities from those without ( $P = .001$ ).

### Clinical Assessment of Port Function

Agreement between provided clinical history and radiologist-performed assessment of port function was poor. For example, of the ports described as being unable to aspirate, 30.9% (17 of 55) could in fact be aspirated by a radiologist. Moreover, of the ports described as being unable to flush, 73.3% (11 of 15) could in fact be freely flushed by a radiologist. This second assessment of port function by a radiologist had diagnostic value; in cases where the provided history was inability to aspirate but a radiologist could aspirate from the port, there were no critical port abnormalities (0 of 17).

## Discussion

There are currently no established guidelines for appropriate diagnostic evaluation of malfunctioning central venous ports. Baskin et al<sup>16</sup> advocate for imaging evaluation of all ports that cannot be rendered fully functional by simple bedside methods. Barnacle et al<sup>14</sup> issue a similar recommendation but point out that some institutions remove all malfunctioning catheters without imaging evaluation. The lack of a standardized diagnostic algorithm leaves considerable room for variability in clinical practice between institutions and potentially even between individual practitioners.

At our institution, malfunction of a subcutaneous port usually prompts a line injection. It is unclear the extent to which these studies actually affect management, since the decision to pursue port-related intervention could presumably be made strictly on the basis of suitability of the catheter for clinical use. That is, if infusion of chemotherapeutic or antimicrobial agents is necessary but cannot be adequately performed using an existing port, then intervention is warranted regardless of cause.

By comparison, the algorithm for diagnostic evaluation of a malfunctioning hemodialysis catheter is extremely limited. Hemodialysis catheters malfunction for the same reasons as central venous ports,<sup>15,18</sup> but there is widespread recognition among nephrologists that any impediment to hemodialysis warrants intervention, regardless of the specific cause of malfunction. As such, line injections intended to reveal the cause of hemodialysis catheter malfunction are rarely performed, because the primary decision point in the treatment algorithm relates to clinical functionality of the catheter without reference to abnormalities on imaging.<sup>19</sup>

Applying a similar philosophy to malfunctioning central venous ports has the potential to streamline care. Specifically, recognizing instances in which radiologic evaluation of malfunctioning chest ports is unlikely to yield useful information may produce cost savings, increase efficiency by obviating the need for direct supervision by a radiologist, and reduce

**Table 2. Clinical Histories and Number of Radiologic Diagnoses in Subcutaneous Ports**

History	Normal	Access needle malfunction	Flipped hub	Fibrin sheath	Abutting vessel wall	Catheter migration	Port occlusion	Port or catheter disruption	Venous stenosis or occlusion	Unknown	Total
None	5									1	6
Redness	2									1	3
Bleeding/leaking	2										2
Inability to access	1	1	6								8
Inability to aspirate	28			33	4	4		4	3		76
Inability to flush	7	1		2			2	4	1		17
Malfunctioning not otherwise specified	4			2		1	2	1	2		12
Pain/swelling (injection-related)	6			1				11		2	20
Pain/swelling (not injection-related)	5			1					1	2	9
Total	60	2	6	39	4	5	4	20	7	6	153

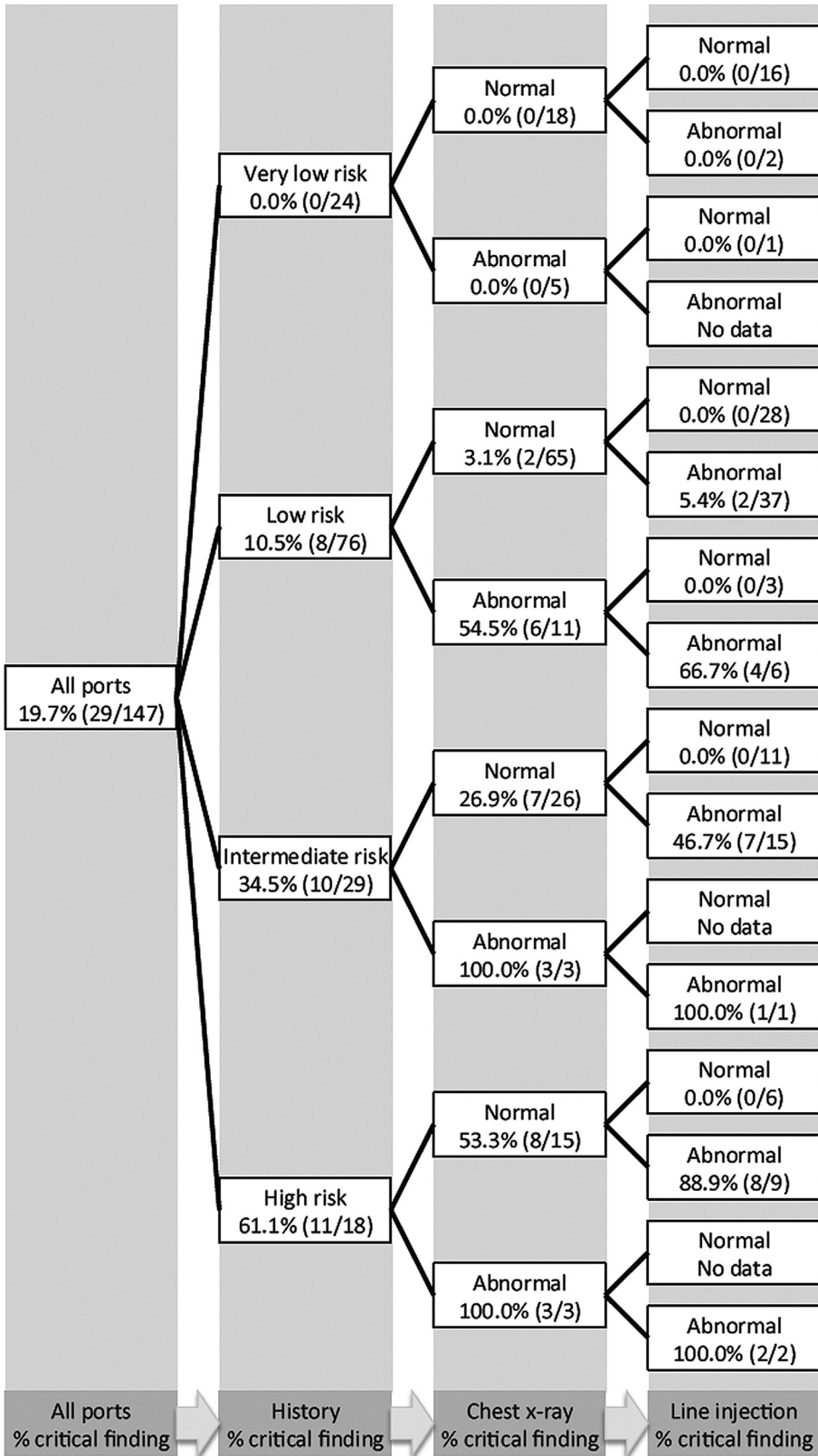
the need to access ports and inject nephrotoxic contrast media. Our data indicate that no imaging evaluation or IR referral is needed for ports with very low risk histories. On the other end of the spectrum, intermediate and high risk histories should proceed directly to line injection without an intervening radiograph.

Optimal management in the face of a low risk history is less clear. Due to the high negative predictive value of a chest radiograph in this group, line injections could be reserved for only those patients with an abnormal chest radiograph (the efficient strategy). However, because the negative predictive value of chest radiograph is not quite 100%, there may be cause to pursue line injections in lieu of chest radiographs in all patients with low risk history (the safe strategy).

A total of 146 chest radiographs and 137 line injections were performed in our cohort. By following the safe strategy, the number of diagnostic studies would have been reduced to 0 chest radiographs and 123 line injections, with no loss of diagnostic accuracy. Alternatively, by following the efficient strategy, the number of diagnostic studies would have been reduced to 76 chest radiographs and just 58 line injections, although this streamlined approach would have missed 2

important port abnormalities in the low risk group. In either approach, IR referral is unnecessary in any case not sufficiently worrisome to warrant a line injection, or in which line injection is normal. On the other hand, IR referral should be obtained following any line injection that demonstrates a critical abnormality such as port occlusion, port or catheter disruption, or catheter migration. Of note, this patterned approach to IR referral pertains only to mechanical causes of port malfunction. Symptoms suggesting a worrisome but nonmechanical port abnormality—sepsis with fluctuance over the port site, for example—warrant IR referral even without a radiographic workup.

The finding of strong disagreement between radiologist and clinician assessment of port functionality does not have a clear explanation in our data, but may reflect differences in forcefulness of aspiration and flushing; incorrect placement of the access needle; or most likely, the passage of time between initial detection of port malfunction at bedside and subsequent referral for radiologic evaluation. If a port with reported inability to aspirate could in fact be aspirated by the radiologist, the baseline risk of a critical port abnormality returned to zero. This result suggests that ports that cannot be aspirated may benefit from a period of watchful



**Figure 2.** Decision tree for malfunctioning chest ports, with frequency of critical port abnormalities (defined as port abnormalities warranting intervention based on imaging findings alone) at each node. Ports are classified first by risk category of clinical history, then by chest radiography, and finally by line injection. In some branches, child node totals do not add to the parent node totals due to the possibility of an unknown study result. For example, there were 5 ports with very low risk history and abnormal chest radiograph, but a line injection was performed for only 1 of these ports.

waiting followed by a repeat attempt at bedside assessment of port function before imaging referral. Employing this additional step is likely to further reduce the number of unnecessary line injections.

One limitation of our study is that some ports were accompanied by inadequate clinical history and were therefore classified as malfunction NOS. The situations in which only limited clinical history is available may vary between institutions, but we

nevertheless expect our results to hold because malfunction NOS represented just 7.8% of ports in our study (12 of 153). Another important limitation of our study is that it involves retrospective review of nonstandardized clinical practice. Because the diagnostic evaluation of malfunctioning subcutaneous ports in our cohort is heterogeneous, it may be that certain cases for which radiographs or line injections are particularly helpful or particularly unhelpful are referred for imaging at different rates, leading to systematic under- or overrepresentation of certain indications for imaging. Accordingly, our data should not be regarded as a measure of the diagnostic performance characteristics of each individual test, but rather as an overview of the yield of current practice patterns in aggregate.

### Conclusions

We reviewed nearly 4 years of radiographs and line injections obtained as part of the diagnostic evaluation of malfunctioning central venous ports with the overall goal of characterizing the diagnostic yield of these imaging studies in the context of patients' known histories. We have identified several scenarios in which imaging does not meaningfully affect subsequent management, and hope that these data will be used as the basis for a more discriminating approach to imaging referral.

### Disclosures

The authors have no conflicts of interest to disclose.

### References

1. Tan PL, Gibson M. Central venous catheters: the role of radiology. *Clin Radiol*. 2006;61(1):13-22.
2. Taber SW, Bergamini TM. Long-term venous access: indications and choice of site and catheter. *Semin Vasc Surg*. 1997;10(3):130-134.
3. Bhutta ST, Culp WC. Evaluation and management of central venous access complications. *Tech Vasc Interv Radiol*. 2011;14(4):217-224.
4. Cil BE, Canyigit M, Peynircioglu B, et al. Subcutaneous venous port implantation in adult patients: a single center experience. *Diagn Interv Radiol*. 2006;12(2):93-98.
5. Denny DF Jr. Placement and management of long-term central venous access catheters and ports. *Am J Roentgenol*. 1993;161(2):385-393.
6. Funaki B. Central venous access: a primer for the diagnostic radiologist. *Am J Roentgenol*. 2002;179(2):309-318.
7. Marcy PY. Central venous access: techniques and indications in oncology. *Eur Radiol*. 2008;18(10):2333-2344.
8. Boardman P, Hughes JP. Radiological evaluation and management of malfunctioning central venous catheters. *Clin Radiol*. 1998;53(1):10-16.
9. Crain MR, Horton MG, Mewissen MW. Fibrin sheaths complicating central venous catheters. *Am J Roentgenol*. 1998;171(2):341-346.
10. Surov A, Jordan K, Buerke M, et al. Port catheter insufficiency: incidence and clinical-radiological correlations. *Onkologie*. 2008;31(8-9):455-461.
11. Cassidy FP Jr, Zajko AB, Bron KM, Reilly JJ Jr, Peitzman AB, Steed DL. Noninfectious complications of long-term central venous catheters: radiologic evaluation and management. *Am J Roentgenol*. 1987;149(4):671-675.
12. Faintuch S, Salazar GM. Malfunction of dialysis catheters: management of fibrin sheath and related problems. *Tech Vasc Interv Radiol*. 2008;11(3):195-200.
13. Mayo DJ. Fibrin sheath formation and chemotherapy extravasation: a case report. *Support Care Cancer*. 1998;6(1):51-56.
14. Barnacle A, Arthurs OJ, Roebuck D, Hiorns MP. Malfunctioning central venous catheters in children: a diagnostic approach. *Pediatr Radiol*. 2008;38(4):363-378.
15. Trerotola SO. Hemodialysis catheter placement and management. *Radiology*. 2000;215(3):651-658.
16. Baskin JL, Pui CH, Reiss U, et al. Management of occlusion and thrombosis associated with long-term indwelling central venous catheters. *Lancet*. 2009;374(9684):159-169.
17. Teichgraber UK, Gebauer B, Benter T, Wagner HJ. Central venous access catheters: radiological management of complications. *Cardiovasc Intervent Radiol*. 2003;26(4):321-333.
18. Besarab A, Pandey R. Catheter management in hemodialysis patients: delivering adequate flow. *Clin J Am Soc Nephrol*. 2011;6(1):227-234.
19. Lok CE, Thomas A, Vercaigne L. A patient-focused approach to thrombolytic use in the management of catheter malfunction. *Semin Dialysis*. 2006;19(5):381-390.