

# UC Davis

## Dermatology Online Journal

### Title

A pruritic pedunculated pink nodule on the leg

### Permalink

<https://escholarship.org/uc/item/1mt6j9tb>

### Journal

Dermatology Online Journal, 29(2)

### Authors

Kazmi, Maha  
Opene, Caroline  
Kiuru, Maija

### Publication Date

2023

### DOI

10.5070/D329260776

### Copyright Information

Copyright 2023 by the author(s). This work is made available under the terms of a Creative Commons Attribution-NonCommercial-NoDerivatives License, available at <https://creativecommons.org/licenses/by-nc-nd/4.0/>

Peer reviewed

# A pruritic pedunculated pink nodule on the leg

Maha Kazmi<sup>1</sup> BS, Caroline Opene<sup>1</sup> MD, Maija Kiuru<sup>1,2</sup> MD PhD

Affiliations: <sup>1</sup>Department of Dermatology, University of California Davis, Sacramento, California, USA, <sup>2</sup>Department of Pathology and Laboratory Medicine, University of California Davis, Sacramento, California, USA

Corresponding Author: Maija Kiuru MD PhD, 3301 C Street, Suite 1400, Sacramento, CA 95816, Email: [mkiuru@ucdavis.edu](mailto:mkiuru@ucdavis.edu)

## Abstract

Herein, we present a patient with a lipidized fibrous histiocytoma, an underrecognized variant of dermatofibroma (cutaneous fibrous histiocytoma). Our patient presented with a nodule on the ankle that showed foamy histiocytes and hyalinized collagen bundles on histology. This case highlights a classic presentation and features of lipidized fibrous histiocytoma, raising further awareness of this distinctive variant of dermatofibroma that should be distinguished from xanthoma and xanthogranuloma.

*Keywords: dermatofibroma, fibrous, histiocytes, histiocytoma, lipidized, xanthogranuloma, xanthoma*

## Introduction

Lipidized fibrous histiocytoma (LFH), a variant of dermatofibroma, is a benign neoplasm. It commonly presents as a polyploid yellowish nodule on the lower limb, characteristically on the ankle (ankle-type fibrous histiocytoma), [1]. Herein, we present a case of LFH, highlighting the characteristic clinical and histopathological features of this underrecognized tumor.

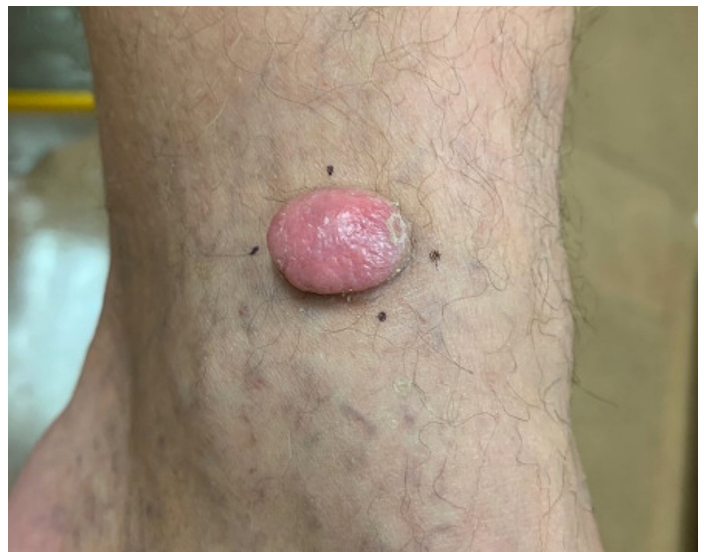## Case Synopsis

A 45-year-old man with no past medical history presented with a lesion on his left ankle that had been present for three years and had never been treated. The patient stated that the nodule was pruritic and rubbed against his socks; he denied bleeding. Physical examination revealed a rubbery

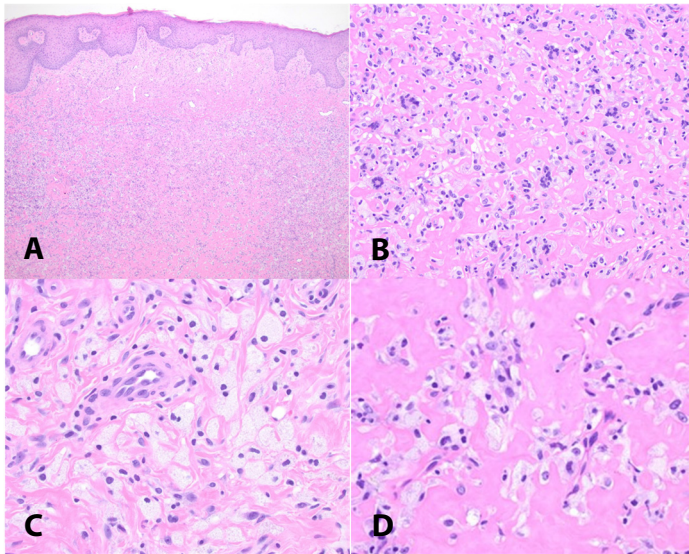
1.8cm pedunculated pink nodule with a broad stalk (**Figure 1**). Dermoscopy showed coiled blood vessels. A shave biopsy was performed (**Figure 2**). Histopathologic examination of the lesion showed foamy histiocytes associated with hyalinized collagenous stroma and peripheral spindled cells with collagen entrapment. The lesional cells were negative for S100 and pan-cytokeratin AE1/AE3 and weakly positive for CD68. These features, in conjunction with the clinical features and location of the lesion, are consistent with lipidized fibrous histiocytoma.

## Case Discussion

Lipidized fibrous histiocytoma is a rare, and underrecognized form of dermatofibroma (fibrous histiocytoma) that presents as a solitary, slow-growing exophytic tumor, that favors the lower



**Figure 1.** A 1.8 cm exophytic pink plaque on the left medial ankle.



**Figure 2.** H&E histopathology. **A)** A proliferation of foamy histiocytes associated with hyalinized collagenous stroma and peripheral spindled cells with collagen entrapment, 4x. **B)** Foamy histiocytes associated with hyalinized osteoid-like collagenous stroma, 20x. **C)** Foamy histiocytes, 40x. **D)** Hyalinized osteoid-like collagenous stroma, 40x.

extremity, particularly the ankle [1,4]. It more commonly presents in male than female patients at a 2.7:1 ratio and is typically found in patients in their fifth and sixth decade of life [1]. It is typically larger than a common dermatofibroma. Unlike xanthomas, it has not been demonstrated to have an association with hyperlipidemia [1].

Histopathologically, lipidized fibrous histiocytoma is characterized by an infiltrate of predominantly foamy histiocytes that cover about 75% of the surface area, in association with abundant, distinctive hyalinized collagen bundles in the stroma that may appear keloid-like or osteoid-like [1-4]. Additionally, there are a few siderophages and a storiform pattern of fibroblast-like spindled cells [1]. Epidermal hyperplasia is often present. On immunohistochemistry, LFH stains negatively for S100, desmin, and cytokeratin [1]. There is positive staining for CD68 in the foamy histiocytes, with possible positive focal staining for CD34 and Factor XIIIa [4]. Recurrences of LFH are rare, even after incomplete excision [1].

Lipidized fibrous histiocytoma should be distinguished from juvenile xanthogranuloma (JXG). Juvenile xanthogranuloma presents as a yellowish-

orange-to-tan papule or nodule that occurs most commonly on the head and neck of children, with 20% of cases developing in adolescents and young adults [5]. Histologic examination of JXG demonstrates a mixed histiocytic proliferation with Touton giant cells, mononuclear cells, and lymphocytes [5]. The histiocytes have more eosinophilic and less lipidized cytoplasm than those in LFH [1]. Additionally, storiform spindled tumor cells, peripheral entrapment of collagen fibers, and epidermal hyperplasia are usually lacking. Juvenile xanthogranuloma stains positively for fascin, CD68, CD4, LCA, and Factor XIIIa, with variable staining for S100 [5,6]. Juvenile xanthogranuloma stains negatively for CD34 [6].

Additionally, LFH should be distinguished from xanthomas. These benign lesions commonly present as yellowish papules, plaques, or nodules distributed over extensors of extremities, buttocks, or hands [7]. Histologically, these subcutaneous lipid deposits notably feature cholesterol-ester and cholesterol-laden, foamy macrophages [7]. Xanthomas more frequently present in the adult population and can present clinically as a variety of types: eruptive, tuberous, tendinous, or planar [7]. Although xanthomas are benign, importantly, they may be associated with hyperlipidemias requiring appropriate management [7].

Lipidized fibrous histiocytoma should furthermore be distinguished from clear cell dermatofibroma, another rare benign variant of dermatofibroma that can similarly be found on the lower extremity [8]. On histology, these lesions present with sheets of clear cells with vesicular nuclei within the dermis that lack significant atypia [8,9]. Other features include epidermal hyperplasia, a storiform arrangement of spindle cells, peripheral sclerotic collagen, and a lymphohistiocytic response predominantly in the periphery [8,9].

## Conclusion

Lipidized fibrous histiocytoma is a rare, and underrecognized form of dermatofibroma (fibrous histiocytoma), classically presenting on the ankle and demonstrating lipidized histiocytes and hyalinized collagen bundles. Recognizing this

variant allows distinction from xanthoma and xanthogranuloma and thus appropriate management.

## Potential conflicts of interest

The authors declare no conflicts of interest.

## References

1. Iwata J, Fletcher CD. Lipidized fibrous histiocytoma: clinicopathologic analysis of 22 cases. *Am J Dermatopathol.* 2000;22:126-34. [PMID: 10770432].
2. Fujita Y, Tsunemi Y, Kadono T, et al. Lipidized fibrous histiocytoma on the left condyle of the tibia. *Int J Dermatol.* 2011;50:634-6. [PMID: 21506990].
3. Luzar B, Calonje E. Cutaneous fibrohistiocytic tumours - an update. *Histopathology.* 2010;56:148-65. [PMID: 20055912].
4. Alves JV, Matos DM, Barreiros HF, Bartolo EA. Variants of dermatofibroma--a histopathological study. *An Bras Dermatol.* 2014;89:472-7. [PMID: 24937822].
5. Kubota Y, Kiryu H, Nakayama J, Koga T. Histopathologic maturation of juvenile xanthogranuloma in a short period. *Pediatr Dermatol.* 2001;18:127-30. [PMID: 11358553].
6. Kraus MD, Haley JC, Ruiz R, et al. "Juvenile" xanthogranuloma: an immunophenotypic study with a reappraisal of histogenesis. *Am J Dermatopathol.* 2001;23:104-11. [PMID: 11285404].
7. Cruz PD, Jr., East C, Bergstresser PR. Dermal, subcutaneous, and tendon xanthomas: diagnostic markers for specific lipoprotein disorders. *J Am Acad Dermatol.* 1988;19:95-111. [PMID: 3042820].
8. Wambacher-Gasser B, Zelger B, Zelger BG, Steiner H. Clear cell dermatofibroma. *Histopathology.* 1997;30:64-9. [PMID: 9023559].
9. Alves JV, Matos DM, Barreiros HF, Bartolo EA. Variants of dermatofibroma--a histopathological study. *An Bras Dermatol.* 2014;89:472-7. [PMID: 24937822].