

UC Irvine

UC Irvine Previously Published Works

Title

Utility of video-fundoscopy and prospects of portable stereo-photography of the ocular fundus in neurological patients

Permalink

<https://escholarship.org/uc/item/1kv460g8>

Journal

BMC Neurology, 22(1)

ISSN

1471-2377

Authors

Khachatryan, Tigran

Mozaffar, Tahseen

Mnatsakanyan, Lilit

Publication Date

2022-12-01

DOI

10.1186/s12883-022-02578-5

Copyright Information

This work is made available under the terms of a Creative Commons Attribution License, available at <https://creativecommons.org/licenses/by/4.0/>

Peer reviewed

RESEARCH

Open Access



Utility of video-fundoscopy and prospects of portable stereo-photography of the ocular fundus in neurological patients

Tigran Khachatryan^{1*}, Tahseen Mozaffar^{1,2} and Lilit Mnatsakanyan¹

Abstract

Background: Proper evaluation of ocular fundi is an integral part of neurological examination. Unfortunately, neurology residents are increasingly uncomfortable performing fundoscopy and interpreting findings because of diminishing skills and lack of experience. This became more prominent during the COVID-19 pandemic as fundoscopy requires proximity to the patient.

With the recent dramatic improvement of smartphone cameras, fundus photography using the PanOptic Ophthalmoscope (Welch Allyn, Skaneateles Falls, NY) with a smartphone adapter offered an alternative to direct fundoscopic examination. We present the first experience with our own design of a universal smartphone adapter.

Methods: This is a single-center case series, consecutive for a single user and certain presenting neurological symptoms, which is aimed to evaluate the feasibility and practicality of a new, universal PanOptic smartphone adapter. Presenting symptoms included headache, ocular symptoms, seizure, or encephalopathy. We used 3D modeling and printing techniques to create the adapter.

We also developed a methodology of capturing stereoscopic images of the optic disc using a single smartphone camera, but the method was not systematically evaluated in this paper.

Results: Here we present our initial experience of fundus video/photography in patients, who presented with encephalopathy, headache, seizure, vision loss, and other ocular symptoms. Fundoscopic abnormalities were discovered in 11 out of 100 patients. Some were incidental findings and were unrelated to the presentation. In one case, fundoscopy played a critical role in establishing the correct diagnosis.

Conclusions: Our custom-designed smartphone adapter allowed obtaining high-quality video and photo recordings using PanOptic Ophthalmoscope. The acquisition of high-quality photos enables a high-yield diagnostic tool and allows revisiting the image in the patient's chart. Improvement of smartphone cameras opens vast horizons for stereo-fundoscopy and 3D reconstruction of the ocular fundus without using sophisticated and costly equipment. Microscopic eye movements allow taking snapshots of two side-by-side photos for 3D reconstruction and stereoscopic image viewing, which is the next level of optic disc assessment.

Keywords: Fundoscopy, Ophthalmoscope, Smartphone, 3D, Fundus photography

Background

Fundoscopy examination is a basic competency requirement for all Neurologists and an important component of neurological examination [1, 2]. Traditional direct fundoscopy requires that examiners position themselves

*Correspondence: tigrank@hs.uci.edu

¹ Department of Neurology, University of California, Irvine, USA
Full list of author information is available at the end of the article



close to the patient which became a serious limitation during COVID-19 pandemic [3]. As part of a resident quality improvement project, medical records of 100 consecutive patients, admitted to the Department of Neurology at UC Irvine Medical Center during the COVID-19 pandemic, were retrospectively reviewed. None of the patients underwent a fundoscopic examination.

With dramatic improvement of camera quality in modern smartphones, fundus photography using PanOptic Ophthalmoscope (Welch Allyn, Skaneateles Falls, NY) with a smartphone adapter offered an alternative to direct examination of ocular fundus. We explored the idea of creating our very own design of universal smartphone adapter for PanOptic Ophthalmoscope to fit all smartphone types, which would help reducing very close contact with the patient and reduce the time needed for examination. We

focused on PanOptic ophthalmoscope due to widespread availability, ease of use and large field of view.

Stereo fundoscopy has been validated as an effective method of optic nerve head assessment and is widely used in ophthalmological practice for diagnosis and treatment of glaucoma and diabetic retinopathy [4–7]. To the best of our knowledge, there are no studies evaluating stereo fundoscopy in the emergency room setting for evaluation of neurological disorders, as the required equipment is not portable and not readily available in Emergency Departments.

Methods

This study is a prospective, single-center case series aimed to evaluate the feasibility and practicality of a new PanOptic smartphone adapter, which was conducted



as part of resident quality improvement project at UC Irvine Medical Center. Cases are consecutive for a single user and certain presenting symptoms as detailed below. Thus, it is not a true prevalence study. All methods were performed in accordance with the relevant guidelines and regulations.

The adapter was designed using MeshMixer (Autodesk Inc.) 3D modeling software (Fig. 1-a). It was then printed with Polyethylene terephthalate glycol filament on a 3D Fused Deposition Modeling printer.

The attachment consists of a foldable arm, a flat surface with double-sided adhesive and an ocular piece, which fits exactly the ocular part of PanOptic Ophthalmoscope (Fig. 1-c). The adapted can be permanently attached to any smartphone case and, with the foldable arm, can be seamlessly carried in the pocket (Fig. 1-b). When fully assembled, our adapter resembles iExaminer (Welch Allyn Inc., Skaneateles Falls, New York, USA) adapter but has several advantages, including foldable arm, low profile and compatibility with all smartphones. Additionally, we designed a smartphone powered light source, which eliminated the need for charging and carrying the battery piece (Fig. 1-d). Thus, one needs to carry only the head of PanOptic ophthalmoscope to obtain fundoscopic images.

Patients, presenting to the emergency department with complaints of headache, ocular symptoms (visual disturbances, blindness, diplopia, pain), seizures or encephalopathy underwent fundoscopic videography and/or photography. We did not use pharmacological pupillary dilation for any of the patients. In cooperative patients, the examiner instructed the patient to focus gaze on a

stationary object and sequentially obtained video recordings from both eyes. In uncooperative patients the bedside nurse carefully held the patient’s eyelid open while the examiner was obtaining the recordings.

Images were captured using iPhone 11 Pro (Apple Inc., CA, USA) smartphone. Photographs were directly uploaded to patient’s chart on Epic using Haiku app for IOS (Epic systems corporation, Verona, WI). Video data was de-identified and deleted after subtracting all necessary snapshots. Fundus videographs and photographs were then reviewed by on-call senior resident and later by the attending neurologist on service during formal rounds. Reviewers were not blinded to prior reviews due to importance of ongoing resident teaching and feedback on interpretation skills. Therefore, we planned to analyze and report outcomes as specific case illustrations rather than period prevalence, quality or accuracy measures.

Data is reported in accordance with Strengthening the Reporting of Observational Studies in Epidemiology (STROBE) Statement (Fig. 2), [8].

We also developed a methodology of capturing stereoscopic images of the optic disc using a single smartphone camera. Healthy volunteer subjects were asked to look sequentially at two objects or light sources located 6ft away from the eye and 30cm apart from each other. Video fundoscopy was performed while the subject was performing the task. The camera remained static in respect to the subject’s forehead, but eyeball moved in the horizontal plane, providing visualization of the fundus under two different angles equal to ten degrees. Subsequently, snapshots from each respective position were

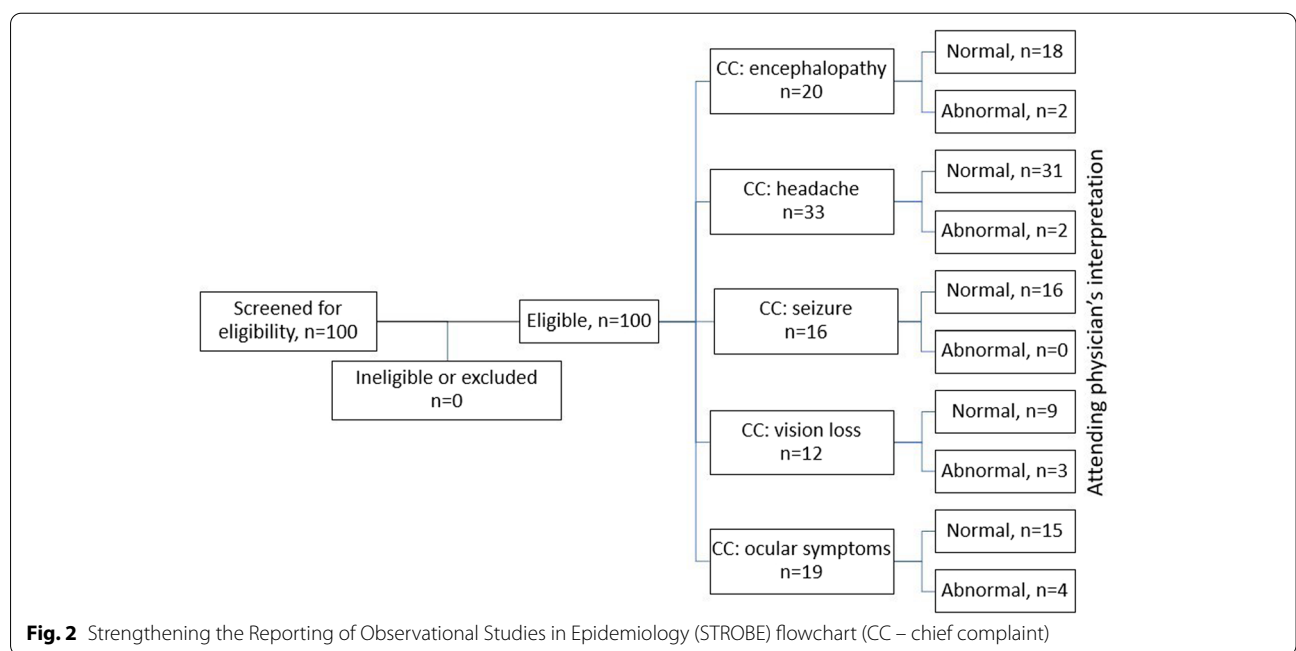


Fig. 2 Strengthening the Reporting of Observational Studies in Epidemiology (STROBE) flowchart (CC – chief complaint)

obtained, which essentially represented a pair of stereoscopic images. Google cardboard or similar 3D headset was utilized to view stereoscopic images. The aforementioned methodology of stereoscopic imaging was developed relatively late in the study, thus was not routinely utilized in presented group of patients.

Upon admission to the hospital, all patients or their legal representatives signed admission terms and conditions agreement, which includes statements about obtaining medical video/photographs. Furthermore, funduscopy is a part of neurological exam and does not require separate written consent. There are no identifiable features in the presented group of photographs.

Results

Data was analyzed after performing fundus video/photographs on 100 patients over the period from December 2019 to February 2021. None of the patients or legal representatives declined enrollment. The presentation included encephalopathy in 20%, headache in 33%, seizure in 16%, vision loss in 12% and other ocular symptoms (diplopia, decreased acuity of vision, eye pain) in 19% of patients. The mean age of the examinees was 44.7 years (range 20–89).

Stereoscopic images were obtained on two healthy volunteers (Fig. 3a and b), and one patient with normal fundoscopic findings. Stereoscopic images resulted in subjectively better perception of cup-to-disc ratio and relation of vessels to the optic disc when compared to 2D images acquired from the same patient (Fig. 3c). Fundoscopic abnormalities were discovered in 11 patients, although some were incidental findings as these were unrelated to the presentation or chief complaint (Fig. 4 a-g). In one patient, funduscopy played a critical role in establishing the diagnosis. As an example of the clinical utility of fundus photography using PanOptic ophthalmoscope, we present a case of a 78 yo man with history of uncontrolled diabetes and chemotherapy due to gastric adenocarcinoma was brought in by family due to altered mental status and decreased oral intake. On initial evaluation patient was diagnosed with diabetic keto acidosis due to beta hydroxybutyrate level of >4.0 mmol/L, bicarbonate level of 19 mmol/L and anion gap of 16 mmol/L prompting admission to medical ICU for further care. Neurology was consulted due to history of bilateral lower extremity weakness after a chiropractic manipulation. Funduscopy was performed as part of the neurological examination and showed bilateral grade 1 papilledema on the right and grade 3 papilledema on the left (Fig. 5). Based on the findings lumbar puncture was recommended which revealed opening pressure of 55 cm H₂O and 235 nucleated cells. Final cytological diagnosis of leptomeningeal carcinomatosis due to gastric

adenocarcinoma was confirmed by CDX2 immunostaining. Patient underwent VP shunt placement and was discharged to acute rehabilitation facility with outpatient follow-up.

Discussion

Since first direct visualization of ocular fundus by Hermann von Helmholtz in 1851, funduscopy has become an integral part of neurological examination [9–11]. Many authors have emphasized the importance of proper fundoscopic examination in neurological patients [11, 12]. However, with introduction of neuro-imaging modalities such as CT and MRI, non-ophthalmology specialists are having an increasingly difficult time to perform funduscopy or interpret the findings because of diminishing skills and lack of experience [9, 11–14]. This is partly explained by the necessity to dilate the pupil for adequate examination, which inherently makes serial neurological examinations more difficult. In 1886, Jackman and Webster published the first human fundus photograph, beginning a new era in visualization of ocular fundus [10, 14, 15]. With advancement of technology, non-mydratric fundus cameras came into practice [9, 16]. The wide field of view and possibility of performing the examination without pharmacologic dilation of the pupil became a huge advantage of non-mydratric fundus cameras [9, 17]. It has a number of other advantages, including higher rate of successful visualization, possibility to share the image among multiple providers, avoiding repeated examinations causing patient discomfort as well as storing images for comparison in the future [9, 12, 21, 22]. Several studies have shown that images even can be obtained by non-medical personnel after a short training period, unlike direct funduscopy, when visualization and interpretation occur simultaneously [2, 3, 10, 12, 16].

However, there is a host of limitations to non-mydratric fundus photography. Even handheld non-mydratric cameras are bulky and difficult to carry around at all times and are not widely used outside the ophthalmology clinic settings [23]. The cost of such cameras is another limitation of its universal use, particularly in countries with limited resources [12]. Additionally, direct ophthalmoscopy allows visualization of retinal venous pulsation, while such interpretation is impossible by viewing still photographs [24]. Finally, trying to time the good fundoscopic view and capture a photo is a skill, that may take longer to acquire than performing a direct funduscopy [23].

In 2001 PanOptic (Welch Allyn Inc., Skaneateles Falls, New York, USA) introduced its new ophthalmoscope and later developed an FDA approved smartphone adapter called iExaminer [9, 23, 25]. According to the

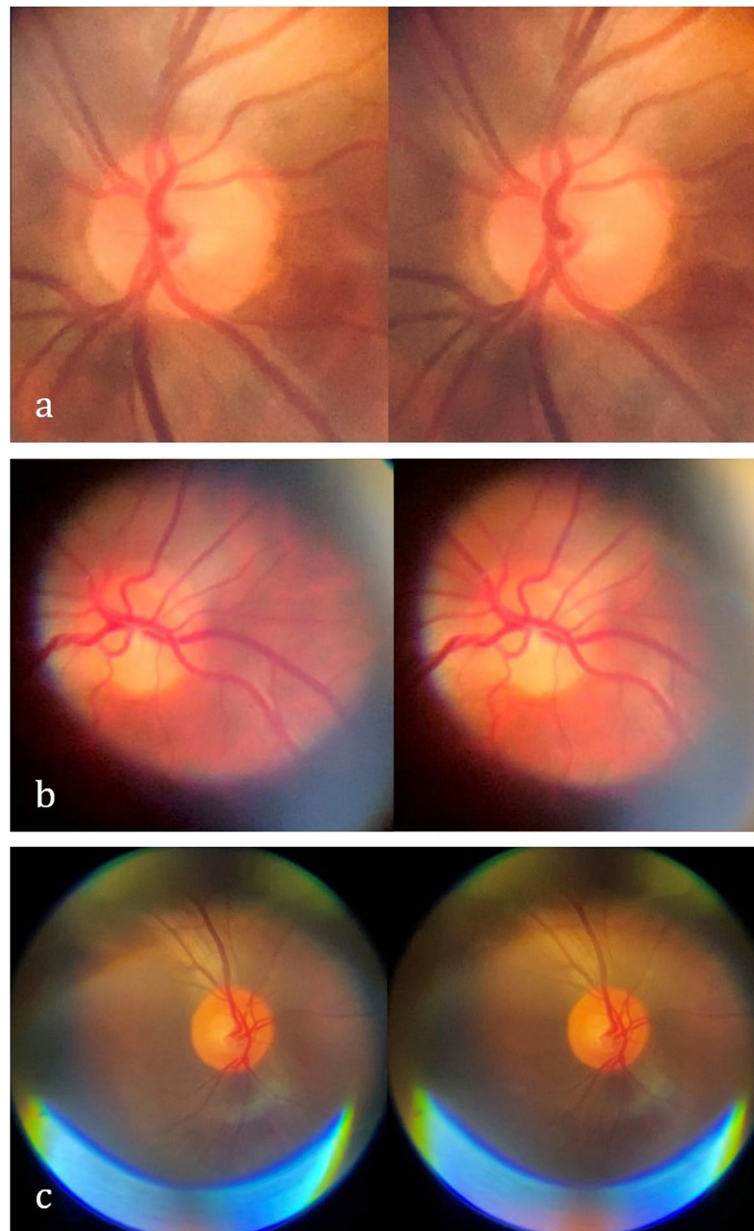


Fig. 3 Stereoscopic images of the ocular fundi generated by capturing two consecutive frames from a video recording after subtle eye movement (requires google cardboard or similar for stereoscopic viewing)

manufacturer's website, the adapter is suitable only for iPhone 4, 4S, 6, 6S, 6 Plus and 6S Plus which are outdated models and unfortunately do not provide satisfactory image quality. Therefore, we designed our own adapter which is suitable for any smartphone. Thus, it does not have to be redesigned with each new generation of smartphones. As of the time of this writing, the adapter is not FDA approved and is meant to be used only in research settings. Current smartphones can take

high-quality video recordings, allowing the examiner to rewind the video and choose the best frame for storing in the patient's chart. It also allows assessing the venous pulsation. What is more exciting, microscopic eye movements allow extracting side-by-side photos from the source fundoscopic video, which can be used for 3D reconstruction and stereoscopic image viewing, which has been shown to increase diagnostic accuracy in ophthalmological pathologies (Fig. 4 a-c) [4–7, 18].

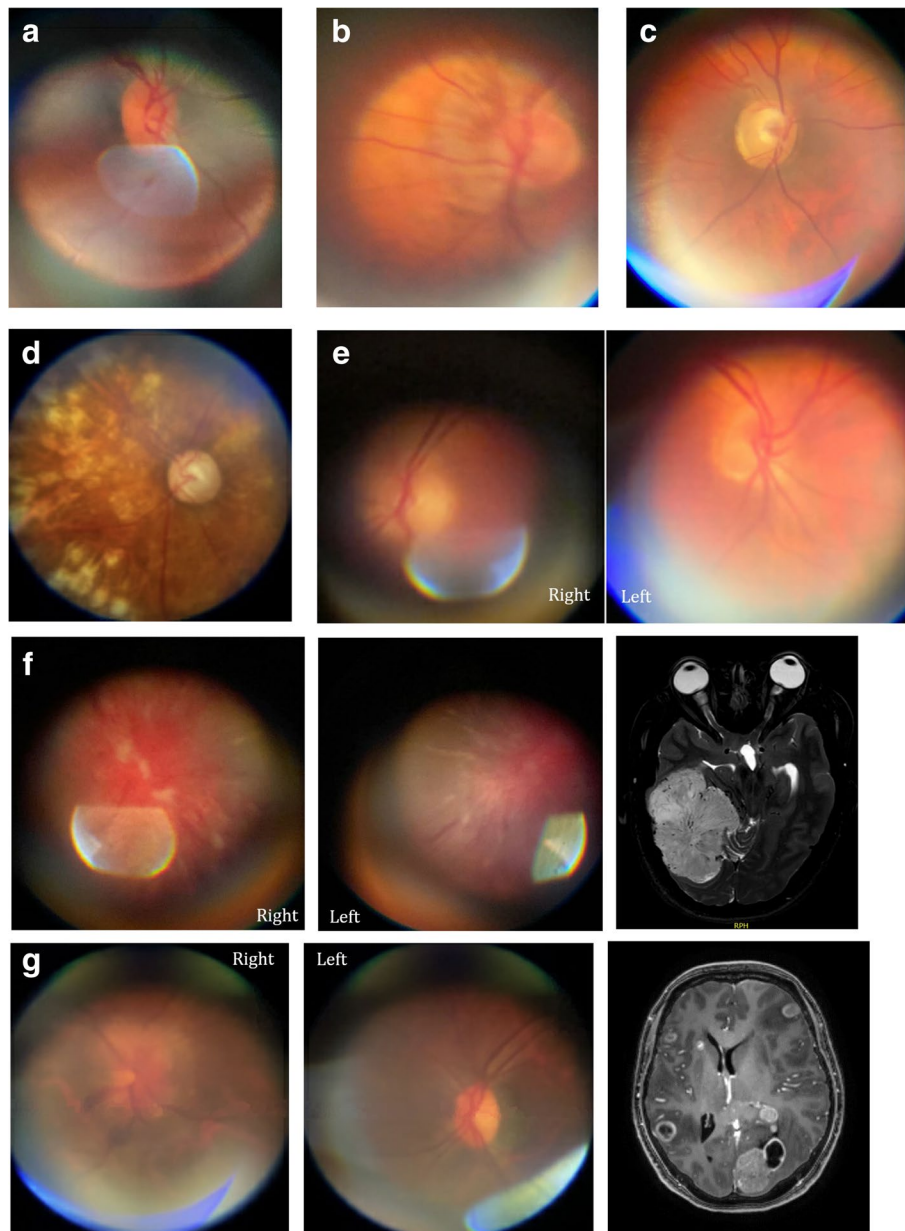


Fig. 4 Fundoscopic abnormalities and incidental findings. **a.** Incidental finding of a small optic disc in a 57 yo woman with blurry vision and migraine attack. **b.** Excessive myelination of optic disc in an 89 yo woman with binocular diplopia of unclear etiology **c.** Optic disc pallor in a 30 yo woman with vision loss, who was subsequently diagnosed with Neuromyelitis Optica. **d.** Multiple laser ablation scars in a 76 yo man with blurred vision, fixed and dilated pupil, who was found to have acute angle closure glaucoma. **e.** Bilateral grade 2 papilledema in a 55 yo with Anaplastic ependymoma. **f.** Bilateral grade 4 papilledema in a 40 yo woman with blurry vision, who was found to have a large right tentorial meningioma. **g.** Foster-Kennedy syndrome in a 50 yo man with metastatic lung cancer.

In our study image acquisition was successful in all patients, even those who were uncooperative or had depressed level of consciousness, mainly due to utilization of video recording and ability to use less light intensity thanks to high-quality of current smartphone

cameras. There was a steep learning curve for examining difficult patients, which sometimes required an assistant to keep eyelids open.

Multiple studies have shown that medical students and junior residents prefer using fundus photography

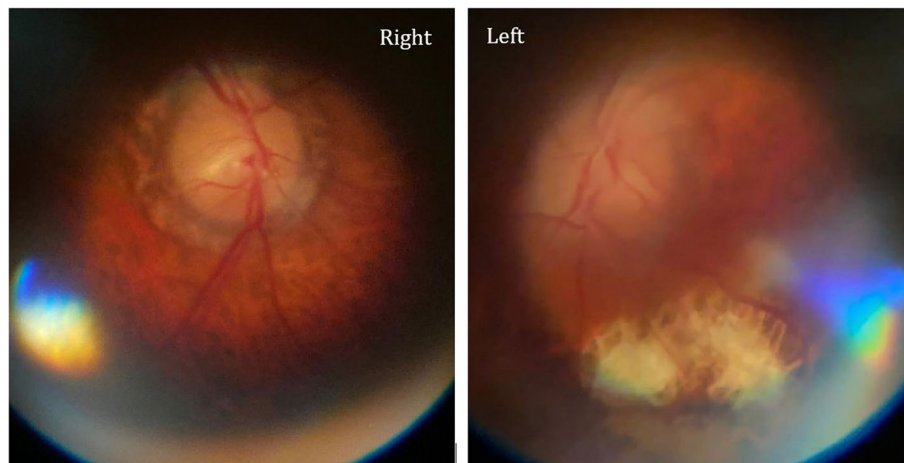


Fig. 5 Bilateral papilledema (grade 1 on the right and grade 3 on the left) in a 78-years-old patient with leptomeningeal carcinomatosis

over direct ophthalmoscopy and it results in greater diagnostic accuracy [10, 15, 19, 20]. In our experience, medical students rotating with the neurology department were able to take high-quality fundus videographs after only 15–20 min of demonstration and practice.

We are planning to evaluate the new PanOptic adapter further by including all residents in the department. We will also expand its use to all inpatient and outpatient clinical settings and evaluate limiting factors for widespread utilization of fundus video/photography, such as hesitation to adopt a new exam tool or medico-legal concerns tied to image interpretation.

Conclusions

We present our initial experience of feasibility and practicality of a custom-built universal smartphone adapter for PanOptic ophthalmoscope to obtain videographs and photographs of ocular fundus in patients presenting to the emergency department with a neurological complaint. Acquisition of high-quality photos enables a high-yield diagnostic tool, allows revisiting the image in patient's chart and serves as a great teaching tool. This study was intended to test the feasibility and practicality of smartphone funduscopy but not diagnostic accuracy, hence the limitation of the study is absence of a control group and blinded outcome.

Improvement of smartphone cameras, along with the method of obtaining stereoscopic images as detailed in the article, creates an opportunity to investigate the utility of stereo-funduscopy in daily clinical practice without using sophisticated and costly equipment.

Acknowledgments

None.

Authors' contributions

TK designed the panoptic adapter, performed fundoscopic examinations, collected and interpreted the data and was a major contributor in writing the manuscript. LM interpreted the data and was a major contributor in writing the manuscript. TM interpreted the data and was a major contributor in writing the manuscript. All authors read and approved the final manuscript.

Funding

None.

Availability of data and materials

The datasets used and/or analyzed during the current study are available from the corresponding author on reasonable request.

Declarations

Ethics approval and consent to participate

All methods were performed in accordance with the relevant guidelines and regulations. According to Policy Number 16 outlined in "Standard Operating Policies and Procedures" of IRB Committee of the University of California, Irvine, "Quality Improvement activities designed to continuously improve the quality or performance of a department or program or health care" do not require prior IRB approval. Since the above data was collected as part of the resident quality improvement project, IRB approval was waived.

Upon admission to the hospital all patients or their legal representatives signed general Terms and Conditions agreement, which reads: "Use of medical information and specimens: I understand that my medical information, photographs and/or video in any form may be used for other UC Irvine Health purposes, such as quality improvement, patient safety and education. I also understand that my medical information and tissue, fluids, cells and other specimens (collectively, "Specimens") that UC Irvine Health may collect during the course of my treatment and care may be used and shared with researchers." Signed terms and conditions forms for all patients are available upon reasonable request. Furthermore, funduscopy is a part of neurological exam and does not require separate written consent.

Consent for publication

Not applicable.

Competing interests

The authors declare that they have no competing interests.

Author details

¹Department of Neurology, University of California, Irvine, USA. ²Department of Pathology & Laboratory Medicine, University of California, Irvine, USA.

Received: 6 September 2021 Accepted: 1 February 2022
Published online: 19 February 2022

References

- Golombievski E, Doerrler MW, Ruland SD, McCoyd MA, Biller J. Frequency of direct funduscopy upon initial encounters for patients with headaches, altered mental status, and visual changes: A pilot study. *Front Neurol*. 2015;10–2.
- Shubhakaran K, Bidot S, Bruce BB, Newman NJ, Biousse V. Nonmydriatic retinal photography in the evaluation of acute neurologic conditions. *Neurol Clin Pract*. 2014;4:94–5.
- Ko MW, Busis NA. Tele-Neuro-Ophthalmology: Vision for 20/20 and Beyond. *J Neuroophthalmol*. 2020;40:378–84.
- Emanuele N, Klein R, Moritz T, Davis MD, Glander K, Anderson R, et al. Comparison of dilated fundus examinations with seven-field stereo fundus photographs in the Veterans Affairs Diabetes Trial. *J Diabetes Complications*. 2009;23:323–9.
- Asakawa K, Kato S, Shoji N, Morita T, Shimizu K. Evaluation of optic nerve head using a newly developed stereo retinal imaging technique by glaucoma specialist and non-expert-certified orthoptist. *J Glaucoma*. 2013;22:698–706.
- Yokoyama Y, Tanito M, Nitta K, Katai M, Kitaoka Y, Omodaka K, et al. Stereoscopic analysis of optic nerve head parameters in primary open angle glaucoma: The glaucoma stereo analysis study. *PLoS One*. 2014;9:e99138.
- Nakagawa T, Suzuki T, Hayashi Y, Mizukusa Y, Hatanaka Y, Ishida K, et al. Quantitative depth analysis of optic nerve head using stereo retinal fundus image pair. *J Biomed Opt*. 2008;13.
- von Elm E, Altman DG, Egger M, Pocock SJ, Gøtzsche PC, Vandenbroucke JP. The strengthening of reporting of observational studies in epidemiology (STROBE) statement: Guidelines for reporting observational studies. *Int J Surg*. 2014;12:1495–9. <https://doi.org/10.1016/j.ijsu.2014.07.013>.
- MacKay DD, Garza PS, Bruce BB, Newman NJ, Biousse V. The demise of direct ophthalmoscopy: A modern clinical challenge. *Neurol Clin Pract*. 2015;5:150–7.
- Pérez MA, Bruce BB, Newman NJ, Biousse V. The use of retinal photography in nonophthalmic settings and its potential for neurology. *Neurologist*. 2012;18:350–5.
- Irani NK, Bidot S, Peragallo JH, Esper GJ, Newman NJ, Biousse V. Feasibility of a Nonmydriatic Ocular Fundus Camera in an Outpatient Neurology Clinic. *Neurologist*. 2020;25:19–23.
- Bruce BB, Biousse V, Newman NJ. Nonmydriatic ocular fundus photography in neurologic emergencies. *JAMA Neurol*. 2015;72:455–9.
- Mackay DD, Garza PS. Ocular Fundus Photography as an Educational Tool. *Semin Neurol*. 2015;35:496–505.
- Bruce BB, Newman NJ, Pérez MA, Biousse V. Non-mydratic ocular fundus photography and telemedicine: Past, present, and future. *Neuro-Ophthalmology*. 2013;37:51–7.
- Biousse V, Bruce BB, Newman NJ. Ophthalmoscopy in the 21st century: The 2017 H. Houston Merritt Lecture. *Neurology*. 2018;90:167–75.
- Alm M, Hautala N, Bloigu R, Huhtakangas J. Comparison of optic disc evaluation methods in neurology emergency patients. *Acta Neurol Scand*. 2019;140:449–51.
- Thulasi P, Fraser CL, Biousse V, Wright DW, Newman NJ, Bruce BB. Nonmydriatic ocular fundus photography among headache patients in an emergency department. *Neurology*. 2013;80:432–7.
- Dunn HP, Teo KZ, Smyth JWP, Weerasinghe LS, Costello J, Pampapathi P, et al. Using non-mydratic fundus photography to detect fundus pathology in Australian metropolitan emergency departments: A prospective prevalence and diagnostic accuracy study. *EMA -Emerg Med Australas*. 2021;33:302–9.
- Bruce BB, Lamirel C, Biousse V, Ward A, Heilpern KL, Newman NJ, et al. Feasibility of nonmydratic ocular fundus photography in the emergency department: Phase i of the FOTO-ED study. *Acad Emerg Med*. 2011;18:928–33.
- Zafar S, Cardenas YM, Leishangthem L, Yaddanapudi S. Opinion and special articles: Amateur fundus photography with various new devices Our experience as neurology residents. *Neurology*. 2018;90:897–901.
- Laurent C, Hong SC, Cheyne KR, Ogbuehi KC. The detection of spontaneous venous pulsation with smartphone video ophthalmoscopy. *Clin Ophthalmol*. 2020;14:331–7.
- Rodenbeck SJ, MacKay DD. Examining the ocular fundus in neurology. *Curr Opin Neurol*. 2019;32:105–10.
- Poletti M, Listorti C, Rucci M. Microscopic eye movements compensate for nonhomogeneous vision within the fovea. *Curr Biol*. 2013;23:1691–5.
- Dunn HP, Kang CJ, Marks S, Witherow JL, Dunn SM, Healey PR, et al. Perceived usefulness and ease of use of funduscopy by medical students: a randomised crossover trial of six technologies (eFOCUS 1). *BMC Med Educ*. 2021;21:1–9.
- Dunn HP, Marks S, Teo KZ, Dunn SM, Healey PR, White AJ. eFOCUS 2: A randomised crossover trial of smartphone funduscopy and direct ophthalmoscopy aiming to improve optic disc interpretation by medical students with e-learning support. *Clin Exp Ophthalmol*. 2021;49:704–13. <https://doi.org/10.1111/ceo.13977>.

Publisher's Note

Springer Nature remains neutral with regard to jurisdictional claims in published maps and institutional affiliations.

Ready to submit your research? Choose BMC and benefit from:

- fast, convenient online submission
- thorough peer review by experienced researchers in your field
- rapid publication on acceptance
- support for research data, including large and complex data types
- gold Open Access which fosters wider collaboration and increased citations
- maximum visibility for your research: over 100M website views per year

At BMC, research is always in progress.

Learn more biomedcentral.com/submissions

