

# UCLA

## UCLA Previously Published Works

### Title

Lateral Thinking: The Lateral Arm Approach for Stereotactic-Guided Breast Biopsies. What We've Learned So Far

### Permalink

<https://escholarship.org/uc/item/1kg5h22s>

### Journal

Current Radiology Reports, 12(4)

### ISSN

2167-4825

### Authors

Najmi, Nooshin  
Rashid, Mollie A  
Fardanesh, Reza  
[et al.](#)

### Publication Date

2024-04-01

### DOI

10.1007/s40134-024-00424-9

Peer reviewed

# **Lateral Thinking: The Lateral Arm Approach for Stereotactic-Guided Breast Biopsies. What We've Learned so Far**

## **Authors:**

Nooshin Najmi, M.D <sup>(1)</sup>; Mollie Rashid, M.D <sup>(1)</sup>; Reza Fardanesh, M.D <sup>(1)</sup>; Cheryce P. Fischer, M.D <sup>(1)</sup>.

## **Corresponding author:**

Nooshin Najmi; nnajmi@mednet.ucla.edu

## **Affiliations:**

(1) Department of Radiological Sciences, David Geffen School of Medicine, University of California at Los Angeles, Los Angeles, California, USA.

## **Declaration of competing interests:**

The authors declare that they have no competing interests

**Authors Disclosures:** None.

## **Abstract**

**Purpose of review:** The purpose of this paper is to review a novel technique for stereotactic-guided breast biopsies utilizing the lateral arm approach.

**Recent findings:** Successful stereotactic-guided biopsies require careful consideration of lesion location and patient anatomy. Cases that cannot be safely performed are often referred for surgical biopsy, which can increase patient anxiety and delay diagnosis. The lateral arm approach provides an alternative needle approach for biopsy that can mitigate some of the most common exclusion criteria for standard techniques. Although there are many benefits to the lateral arm approach, it has not yet been widely adopted. This article reviews the lateral arm approach, including patient selection, procedural technique, advantages, and disadvantages. Case examples utilizing the technique will also be discussed to illustrate our institutional experience (including procedural tips) and how the lateral arm approach can be integrated into breast imaging practice.

**Summary:** The lateral arm approach can expand the patient population that can undergo stereotactic-guided breast biopsy, which may obviate the need for surgical biopsy or short-term follow-up. The technique also allows for a creative approach to biopsy in challenging cases. Proficiency with the lateral arm approach can expand a

breast imager's interventional skills, improve patient care, and allow for more expedient diagnosis of suspicious breast findings.

**Keywords:** lateral arm, stereotactic-guided biopsy, tomosynthesis-guided biopsy, breast imaging

## **Introduction**

Breast cancer is the most common cancer in women in the United States, with an overall 13% risk of developing breast cancer [1]. Digital breast tomosynthesis (DBT) is used for the detection of breast cancer and involves multiple low-radiation projections obtained across an arc of a moving X-ray source that are reconstructed into a series of stacked images [2]. DBT improves both screening and diagnostic imaging outcomes and is emerging as the standard of care. It is also a powerful technique for performing breast biopsy procedures [3, 4]. Tomosynthesis-guided breast biopsy (TB) is the procedure of choice for mammographically visible findings with no ultrasound correlate, which include asymmetries, masses, architectural distortion, and calcifications. TB is performed with either a prone table or an upright DBT unit with improved patient comfort [4]. However, there are limitations for TB using the standard approach (vertical approach), which result in canceling the procedure and referring the patient to surgical biopsy in approximately 13% of patients [5•]. Image-guided biopsies have advantages over surgical biopsy, including less scarring, fewer complications, faster recovery, lower cost, and similar accuracy [6]. Therefore, image-guided biopsies are the preferred method of diagnosis. By introducing the lateral arm technique, the aforementioned limitations can be minimized, and only up to 4% of patients are sent for surgical biopsy for diagnosis due to unsuccessful TB [5•].

In August 1999, General Electric Medical Systems (Milwaukee, WI) introduced a lateral arm-support system for vacuum-suction needles to be added to upright stereotactic units [7]. In 2001, Lehman et al. described the accuracy of this system on an upright unit in a turkey breast model, and the accuracy was reported to be 100% in their study [8]. Although the lateral arm device approach has been available on the market as an add-on to stereotactic biopsy devices since 2007 [5•], it is still considered a new technique for most institutes. In this article, we will discuss the lateral arm approach, highlight its advantages and limitations, and discuss case examples.

## **Patient Selection, Advantages and Limitations**

The lateral arm approach widens the population of patients who can undergo tomosynthesis biopsy. Lesions that are not amenable to conventional tomosynthesis biopsy can often be biopsied using the lateral arm approach, thereby avoiding surgical biopsy.

Patients with thinner breasts can undergo a lateral arm approach biopsy when a conventional approach is not safe. Generally, the conventional approach requires a minimum breast thickness of at least 2 cm to avoid hitting the detector during the procedure. With the lateral arm approach, the minimum needed thickness of the breasts is much lower than that of the conventional approach, with multiple institutions reporting a minimum breast thickness of approximately 1 centimeter to safely perform the procedure [9, 10••, 11].

The lateral arm approach allows for increased visualization of the target throughout the procedure, whereas the lesion can become obscured by lidocaine during a conventional approach [5•, 7]. This can be particularly useful when targeting subtle lesions. Kerger et al also suggested a decrease in radiation dose to the patient due to a decreased number of views [5•].

Additionally, the lateral arm approach is ideal for targeting superficial and peripheral lesions, which would usually not be amenable to the conventional approach secondary to needle trough size [12]. Lesions near the chest wall may also be targeted more successfully using an upright table and lateral arm approach compared to the prone table conventional approach [7]. However, central lesions are more difficult to access with the lateral arm approach, and in larger breasts, there may be inadequate anesthesia along the biopsy tract due to the limits of a 9 cm spinal needle for anesthesia [5•, 11].

When selecting patients for lateral arm biopsy, general stereotactic biopsy patient selection considerations still apply, including whether to perform the procedure on a prone or upright table (if both are available). For instance, a prone biopsy table has a manufacturer-set weight limit. Additionally, the prone table requires that a patient be able to lay on their stomach for the duration of the procedure. This may be difficult in patients with mobility issues. However, patients who have had prior attempted biopsy with vasovagal reaction on an upright system may benefit from the prone table.

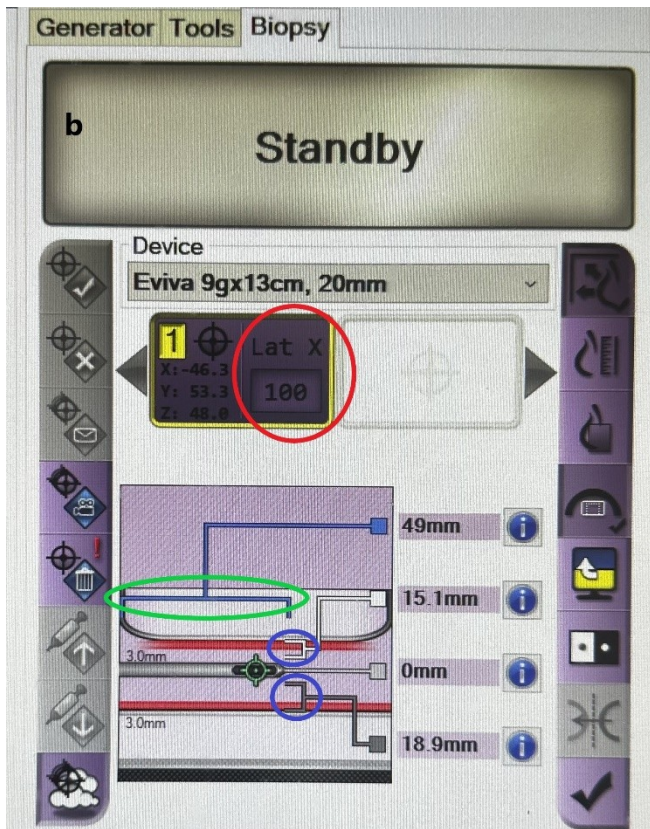

## **Technique**

The lateral arm approach can be performed using either a prone table or an upright unit with an add-on accessory or using a newer prone table where the device is already equipped on the unit. At our institute, we use the Hologic Affirm (Marlborough, MA) prone biopsy system with built in lateral arm or the Hologic Affirm lateral arm accessory for the upright unit and Eviva biopsy device. At our institute, we first attempt the vertical approach. If the area of interest is not amendable to biopsy using the vertical approach, the lateral arm approach is used. In the lateral arm approach, the needle is inserted parallel to the compression paddle, and the biopsy device moves along the X axis, as opposed to the vertical technique in which the needle is inserted perpendicular to the compression paddle and the biopsy device moves along the Z axis. In the prone table, given total 360-

degree breast access, the area of interest can be accessed with a lateral arm approach whether the underlying view is craniocaudal, mediolateral, or lateromedial. In the upright unit, the lesion can usually be accessed from the right or left, with the breast positioned in craniocaudal view. In the Hologic Affirm Upright unit, the left lateral accessory is color coded blue, and the right is yellow.

With the upright unit, when the decision is made to proceed with the lateral arm technique, the needle guide holder is removed, and the lateral arm compression paddle is installed on the unit, signaling the system to target for this approach. The adaptor and needle guide are then connected to the carriage. Then, the device mount is slid onto the lateral arm and locked. Then, the lateral arm stand is installed on the image receptor to elevate the breast from the image detector. While positioning the breast between the compression paddle and stand, it is important that the edge of the compression paddle is aligned with the breast edge on the entrance side. This will reduce miscalculation of the X and X lateral coordinates.

After the breast is in the appropriate position, a scout tomosynthesis image is obtained, and the target is identified. By a single click on the target, the coordinates (X, Y, Z and lateral X) are automatically calculated and transmitted to the biopsy control module. Targeting slightly anterior to the lesion with directional sampling toward the chest wall or targeting slightly posterior to the lesion with directional sampling toward the nipple reduces lesion movement toward the safety margin. On the procedure screen, in addition to the coordinates, the safety margins to the superior and inferior skin surfaces and the depth of needle needed for local anesthesia are shown. After confirming the coordinates on the biopsy control module, the Z rail on the Affirm is advanced to the target by pushing the motor enabled buttons. Then, the Z knob is used to move the Z rail until all the X, Y and Z differential lines are green and all the differential numbers are zero. The X-lateral calculates how far the biopsy device needs to be manually inserted in the breast and should be set on the lateral arm. Then, the sterile needle guide is attached, and the biopsy device is loaded onto the lateral arm. (Fig. 1).

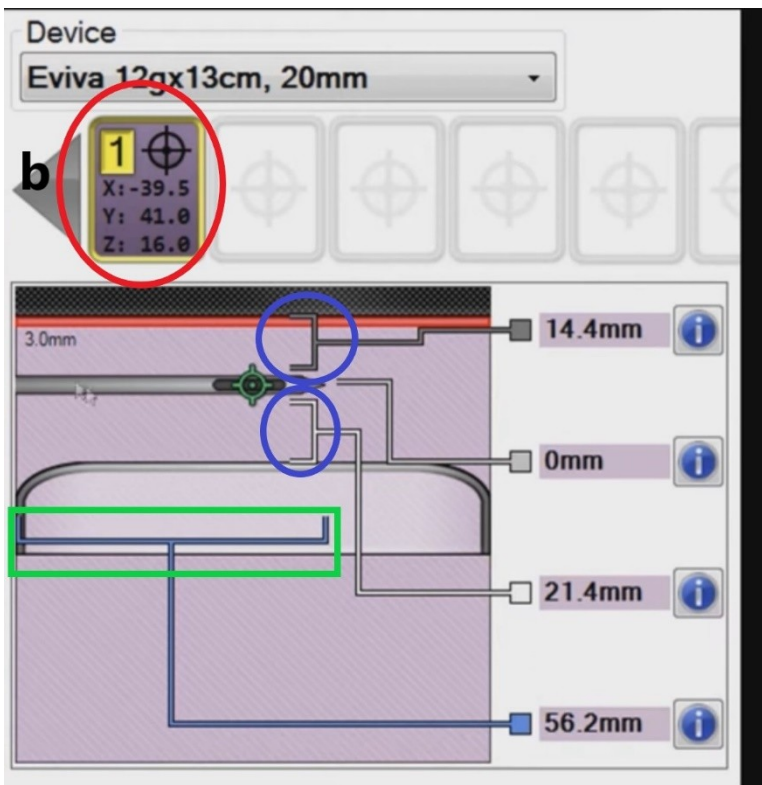
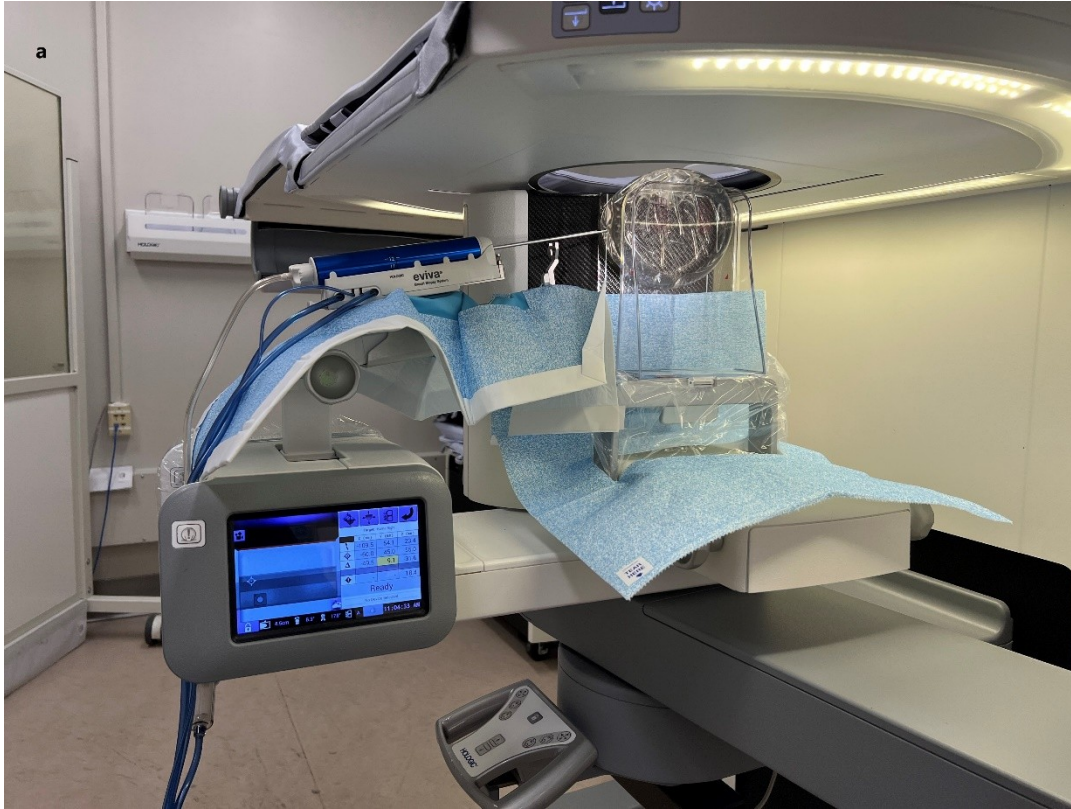


**Fig. 1 a** Illustrates different parts of the upright lateral arm accessory: 1. Lateral arm compression paddle; 2. Lateral arm stand; 3. Lateral arm accessory; 4. Adaptor and needle holder connected to the carriage; 5. Z knob; 6. X- lateral coordinate; 7. X-stop. **b** Procedure screen on the upright lateral arm approach biopsy, demonstrating the X-lateral coordinate (red circle) in addition to X, Y and Z. Safety margins to the compression paddle and detector are denoted by the blue circle. The distance from the skin entrance to the needle tip is denoted by the green oval. This distance is used to determine the depth needed for local anesthesia

The distance from the edge of the biopsy paddle to the needle tip, shown on the procedure screen, can be used to guide the depth of the local anesthesia. Given that this distance is usually greater than the standard needle used for numbing, an 18 G, 9 cm long spinal needle is used for local anesthesia. The device is then inserted manually into the breast, stopping at the lateral X. After verifying that the numbers at the needle location and the X-stop are the same value, the carriage should be locked. A prefire image is obtained to confirm the needle location, the biopsy device is fired, and the postfire image is obtained. After confirming the position of the needle on the postfire image, targeted sampling is performed. As the lateral arm technique is usually used in thin breasts, the important safety margins to consider are the distances to the skin surfaces. To avoid suctioning the skin toward the trough during the biopsy, biopsy toward the head and feet should be avoided. After confirming the target in the specimen, a biopsy marker is placed.

A prone table unit with a built-in lateral arm does not need a lateral arm accessory or needle mount. When the decision is made to utilize the lateral arm approach, the biopsy arm should be unlocked and positioned to access the breast from the side. In the prone table, the breast can be accessed from superior or inferior when the breast is in mediolateral or lateromedial position or can be accessed from the lateral or medial when the breast is in craniocaudal position. After the breast is in the appropriate position, a scout tomosynthesis image is obtained, and the area of interest is targeted. In the prone table, no X-lateral coordinate needs to be calculated. By pushing the motor enable buttons, the biopsy arm will be in position for Y and Z coordinates. After local anesthesia is achieved, the needle is manually advanced in the breast to the X coordinate. After confirming the position of the needle in the prefire and postfire images, biopsy is performed. (Fig. 2).



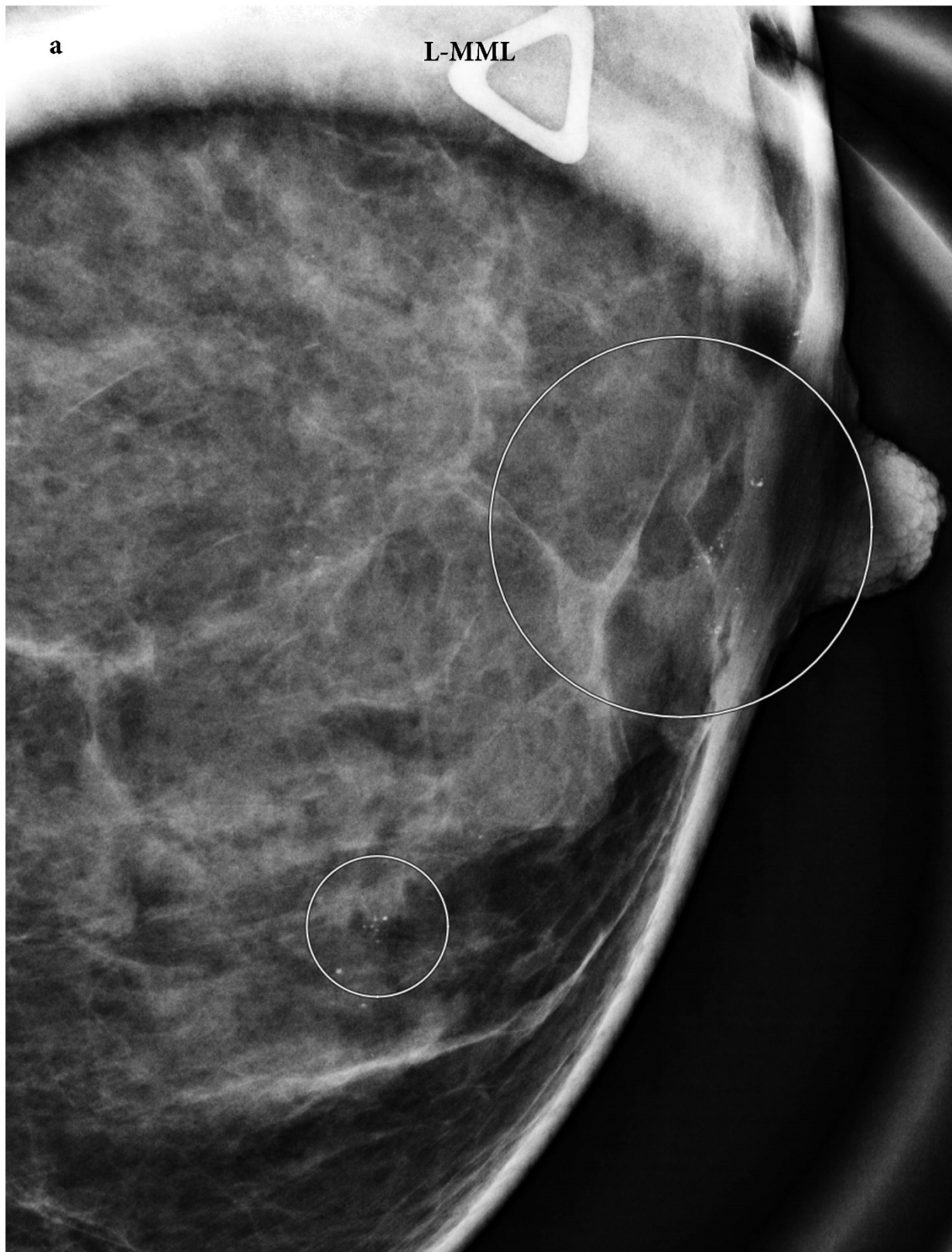


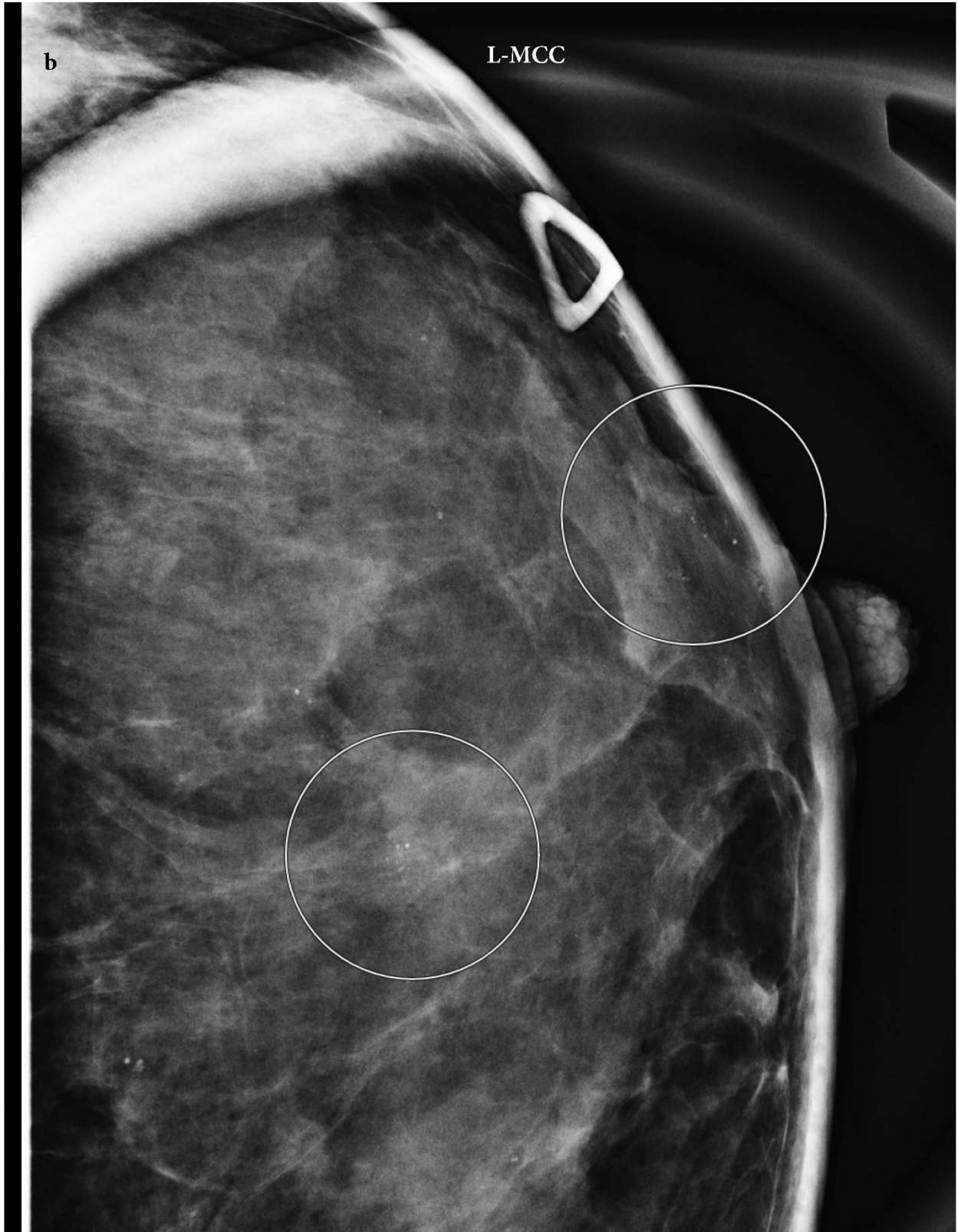


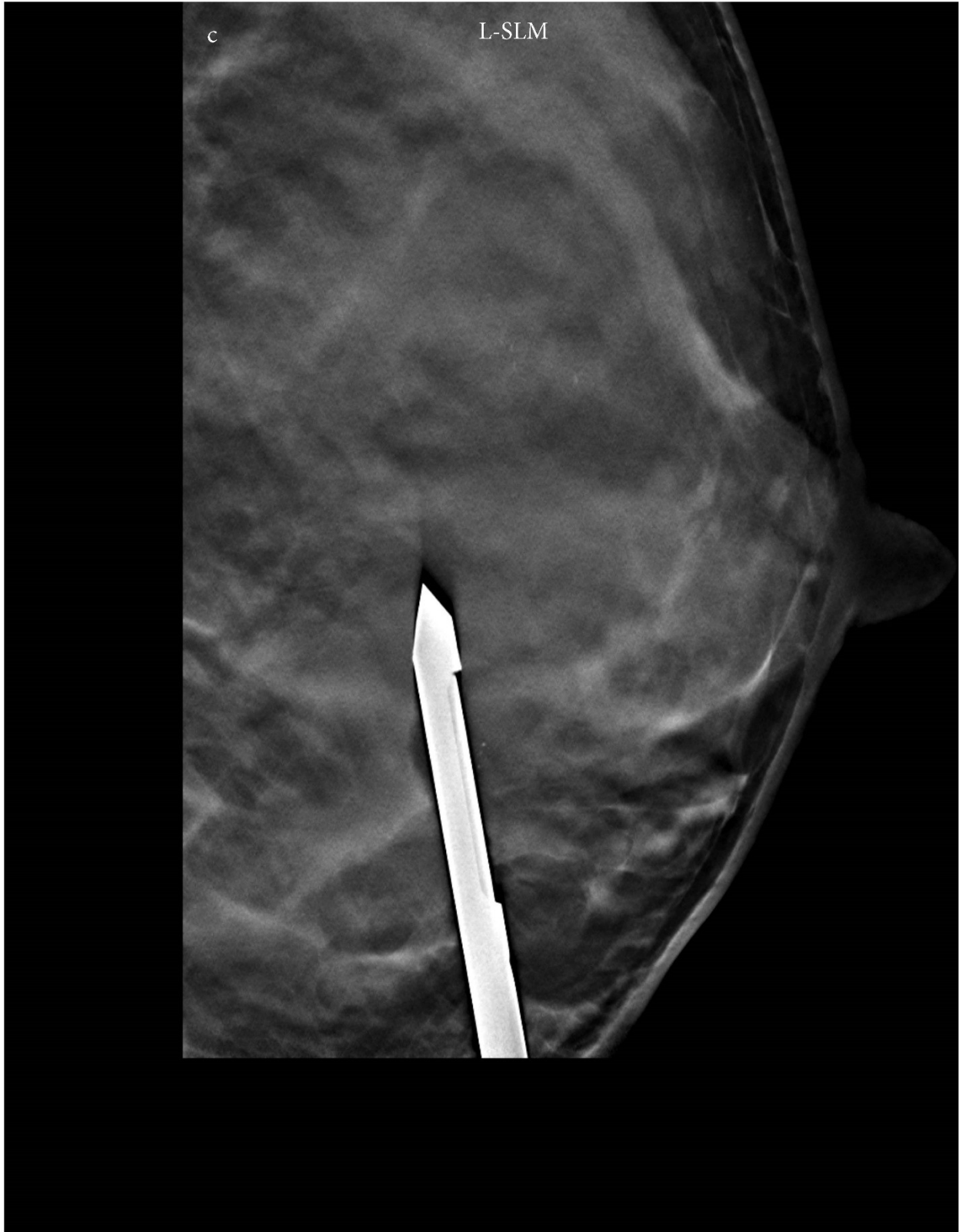**Fig. 2 a** Prone table lateral arm technique with the biopsy device inserted parallel to the compression paddle and the biopsy device moving along the X axis. **b** Procedure screen on the prone table lateral arm technique biopsy, demonstrating X, Y and Z coordinates (red circle); Safety margins to the compression paddle and detector denoted by the blue circle; The distance from the skin entrance to the needle tip is denoted by the green oval. This distance is used to determine the depth needed for local anesthesia

## Case Examples

**Case 1: A** 38-year-old woman presented with left breast palpable concern, and diagnostic mammogram and targeted ultrasound demonstrated no suspicious masses or areas of architectural distortion. However, two groups of amorphous calcifications were identified, one in the subareolar region and the other at the 6 o'clock position. Subareolar location is usually a challenging location for stereotactic biopsies given the less compression of the breast in this location, even in breasts with more than 3 cm thickness. This patient's breast thickness was 2 cm, and therefore, the lateral arm approach was attempted for both groups on the prone table. For the 6 o'clock calcifications, the patient was positioned lateromedially, and the calcifications were sampled using the lateral arm technique from below, since the shortest distance from skin to target was from an inferior approach. For the subareolar calcifications, the patient was positioned craniocaudally, and the calcifications were sampled using the lateral arm technique with a lateral approach. Given the superficial location of these calcifications in the subareolar region, a blunt-ended petite needle was used to ensure safety margins. The pathology results for both groups were benign breast tissue and calcifications associated with microcysts. (Fig. 3).

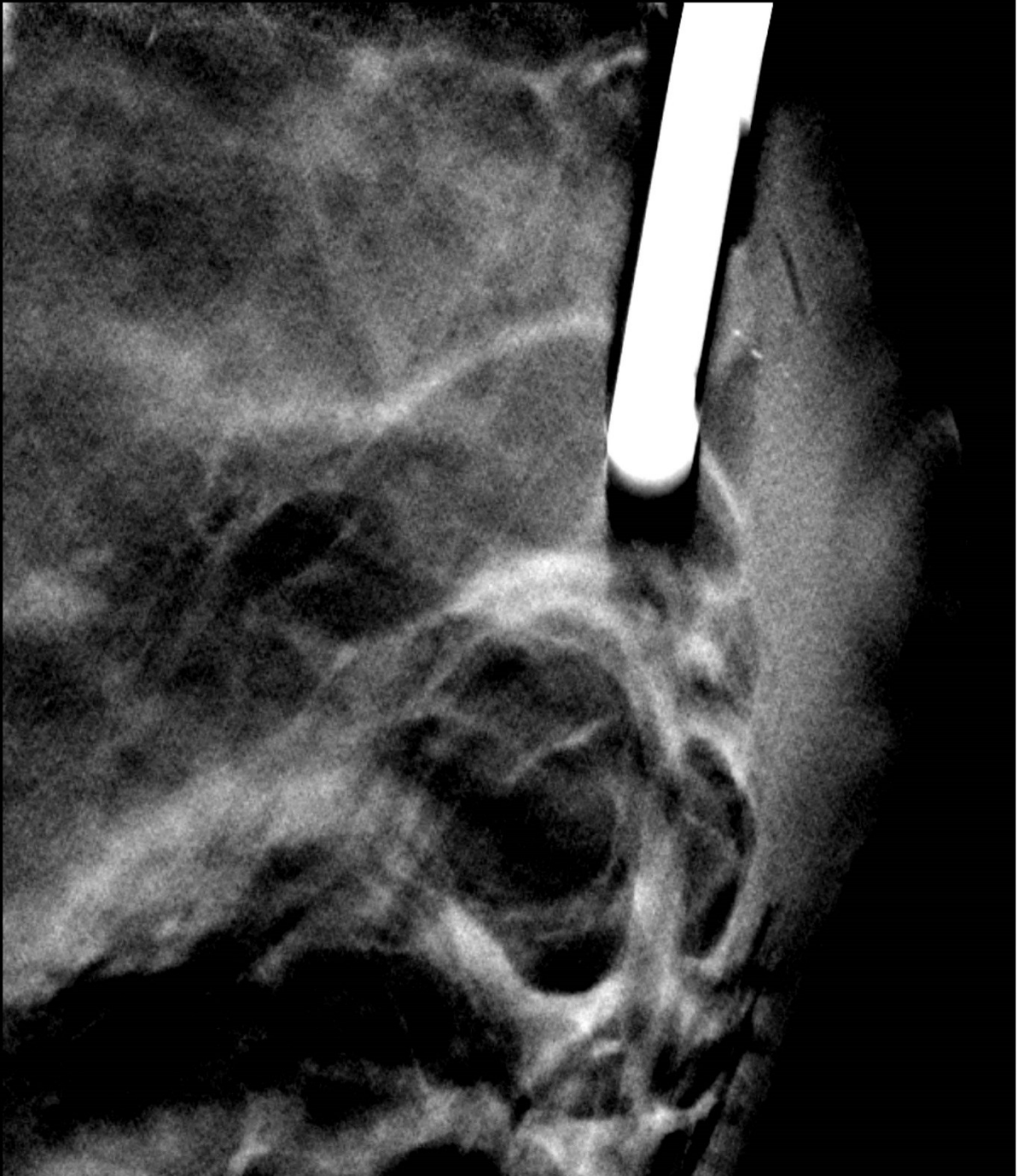






d

L-SCC

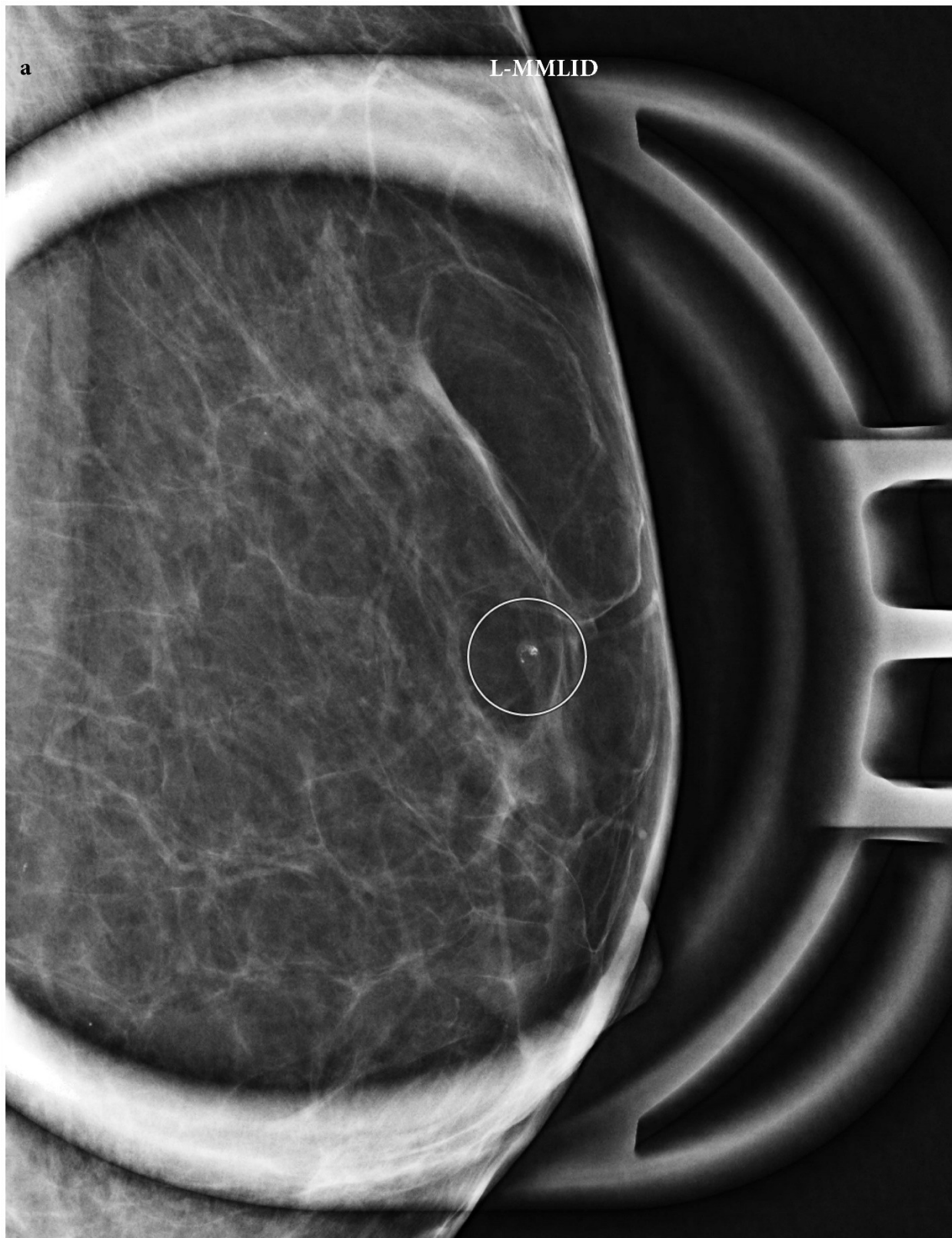


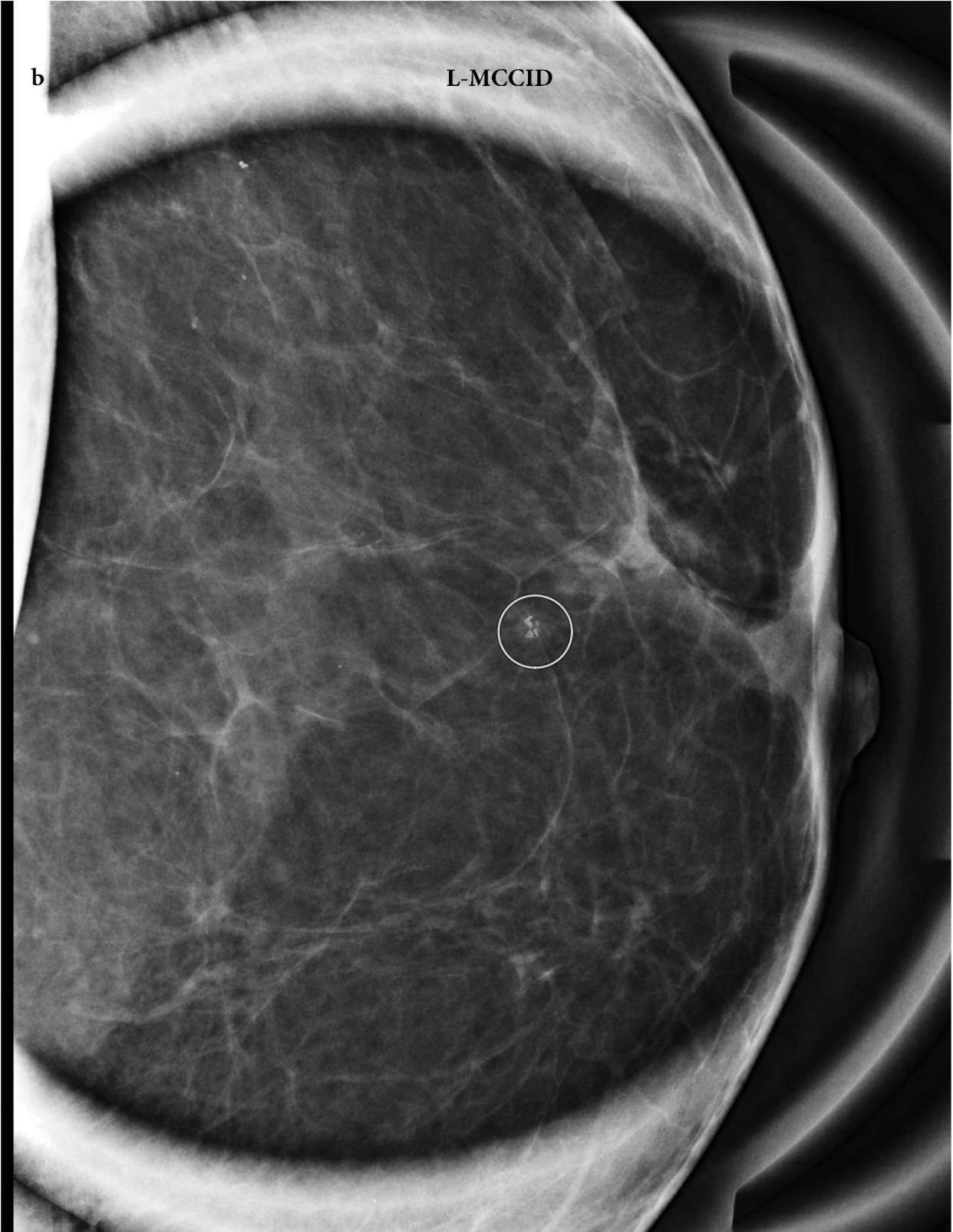**Fig. 3 a and b**, Mediolateral magnification and Craniocaudal magnification views of the left breast show two groups of amorphous calcifications in the subareolar region

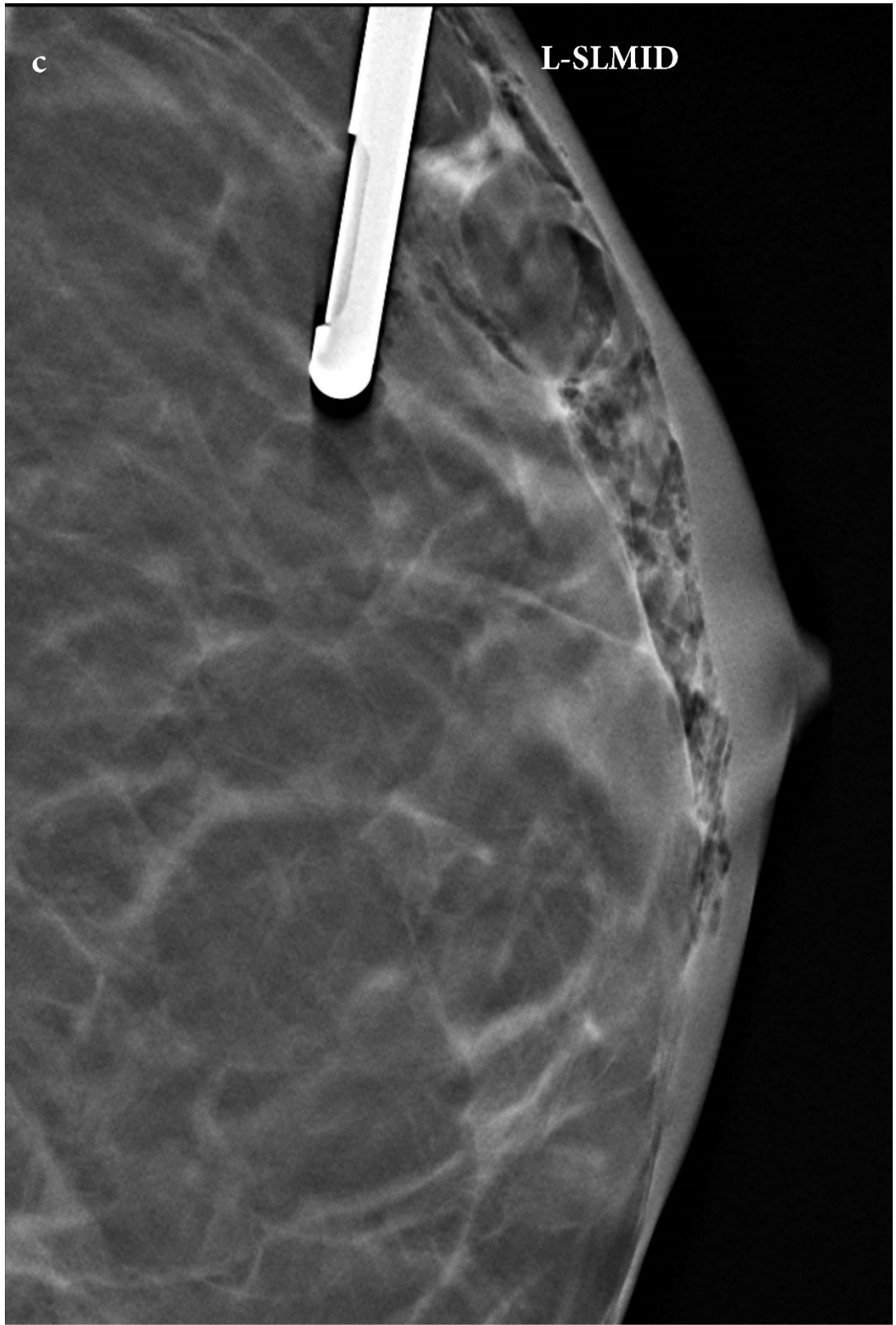and at 6 o'clock, denoted by circles. **c** Postfire image of the tomosynthesis-guided biopsy of the 6 o'clock calcifications utilizing inferior access, lateral arm approach, shows the standard needle trough in the appropriate position in relation to the calcifications. **d** Postfire image of the tomosynthesis-guided biopsy of the subareolar calcifications utilizing lateral access, lateral arm approach, showing the blunt-ended petite needle trough in the appropriate position in relation to the calcifications

**Case 2: A** 58-year-old woman with subpectoral silicone implants called back for a new group of calcifications in the left breast. Magnification views revealed coarse heterogeneous calcification with grouped distribution at 12 o'clock, for which stereotactic biopsy was recommended. Patients with breast implants generally have thinner breasts, and this patient's breast thickness was 2.2 cm. Therefore, the lateral arm technique was utilized for tissue sampling. Given that a shorter distance was achievable from a superior approach, the breast was positioned lateromedially with the implant displaced, and the calcifications were accessed from a superior approach. Pathology revealed calcifications associated with chronic inflammation and foreign body giant cell reaction. (Fig. 4).





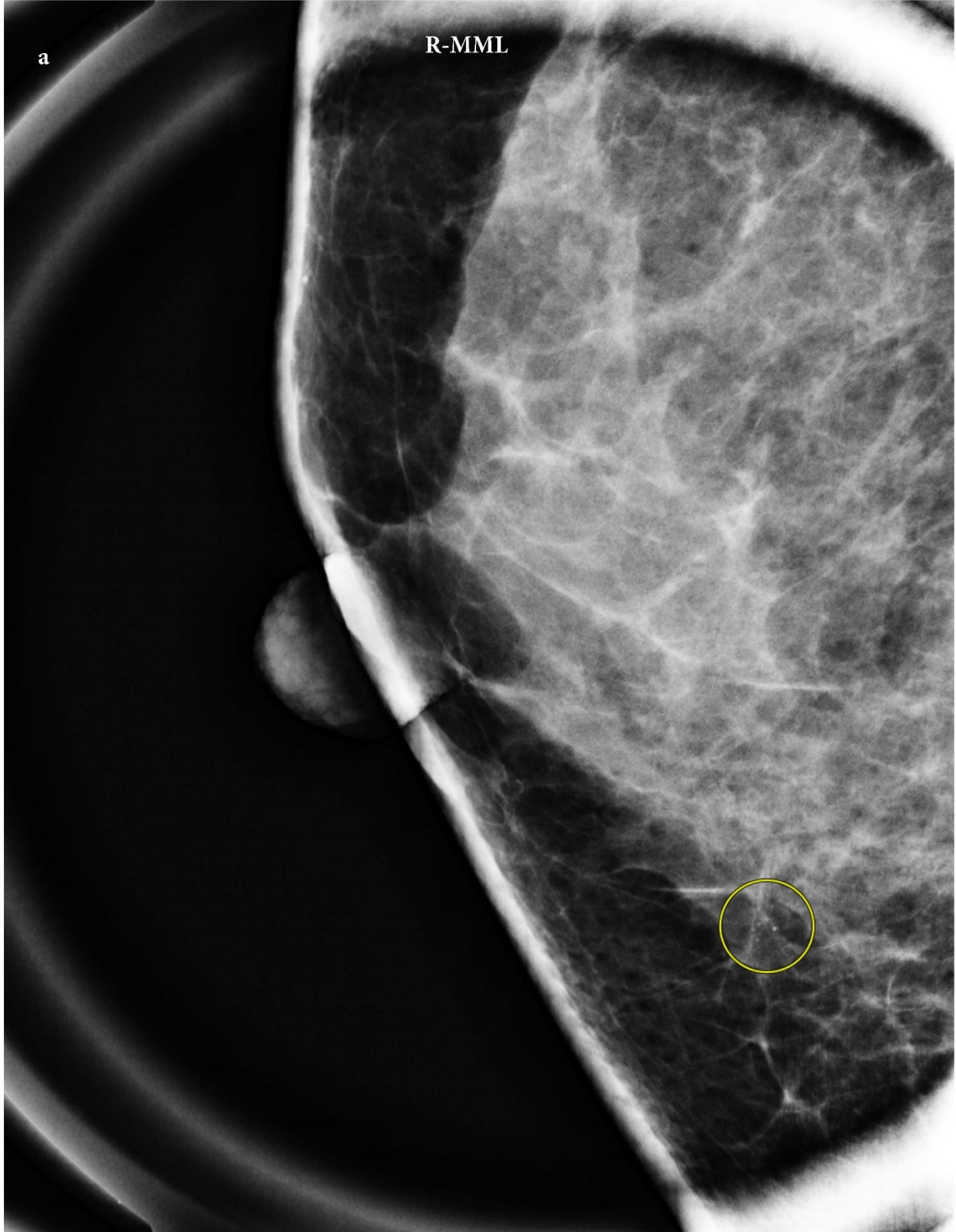



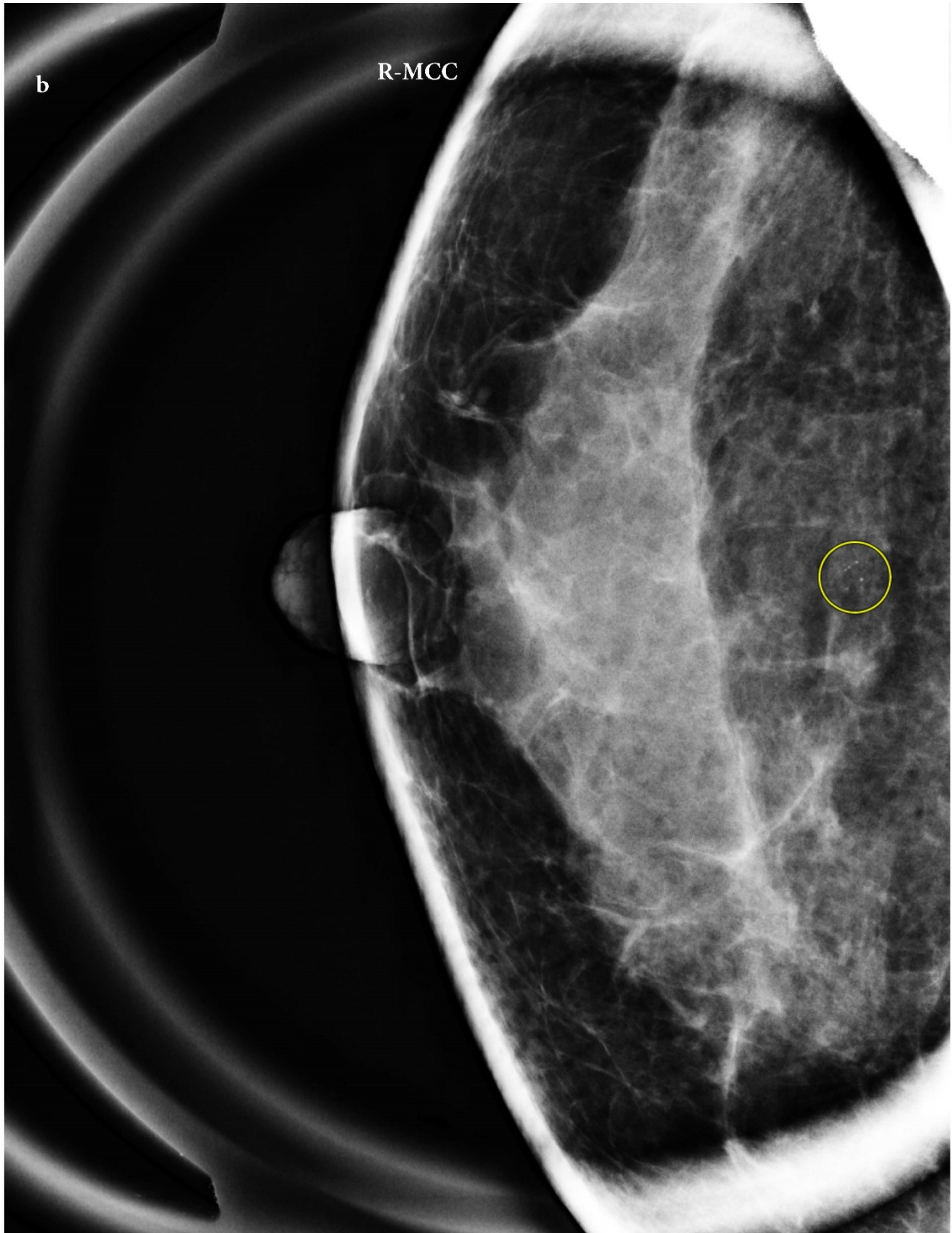
**Fig. 4 a and b**, Mediolateral implant displaced magnification and Craniocaudal implant displaced magnification views of the left breast show a group of coarse

heterogeneous calcifications at 12 o'clock, denoted by circles. **c** Postfire image of the tomosynthesis-guided biopsy of the 12 o'clock calcifications utilizing superior access, lateral arm approach, showing the blunt ended petite needle trough covering the calcifications

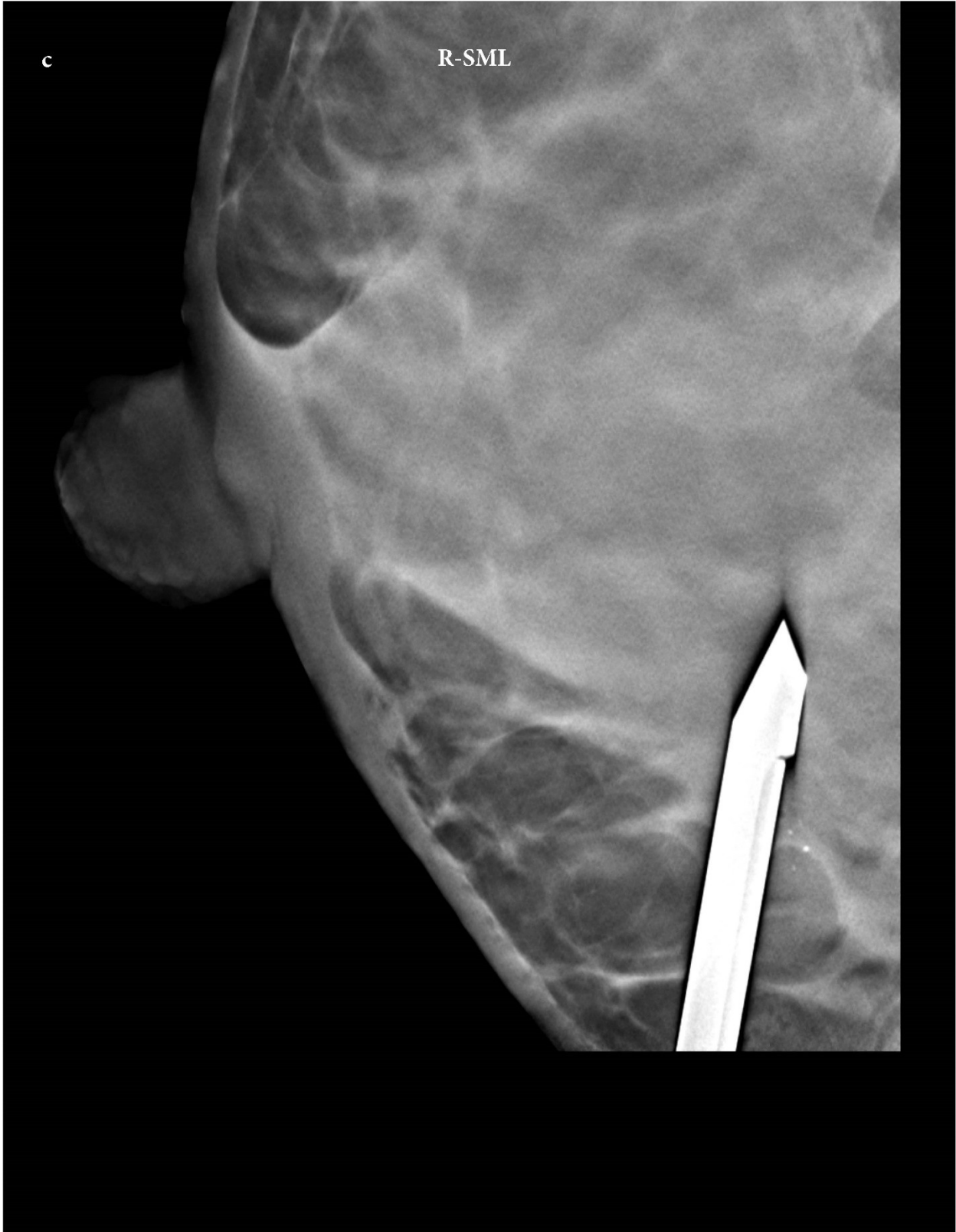
**Case 3: A** 48-year-old woman called back for a new group of calcifications in the right breast. Magnification views showed grouped amorphous calcifications at 6 o'clock, for which stereotactic biopsy was recommended. The patient's breast thickness at the time of diagnostic work-up was 2.7 cm. First, conventional prone table stereotactic biopsy from below was attempted. However, at the time of targeting for biopsy, the breast thickness was approximately 2 cm, and therefore, the conventional approach was not successful. The patient's breast was repositioned to a mediolateral view, and the calcifications were accessed from inferiorly, utilizing the lateral arm approach. Pathology revealed calcifications associated with mucocele-like lesion. (Fig. 5).







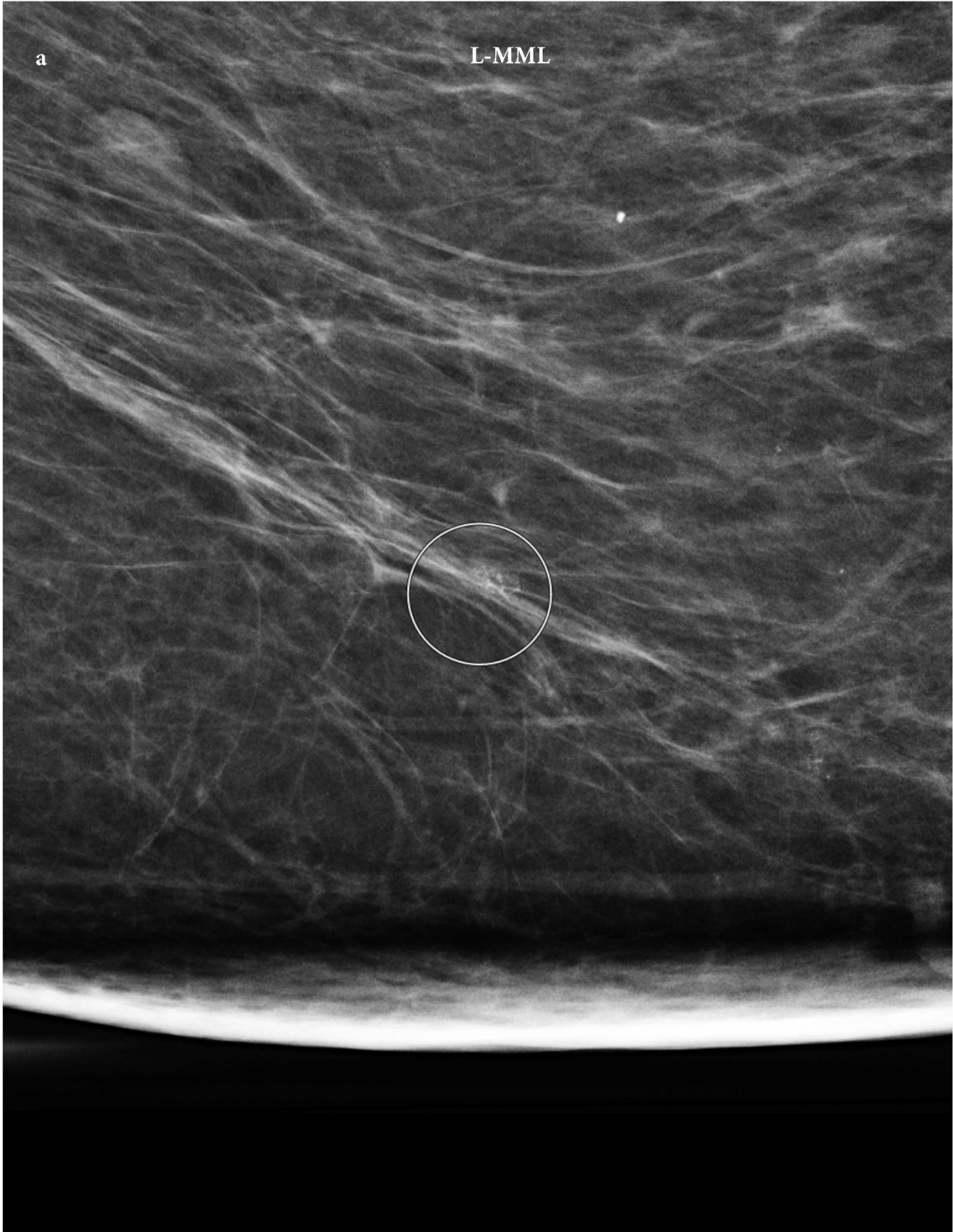


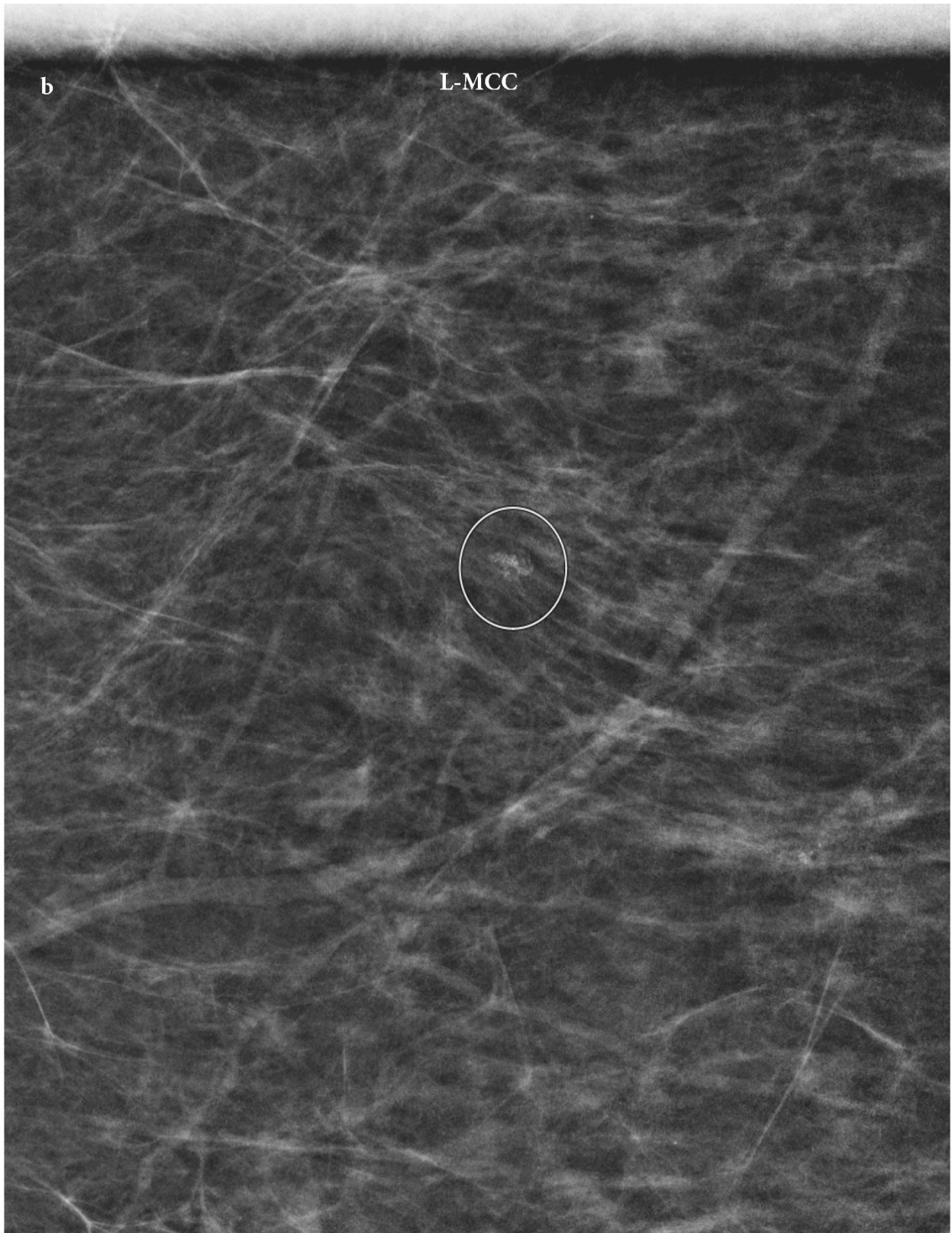


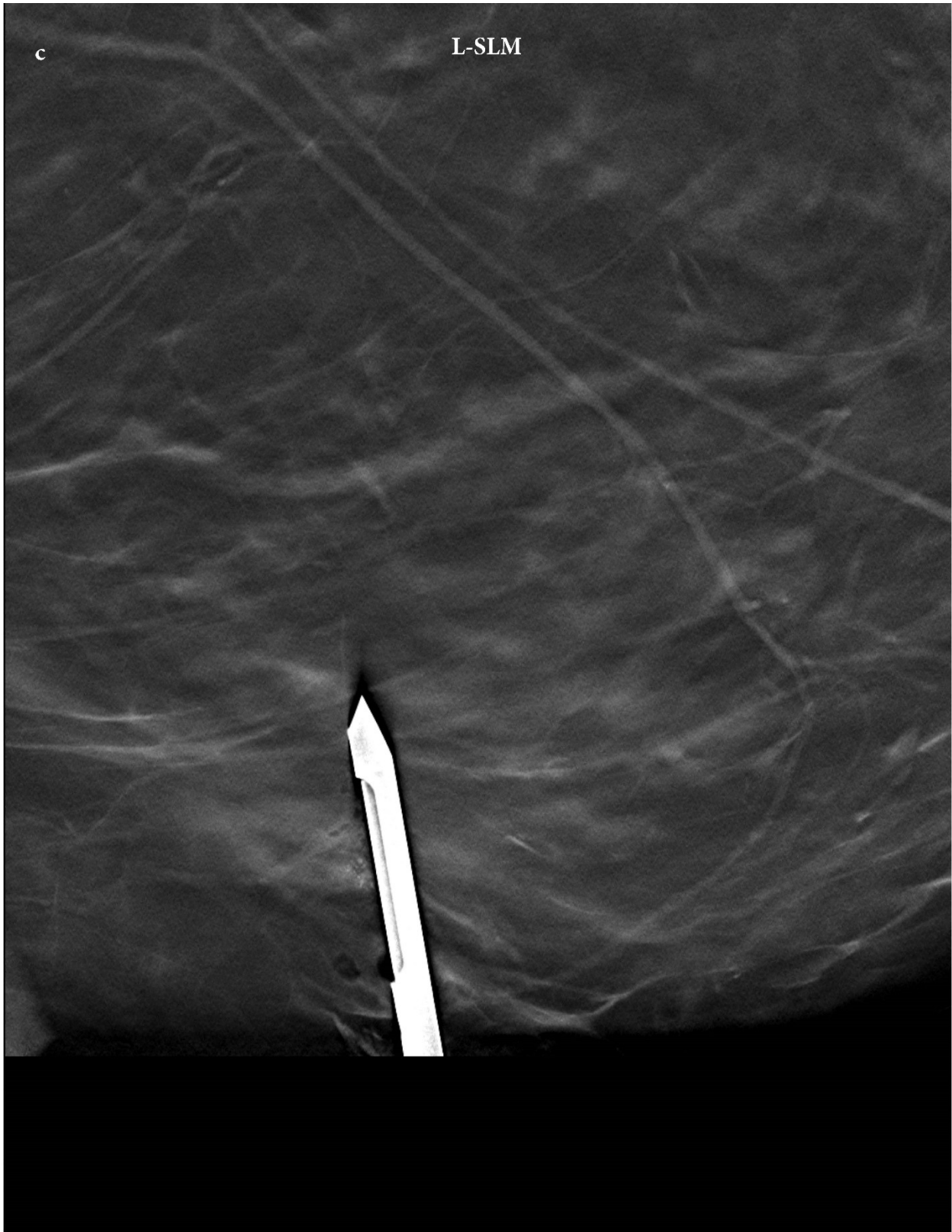**Fig. 5 a and b**, Mediolateral magnification and Craniocaudal magnification views of the right breast show a group of amorphous calcifications at 6 o'clock, denoted by

circles. **c** Postfire image of the tomosynthesis-guided biopsy of the 6 o'clock calcifications utilizing inferior access, lateral arm approach, showing the standard needle trough in the appropriate position in relation to the calcifications

**Case 4: A** 67-year-old woman called back for a new group of calcifications in the left breast. Magnification views showed amorphous calcification with a grouped distribution at 6 o'clock. The breast thickness was 67 mm, and conventional stereotactic biopsy on the prone table was attempted. However, given the superficial location of the target, when the breast was compressed on the craniocaudal view, even with a petit needle, there was not enough safe margin at the skin entrance for tissue sampling. In addition, given the very inferior location of the target, lateral or medial approaches were not feasible, as not enough compression was achievable in the very inferior aspect of the breast. The patient's breast was repositioned lateromedially, and the calcifications were accessed inferiorly utilizing the lateral arm approach. The pathology revealed atypical ductal hyperplasia (ADH) concerning for ductal carcinoma in situ (DCIS). (Fig. 6).





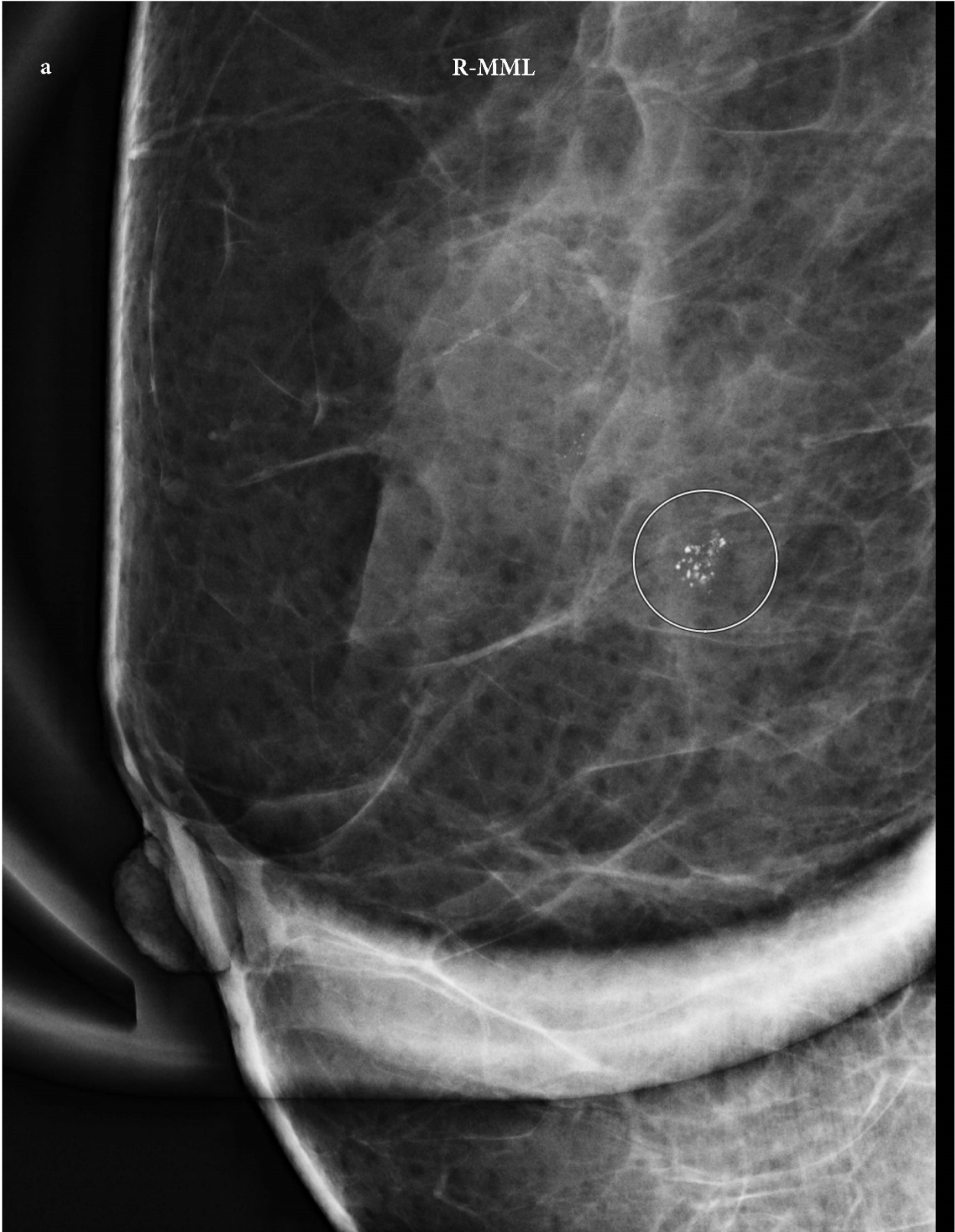


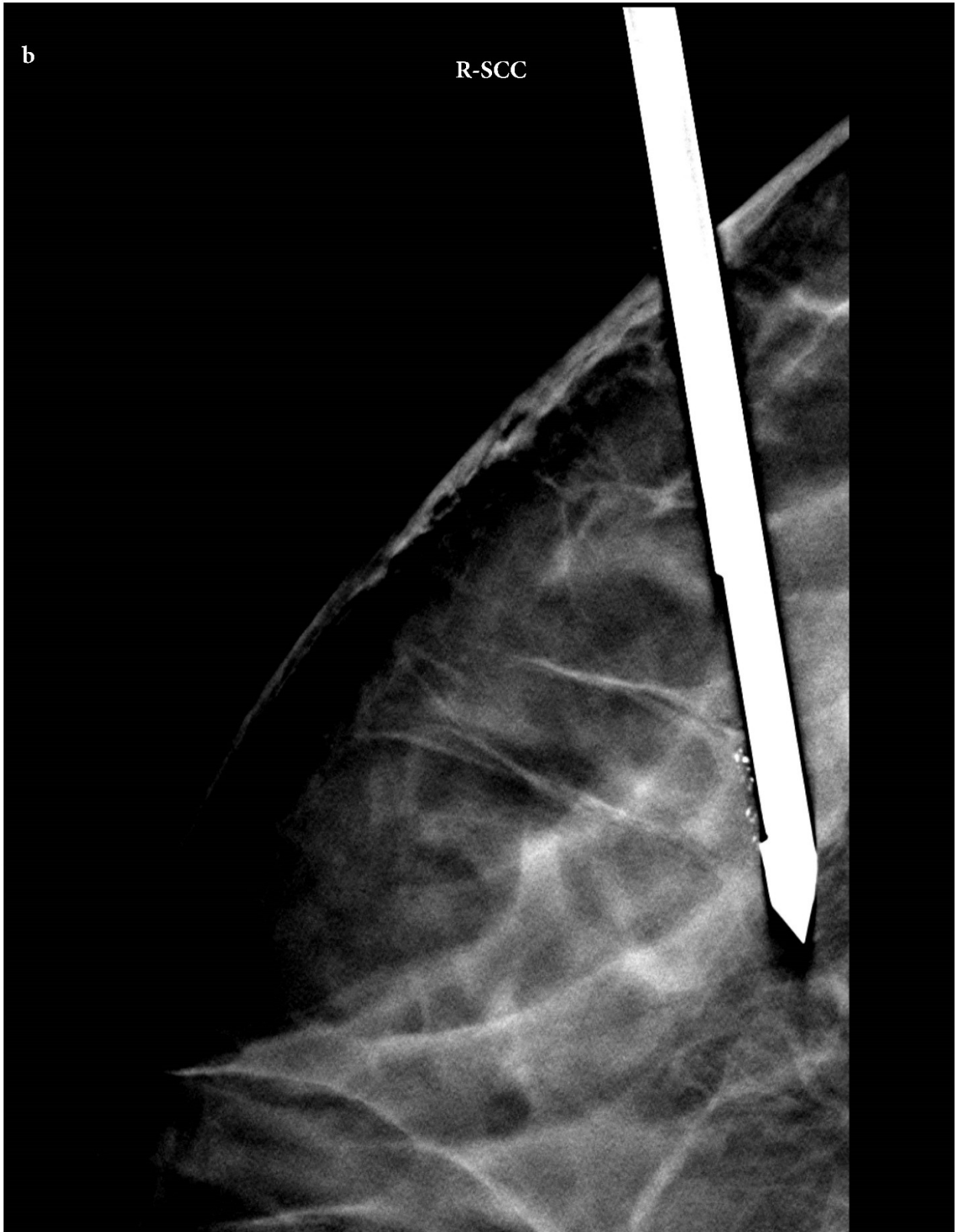**Fig. 6 a and b**, Mediolateral magnification and Craniocaudal magnification views of the left breast show a group of amorphous calcifications at 6 o'clock, denoted by

circles. **c** Postfire image of the tomosynthesis-guided biopsy of the 6 o'clock calcifications utilizing inferior access, lateral arm approach, showing the standard needle trough in the appropriate position in relation to the calcifications

**Case 5: A** 59-year-old woman called back for a new group of calcifications in the right breast. Magnification views showed a group of coarse heterogeneous calcifications at 10 o'clock. Conventional lateral and superior approaches were initially attempted. However, given a breast thickness of 2.1 cm, the conventional approach was not successful. Since the calcifications were laterally located, the breast was positioned craniocaudally, and the lateral arm approach was utilized, accessing the target from the lateral side of the breast. Pathology revealed focal atypical ductal hyperplasia (ADH) and flat epithelial atypia (FEA). (Fig. 7).







**Fig. 7. a** Mediolateral magnification view of the left breast shows a group of coarse heterogeneous calcifications at 10 o'clock, denoted by a circle. **b** Postfire image of

the tomosynthesis-guided biopsy of the 10 o'clock calcifications utilizing lateral access, lateral arm technique, shows the standard needle trough in the appropriate position in relation to the calcifications

### **Tips for successful lateral arm technique biopsy**

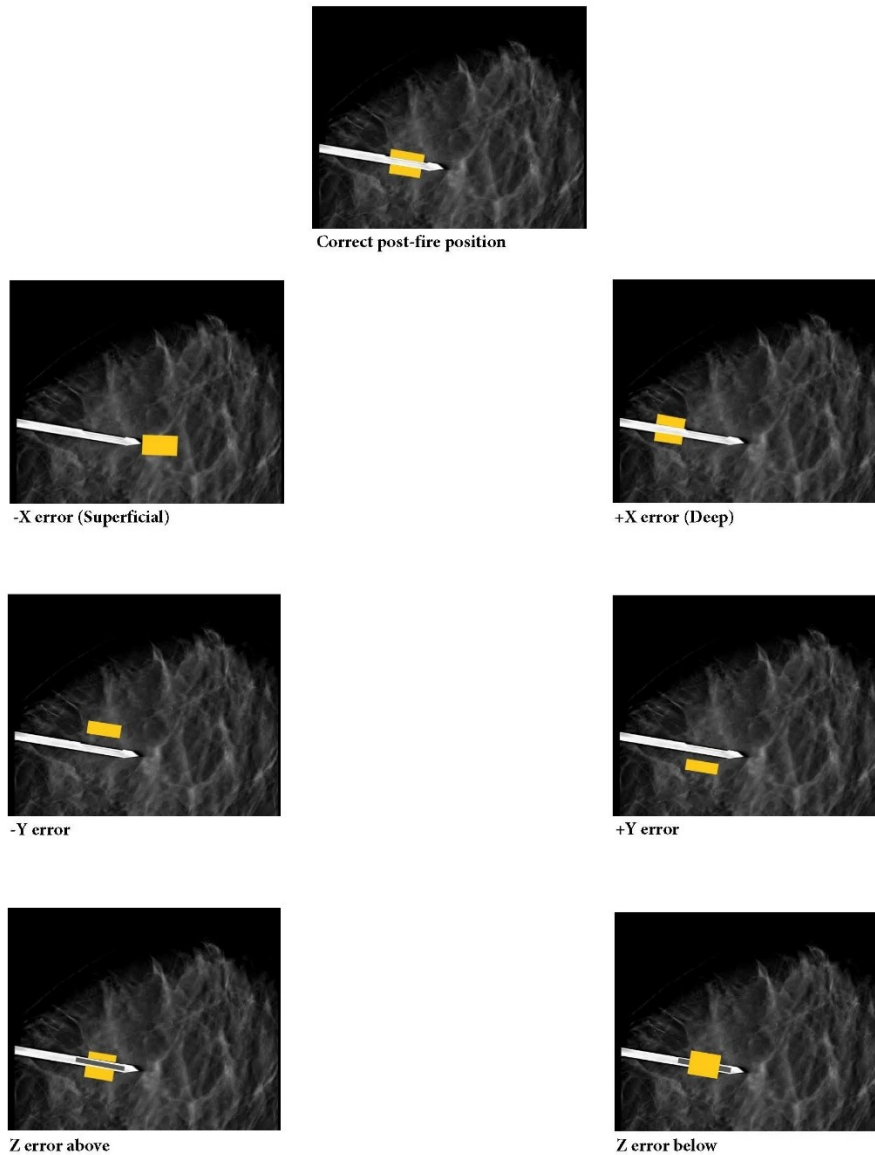
Similar to any image-guided biopsy, planning the biopsy and the approach is the main key. Similar to the conventional vertical approach, if the target is only seen on one view, the breast should be positioned in the same view. If the target is seen in both views, then a shorter distance to the target is preferred.

While positioning the breast, it is important to have the edge of the compression paddle aligned with the breast edge on the entrance side. If the edge of the entrance site of the breast is deeper to the edge of the compression paddle and detector, in addition to miscalculation of the coordinates, the numbing and needle entrance will also be challenging due to less accessibility of the skin, especially in thinly compressed breasts.

If the target site is deep, a spinal needle should be used for local anesthesia. Usually, a skin nick with a scalpel is not necessary. However, sometimes when the breast is very thin, a skin nick can be made to avoid skin tenting at the entrance site.

As the needle enters the breast (parallel to the compression), placing extra compression by another hand on the compression paddle or other side of the breast (opposite to the entrance site) can help stabilize the breast and facilitate needle entrance.

The postfire tomosynthesis image should be carefully evaluated for the relation of the trough and the target. X, Y and Z errors can occur. Retargeting can be performed based on the degree of the error, but usually adjusting the needle or increasing sampling in some clock location is usually sufficient for a successful biopsy. In the upright lateral arm technique, the X-error is about the depth of the needle. +X and -X errors are defined when the needle trough is deep to the lesion or short of the lesion, respectively, which can be corrected by retargeting or pulling back the needle for +X error or advancing the needle for -X error. +Y and -Y errors are defined when the needle trough is anterior to the target or posterior to the target, respectively. These can be corrected by retargeting or increasing sampling at the 9 o'clock position for +Y error and at 3 o'clock for -Y error. Z error below and Z error above are defined when the needle trough is inferior to the target or superior to the target, respectively. These can be corrected by retargeting or increasing sampling at the 6 o'clock position for Z error below and at 12 o'clock for Z error above. [Fig. 8].



**Fig. 8** Troubleshooting in the upright lateral arm approach. In this figure, the correct position of the needle trough in relation to the target is shown in the postfire image. In -X error, the needle trough is short of the lesion, which can be corrected by advancing the needle. In +X error, the needle trough is deep to the lesion, which can be corrected by pulling back the needle. In the -Y error, the needle trough is posterior to the lesion and can be corrected by increased sampling at 3 o'clock. In +Y error, the needle trough is anterior to the lesion and can be corrected by increasing sampling at 9 o'clock. In the Z error below, the needle trough is inferior to the lesion and can be corrected by increased sampling at 6 o'clock. In Z error above, the needle trough is superior to the lesion and can be corrected by increased sampling at 12 o'clock

## Discussion

Approximately 4% of the US patient population has thin breasts with a breast thickness of less than 3.5 cm at mammography. This group of patients is precluded from stereotactic guided biopsy with the traditional standard needle approach. The lateral needle approach can help avoid unnecessary surgical excisional biopsies in cases where biopsy is technically not feasible due to thin breasts. In November 1990, Joachim Teubner introduced the preliminary lateral arm attachment at the annual Radiological Society of North America meeting. Further modifications and improvements were applied, and finally, the attachment was approved by the United States Food and Drug Administration in August 1999 [7]. The lateral arm approach can be used not only in women with very thin breasts but also in cases as an alternative to the standard approach regardless of breast thickness. The advantages of this technique compared to the standard approach include decreased risk of biopsy marker migration, easier targeting with superior lesion accessibility, better target visualization, shorter biopsy time, and less radiation.

Several studies have investigated outcomes with lateral arm stereotactic guided biopsy. Our findings are similar to prior studies that showed that the lateral arm approach is safe and effective for stereotactic guided biopsy regardless of breast thickness. There were no major complications or biopsy marker migration. Nakamura et al. studied stereotactic vacuum-assisted breast biopsy on the upright unit using the lateral arm approach on 124 biopsies in Japan. In their study, the minimum breast thickness was 10 mm, and they were able to use 11 G needles for all biopsies. This is a great advantage in Japan and other Asian countries, as Japanese women have thinner breasts than most Western women [11]. Myong et al evaluated the utility of adding the lateral arm approach to the vertical approach on prone stereotactic biopsies. In their study, 127 biopsies were included, and the success rate of the vertical approach was 83.8%. This increased to 97.7% when the lateral approach was also used. The mean breast thickness was  $2.7 \pm 1$  cm for the lateral arm approach, in compared to  $4 \pm 1.2$  cm for the vertical approach [9]. Cohen et al. retrospectively compared 147 lateral arm technique biopsies with 177 vertical approach biopsies on the prone table unit. There was no significant difference in total procedure time, lesion targeting time, tissue sampling time, clip migration, positive predictive values or hematoma formation. A total of 1.3 cm was the thinnest compression in the lateral arm compared to 2.9 cm in the vertical approach. Fewer exposures were used with the lateral arm compared to the vertical approach, which resulted in less radiation [10••]. Weaver et al. compared clip migration and hematoma formation between 292 conventional vertical approach biopsies and 97 lateral arm technique biopsies in the prone table unit. In their study, there was no significant difference in hematoma formation or clip migration rate with either a 1 cm or 2 cm threshold. Clip migration with 1 cm threshold and 2

cm threshold were 15% in compared to 5.8% for the vertical approach and 10% in compared to 3.1% for the lateral arm approach, respectively [12].

It has been one year since our institute started the lateral arm technique, mainly performed in our central location with the prone table unit. This technique was mainly used in patients for whom the conventional vertical approach was not successful, given the breast thickness or location of the lesion. The prone table lateral arm approach versus the upright lateral arm technique is more favorable in our institute, as there is no extra accessory to be mounted on the machine, and in less than 5 minutes, the patient can be repositioned from the vertical approach to the lateral arm approach. Adopting the lateral arm technique has been an enormous help in reducing unnecessary surgical biopsies for lesions that are not amenable for stereotactic biopsy using the conventional vertical approach, especially in Los Angeles County with a diverse population including the Asian population with thinner breasts or patients with implants.

## **Conclusions**

Prior to the introduction of the lateral arm technique, if the area of interest was not feasible for tissue sampling given the thin breast or location of the lesion, patients were referred for excisional biopsy. The lateral arm approach is a novel technique that can be used safely in the breast as thin as 1 cm thickness or for superficial lesions. In addition, given that the X-ray beam is perpendicular to the needle, the target and the relation of the target to the needle trough are easily seen, and this technique can be used for noncalcified targets or subtle targets in which visibility of the target in the biopsy trough can increase accurate targeting. This technique can be easily performed on the prone table with no need for additional equipment or can be performed on the upright unit with an add-on accessory on the unit. This technique can be easily adopted in practice, and both radiologists and technologists should be trained, as if the conventional vertical approach biopsy is not feasible at the time of biopsy, the lateral arm technique should be attempted, and having access to both techniques can increase successful mammographic-guided biopsies up to 99%.

## **Declarations:**

This article does not contain any studies with human or animal subjects performed by any of the authors.

## **References:**

1. American Cancer Society. Cancer Facts and Figures 2023. Atlanta, Ga: American Cancer Society; 2023.  
<https://www.cancer.org/content/dam/cancer-org/research/cancer-facts-and-statistics/annual-cancer-facts-and-figures/2023/2023-cancer-facts-and-figures.pdf>.
2. Sechopoulos I. A review of breast tomosynthesis. Part I. The image acquisition process. *Med Phys*. 2013; 40(1):014301.  
<https://doi.org/10.1118/1.4770279>.
3. Chong A, Weinstein SP, McDonald ES, Conant EF. Digital Breast Tomosynthesis: Concepts and Clinical Practice. *Radiology*. 2019; 292(1):1-14. <https://doi.org/10.1148/radiol.2019180760>.
4. Vijapura CA, Wahab RA, Thakore AG, Mahoney MC. Upright Tomosynthesis-guided Breast Biopsy: Tips, Tricks, and Troubleshooting. *RadioGraphics*. 2021; 41(5):1265-1282.  
<https://doi.org/10.1148/rg.2021210017>.
5. • Kerger A, Griffith B, Patel M, Hawley J, Povoski SP. The lateral arm device for mammographic breast procedures: overview of its uses, safety, and efficacy. *Expert Rev Med Devices*. 2021; 18(5):413-420.  
<https://doi.org/10.1080/17434440.2021.1908884>. *This article compare lateral arm approach with vertical approach, emphasizing on lateral arm benefits.*
6. ACR Practice Parameter for the Performance of Stereotactic/Tomosynthesis-Guided Breast Interventional Procedures; Revised 2020 (Resolution 3).  
<https://www.acr.org/-/media/ACR/Files/Practice-Parameters/stereo-breast.pdf>. Accessed 1 Oct 2020.
7. Georgian-Smith D, D'Orsi C, Morris E, Clark CF Jr, Liberty E, Lehman CD. Stereotactic biopsy of the breast using an upright unit, a vacuum-suction needle, and a lateral arm-support system. *AJR Am J Roentgenol*. 2002; 178(4):1017-24. <https://doi.org/10.2214/ajr.178.4.178101>.
8. Lehman CD, Sieler-Gutierrez HJ, Georgian-Smith D. Lateral approach biopsy adapter: accuracy on an upright unit in a turkey breast model. *AJR Am J Roentgenol*. 2001; 177(4):897-9.  
<https://doi.org/10.2214/ajr.177.4.1770897>.
9. Myong JH, Kang BJ, Yoon SK, Kim SH, An YY. The clinical utility of a adding lateral approach to conventional vertical approach for prone stereotactic vacuum-assisted breast biopsy. *Korean J Radiol*. 2013; 14(4):568-75.  
<https://doi.org/10.3348/kjr.2013.14.4.568>.
10. ••Cohen EO, Weaver O, Korhonen KE, Sun J, Leung JWT. Retrospective Comparison of the Lateral-Arm and Vertical Needle Approaches for Prone Tomosynthesis-Guided Breast Biopsy. *Can Assoc Radiol J*. 2023.  
<https://doi.org/10.1177/08465371231164601>. *This article compare lateral arm approach with vertical approach in prone table unit, emphasizing on technical details and outcomes.*



11. Nakamura Y, Urashima M, Matsuura A, Nishihara R, Itoh A, Kagemoto M, Higaki K. Stereotactic directional vacuum-assisted breast biopsy using lateral approach. *Breast Cancer*. 2010; 17(4):286-9. <https://doi.org/10.1007/s12282-009-0162-4>.
12. Weaver O, Cohen EO, Perry RE, Tso HH, Phalak K, Srinivasan A, Bassett R, Leung JWT. Does lateral arm technique decrease the rate of clip migration in stereotactic and tomosynthesis-guided biopsies? *Insights Imaging*. 2021; 12(1):193. <https://doi.org/10.1186/s13244-021-01136-w>.