

# UCLA

## UCLA Previously Published Works

### Title

Triple-Organ Transplantation: Dual Heart-Kidney Transplantation After Lung Transplantation.

### Permalink

<https://escholarship.org/uc/item/1kf0z8j1>

### Journal

JACC: Case Reports, 29(17)

### Authors

Webb, Martine

Wilson, James

Weigt, S

et al.

### Publication Date

2024-09-04

### DOI

10.1016/j.jaccas.2024.102493

Peer reviewed

## HEART FAILURE AND CARDIOMYOPATHIES

### CASE REPORT: CLINICAL CASE

# Triple-Organ Transplantation



## Dual Heart-Kidney Transplantation After Lung Transplantation

Martine Webb, MD,<sup>a</sup> James Wilson, MD,<sup>b</sup> S. Samuel Weigt, MD, MS,<sup>c</sup> David Sayah, MD, PhD,<sup>c</sup> Nima Nassiri, MD,<sup>d</sup> Abbas Ardehali, MD,<sup>e</sup> Daniel Cruz, MD,<sup>f,g</sup> Ali Nsair, MD,<sup>f,g</sup> Megan Kamath, MD<sup>f,g</sup>

### ABSTRACT

We present a patient with a history of lung transplantation who subsequently underwent dual heart-kidney transplantation for nonischemic cardiomyopathy and chronic kidney disease, becoming one of the rare cases of triple-organ transplantation. This case underscores the evolving challenges and successes in managing complex transplant recipients. (JACC Case Rep. 2024;29:102493) © 2024 Published by Elsevier on behalf of the American College of Cardiology Foundation. This is an open access article under the CC BY-NC-ND license (<http://creativecommons.org/licenses/by-nc-nd/4.0/>).

### HISTORY OF PRESENTATION

The patient presented to the emergency department with progressive fatigue and dyspnea on exertion. He also noted intermittent lower extremity edema and orthopnea but denied palpitations or lightheadedness. On arrival, he was hemodynamically stable with a blood pressure of 106/68 mm Hg, heart rate of 59 beats/min in sinus rhythm, and oxygen saturation of 94% on room air. Physical examination showed signs of volume overload. He was admitted to the inpatient cardiology service for decompensated heart failure.

### MEDICAL HISTORY

The patient is a 63-year-old man with a history of hypersensitivity pneumonitis who underwent

### LEARNING OBJECTIVES

- To understand the challenges and additional considerations required for patients with existing solid organ transplants who are undergoing heart transplantation evaluation.
- To know both benefits and potential side effects to tacrolimus- vs sirolimus-based immunosuppressive regimens for patients with heart transplants.
- To realize that transplantation physicians should recognize the challenges of immunosuppression and postoperative surveillance in a patient undergoing heart transplantation with a history of skin cancer and prior organ transplantation.

From the <sup>a</sup>Department of Medicine, David Geffen School of Medicine at UCLA, Los Angeles, California, USA; <sup>b</sup>Division of Nephrology, David Geffen School of Medicine at UCLA, Los Angeles, California, USA; <sup>c</sup>Division of Pulmonology, David Geffen School of Medicine at UCLA, Los Angeles, California, USA; <sup>d</sup>Department of Urology, UCLA Kidney and Pancreas Transplantation Program, David Geffen School of Medicine at UCLA, Los Angeles, California, USA; <sup>e</sup>Division of Cardiac Surgery, David Geffen School of Medicine at UCLA, Los Angeles, California, USA; <sup>f</sup>Division of Cardiology, David Geffen School of Medicine at UCLA, Los Angeles, California, USA; and the <sup>g</sup>Heart Transplant Program, David Geffen School of Medicine at UCLA, Los Angeles, California, USA.

The authors attest they are in compliance with human studies committees and animal welfare regulations of the authors' institutions and Food and Drug Administration guidelines, including patient consent where appropriate. For more information, visit the [Author Center](#).

Manuscript received May 9, 2024; revised manuscript received July 1, 2024, accepted July 3, 2024.

**ABBREVIATIONS  
AND ACRONYMS****BOLT** = bilateral orthotopic lung transplantation**CKD** = chronic kidney disease**DDRT** = deceased donor renal transplantation**OHT** = orthotopic heart transplantation**VT** = ventricular tachycardia

bilateral orthotopic lung transplantation (BOLT) 7 years before presentation, complicated by A1 acute cellular rejection treated with prednisone. He was on triple immunosuppression with tacrolimus, sirolimus, and prednisone. The patient also had a history of chronic kidney disease (CKD) stage 3 due to calcineurin toxicity, and recurrent squamous cell/basal cell carcinomas of the face, having undergone multiple excisions. Cardiac history included mitral valve repair at age 38, paroxysmal atrial fibrillation, and nonischemic cardiomyopathy with an ejection fraction of 30%-35%, which developed after lung transplantation and led to discovery of a titin mutation. The patient received an implantable cardioverter-defibrillator for his history of ventricular tachycardia (VT), which had been refractory to multiple ablation efforts. He presented on amiodarone and mexiletine.

**DIFFERENTIAL DIAGNOSIS**

The differential diagnosis of this patient with a history of BOLT and ischemic cardiomyopathy presenting with fatigue and dyspnea on exertion includes pulmonary infection, lung transplant rejection, decompensated heart failure, post-transplantation lymphoproliferative disease, acute myocarditis/pericarditis, and acute renal failure.

**INVESTIGATIONS**

Laboratory results on admission were notable for an elevated brain natriuretic peptide of 2,415 pg/mL. His tacrolimus and sirolimus levels were within goal. Creatinine was 1.95 mg/dL, which was near his baseline, and continued to uptrend to a peak of 2.7 mg/dL during his admission. Transthoracic echo demonstrated an ejection fraction of 27.5%. Interrogation of his implantable cardioverter-defibrillator revealed 6 episodes of sustained VT in the 2 months leading up to his admission despite adherence to his antiarrhythmics. The patient underwent right-sided heart catheterization, which showed pulmonary artery pressure of 45/24 mm Hg and cardiac index of 2.09 L/min/m<sup>2</sup> using thermodilution. Biopsy of several skin lesions were consistent with squamous cell carcinoma. Pulmonary function testing was performed, and remained unchanged from prior evaluation.

**MANAGEMENT**

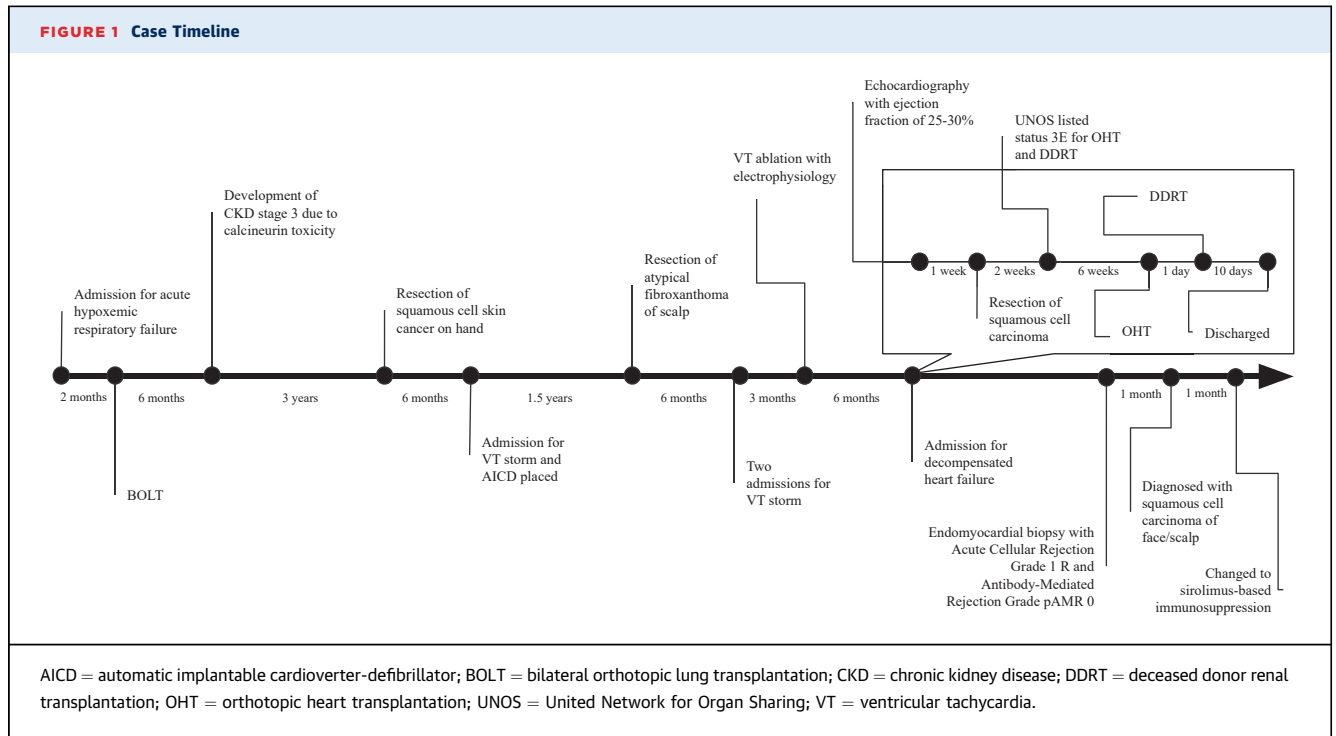
The patient was evaluated using electrophysiology and deemed not to be a candidate for further

ablations or stereotactic body radiotherapy. Given his worsening cardiac function and history of refractory VT, the patient underwent evaluation for orthotopic heart transplantation (OHT) and deceased donor renal transplantation (DDRT). He received intermittent intravenous diuresis during his hospitalization. Approximately 2 months into his hospitalization, the patient was accepted for a dual heart-kidney transplantation. He underwent OHT without significant complications, and was taken back to the operating room for DDRT on postoperative day 1. Given his history of skin cancer and prior lung transplantation, the patient was induced with Basiliximab on postoperative days 0 and day 4, as well as intraoperative solumedrol. The remainder of his hospital course was unremarkable, and he was discharged home on postoperative day 9 on an immunosuppression regimen of tacrolimus, mycophenolic acid, and a prednisone taper.

**DISCUSSION**

We present a patient with a history of BOLT who underwent dual OHT/DDRT for nonischemic cardiomyopathy and CKD (Figure 1). Patients with end-stage heart failure frequently have comorbid conditions including CKD or cirrhosis. As such, dual-organ transplantation (heart-lung, heart-kidney, heart-liver) is becoming more common. However, to our knowledge, only 2 cases of triple-organ transplantation have been reported, both of which were liver-lung-kidney.<sup>1,2</sup> We believe this is the first reported case of a heart-kidney transplant after prior lung transplantation. Although the median survival after lung transplantation is 6.2 years, having evaluated this patient thoroughly, we thought he would be an appropriate candidate for additional dual-organ transplantation based on his functional status and lack of prior organ rejection. Given the patient's prior clamshell incision, a re-do sternotomy was complex, necessitating lysis of dense adhesions within the mediastinum that required extended hemostasis.

This patient's history of multiple skin cancers posed additional challenges in pretransplantation evaluation. At baseline, patients with solid organ transplants are at elevated risk of developing skin cancer, most frequently nonmelanomatous malignancies.<sup>3</sup> The patient was found to have 2 lesions on admission, for which pathology returned as squamous cell carcinoma in situ. Therefore, a multidisciplinary discussion with the dermatology department was necessary before this patient being listed for

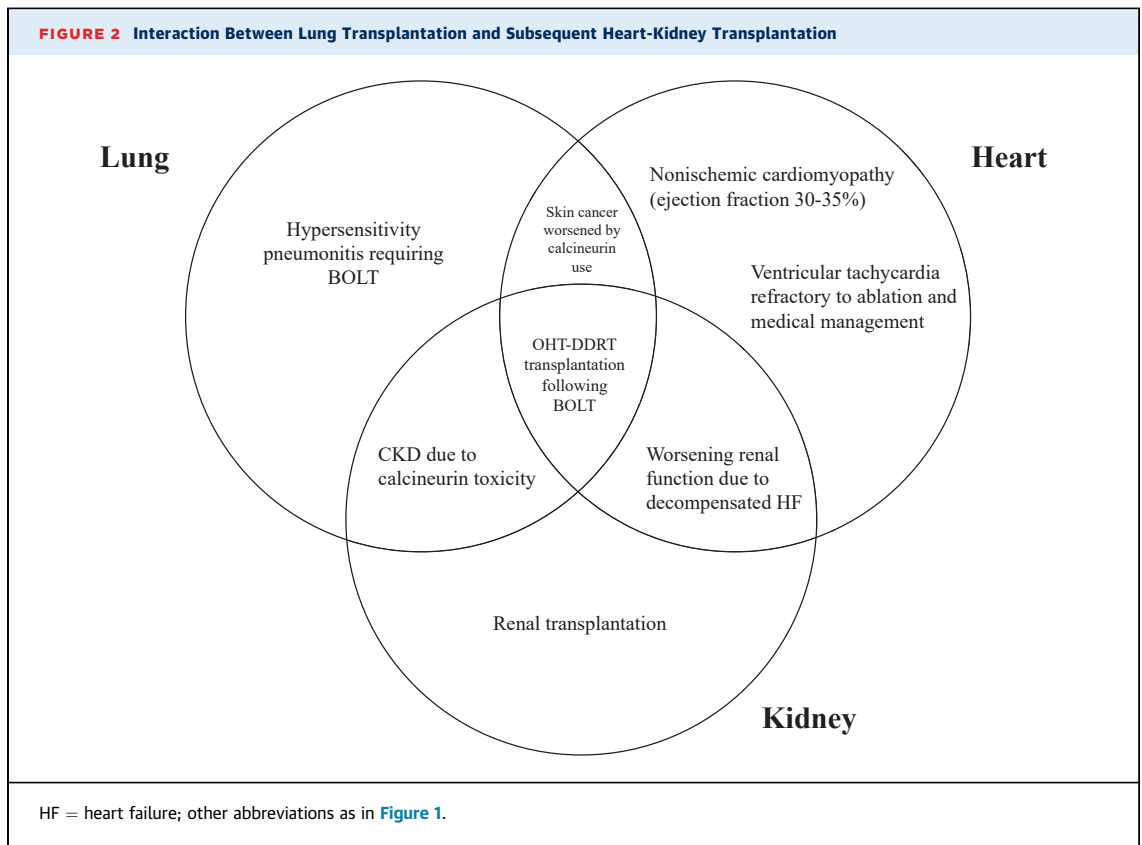


heart-kidney transplantation. High-risk features, such as poorly differentiated cells, perineural invasion, or primary site on the ear or lip, were not seen on this patient’s biopsies. Therefore, the patient’s history of skin malignancies was not an indication to delay transplantation.

Given his skin cancer risk, coupled with his history of prior solid organ transplantation, the choice of immunosuppressive regimen in this patient was nuanced. This patient was induced intraoperatively with solumedrol and basiliximab on postoperative days 0 and 4, due to his high-risk dual-organ transplantation and prior immunosuppressed status. Because this patient had no donor-specific antibodies detected at the time of transplantation, cross sensitivity was not a consideration in reviewing potential donor options.

Maintenance immunosuppression likewise required multidisciplinary discussion. Calcineurin inhibitors, such as tacrolimus and cyclosporine, are commonly used as maintenance immunosuppression after solid organ transplantation, and are known to increase the risk of developing nonmelanomatous skin cancers.<sup>3</sup> This class of medication is suggested to

have oncogenic properties due to their cytokine production, which promotes tumor growth, angiogenesis, and metastasis.<sup>4</sup> In contrast, mammalian target of rapamycin inhibitors, such as sirolimus, are newer agents that may have antitumor properties by blocking angiogenesis.<sup>4</sup> However, meta-analyses show conflicting evidence regarding the effect of a sirolimus-based immunosuppressive regimen on the prevention of skin cancers in transplant recipients.<sup>5</sup> In general, conversion from tacrolimus to sirolimus may reduce the risk of developing non-melanomatous skin cancers in the short term, whereas the evidence regarding long-term prevention is less clear.<sup>5</sup> It is important to note that sirolimus has been associated with increased adverse effects, including albuminuria, epistaxis, pneumonitis, mouth ulcerations, and rash.<sup>6</sup> Given that this patient had already developed skin cancer on a tacrolimus-based regimen, the decision was made to transition him early to a sirolimus-based regimen and monitor closely for wound healing. Additionally, the goal immunosuppression level in this patient required consideration for the health of all organs, and required coordination with



transplant pulmonary, cardiology, and nephrology specialists.

#### **FOLLOW-UP**

The patient is clinically doing well and participating in cardiac rehabilitation. An echocardiogram performed 2 weeks after his OHT demonstrated excellent graft function. Endomyocardial biopsy performed 1-month post-transplantation was notable for acute cellular rejection grade 1R and pathological antibody-mediated rejection grade 0 ([Figure 1](#)), which was managed with ongoing surveillance biopsies and standard immunosuppression. Right-sided heart catheterization showed normal filling pressures and cardiac output. He was transitioned from tacrolimus to a sirolimus-based immunosuppressive regimen. The patient was found to have new squamous cell carcinoma of the left parietal and right temporal regions, and underwent wide local excision. Given his high-risk status and chronic immunosuppression, he is undergoing adjuvant radiation therapy for focal residual disease found near his right temple.

#### **CONCLUSIONS**

This case represents a rare instance of dual heart-kidney transplantation after remote lung transplantation, highlighting the evolving complexity and success of transplant medicine. A multidisciplinary approach, particularly in navigating immunosuppression management and heightened cancer risk, is critical in ensuring graft function and patient safety ([Figure 2](#)). Long-term monitoring will be essential in addressing potential complications in this unique patient population.

#### **FUNDING SUPPORT AND AUTHOR DISCLOSURES**

The authors have reported that they have no relationships relevant to the contents of this paper to disclose.

**ADDRESS FOR CORRESPONDENCE:** Dr Martine Webb, David Geffen School of Medicine at UCLA, Department of Medicine, 757 Westwood Plaza, Suite 7236, Los Angeles, California 90095, USA. E-mail: [mmadill@mednet.ucla.edu](mailto:mmadill@mednet.ucla.edu). X handle: [@martine\\_s\\_webb](https://twitter.com/martine_s_webb).

---

## REFERENCES

1. Shah L, Dube G, Dove L, et al. Combined liver-kidney transplant in a patient with cystic fibrosis. *Am J Case Rep.* 2021;22:e930867. <https://doi.org/10.12659/AJCR.930867>
2. Zhang T, Price MB, Bravo N, et al. Combined lung-liver and delayed kidney transplantation for cystic fibrosis clinical approach and outcome: a case report. *Transplant Proc.* 2020;52:2824-2826. <https://doi.org/10.1016/j.transproceed.2020.02.154>
3. Rollan MP, Cabrera R, Schwartz RA. Current knowledge of immunosuppression as a risk factor for skin cancer development. *Crit Rev Oncol Hematol.* 2022;177:103754. <https://doi.org/10.1016/j.critrevonc.2022.103754>
4. Blagosklonny MV. Cancer prevention with rapamycin. *Oncotarget.* 2023;14:342-350. <https://doi.org/10.18632/oncotarget.28410>
5. Kreher MA, Noland MMB, Konda S, Longo MI, Valdes-Rodriguez R. Risk of melanoma and non-melanoma skin cancer with immunosuppressants, part I: calcineurin inhibitors, thiopurines, IMDH inhibitors, mTOR inhibitors, and corticosteroids. *J Am Acad Dermatol.* 2023;88:521-530. <https://doi.org/10.1016/j.jaad.2022.11.044>
6. Zhang G, Duan B, Li G. mTORi-based immunosuppression reduces HCC recurrence at the expense of increased adverse side effects: a systematic review and meta-analysis. *Clin Transplant.* 2022;36:e14823. <https://doi.org/10.1111/ctr.14823>

---

**KEY WORDS** advanced heart failure, heart transplantation, multiorgan transplantation, transplant medicine