

UC Irvine

UC Irvine Previously Published Works

Title

Photodynamic therapy of port wine stain: preliminary clinical studies

Permalink

<https://escholarship.org/uc/item/1kc4g252>

Author

Nelson, J Stuart

Publication Date

1993-07-01

DOI

10.1117/12.147022

Copyright Information

This work is made available under the terms of a Creative Commons Attribution License, available at <https://creativecommons.org/licenses/by/4.0/>

Peer reviewed

Photodynamic therapy of port wine stain: preliminary clinical studies

J. Stuart Nelson

Beckman Laser Institute and Medical Clinic
Departments of Surgery and Dermatology
University of California, Irvine
Irvine CA 92715

ABSTRACT

The broad, long term objective of this work is the development of Photodynamic Therapy (PDT) for application in the clinical management of patients with port wine stain (PWS). PDT involves the use of an exogenous drug which is concentrated in a targeted tissue. When irradiated at wavelengths specifically absorbed by the drug, selective destruction of the targeted tissue, without the production of heat, occurs. The results of this preliminary study demonstrate in human PWS patients that a photosensitizer, such as PHOTOFRIN^R, activated by red light at the appropriate therapeutic wavelength, can cause destruction of subsurface blood vessels in the skin with a high degree of specificity, and further study appears warranted.

2. INTRODUCTION

Port wine stain (PWS) is a congenital, progressive vascular malformation of the skin involving capillaries, and possibly perivenular nerves (1). Although PWS may occur anywhere on the body, two thirds of lesions involve the face and neck. In early childhood, PWS are faint pink macules, but the lesions tend to darken progressively, and by middle age, they often become raised as a result of the development of vascular papules or nodules and, occasionally, tumors. These changes in color and contour are attributed to the progressive ectasia of the abnormal dermal vascular plexus (2). The hypertrophy of underlying bone and soft tissue that occurs in approximately two-thirds of patients with PWS, further disfigures the facial features of many children (3).

Historical treatments for PWS included scalpel surgery, ionizing radiation, skin grafting, dermabrasion, cryosurgery, tattooing, and electrotherapy. Clinical results were considered unsatisfactory due to the cosmetically unacceptable scarring post treatment (4). These are no longer considered viable treatment options.

More recent treatment options using the argon or flashlamp pulsed dye laser have offered a superior approach in therapy due to their ability to destroy selectively cutaneous blood vessels. Light will pass through the epidermis and then be preferentially absorbed by hemoglobin (the major chromophore in blood) in the ectatic capillaries in the upper dermis. There, the radiant energy will be converted to heat causing thermal damage and thrombosis in the targeted vessels. The degree of selectivity depends on laser parameters such as wavelength, pulse duration and energy density which are inherent in each type of laser. However, the epidermis is not totally spared due to partial absorption of energy therein by melanin and to dissipation of heat from the injured vessels. Unfortunately, for many lesions, the threshold for epidermal changes following laser therapy is very close to the threshold for permanent blanching of the PWS. Furthermore, only a small proportion of patients obtain 100% fading of their PWS, even after undergoing multiple treatments, due to the shallow penetration of light at the wavelengths employed in conventional laser therapy (5).

The basic concept of Photodynamic therapy (PDT), is that certain molecules can function as photosensitizers. The presence of these photosensitizers in biological tissues makes the latter vulnerable to light at wavelengths absorbed by the chromophore. The photosensitizer absorbs photons of the appropriate wavelength and is elevated to an excited state. The excited photosensitizer subsequently reacts with a substrate, such as oxygen, to produce highly reactive singlet molecular oxygen which causes irreversible oxidative damage to biologically important molecules (6).

Both the scope and level of activity in basic research and in the clinical application of PDT for the treatment of malignant tumors have grown enormously during the past few years and have been thoroughly reviewed in recent symposia (7,8). Porphyrin sensitizers have received the most attention since the observation by Dougherty et al. in 1975 (9) that hematoporphyrin derivative (HpD), activated by light from a xenon arc lamp, could cause complete eradication of a transplanted mouse mammary tumor without appreciable damage to the overlying skin. Concentration of the "active ingredient" in HpD led to the introduction of commercially available PHOTOFRIN[®] (also called dihematoporphyrin ether/ester or DHE) into clinical trials in 1983.

Histopathology of PDT treated tumors shows that apparent internal hemorrhage and red cell extravasation are common findings after PDT, not only in experimental animal tumors but in tumors in patients as well. This observation suggests that the effects of PDT leading to necrosis of tumor tissue are not the result of direct tumor cell kill but are secondary to destruction of the tumor microvasculature (10,11). The localization of isotopically labeled HpD using autoradiography showed that tritiated HpD was distributed at a ratio of 5:1 in the surrounding perivascular stroma as compared to tumor cells (12). Using tumor cell clonogenicity following PDT to assess in vitro colony formation, it was found that clonogenicity was unaffected by PDT if the tumor tissue was excised and explanted immediately (13). If, however, tumor cells were left in situ following PDT for varying lengths of time (1-24 hrs.), tumor cell death occurred rapidly and progressively implying that one of the major factors contributing to tumor destruction may be damage to the tumor circulation and the consequences of treatment-induced changes in tumor physiology. Taken together, these studies suggest that the vascular compartment represents an important target for PDT in the treatment of malignant tumors and possibly for other clinical indications.

The rationale for using PDT for PWS is based on the fact that it will allow the destruction of the targeted blood vessels buried deep within the skin, without the production of heat. Due to the absence of heat production, risks inherent in conventional laser therapy, such as hypertrophic scarring, changes in the normal skin pigmentation, atrophy, or induration, would not be expected. Therefore PDT is a potentially more effective and safer approach to the clinical management of patients with PWS and other vasculopathies. In addition, the greater tissue penetrance of the longer red wavelengths used in PDT makes it ideal for treatment of deeper, larger PWS malformations and hemangiomas, thus substantially expanding the population of patients expected to benefit from laser treatment.

3. PRELIMINARY CLINICAL STUDY

Permission to conduct an experimental protocol was sought and obtained from the Food and Drug Administration (FDA) as Investigational New Drug (IND) application number 37,982. The objective of this ongoing clinical trial is to obtain data on dose-ranging, as well as tolerance and safety, with low dose systemic PHOTOFRIN[®] activated by red light ($\lambda = 630 \text{ nm}$) sufficient to produce clinically significant blanching of treated PWS sites in comparison to pretreatment and untreated control sites. Successive patient groups will be given sequential escalating drug doses and within each drug dosage group, escalating light doses, all found to be well tolerated in our as yet unpublished most recent studies on psoriasis (n = 25).

In the first group of subjects ($n = 5$), each patient had a series of PWS and normal skin test sites treated with PDT using PHOTOFRIN[®] at an initial 0.75 mg/kg dosage. Total laser light doses ($\lambda = 630$ nm) ranging from 25-100 J/cm² were administered at varying time points post drug administration (acutely, 15, 30, 60 minutes, and 2, 4, 8 and 24 hrs). Although mild-moderate purpura was seen in the PWS test sites immediately after light exposure, no blanching was seen.

In the second group of subjects ($n = 10$), the PHOTOFRIN[®] dosage was increased to 1.0 mg/kg and each patient had a series of PWS and normal skin test sites treated with comparable light doses at the same time intervals after drug administration as described above. The results showed complete blanching (100%) in three subjects of all PWS test sites that received a light dosage of 75-100 J/cm² delivered between 30 minutes and 2 hrs after drug administration (Figure 1). It should be emphasized that the PWS blanching response appears to be permanent as follow-up of each of these subjects has now continued for a minimum of six months. In PWS patients who have received conventional photothermal laser treatment, major revascularization of the blanched PWS sites, has never been observed. In the remaining seven subjects, the results were as follows:

- 0 subjects showed significant blanching (75-99%)
- 1 subjects showed moderate blanching (50-74%)
- 1 subject showed mild blanching (25-49%)
- 1 subject showed minimal blanching (0-24%)
- 4 subjects showed no response

Most importantly, no skin surface textural changes (ie., hypertrophic scarring, atrophy, induration) or changes of the normal skin pigmentation in the PWS test sites were noted. At no time did the microscopic findings of PDT treated blanched PWS sites demonstrate any damage in the normal overlying epidermis, epidermal basal layer, or epidermal/dermal junction, implying a high degree of specificity of the treatment for the hypervascular dermis (Figure 2). Furthermore, the results showed that this combination of drug and light dosages was well tolerated without clinically significant photosensitivity on normal skin test sites treated with the same drug and light dosages as the PWS sites. There was minimal erythema of the normal skin sites treated at total light doses of 50-100 J/cm² immediately after laser irradiation. This erythema persisted through 2-4 hrs posttreatment before resolving spontaneously without adverse effects.

4. DISCUSSION

It has been demonstrated in human PWS patients that a photosensitizer, such as PHOTOFRIN[®], activated by red light at the appropriate therapeutic wavelength, can cause destruction of subsurface blood vessels in the skin with a high degree of specificity, and further study appears warranted. Furthermore, the results show that PDT induced PWS blanching in patients may be achieved using a combination of drug and light dosages that did not produce clinically significant photosensitivity of normal skin. Based on the results of these studies, it may be possible to devise a new approach in the treatment of PWS in patients. If the outcome of the photochemical approach is successful, the risks of adverse effects of porphyrins, mainly skin photosensitization, are far less onerous. The advantages of the proposed PDT treatment of PWS over conventional photothermal therapy are very convincing:

1. the milliwatt (40-50 mW/cm²) continuous red light will avoid the epidermal thermal injury produced by high peak power pulsed green or yellow light employed in argon or flashlamp pulsed dye lasers, respectively. No skin surface textural changes (ie., hypertrophic scarring, atrophy, induration) or changes of the normal skin pigmentation in the PWS test sites treated with PDT, were noted.

2. red light ($\lambda = 630 \text{ nm}$) will penetrate deeper into skin, especially in the presence of thick PWS, and thereby achieve deeper treatment than photothermal treatment.
3. because PDT uses continuous low irradiance light over long time exposures (minutes), the dose effect at deeper skin layers accumulates as the exposure time is increased. This property contrasts sharply with conventional photothermal therapy which must achieve a sufficient "temperature jump" with the single millisecond or less exposure to the pulsed laser. Multiple pulses do not increase the depth of light penetration or improve the blanching effect of the treatment.

Future studies are planned to extend these initial findings and to obtain data relative to the clinical efficacy and safety of PDT for application in the clinical management of PWS patients. It is believed that many questions associated with PDT treatment of PWS patients will be answered once a basic understanding of the drug and light dosimetry parameters necessary to produce clinically significant blanching are achieved.

5. ACKNOWLEDGMENTS

This project was supported in part by Department of Defense grant SDI084-88-C-0025, Department of Energy grant DE-FG03-91ER61227, and the Ortho Pharmaceuticals Dermatology Foundation Career Development Award.

6. REFERENCES

1. Mulliken, JB, Young, AR. Vascular Birthmarks - Hemangiomas and Malformations. Philadelphia, PA: W. B. Saunders Co., 1988.
2. Barsky, SH, Rosen, S, Geer, DE, Noe, JM. The nature and evolution of port wine stains: a computer assisted study. *J. Invest. Dermatol.* 1980;74:154-157.
3. Geronemus, RG, Ashinoff, R. The medical necessity of evaluation and treatment of port-wine stains. *J. Dermatol. Surg. Oncol.* 1991;17:76-79.
4. Dixon, JA, Huether, S, Rotering, R. Hypertrophic scarring in argon laser treatment of port wine stains. *Plast. Reconstr. Surg.* 1984;73:771-779.
5. Olbricht, SM, Stern, RS, Tang, SV, Noe, JM, Arndt, KA. Complications of cutaneous laser therapy: a survey. *Arch. Dermatol.* 1987;123:345-349.
6. Weishaupt, KR, Gomer, CJ, Dougherty, TJ. Identification of singlet oxygen as the cytotoxic agent in photoinactivation of a murine tumor. *Cancer Res.* 1976;36:2326-2329.
7. Kessel, D. (ed). Photodynamic Therapy of Neoplastic Disease, Vols. 1 and 2, Boca Raton, FL: CRC Press, Inc., 1990.
8. Gomer, CJ. Preclinical examination of first and second generation photosensitizers used in photodynamic therapy. *Photochem. Photobiol.* 1991;54:1093-1107.
9. Dougherty, TJ, Grindey, GB, Fiel, R. Photoradiation therapy II: Cure of animal tumors with hematoporphyrin and light. *J. Natl. Cancer Inst.* 1975;55:115-121.
10. Nelson, JS, Liaw, L-H, Berns, MW. Mechanism of tumor destruction in photodynamic therapy. *Photochem. Photobiol.* 1987;46:829-836.
11. Nelson, JS, Liaw, L-H, Orenstein, A, Roberts, WG, Berns, MW. Mechanism of tumor destruction following photodynamic therapy with hematoporphyrin derivative, chlorin and phthalocyanine. *J. Natl. Cancer Inst.* 1988;80:1599-1605.
12. Bugelski, PJ, Porter, CW, Dougherty, TJ. Autoradiographic distribution of hematoporphyrin derivative in normal and tumor tissue of the mouse. *Cancer Res.* 1981;41:4606-4612.
13. Henderson, BW, Waldow, SM, Mang, TS, Potter, WR, Malone, PB, Dougherty, TJ. Tumor destruction and kinetics of tumor cell death in two experimental mouse tumors following photodynamic therapy. *Cancer Res.* 1985;45:572-576.

7. FIGURES

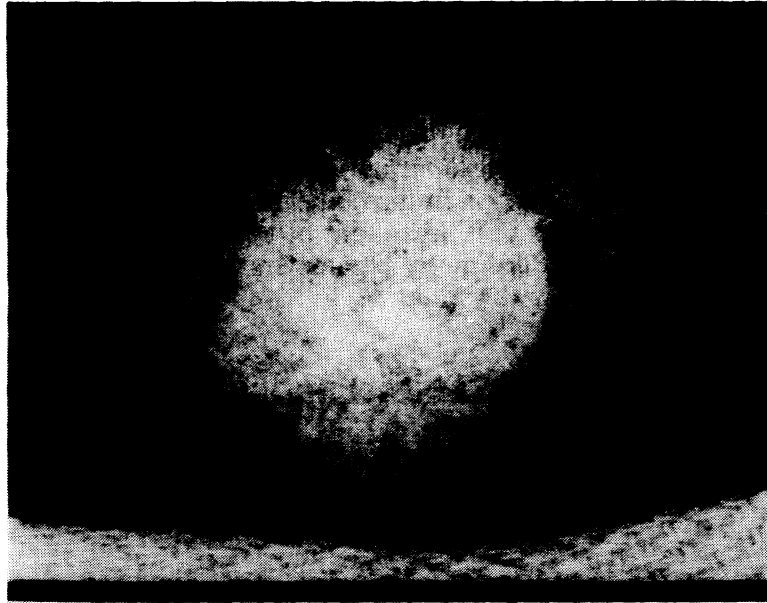


Figure 1

Twenty-nine year old Caucasian female with extensive left upper chest PWS treated with PDT using a PHOTOFRIN[®] dosage of 1.0 mg/kg. The blanching test site shown received a light dosage ($\lambda = 630 \text{ nm}$) of 100 J/cm^2 delivered 2 hours after drug administration. Photograph was taken four months after PDT.

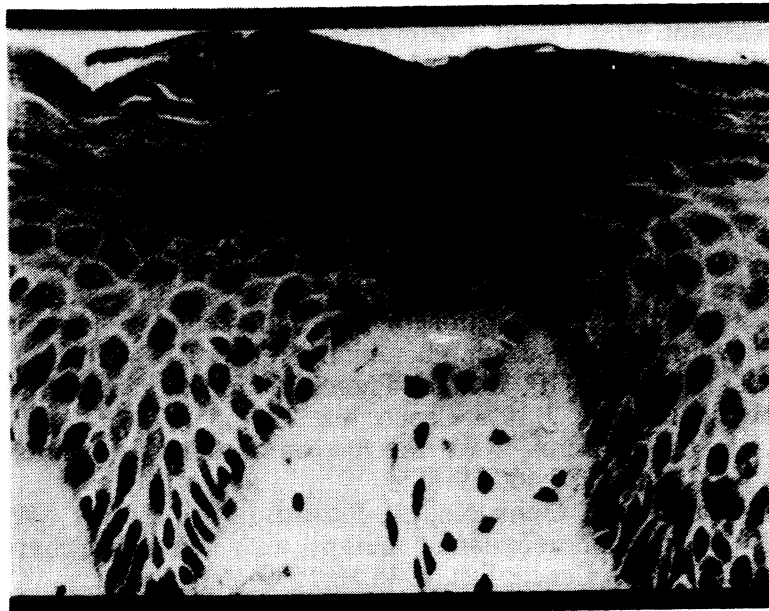

Figure 2

Histopathology from the patient shown in Figure 1. Photomicrograph is biopsy taken four months after PDT. There are no ultrastructural changes noted in the epidermis, epidermal basal layer, or epidermal/dermal junction. X 35.