

# UCSF

## UC San Francisco Previously Published Works

### Title

Safety and antitumor activity of the anti-PD-1 antibody pembrolizumab in patients with recurrent carcinoma of the anal canal

### Permalink

<https://escholarship.org/uc/item/1k4632z5>

### Journal

Annals of Oncology, 28(5)

### ISSN

0923-7534

### Authors

Ott, PA  
Piha-Paul, SA  
Munster, P  
et al.

### Publication Date

2017-05-01

### DOI

10.1093/annonc/mdx029

Peer reviewed

## ORIGINAL ARTICLE

# Safety and antitumor activity of the anti-PD-1 antibody pembrolizumab in patients with recurrent carcinoma of the anal canal

P. A. Ott<sup>1\*</sup>, S. A. Piha-Paul<sup>2</sup>, P. Munster<sup>3</sup>, M. J. Pishvaian<sup>4</sup>, E. M. J. van Brummelen<sup>5</sup>, R. B. Cohen<sup>6</sup>, C. Gomez-Roca<sup>7</sup>, S. Ejadi<sup>8</sup>, M. Stein<sup>9</sup>, E. Chan<sup>10</sup>, M. Simonelli<sup>11</sup>, A. Morosky<sup>12</sup>, S. Saraf<sup>12</sup>, K. Emancipator<sup>12</sup>, M. Koshiji<sup>12</sup> & J. Bennouna<sup>13</sup>

<sup>1</sup>Center for Immuno-Oncology, Dana-Farber Cancer Institute, Boston; <sup>2</sup>Department of Investigational Cancer Therapeutics, Division of Cancer Medicine, The University of Texas MD Anderson Cancer Center, Houston; <sup>3</sup>Department of Medicine (Hematology/Oncology), Helen Diller Family Comprehensive Cancer Center, University of California, San Francisco; <sup>4</sup>Department of Hematology/Oncology, Georgetown University, Washington DC, USA; <sup>5</sup>Department of Molecular Pathology & Clinical Pharmacology, Netherlands Cancer Institute, Amsterdam, The Netherlands; <sup>6</sup>Department of Medicine, University of Pennsylvania, Philadelphia, USA; <sup>7</sup>Clinical Research Unit, Institut Claudius Regaud and Institut Universitaire du Cancer—Oncopole, Toulouse, France; <sup>8</sup>Department of Medical Oncology, Virginia G. Piper Cancer Center, Scottsdale; <sup>9</sup>Department of Medical Oncology, Rutgers Cancer Institute of New Jersey, New Brunswick; <sup>10</sup>Department of Medicine (Hematology/Oncology), Vanderbilt-Ingram Cancer Center, Nashville, USA; <sup>11</sup>Department of Medical Oncology and Hematology, Humanitas Cancer Center, Rozzano, Italy; <sup>12</sup>Department of Clinical Oncology, Merck & Co, Inc., Kenilworth, USA; <sup>13</sup>Department of Medical Oncology, Institut de Cancérologie de l'Ouest, Nantes, France

\*Correspondence to: Dr Patrick A. Ott, Center for Immuno-Oncology, Dana-Farber Cancer Institute, 450 Brookline Avenue, Boston, MA 02215-5450, USA.  
Tel: +1-617-632-5990; E-mail: patrick\_ott@dfci.harvard.edu

Note: This study was previously presented in part at: European Cancer Congress in Vienna, Austria, on 27 September 2015; Ott PA et al., Pembrolizumab (MK-3475). For PD-L1-Positive Squamous Cell Carcinoma of the Anal Canal: Preliminary Safety and Efficacy Results From KEYNOTE-028.

**Background:** Safety and efficacy of pembrolizumab, a humanized programmed death 1 monoclonal antibody, was assessed in KEYNOTE-028, a multicohort, phase Ib trial for patients with programmed death ligand 1 (PD-L1)-positive advanced solid tumors. We report results for the cohort of patients with advanced anal carcinoma.

**Patients and methods:** Patients with PD-L1-positive tumors ( $\geq 1\%$ ) received intravenous pembrolizumab 10 mg/kg once every 2 weeks for up to 2 years or until confirmed progression or unacceptable toxicity. Response was assessed every 8 weeks for the first 6 months and every 12 weeks thereafter per Response Evaluation Criteria In Solid Tumors, version 1.1. Primary endpoints were safety and overall response rate per investigator review. Secondary endpoints included progression-free survival, overall survival, and response duration. Data cutoff date was 1 July 2015.

**Results:** Of the 43 patients with advanced anal carcinoma evaluable for PD-L1 expression, 32 (74%) had PD-L1-positive tumors as assessed with the 22C3 prototype assay, of whom 25 were enrolled between April and September 2014. Sixteen patients (64%) experienced treatment-related adverse events; the most common ones were diarrhea and fatigue in four patients (16%) each and nausea in three patients (12%). There were no treatment-related deaths or discontinuations as of the data cutoff date. Among the 24 patients with squamous cell carcinoma histology, four had confirmed partial response, for an overall response rate of 17% [95% confidence interval (CI), 5%–37%] and 10 (42%) had confirmed stable disease, for a disease control rate of 58%. One additional patient with non-squamous histology had confirmed stable disease.

**Conclusion:** In this population of patients with PD-L1-positive advanced squamous cell anal carcinoma, pembrolizumab demonstrated a manageable safety profile and encouraging antitumor activity. These data support further study of pembrolizumab for this patient population.

**ClinicalTrials.gov:** NCT02054806.

**Key words:** squamous cell advanced anal carcinoma, pembrolizumab, immunotherapy, PD-1, PD-L1, KEYNOTE-028

## Introduction

Anal carcinoma is a rare cancer type, with an incidence of 1–2 cases/100 000 per year worldwide [1]. Approximately 84% of anal carcinoma is associated with high-risk types of human papilloma virus (HPV), primarily HPV-16 [2]. The standard of care for localized disease is chemotherapy with 5-fluorouracil (5-FU) and mitomycin in combination with radiotherapy, which results in a 5-year disease-free survival rate of ~60% [3–5]. Based on limited data, the standard of care after progression or development of distant metastatic disease is 5-FU and cisplatin, and the 5-year survival rate for these patients is ~15%; however, if cisplatin-based chemotherapy fails, no other regimens have been shown to be effective [6].

Many cancers evade immune surveillance and destruction through upregulation of the immune cell checkpoint molecule programmed death ligand 1 (PD-L1). Interaction between the programmed death 1 (PD-1) receptor, expressed on tumor-infiltrating T cells, and its ligand PD-L1 leads to the functional inactivation of T cells, a mechanism known as adaptive immune resistance [7, 8]. Monoclonal antibodies against PD-1 and PD-L1, including pembrolizumab, nivolumab, and atezolizumab, have demonstrated antitumor activity in a diverse set of tumor types [9–11]. A correlation between pretreatment PD-L1 expression and response to anti-PD-1 therapy has also been reported in multiple tumor types [12–14].

The KEYNOTE-028 study evaluated pembrolizumab monotherapy in 20 different PD-L1-positive advanced or recurrent cancers with significant unmet medical need. Results from the anal carcinoma cohort of KEYNOTE-028 are reported herein.

## Methods

### Study design and population

KEYNOTE-028 (ClinicalTrials.gov, NCT02054806) is a multicenter, open-label, phase Ib trial in 20 cohorts of patients with PD-L1-positive advanced solid tumors. Patients in the anal carcinoma cohort were enrolled at 12 investigational sites in Europe and the USA.

Eligible patients had histologically or cytologically confirmed locally advanced or metastatic carcinoma of the anal canal, failure of prior standard therapy, and tumor PD-L1 positivity. Other eligibility requirements were age  $\geq 18$  years, measurable disease based on Response Evaluation Criteria In Solid Tumors, version 1.1 (RECIST v.1.1), Eastern Cooperative Oncology Group performance status of 0 or 1, and adequate organ function as established by laboratory testing conducted  $< 10$  days before the first pembrolizumab dose. Key exclusion criteria included diagnosis of immunodeficiency or systemic steroid therapy  $< 7$  days before the first pembrolizumab dose, active autoimmune disease, interstitial lung disease, active brain metastases (metastases stable for  $\geq 4$  weeks before the first pembrolizumab dose were permitted), and previous therapy with an immune checkpoint inhibitor. The study protocol and all amendments were approved by the institutional review boards or ethics committees of all participating sites. All patients provided written informed consent.

### Treatment and assessments

Pembrolizumab was given intravenously at 10 mg/kg once every 2 weeks for up to 2 years or until confirmed disease progression, unacceptable toxicity, or patient/investigator decision. Response was assessed by

computed tomography or magnetic resonance imaging every 8 weeks for the first 6 months and every 12 weeks thereafter. Adverse events (AEs) were monitored throughout the study and for 30 days after the end of treatment (90 days for serious AEs) and graded according to the National Cancer Institute Common Terminology Criteria for Adverse Events, version 4.0. AEs of special interest were defined as events with potentially drug-related immunologic causes.

An archived formalin-fixed, paraffin-embedded tumor sample or a newly obtained biopsy specimen was assessed at a central laboratory for PD-L1 expression at screening with a laboratory-developed prototype immunohistochemistry (IHC) assay (QualTek Molecular Laboratories, Goleta, CA) [15] using the 22C3 antibody (Merck & Co., Inc., Kenilworth, NJ). PD-L1 positivity was defined as membrane staining of  $\geq 1\%$  of scorable cells, including both neoplastic cells and contiguous mononuclear inflammatory cells, or the presence of a distinctive interface pattern.

### Outcomes

Primary endpoints were safety and overall response rate (ORR). ORR was determined by investigator assessment and defined as the proportion of patients having confirmed complete response (CR) or partial response (PR) per RECIST v1.1 at any time during the study. Secondary endpoints included progression-free survival (PFS), defined as time from enrollment to the first documented instance of disease progression according to RECIST v1.1 or death from any cause, whichever occurred first; overall survival (OS), defined as time from enrollment to death from any cause; and duration of response (DOR), defined as time from the first RECIST v1.1-based response to disease progression in patients who experienced PR or better.

### Statistical analysis

The binomial exact method was used for power and sample size calculations. A sample size of 22 assessable patients in this cohort was calculated to provide 80% power to demonstrate that the best ORR exceeded 10% at an overall one-sided 8% alpha-level if the true ORR within the cohort was 35%. Efficacy was assessed in patients who received  $\geq 1$  dose of pembrolizumab and had measurable disease at baseline according to RECIST v1.1. Safety was assessed in patients who received  $\geq 1$  dose of pembrolizumab. The truncated sequential probability test was used for evaluation of ORR. The Kaplan–Meier method was used to estimate PFS, OS, and DOR. The data cutoff date for this report was 1 July 2015.

## Results

### Baseline patient characteristics

Of 43 patients screened for PD-L1 expression, 32 (74%) had PD-L1-positive tumors as assessed with the prototype IHC assay. Four of these patients did not meet eligibility criteria, three were excluded after the enrollment limit was reached, and the other 25 were enrolled between April and September 2014. Median age was 63 years (range 46–82 years), 23 patients (92%) were women, and the majority (96%) had squamous cell carcinoma (SCC) (Table 1). One patient with non-SCC histology (perineal epidermoid carcinoma) was enrolled as a protocol violation. Most patients were pretreated, with 13 (52%) having received  $\geq 2$  prior treatments for advanced disease. Although three (12%) patients did not receive prior treatment of advanced disease, they experienced disease progression shortly after receiving adjuvant and/or (neo)adjuvant treatment.

**Table 1. Patient baseline characteristics**

Characteristic	N = 25
Median age, years (range)	63 (46–82)
Sex	
Male	2 (8)
Female	23 (92)
Race	
White	19 (76)
Black or African American	1 (4)
Not specified	5 (20)
ECOG performance status	
0	5 (20)
1	20 (80)
Histology at baseline	
SCC	24 (96)
Perineal epidermoid carcinoma <sup>a</sup>	1 (4)
Adjuvant or neoadjuvant systemic therapy	6 (24)
Prior radiation	18 (72)
Prior lines of therapy for advanced disease	
0 <sup>b</sup>	3 (12)
1	7 (28)
2	6 (24)
≥3	7 (28)
Unknown	2 (8)
Prior therapies for advanced disease <sup>c</sup>	
5-FU + mitomycin	15 (60)
5-FU ± platinum ± other	12 (48)
Gemcitabine + platinum ± other	4 (16)
Chk-1 inhibitor	2 (8)
Etirinotecan pegol	2 (8)
Other	10 (40)

Data are presented as *n* (%) unless indicated otherwise.

<sup>a</sup>Protocol violation.

<sup>b</sup>Although these three patients did not receive prior treatment for advanced disease, they had disease progression shortly after receiving adjuvant and/or (neo)adjuvant treatment.

<sup>c</sup>Patients could have received >1 prior therapy.

5-FU, 5-fluorouracil; Chk-1, checkpoint kinase 1; ECOG, Eastern Cooperative Oncology Group; SCC, squamous cell carcinoma.

**Table 2. Treatment-related adverse events**

Any-grade adverse events occurring in ≥ 2 patients, <i>n</i> (%)	N = 25
Diarrhea	4 (16)
Fatigue	4 (16)
Nausea	3 (12)
Dry mouth	2 (8)
Hypersensitivity	2 (8)
Hypothyroidism	2 (8)
Night sweats	2 (8)
Stomatitis	2 (8)
Thrombocytopenia	2 (8)
Vomiting	2 (8)
<b>Grade 3–4 adverse events occurring in ≥ 1 patient, <i>n</i> (%)</b>	
Colitis (grade 3) <sup>a</sup>	1 (4)
Diarrhea (grade 3) <sup>a</sup>	1 (4)
General physical health deterioration (grade 3)	1 (4)
Increased blood thyroid stimulating hormone (grade 3)	1 (4)

<sup>a</sup>Occurred in the same patient.

**Table 3. Best overall response in patients with SCC histology (N = 24)**

Best response <sup>a</sup>	<i>n</i>	%	95% CI
Complete response	0	0	0–14
Partial response	4	17	5–37
Stable disease	10	42	22–63
Progressive disease	9	38	19–59
Not assessed <sup>b</sup>	1	4	0–21

<sup>a</sup>All responses are confirmed.

<sup>b</sup>Patient discontinued therapy because of toxicity before the first post-baseline response assessment.

CI, confidence interval; SCC, squamous cell carcinoma.

## Safety

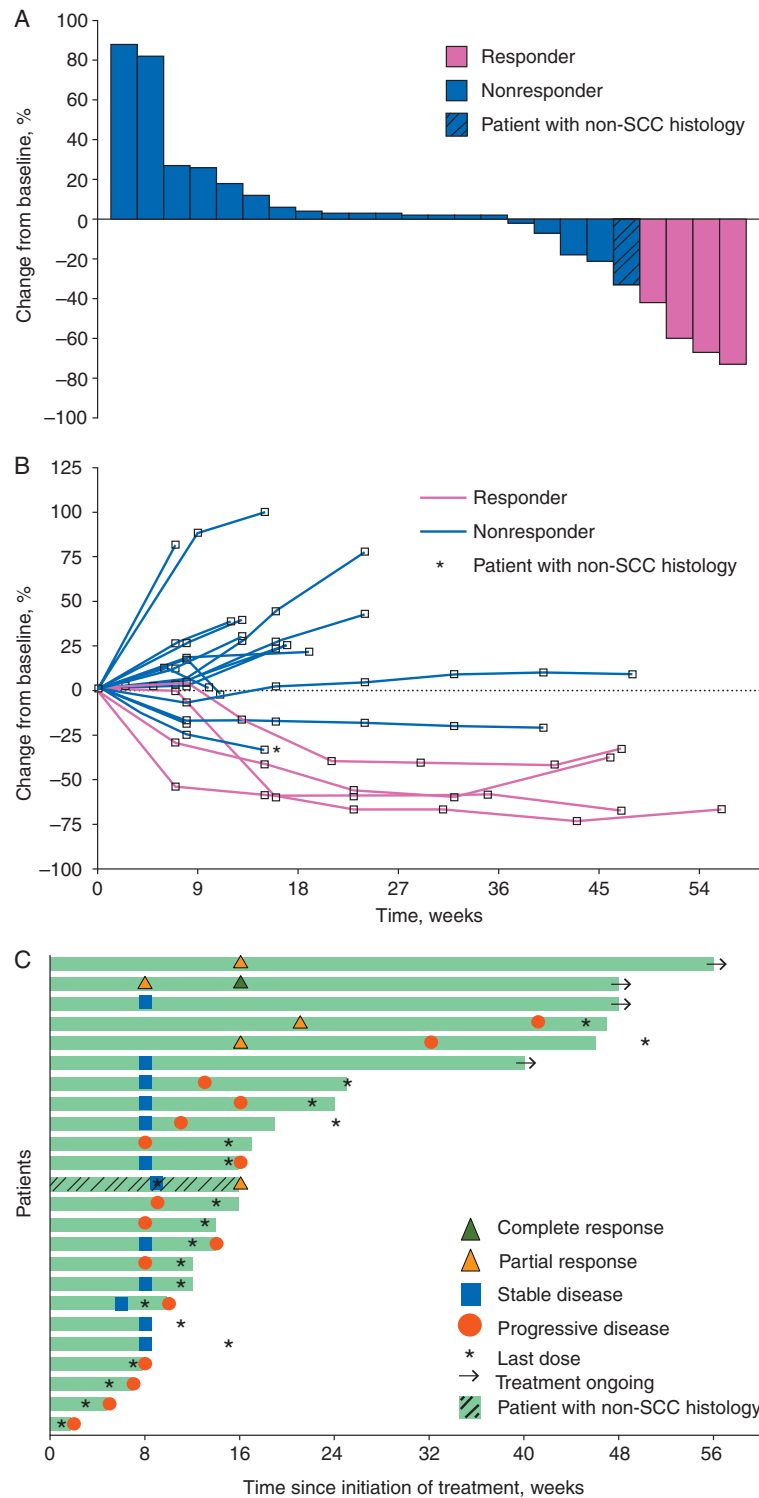
As of the data cutoff date, median follow-up duration was 10.6 months (range 0.3–15.0 months) and median duration of therapy was 92 days (range 1–449 days). Sixteen patients (64%) experienced treatment-related AEs (Table 2), most commonly diarrhea, fatigue (*n* = 4 each; 16%), and nausea (*n* = 3; 12%). There were four grade 3 treatment-related AEs, including increased blood thyroid-stimulating hormone (TSH) level and general physical health deterioration (*n* = 1 each), and colitis and diarrhea in the same patient. No grade 4 or higher treatment-related AEs were seen. Treatment-related AEs of special interest occurred in three patients (12%): grade 2 hypothyroidism in two patients and grade 3 colitis in one patient. One additional patient experienced grade 2 hypothyroidism not considered by the investigator to be related to treatment and grade 3 treatment-related increased

TSH, which was not included as a term in the analysis of AEs of special interest.

Of 25 enrolled patients, one patient discontinued therapy because of toxicity before the first postbaseline response evaluation (grade 5 intestinal perforation unrelated to pembrolizumab treatment). There were no treatment-related study discontinuations or deaths as of the data cutoff date.

## Clinical activity

By investigator review, ORR was 17% [95% confidence interval (CI), 5.0%–37%] among the 24 patients with SCC histology, and all four patients had confirmed PR (Table 3). Ten patients (42%) had confirmed stable disease (SD) with a median duration of 3.6 months (range 1.8+ to 11+ months). The disease control rate was 58% (14 of 24 patients). The one patient with non-SCC histology (perineal epidermoid carcinoma) had confirmed SD at 9 weeks and unconfirmed PR as of the data cutoff date and was



**Figure 1.** (A) Maximum change from baseline in tumor size. Includes patients with  $\geq 1$  postbaseline tumor assessment ( $n = 24$ ). Responders were defined as patients having confirmed complete response or partial response per RECIST v1.1 by investigator review. (B) Longitudinal change from baseline in tumor size. Includes patients with  $\geq 1$  postbaseline tumor assessment ( $n = 24$ ). Responders were defined as patients having confirmed complete response or partial response per RECIST v1.1 by investigator review. (C) Treatment exposure and response duration. The length of each bar represents the time to the last radiographic assessment. Both confirmed and unconfirmed responses per RECIST v1.1 by investigator review are shown.

subsequently lost to follow-up. All five responders, regardless of histology, had received prior therapy for advanced disease.

Overall, nine (38%) of 24 assessable patients had a decrease from baseline in the size of their target lesions (Figure 1A), which

was maintained over several assessments (Figure 1B). Among the five patients with a response, regardless of histology, median time to response was 3.6 months (range 1.6–4.8 months), and median DOR was not reached (range  $<0.1+$  to 9.2+ months). At the

time of analysis, two of the four responses in patients with SCC histology were ongoing (Figure 1C) and were sustained for longer than 9 months (see supplementary materials, available at *Annals of Oncology* online, for additional details on these two patients). Two patients with SD also remained on treatment as of the data cutoff date.

Median PFS was 3.0 months (95% CI 1.7–7.3 months), and 6- and 12-month PFS rates were 31.6% and 19.7%, respectively (supplementary Figure S1A, available at *Annals of Oncology* online). Median OS was 9.3 months (95% CI, 5.9 months to not available), and the 6- and 12-month OS rates were 64.5% and 47.6%, respectively (supplementary Figure S1B, available at *Annals of Oncology* online).

## Discussion

Because PD-L1 expression is associated with higher antitumor activity of PD-1 blockade in other tumor types [12–14], PD-L1 positivity was used as a selection criterion in this study to potentially enrich for patients most likely to respond to pembrolizumab. In this population of mostly pretreated patients with PD-L1-positive advanced anal carcinoma, pembrolizumab demonstrated manageable safety and encouraging antitumor activity, with an ORR of 17% in those patients with SCC histology (4 of 24 patients). To our knowledge, this study represents the first published manuscript describing immune checkpoint blockade in patients with previously treated advanced anal carcinoma.

PD-L1 positivity, which had not been previously defined in anal cancer, was found to be high (74% of screened patients) in this study. The high rate of PD-L1 expression in anal cancer may not be surprising given the immune responses against the HPV E7 oncoprotein identified previously in this tumor type [16]. High frequencies of tumor-infiltrating lymphocytes and inflammatory responses have been identified in virally driven cancers and have been linked with upregulation of PD-L1 in HPV-associated head and neck cancer [17–19]. This upregulation of PD-L1 is mediated by interferon- $\gamma$  secreted by T cells and has been termed ‘adaptive immune resistance’ [8, 20]. HPV status was not collected in this study and was only available for three of the enrolled patients (two responders and one non-responder), all of whom were HPV positive. The number of patients in this study with known HPV status was too small to determine an association with pembrolizumab activity.

Similar to the results of other immune checkpoint inhibitors in various tumor types [11–13], only a subset of patients with PD-L1-positive tumors in this study experienced clinical benefit, suggesting that other biomarkers should be explored for the ability to predict antitumor activity of pembrolizumab. Immune gene signatures were shown to correlate with response to PD-1 blockade in several other solid tumor types [21–23], and an association between tumor infiltration of CD8+ and CD3+ T cells with response to PD-1 inhibition was reported with another anti-PD-1 antibody, nivolumab, in patients with SCC anal carcinoma [24]. Mutational load has been reported to correlate with response to immune checkpoint blockade in other cancers including melanoma, non-small cell lung cancer, and colorectal cancer, and may be relevant in advanced anal carcinoma as well [25–28]. Although the mutational rate of anal cancer has not been assessed comprehensively, it has been reported to

be in the intermediate range, along with other HPV-associated cancers such as head and neck and cervical cancer [29–31].

In conclusion, pembrolizumab demonstrated manageable safety and encouraging antitumor activity in patients with PD-L1-positive advanced SCC anal carcinoma. Further evaluation of PD-1 blockade, alone or in combination with a partnering agent, in this patient population and of potential biomarkers is warranted.

## Acknowledgments

The authors thank the patients and their families and all investigators and site personnel; Karen Stein (Merck & Co., Inc., Kenilworth, NJ) for data interpretation; QualTek Molecular Laboratories (Goleta, CA) for PD-L1 immunohistochemistry assay testing; Ann Swift (Merck & Co., Inc., Kenilworth, NJ) for manuscript preparation; and Roger Dansey (Merck & Co., Inc., Kenilworth, NJ) for critical manuscript review. Medical writing and editorial assistance, funded by Merck & Co., Inc., were provided by Sarah Adai and Payal Gandhi of the ApotheCom oncology team (Yardley, PA).

## Funding

Funding for this study was provided by Merck & Co., Inc., Kenilworth, NJ. No grant numbers apply.

## Disclosure

PAO: research funding from BMS, Merck & Co., Inc., Celldex, Astra-Zeneca/MedImmune, ArmoBiosciences; consultancy for BMS, Amgen, Celldex, Alexion, Cytomx; speaking fee from Merck & Co., Inc.; MJP, EMJV, and RBC: research funding from Merck & Co, Inc.; MS (Stein): research funding from Merck & Co., Inc., Roche, and Amgen; EC: research funding from Merck & Co., Inc.; advisory boards for Advaxis, Merrimack, EMD Serono, Taiho, and Bayer; AM, SS, and MK: employee of Merck Sharp & Dohme Corp., a subsidiary of Merck & Co., Inc., Kenilworth, NJ; KE: employee of and stock ownership in Merck Sharp & Dohme Corp., a subsidiary of Merck & Co., Inc., Kenilworth, NJ; stock ownership in Bayer AG and Johnson and Johnson; spousal employment by and stock ownership of Celgene; JB: research funding from Merck & Co, Inc.; personal fees (advisory boards and symposia) from Astra-Zeneca, Boehringer-Ingelheim, Merck & Co., Inc., and Roche; SAPP, PM, CGR, SE, and MS: none.

## References

1. Grulich AE, Poynten IM, Machalek DA et al. The epidemiology of anal cancer. *Sex Heal* 2012; 9: 504–508.
2. De Vuyst H, Clifford GM, Nascimento MC et al. Prevalence and type distribution of human papillomavirus in carcinoma and intraepithelial neoplasia of the vulva, vagina and anus: a meta-analysis. *Int J Cancer* 2009; 124: 1626–1636.
3. Bartelink H, Roelofsens F, Eschwege F et al. Concomitant radiotherapy and chemotherapy is superior to radiotherapy alone in the treatment of locally advanced anal cancer: results of a phase III randomized trial of the European Organization for Research and Treatment of Cancer

- Radiotherapy and Gastrointestinal Cooperative Groups. *J Clin Oncol* 1997; 15: 2040–2049.
4. Flam M, John M, Pajak TF et al. Role of mitomycin in combination with fluorouracil and radiotherapy, and of salvage chemoradiation in the definitive nonsurgical treatment of epidermoid carcinoma of the anal canal: results of a phase III randomized intergroup study. *J Clin Oncol* 1996; 14: 2527–2539.
  5. Ajani JA, Winter KA, Gunderson LL et al. Fluorouracil, mitomycin, and radiotherapy vs fluorouracil, cisplatin, and radiotherapy for carcinoma of the anal canal: a randomized controlled trial. *JAMA* 2008; 299: 1914–1921.
  6. National Comprehensive Cancer Network, Inc.: NCCN Clinical Practice Guidelines in Oncology. Anal Carcinoma v.1 2017. 2016. [https://www.nccn.org/professionals/physician\\_gls/pdf/anal.pdf](https://www.nccn.org/professionals/physician_gls/pdf/anal.pdf) (24 October 2016, date last accessed).
  7. Spranger S, Spaepen RM, Zha Y et al. Up-regulation of PD-L1, IDO, and T<sub>regs</sub> in the melanoma tumor microenvironment is driven by CD8<sup>+</sup> T cells. *Sci Transl Med* 2013; 5: 200ra116.
  8. Taube JM, Anders RA, Young GD et al. Colocalization of inflammatory response with B7-H1 expression in human melanocytic lesions supports an adaptive resistance mechanism of immune escape. *Sci Transl Med* 2012; 4: 127ra37.
  9. Sharma P, Allison JP. The future of immune checkpoint therapy. *Science* 2015; 348: 56–61.
  10. Powles T, Eder JP, Fine GD et al. MPDL3280A (anti-PD-L1) treatment leads to clinical activity in metastatic bladder cancer. *Nature* 2014; 515: 558–562.
  11. Muro K, Chung HC, Shankaran V et al. Pembrolizumab for patients with PD-L1-positive advanced gastric cancer (KEYNOTE-012): a multicentre, open-label, phase 1b trial. *Lancet Oncol* 2016; 17: 717–726.
  12. Topalian SL, Hodi FS, Brahmer JR et al. Safety, activity, and immune correlates of anti-PD-1 antibody in cancer. *N Engl J Med* 2012; 366: 2443–2454.
  13. Garon EB, Rizvi NA, Hui R et al. for the KEYNOTE-001 Investigators: Pembrolizumab for the treatment of non-small-cell lung cancer. *N Engl J Med* 2015; 372: 2018–2028.
  14. Larkin J, Chiarion-Sileni V, Gonzalez R et al. Combined nivolumab and ipilimumab or monotherapy in untreated melanoma. *N Engl J Med* 2015; 373: 23–34.
  15. Dolled-Filhart M, Locke D, Murphy T et al. Development of a prototype immunohistochemistry assay to measure programmed death ligand-1 expression in tumor tissue. *Arch Pathol Lab Med* 2016; 140: 1259–1266.
  16. Draper LM, Kwong MLM, Gros A et al. Targeting of HPV-16<sup>+</sup> epithelial cancer cells by TCR gene engineered T cells directed against E6. *Clin Cancer Res* 2015; 21: 4431–4439.
  17. Heusinkveld M, Goedemans R, Briet RJP et al. Systemic and local human papillomavirus 16-specific T-cell immunity in patients with head and neck cancer. *Int J Cancer* 2012; 131: E74–E85.
  18. Lyford-Pike S, Peng S, Young GD et al. Evidence for a role of the PD-1:PD-L1 pathway in immune resistance of HPV-associated head and neck squamous cell carcinoma. *Cancer Res* 2013; 73: 1733–1741.
  19. Partlová S, Bouček J, Kloudová K et al. Distinct patterns of intratumoral immune cell infiltrates in patients with HPV-associated compared to non-virally induced head and neck squamous cell carcinoma. *Oncoimmunology* 2015; 4: e965570.
  20. Spranger S, Bao R, Gajewski TF. Melanoma-intrinsic  $\beta$ -catenin signalling prevents anti-tumour immunity. *Nature* 2015; 523: 231–235.
  21. Ribas A, Robert C, Hodi FS et al. Association of response to programmed death receptor 1 (PD-1) blockade with pembrolizumab (MK-3475) with an interferon-inflammatory immune gene signature. *J Clin Oncol* 2015; 33(Suppl): Abstr 3001.
  22. Seiwert T, Burtneß B, Weiss J et al. Inflamed-phenotype gene expression signatures to predict benefit from the anti-PD-1 antibody pembrolizumab in PD-L1+ head and neck cancer patients. *J Clin Oncol* 2015; 33(Suppl): Abstr 6017.
  23. Shankaran V, Muro K, Bang Y-J et al. Correlation of gene expression signatures and clinical outcomes in patients with advanced gastric cancer treated with pembrolizumab (MK-3475). *J Clin Oncol* 2015; 33(Suppl): Abstr 302.
  24. Morris VK, Mahvash A, Vence L et al. NCI#9673 phase II study of nivolumab in refractory metastatic squamous cell carcinoma of the anal canal: immunologic correlates of response. Presented at the American Association for Cancer Research Annual Meeting, New Orleans, LA, 16–20 April 2016.
  25. Rizvi NA, Hellmann MD, Snyder A et al. Mutational landscape determines sensitivity to PD-1 blockade in non-small cell lung cancer. *Science* 2015; 348: 124–128.
  26. Snyder A, Makarov V, Merghoub T et al. Genetic basis for clinical response to CTLA-4 blockade in melanoma. *N Engl J Med* 2014; 371: 2189–2199.
  27. Van Allen EM, Miao D, Schilling B et al. Genomic correlates of response to CTLA-4 blockade in metastatic melanoma. *Science* 2015; 350: 207–211.
  28. Le DT, Uram JN, Wang H et al. PD-1 blockade in tumors with mismatch-repair deficiency. *N Engl J Med* 2015; 372: 2509–2520.
  29. The Cancer Genome Atlas Network: Comprehensive genomic characterization of head and neck squamous cell carcinomas. *Nature* 2015; 517: 576–582.
  30. Ojesina AI, Lichtenstein L, Freeman SS et al. Landscape of genomic alterations in cervical carcinomas. *Nature* 2014; 506: 371–375.
  31. Chung JH, Sanford E, Johnson A et al. Comprehensive genomic profiling of anal squamous cell carcinoma reveals distinct genomically defined classes. *Ann Oncol* 2016; 27: 1336–1341.