

UCSF

UC San Francisco Previously Published Works

Title

A case of tracheo-innominate artery fistula successfully treated with endovascular stent of the innominate artery.

Permalink

<https://escholarship.org/uc/item/1k3991g1>

Journal

Journal of general and family medicine, 18(4)

ISSN

2189-6577

Authors

Yogo, Aoi
Komori, Masafumi
Yano, Yudai
[et al.](#)

Publication Date

2017-08-01

DOI

10.1002/jgf2.37

Peer reviewed

A case of tracheo-innominate artery fistula successfully treated with endovascular stent of the innominate artery

Aoi Yogo MD¹ | Masafumi Komori MD¹ | Yudai Yano MD¹ | Koji Fujita MD¹ |
Eiichiro Sando MD¹ | Mitsuhsa Kotani MD² | Hiroshi Sugimura MD³ | Atsushi Ochi MD⁴ |
Sandra Moody MD, BSN, AGSF¹ | Makito Yaegashi MD, FACP, FCCP¹

¹General Internal Medicine, Kameda Medical Center, Kamogawa, Chiba, Japan

²Cardiovascular Surgery, Kameda Medical Center, Kamogawa, Chiba, Japan

³Thoracic Surgery, Kameda Medical Center, Kamogawa, Chiba, Japan

⁴Otorhinolaryngology, Kameda Medical Center, Kamogawa, Chiba, Japan

Correspondence

Aoi Yogo, General Internal Medicine, Kameda Medical Center, Kamogawa, Chiba, Japan.
Email: ygai0430@yahoo.co.jp

Abstract

Tracheo-innominate artery fistula (TIF) is a rare but life-threatening complication of tracheostomy. We describe a 44-year-old man who was admitted for a pressure ulcer infection with a third tracheostomy in place. He showed massive hemoptysis from the TIF, followed by cardiopulmonary arrest. The cuff of the tube was hyperinflated; however, even a slight movement of the tube resulted in recurrent massive hemorrhage. Thus, an endovascular stent graft was placed. Our case shows that sentinel bleeding may be found prior to TIF, and an endovascular repair can be a lifesaving temporizing option, when the hemorrhage was not controlled by hyperinflating the cuff of the tube.

KEYWORDS

endovascular repair, endovascular stent graft, sentinel bleeding, tracheostomy, tracheo-innominate artery fistula (TIF)

1 | INTRODUCTION

Tracheo-innominate artery fistula (TIF) is a life-threatening complication of tracheostomy, and the management of TIF is a surgical emergency.¹ Bleeding results from vessel erosion caused by direct pressure on the innominate artery either from the tip of the tracheal cannula or from an overinflated cuff.² Sentinel bleeding, a small amount of hemoptysis, can be found in patients prior to TIF. If patients present with massive hemorrhage, the first step to control brisk bleeding, while planning operative intervention, is to hyperinflate the cuff while adjusting the depth of the endotracheal tube to apply pressure to the bleeding site.³ However, some will experience recurrent hemorrhage even with this technique. In this situation, an endovascular repair could be a lifesaving temporizing option to control bleeding.^{4,5} Here we describe a patient who presented with TIF after sentinel bleeding and whose condition was stabilized with an endovascular stent while waiting for a definitive

operation. In addition, we review the current literature regarding this topic.

2 | CASE

A 44-year-old man with a tracheostomy was admitted for septic shock from a sacral pressure ulcer infection. He had a history of diabetes, end-stage kidney disease on hemodialysis, spinal cord injury at level T5-T6 due to a motor vehicle accident at the age of 16, and bilateral hemipelvectomy and lower-limb amputation because of recurrent osteomyelitis related to the pressure ulcers. His first tracheostomy was performed outside hospital in anticipation of the need for long-term mechanical ventilatory support as a result of acute respiratory failure secondary to gas gangrene from the pressure ulcer infection and pneumonia with CO₂ narcosis. He underwent his third tracheostomy 72 days before admission. The tracheal cannula

(Speech Cannula[®], Koken[®], Tokyo, Japan) had been used with the cuff inflated. There was a small amount of hemoptysis 4 days prior to obvious onset of the TIF. He had no anticoagulant or antiplatelet agent, and his platelet and coagulation function tests within the normal range.

On day 16 in the hospital, massive hemorrhage from the tracheostomy site ensued during suctioning, followed by cardiopulmonary arrest from asphyxiation. After cardiopulmonary resuscitation and replacement of the tracheostomy tube with an endotracheal tube were performed, he was transferred to the intensive care unit where he suffered a second cardiopulmonary arrest from hemoptysis-induced upper airway obstruction. Fiberoptic laryngoscopy showed the TIF as the source of bleeding based on the right anterior location of the hemorrhage and adjacent anatomical location of the trachea and innominate artery, as observed on previous computed tomography (Figure 1A). The cuff of the tube was hyperinflated, but even a slight movement of the tube resulted in recurrent massive hemorrhage. Thus, an endovascular stent graft was placed from his right common carotid artery under general anesthesia. Because the innominate artery was short (4 cm), placing endovascular stent within the length of innominate artery was not expected to seal the bleeding site. Therefore, the procedure to place a 7 cm endovascular stent graft (PXL161007, Gore[®] Excluder[®], Gore) through the innominate and right proximal common carotid arteries sacrificing the right subclavian artery was selected (Figure 2A,B). There was no further

hemorrhaging from the TIF. Four days later, he had an anterior mediastinal tracheostomy after laryngotracheal separation using a pectoralis major myocutaneous flap (Figure 1B). The postoperative course was uneventful with no neurologic sequela.

3 | DISCUSSION

The incidence of TIF in patients who have undergone tracheostomy is 0.1%-1% with peak incidence 3 days to 6 weeks following tracheostomy.^{1,4,6} TIF has a mortality rate approaching 100% without operative intervention, and the survival rate may reach 80% among properly managed patients.^{1,2,5} Several authors suggested some contributing factors for TIF formation, such as a low tracheostomy, performed below the third or fourth tracheal rings, overinflated cuff, prolonged tracheostomy, and neck/chest deformity.⁷

Tracheobronchial bleeding in the form of bloody secretions is found in 22% of patients who have undergone tracheostomy,⁸ and sentinel bleeding is observed in approximately 50% of TIF patients.¹ Pulsations of the tracheal cannula were also reported in only 5% of the patients.¹ Bleeding within 48 h is typically associated with local factors such as traumatic puncture of anterior jugular or inferior thyroid veins, systemic coagulopathy, erosions secondary to tracheal suction, or bronchopneumonia.^{1,4} Any patient having >10 ml of blood at the tracheostomy site or cannula 48 h or more after tracheostomy must

FIGURE 1 (A) (before endovascular repair) Adjacent anatomical location of the trachea and innominate artery as observed on computed tomography. (B) (after endovascular repair) Contrast-enhanced computed tomography after the anterior mediastinal tracheostomy and laryngotracheal separation

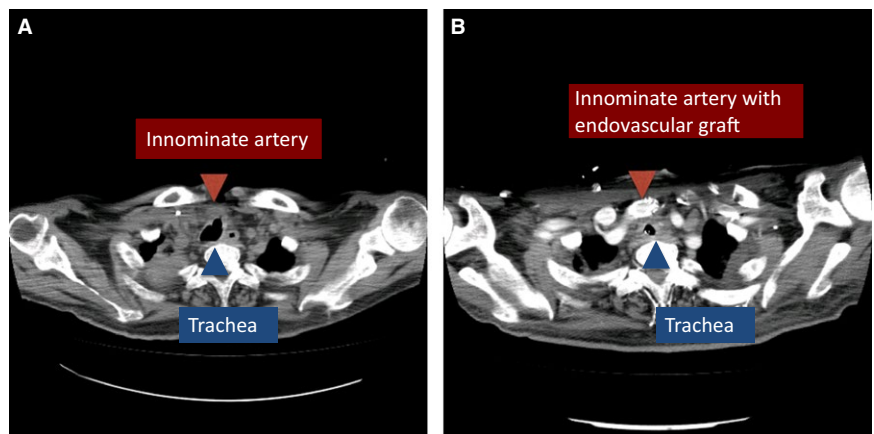
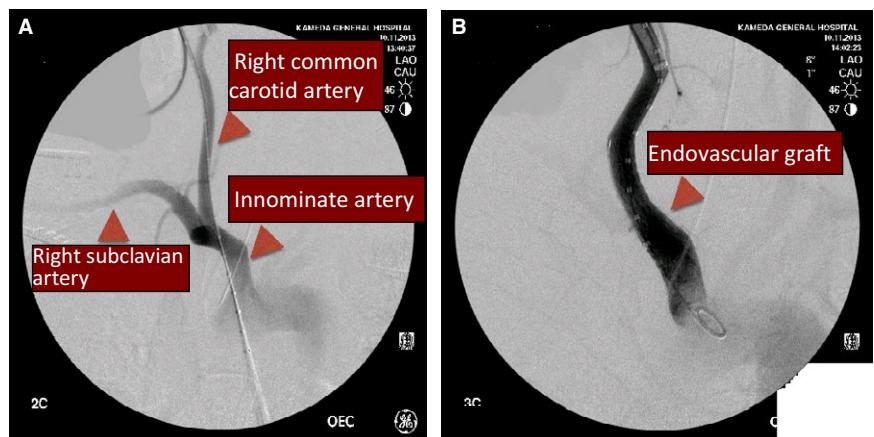


FIGURE 2 (A) The angiography revealed no anatomical anomaly of the trachea and innominate artery, or no leakage of contrast from the fistula. (B) The angiography after an endovascular stent graft was placed through the innominate and right proximal common carotid arteries



be assumed to have bleeding from tracheo-innominate erosion until proven otherwise.^{4,5} Direct visualization is accomplished with a flexible nasopharyngoscope or a bronchoscope through the tube. Bleeding from the right anterior wall at the 6-7 tracheal rings is consistent with the diagnosis.³ Thus, any bleeding from a tracheostomy site should not be taken lightly.

If TIF is suspected, the first three emergency steps must be taken to control the bleeding until the start of the operation. First, flexible bronchoscopy through the tracheostomy tube should be performed to clear and secure the airway. Second, the tracheostomy cuff should be hyperinflated. Finally, the depth of the tracheostomy tube need to be adjusted in order to apply the pressure to the bleeding site, or digital compression should be applied by inserting the finger into the tracheostomy incision to pressure against the right anterior location between the trachea and innominate artery.^{1,3,5} Although this is successful in 80% of the cases, some will experience recurrent hemorrhage despite this technique.⁵ In such situations, an endovascular stent could be a lifesaving temporizing option to control bleeding while maintaining the airway. If there are no percutaneous angioplasty and operating system in your facility, you should transfer to the facility while retaining the compression.¹

Fourteen cases have been reported so far, in which endovascular stent was used prior to surgical treatment in the management of TIF.⁹ However, without subsequent operative intervention, the risk of graft infection is high owing to the adjacent anatomical location of the trachea and innominate artery.¹⁰ Thus, the standard and definitive treatment is resection of the innominate artery in contact with the tracheal erosion and suture of the divided ends so that no artery remains in contact with the trachea for further erosions to occur.^{5,9} There are insufficient data to use the endovascular stent graft repair as the first-line treatment replacing the surgical treatment. A case of recurrent TIF due to stent graft fracture is reported as well. Long-term follow-up data for success and complications are needed before widespread use for this purpose.⁹

In conclusion, tracheo-innominate artery fistula should be considered in patients with the bleeding from the tracheostomy site, as a rare but life-threatening complication of tracheostomy. In addition, an endovascular stent can be a lifesaving temporizing option for TIF when the hemorrhage could not be controlled by hyperinflating the cuff of the tube.

CONFLICT OF INTEREST

The authors have stated explicitly that there are no conflicts of interest in connection with this article.

REFERENCES

1. Grant CA, Dempsey G, Harrison J, et al. Tracheo-innominate artery fistula after percutaneous tracheostomy: three case reports and a clinical review. *Br J Anaesth*. 2006;96:127-31.
2. Fujio N, Kazumitsu O, Kazuo K, et al. Tracheo-innominate artery fistula after tracheostomy: a case report. *J Japan Soc Resp Endos*. 1997;19:400-4.
3. Patel MR, Cannon TY, Shores CG. Chapter 242. Complication of Airway Devices. In: Tintinalli JE, Stapczynski JS, Ma OJ, Cline DM, Cydulka RK, Meckler GD, editors. *Tintinalli's emergency medicine: A comprehensive study guide*. New York: The McGraw-Hill Companies. 7th Edition. 2011; p. 1594-5.
4. Maeda M, Kubo A, Watanabe M, et al. A case of tracheoinnominate artery fistula after tracheostomy. *Jpn J Neurosurg (Tokyo)*. 2013;22:141-5.
5. Jones JW, Reynolds M, Hewitt RL, et al. Tracheo-innominate artery erosion: successful surgical management of a devastating complication. *Ann Surg*. 1976;184:194-204.
6. Scalise P, Prunk SR, Healy D, et al. The incidence of tracheoarterial fistula in patients with chronic tracheostomy tubes: a retrospective study of 544 patients in a long-term care facility. *Chest*. 2005;128:3906-9.
7. Teruya K, Sowa T, Fujinaga T, et al. Tracheo-innominate artery fistula: two case reports and a clinical review. *Ann Thorac Cardiovasc Surg*. 2013;19:60-2.
8. Arola MK. Tracheostomy and its complications. A retrospective study of 794 tracheostomized patients. *Ann Chir Gynaecol*. 1981;70:96-106.
9. Ahn HY, Son BS, Kim DH, et al. Recurrent tracheoinnominate artery fistula due to stent graft fracture. *Eur J Pediatr Surg Rep*. 2015;3:12-4.
10. Tadashi M, Makoto M, Sachiho F, et al. Tracheoinnominate artery fistula: a case report. *J Japan Surg Assoc*. 2002;63:2399-401.

How to cite this article: Yogo A, Komori M, Yano Y, et al. A case of tracheo-innominate artery fistula successfully treated with endovascular stent of the innominate artery. *J Gen Fam Med*. 2017;18:162-164. <https://doi.org/10.1002/jgf2.37>