

UC Davis

Dermatology Online Journal

Title

Adenocarcinoma of the colon presenting with scrotal metastasis: case report and review of the literature

Permalink

<https://escholarship.org/uc/item/1jg0t4kw>

Journal

Dermatology Online Journal, 22(1)

Authors

Udkoff, Jeremy
Cohen, Philip R

Publication Date

2016

DOI

10.5070/D3221029794

Copyright Information

Copyright 2016 by the author(s). This work is made available under the terms of a Creative Commons Attribution-NonCommercial-NoDerivatives License, available at <https://creativecommons.org/licenses/by-nc-nd/4.0/>

Peer reviewed

Case presentation

Adenocarcinoma of the colon presenting with scrotal metastasis: case report and review of the literature

Dermatology Online Journal 22 (1): 11

Jeremy Udkoff MA¹ and Philip R Cohen MD²

¹Medical School, and ²Department of Dermatology, University of California San Diego, San Diego, CA

Correspondence:

Jeremy Udkoff, MA
1265 Canyon Rim Cir
Westlake Village, CA 91362
jeremy.udkoff@gmail.com

Philip R. Cohen, MD
10991 Twinleaf Ct
San Diego, CA 92131
mitehead@gmail.com

Abstract

Background: The scrotum is an uncommon site for cutaneous metastases from visceral malignancies.

Purpose: A man with colon cancer, which subsequently developed cutaneous metastasis to the scrotum is described.

Materials and Methods: PubMed medical database was used to search the following terms separately and in combination: cutaneous metastasis, skin metastasis, scrotal metastasis, scrotum, rectal cancer, and colon cancer.

Results: Cutaneous metastasis most frequently occur in the vicinity of the primary tumor. Skin sites of metastatic cancer may include the abdomen, back, chest, face, scalp, and genitalia. The reported patient developed metastatic cutaneous lesions of his colon cancer not only on the abdomen but also on the scrotum. Including our patient, 9 men have been described with metastatic colon or rectal carcinoma localized to the scrotum. The lesions were the presenting sign of malignancy in one man and in the others, the lesions appeared within 24 months of their initial diagnosis of cancer. The skin metastases were pleomorphic; they appeared as papules, nodules and/or cutaneous induration. Survival data was only reported in five of the patients. However, colon or rectal metastases to the scrotum is a poor prognostic sign with a mean survival time of 11 months.

Conclusion: Scrotal metastases from carcinoma of the colon or rectum may be the initial presentation of malignancy or herald the discovery of recurrent disease. The morphology of the metastatic tumor is variable: papules, nodules and/or sclerosis. The development of scrotal metastases from colon or rectal carcinoma portends a poor prognosis. Most of the patients succumb to their metastatic disease within a year.

Keywords: Adenocarcinoma, cancer, colon, colorectal, cutaneous, metastasis, and scrotum

Introduction

Cutaneous metastases usually represent progressive or recurrent visceral carcinoma [1]. However, albeit rarely, they can be the presenting sign of a previously undiagnosed internal malignancy [2]. Colorectal carcinoma uncommonly metastasizes to the skin,

and the scrotum is an exceedingly rare site for these metastases [3]. We describe a man with metastatic colorectal adenocarcinoma to the scrotum and reviewed the features of other men with scrotal metastases originating in the colon and rectum.

Case synopsis

A 56-year-old man presented for evaluation of asymptomatic skin lesions on his abdominal scar and scrotum. The lesions had been present for seven months. Some of the lesions had resolved whereas others had appeared during these months.

Two years earlier, the patient underwent a colonoscopy and was diagnosed with stage T3 adenocarcinoma of the colon. He was initially treated with 3 cycles of fluorouracil, leucovorin and oxaliplatin (FOLFOX), and capecitabine-chemoradiation followed by abdominoperineal resection of the tumor. Following surgery, he received three additional cycles of FOLFOX and was evaluated to be cancer free.

One year and five months after the diagnosis of colon adenocarcinoma, he presented with cutaneous nodules on his scrotum and abdomen. They had previously been treated with antifungals without improvement. The skin nodules had been biopsied; microscopic evaluation revealed adenocarcinoma.

He then received 5 cycles of fluorouracil, leucovorin, and irinotecan (FOLFIRI) plus cetuximab. Many of the cutaneous lesions disappeared. However, new nodules also appeared. One month after completion of his antineoplastic treatment, (which was 2 years after his cancer diagnosis) he presented for additional evaluation of his recurrent skin lesions.

Cutaneous examination revealed multiple flesh-colored 1-3mm papules overlaying a midline incision scar in the suprapubic region (Figure 1). His scrotum was edematous and contained many small confluent 3-9mm papules and nodules (Figure 2).

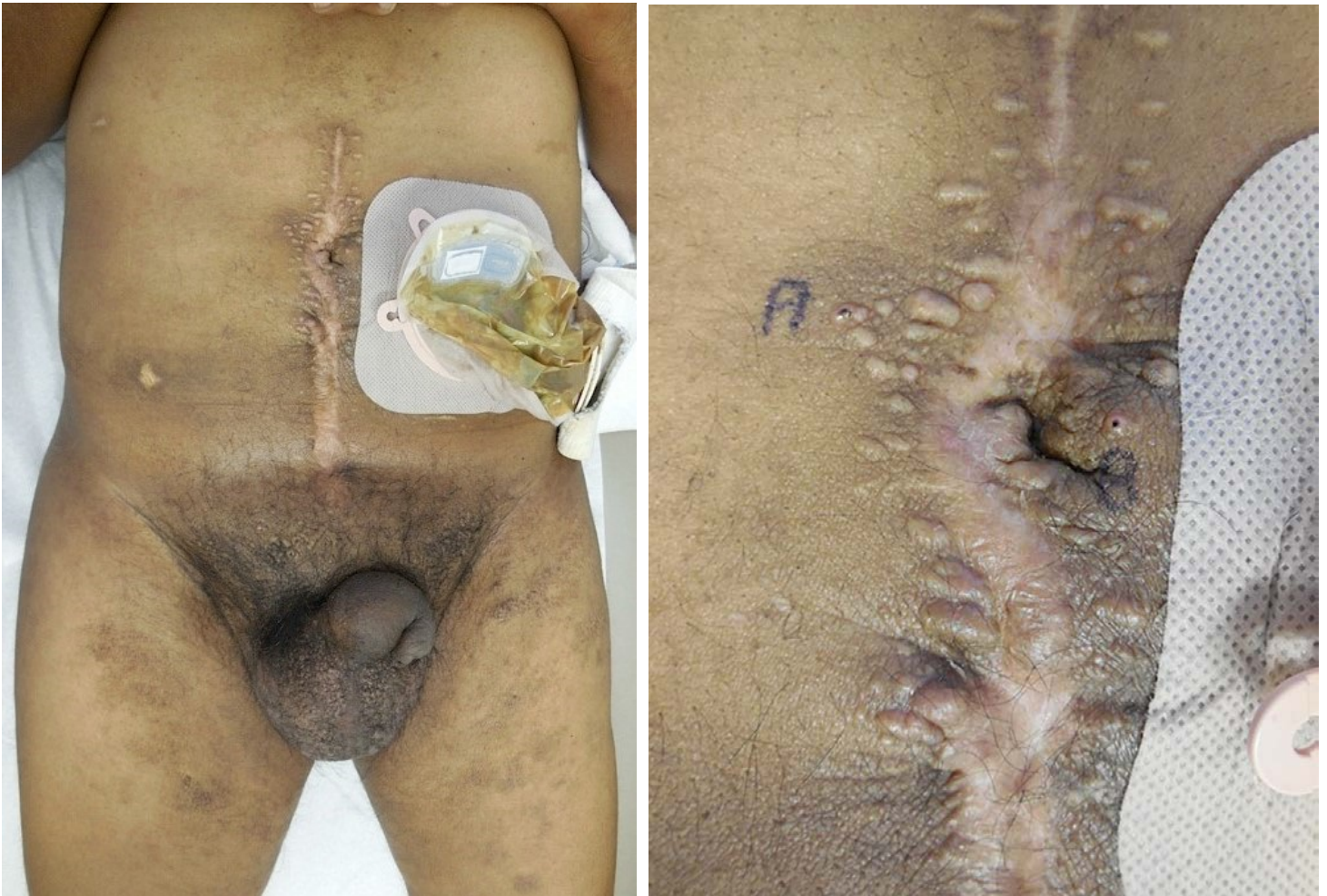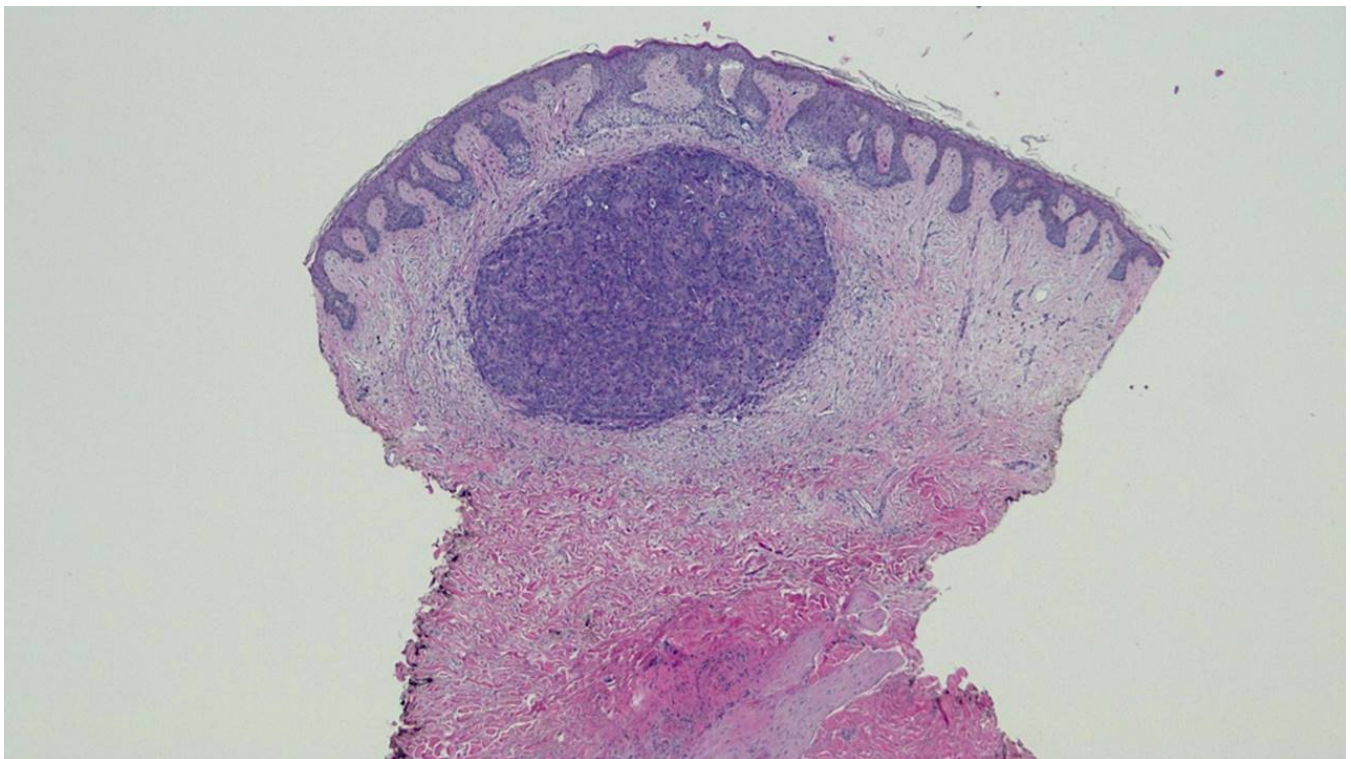


Figure 1 (a and b). Distant (a) and closer (b) views of the abdomen, groin and proximal legs show flesh-colored 1-3mm papules found overlaying the midline incision scar in the suprapubic region. A and B (b) are the biopsy sites that showed adenocarcinoma.

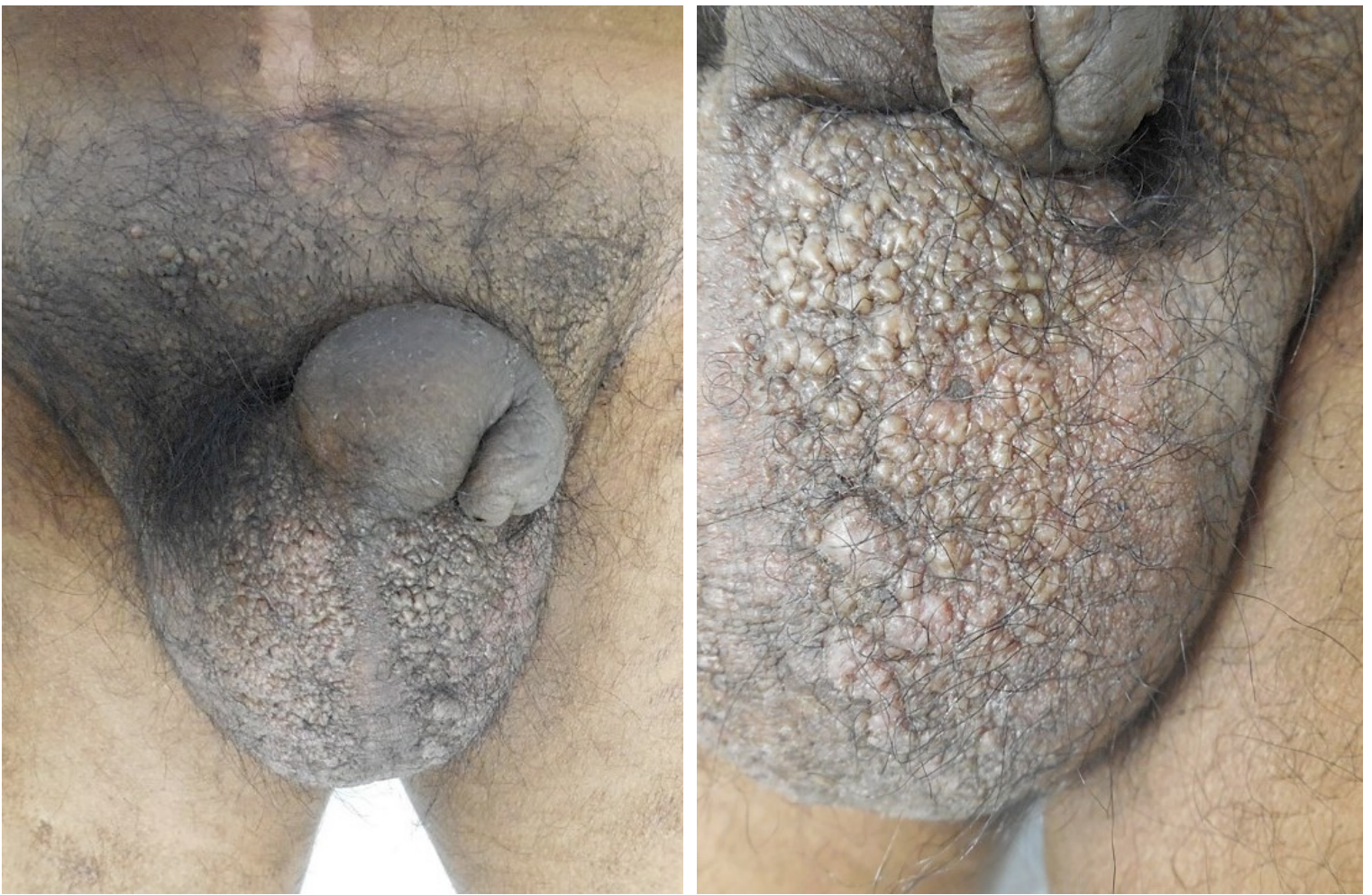

Figure 2 (a and b). Distant (a) and closer (b) views of the patient's edematous scrotum. Many asymptomatic, 3-9mm, individual and confluent papules are present; biopsy confirmed the diagnosis of metastatic adenocarcinoma.

Microscopic examination of the papules from the scar and scrotum showed similar changes. Large anaplastic tumor cells with nuclear pleomorphism and mitosis, as well as focal duct formation was present within the dermis (Figure 3). Correlation of the clinical presentation with the pathologic findings established a diagnosis of metastatic colorectal adenocarcinoma to the suprapubic incisional scar and the scrotum.



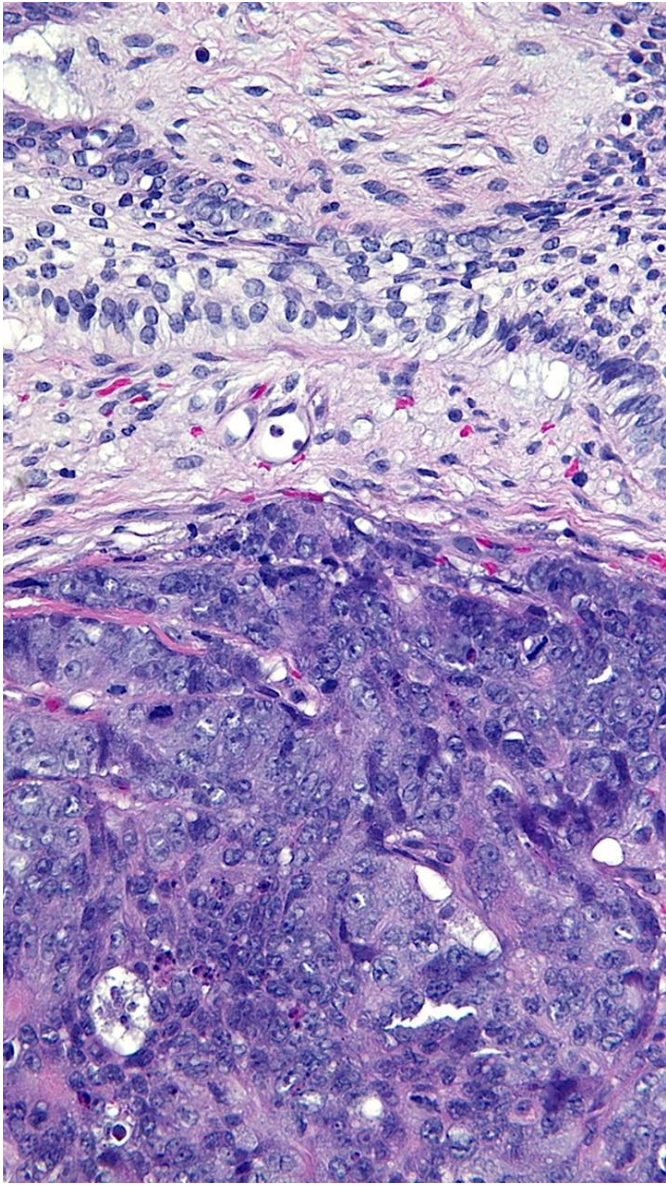
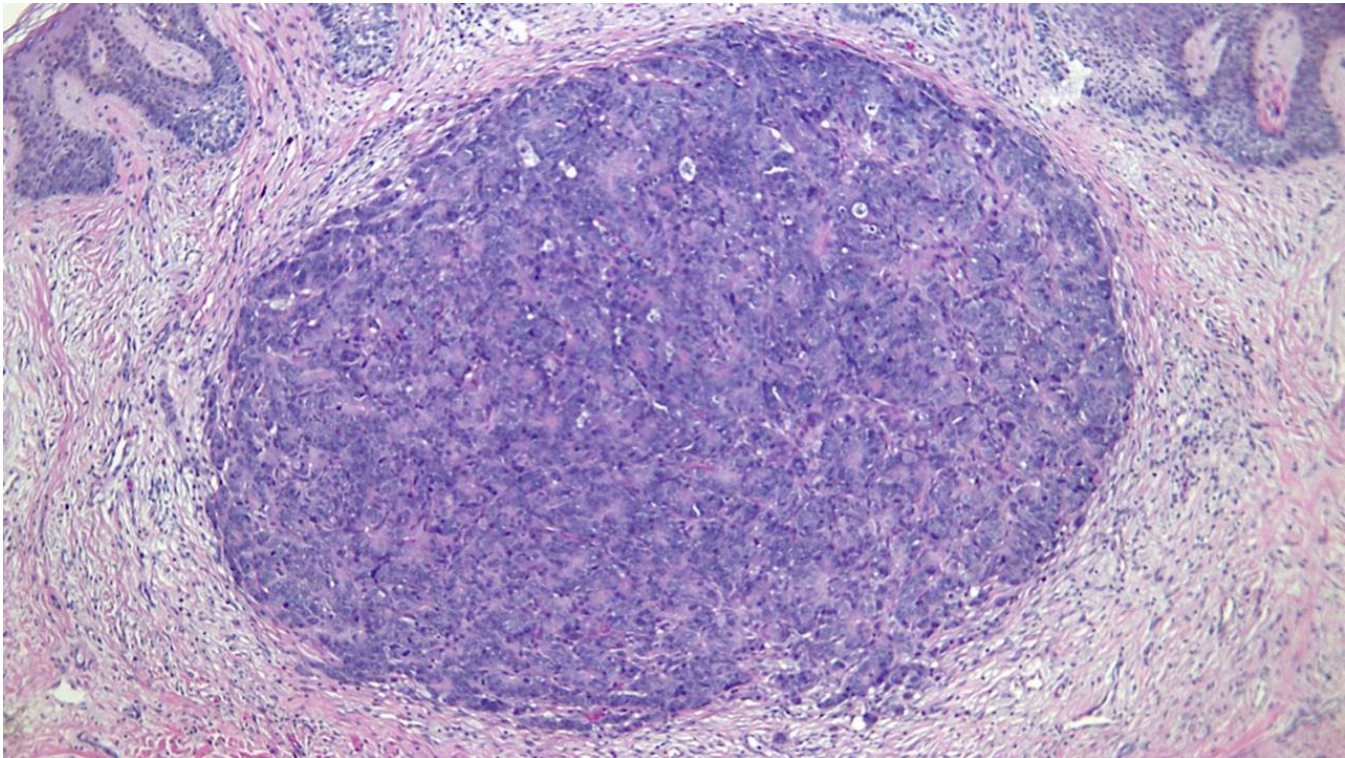


Figure 3 (a,b and c). Low (a), medium (b), and high (c) magnification views of the biopsy specimen from the scrotum in the man with metastatic adenocarcinoma of the rectum. Metastatic tumor is in the dermis presenting as a basophilic nodule. The tumor cells are large and anaplastic; the nuclei are pleomorphic and contain mitosis. There is focal duct formation [hematoxylin and eosin; a= 4x, b= 10x, c= 40x].

The patient was restarted on antineoplastic therapy and he completed 6 cycles of FOLFIRI and cetuximab chemotherapy. His cancer was considered to be stable and some of the skin lesions resolved. However, at follow-up examination – 18 months after the initial discovery of scrotal metastases- there was still clinical evidence of cutaneous metastases.

Discussion

Colorectal cancer is the second leading cause of cancer death in the United States. An estimated 132,700 colorectal cancer cases will be newly diagnosed and 49,700 persons will die of the disease in 2015 [4]. Indeed, although metastases are common in individuals who have advanced colorectal cancer, only 11 percent of oncology patients with carcinoma of their colon or rectum develop cutaneous metastases [3]. Metastases of colorectal cancer to the scrotum is extraordinarily rare.

To the best of our knowledge, only 9 men -including our patient- have been described with colorectal cancer metastases to the scrotum (Table 1) [2,5-12]. The median age of the men at the diagnosis of colorectal cancer was 65 years old (range 30 years to 72 years). Eight men had adenocarcinoma and one had squamous cell carcinoma [10].

Table 1. Scrotal metastases of colorectal cancer origin [a]

Case	Age (years)	Histo	Tumor morphology	Symptoms	Int (mo)	Treatment	Last follow-up	Ref
1	30	Adeno	Ulcerated Pap & Plaques [b]	Pain	24	Fluorouracil and leucovorin	NR	5
2	50	Adeno	Nod	ASX	4	NR	7 -	6
3	56	Adeno	Pap	ASX	24	Fluorouracil based regimens and capecitabine-chemoradiation [c]	18 +	CR
4	60	Adeno	Nod	NR	21	NR	NR	7
5	65	Adeno	Nod	ASX	20	Capecitabine and radiotherapy	12 +	8
6	65	SCC	Nod	Pruritic	5	Multiple	13 -	9,10
7	69	Adeno	Plaques & Nod	ASX	5	NR	6 -	11
8	72	Adeno	Ulcerating lesion	ASX	11	NR	NR	12
9	NR	NR	Nod	NR	PAD	NR	NR	2

[a] Abbreviations: Adeno, adenocarcinoma; ASX, asymptomatic; CR, current report; Histo, histology; Int, interval between initial diagnosis of cancer and appearance of metastasis; mo, months; Nod, nodules; NR, not reported; PAD, present at diagnosis; Pap, papules; Plaques, plaques; Ref, reference; SCC, squamous cell carcinoma; TO, tumor origin; +, alive at follow-up, -, dies after final follow-up.

[b] The lesions were also erythematous and indurated.

[c] The lesions were initially treated with 3 cycles of FOLFOX and capecitabine-chemoradiation followed by 11 cycles of FOLFIRI and cetuximab.

Scrotal metastases from colorectal cancer may present with various morphologies, including papules and nodules, plaques and erythematous, indurated areas. Papules and nodules are the most common skin lesions. Associated findings may include bleeding, edema, and ulceration. The lesions can be asymptomatic or painful. They can be either solitary or multiple [10]. Our patient presented with multiple painless papules.

Colorectal cancer skin metastases most frequently occur in the vicinity of the primary tumor, such as the abdomen. Other sites of involvement include the back, chest, face, genitalia, and scalp. Many lesions are found on or around surgical scars in these areas [3].

The majority of men with colorectal cancer metastases to the scrotum have painless skin lesions. Indeed, 71 percent (5 of 7) of patients had asymptomatic cutaneous metastases. Two patients' colorectal carcinoma skin metastases were symptomatic on presentation: One man's nodule was pruritic, and the other man's lesions were painful.

Scrotal metastases usually present after the diagnoses of the patient's primary malignancy has been established. However, scrotal metastases were the presenting sign of a previously undiagnosed colorectal cancer in one patient [2]. Cutaneous metastases to the scrotum in the other eight occurred at a median of 14 months after the discovery of their primary cancer.

Cutaneous metastases of the scrotum can mimic other skin lesions. These include cysts, lipogranuloma, lymphangioma, nevi, non-melanoma skin cancer, and scabies [13]. Microscopic examination of new skin lesions on the scrotum can readily differentiate these lesions from cutaneous metastases.

Pathologic features of scrotal metastases display findings similar to those observed in the primary cancer. These findings may include anaplastic cells with nuclei that show pleomorphism, hyperchromicity, and increased mitotic activity. In addition, duct formation may be present in patients with adenocarcinoma.

The possible mechanisms for metastatic spread of primary visceral malignancy to skin include hematogenous or lymphatic spread, direct extension, spread along ligaments, and seeding of exfoliated tumor cells [12]. We suspect that either hematogenous or lymphatic spread of colorectal carcinoma to the scrotum is the most likely mechanism of tumor dissemination. Although a recent review of scrotal metastases did not reveal any individuals demonstrating surgery-related incisional spread of the metastases to their scrotum, our patient also developed cutaneous metastases in the scar about his abdomen [10].

The presentation of scrotal metastases is usually a sign of advanced neoplastic disease. The men do not have a good prognosis. Follow-up of the patients with scrotal metastases from colorectal carcinoma includes 5 patients. Survival, following diagnosis of skin metastases ranged from 6 to 18 months with an average of 11 months. Only three men were alive at 12 months of follow-up. Our patient is unique. He has survived 18 months since diagnosis of his cutaneous scrotal metastases. He was initially treated with a fluorouracil based regimen, in addition to capecitabine radiotherapy. His skin metastases partially responded to FOLFIRI and cetuximab resulting in stable metastatic disease. Another patient with colorectal scrotal metastases, a 65-year-old man with squamous cell carcinoma of the anal canal, survived 13 months. He had been treated with a variety of antineoplastic drugs including 5-fluorouracil and cisplatin, as well as concurrent radiation. The third patient who survived for at least a year was a 65-year-old man with adenocarcinoma of the rectum [9,10]. He survived for 12 months. He had been treated with capecitabine radiotherapy [8].

Conclusion

Visceral malignancies with metastases to skin can be a presenting feature of a previously undiagnosed cancer or a sign of persistent or recurrent neoplasm in an oncology patient. The abdomen, back, chest, face, scalp, and genitalia are the most common sites of metastatic tumor spread from primary colorectal carcinoma and the metastases often involve surgical scars. The scrotum is an extraordinarily rare location for cutaneous metastases. Yet, including our patient, 9 men have been described whose primary colorectal cancer metastasized to their scrotum. The lesions occurred at a median of 14 months after the discovery of primary cancer. However, in one man it was the presenting feature of his unsuspected visceral malignancy. The skin lesions have variable morphology, including papules, nodules, and cutaneous induration. The mean survival time, following the diagnosis of cutaneous scrotal metastases, was 11 months. Scrotal metastases from colorectal carcinoma is a poor prognostic sign; however, survival at 12 or more months follow-up was observed for three patients.

References

1. Schwartz RA. Cutaneous metastatic disease. *J Am Acad Dermatol* 1995;33(2 Pt 1):161-182. [PMID: 7622642]
2. Lookingbill DP, Spangler N, Sexton FM. Skin involvement as the presenting sign of internal carcinoma. A retrospective study of 7316 cancer patients. *J Am Acad Dermatol* 1990;22:19-26. [PMID: 2298962]
3. Lookingbill DP, Spangler N, Helm KF. Cutaneous metastases in patients with metastatic carcinoma: a retrospective study of 4020 patients. *J Am Acad Dermatol* 1993;29:228-236. [PMID: 8335743]
4. Siegel RL, Miller KD, Jemal A. Cancer statistics, 2015. *CA Cancer J Clin*. 2015;65:5-29. [PMID: 25559415]
5. Boucher KW, Heymann WR. Ulcerated papules of the scrotum. *Arch Dermatol* 2001;137:495-500. [PMID: 11295934]

6. Hayashi H, Shimizu T, Shimizu H. Scrotal metastases originating from colorectal carcinoma. *Clin Exp Dermatol* 2003;28:226-227. [PMID: 12653722]
7. Shetty MR, Khan F. Carcinoma of the rectum with scrotal metastases. *Br J Urol* 1988;62:612. [PMID: 3219519]
8. Ozgen A, Karakaya E, Bozdoğan N. Scrotal skin metastasis from rectum adenocarcinoma. *Rare Tumors*. 2013;5(4):e60. [PMID: 24416494]
9. Hoyt BS, Cohen PR. Radiation port cutaneous metastases: Reports of two patients whose recurrent visceral cancers presented as skin lesions at the site of previous radiation and literature review. *Indian Journal of Dermatology*. 2014;59(2):176-181. [PMID: 24700938]
10. Hoyt BS, Cohen PR. Cutaneous scrotal metastasis: origins and clinical characteristics of visceral malignancies that metastasize to the scrotum. *Int J Dermatol* 2013;52(4):398-403. [PMID: 23331276]
11. Reuter J, Bruckner-Tuderman L, Braun-Falco M. Epidermotropic scrotal metastasis of colorectal cancer. *Int J Colorectal Dis* 2007;22:1133–1134. [PMID: 16688461]
12. McWeeney DM, Martin ST, Ryan RS, Tobbia IN, Donnellan PP, Barry KM. Scrotal metastases from colorectal carcinoma: a case report. *Cases Journal* 2009;2:111. [PMID: 19183499]
13. Schellhammer PF, Jordan GH, Robey EL, Spaulding JT. Premalignant lesions and nonsquamous malignancy of the penis and carcinoma of the scrotum. *Urol Clin North Am* 1992;19:131-142. [PMID: 1736473]