

UCLA

UCLA Previously Published Works

Title

Phlegmasia cerulea dolens associated with acute coronavirus disease 2019 pneumonia despite supratherapeutic warfarin anticoagulation.

Permalink

<https://escholarship.org/uc/item/1j9909d1>

Journal

Journal of vascular surgery cases and innovative techniques, 6(4)

ISSN

2468-4287

Authors

Chun, Tristen T
Jimenez, Juan Carlos
Pantoja, Joe L
et al.

Publication Date

2020-12-01

DOI

10.1016/j.jvscit.2020.10.002

Peer reviewed

Phlegmasia cerulea dolens associated with acute coronavirus disease 2019 pneumonia despite suprathreshold warfarin anticoagulation

Tristen T. Chun, MD,^a Juan Carlos Jimenez, MD, MBA,^a Joe L. Pantoja, MD,^a John M. Moriarty, MD,^b and Shanna Freeman, NP,^a Los Angeles, Calif

ABSTRACT

Patients with acute coronavirus disease 2019 (COVID-19) respiratory infection are associated with concomitant thromboembolic complications and a hypercoagulable state. Although these mechanisms are not completely understood, unique alterations in the serum markers for hemostasis and thrombosis have been detected. A high index of suspicion is required by vascular surgeons for patients presenting with this novel virus. We present the case of a 51-year-old man with acute COVID-19 pneumonia who developed phlegmasia cerulea dolens despite chronic warfarin therapy and a suprathreshold international normalized ratio. (*J Vasc Surg Cases and Innovative Techniques* 2020;6:653-6.)

Keywords: Coronavirus disease 2019; Deep vein thrombosis; Gangrene; Phlegmasia cerulea dolens; Thrombectomy

CASE REPORT

A 51-year-old man had presented to an outside hospital with a 2-day history of cough, fever, and shortness of breath and was admitted with a diagnosis of acute coronavirus disease 2019 (COVID-19) pneumonia. He progressed to acute hypoxic respiratory failure (80% oxygen saturation with 60% bilevel positive airway pressure) but refused intubation. His medical history included congenital tricuspid atresia and pulmonic stenosis that had been repaired with a Fontan procedure as a child. The patient had been receiving long-term warfarin secondary to recurrent paroxysmal atrial flutter. He had no history of deep vein thrombosis or a hypercoagulable condition. He was also noted to have moderate, constant pain, mostly in the foot but also up to the midshin and thigh, and calf edema, motor weakness, and discoloration in his left lower extremity. All leg and thigh muscle compartments were soft on physical examination (Fig 1). On presentation to an outside hospital, his international normalized ratio (INR) was found to be suprathreshold (7.5), and he received a dose of oral vitamin K and convalescent

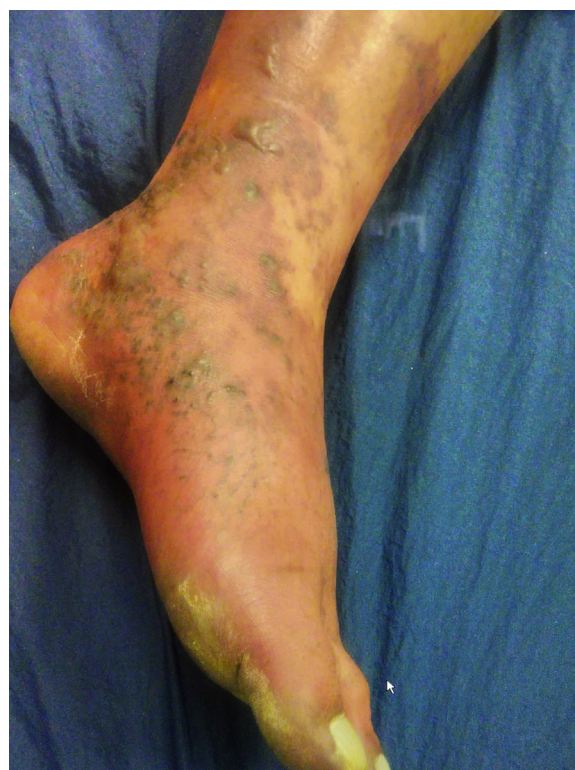

Fig 1. Venous outflow obstruction of the foot due to phlegmasia cerulea dolens before mechanical thrombectomy.

From the Department of Vascular Surgery, Gonda (Goldschmied) Vascular Center,^a and Department of Radiology,^b David Geffen School of Medicine at UCLA.

Author conflict of interest: J.M.M. is a consultant for Inari Medical, which produces the mechanical thrombectomy device used in the present case, although not mentioned by name in our report. T.T.C., J.C.J., J.L.P., and S.F. have no conflicts of interest.

Correspondence: Juan Carlos Jimenez, MD, MBA, Department of Vascular Surgery, Gonda (Goldschmied) Vascular Center, David Geffen School of Medicine at UCLA, 200 Medical Plaza, Ste 526, Los Angeles, CA 90095 (e-mail: jcjimenez@mednet.ucla.edu).

The editors and reviewers of this article have no relevant financial relationships to disclose per the JVS policy that requires reviewers to decline review of any manuscript for which they may have a conflict of interest.

2468-4287

© 2020 The Authors. Published by Elsevier Inc. on behalf of Society for Vascular Surgery. This is an open access article under the CC BY-NC-ND license (<http://creativecommons.org/licenses/by-nc-nd/4.0/>).

<https://doi.org/10.1016/j.jvscit.2020.10.002>

plasma. Before his transfer, his white blood cell count was 10.2 K/ μ L, hemoglobin 14.7 g/dL, platelet count 110 K/ μ L, and a prothrombin time of 26.7 seconds.

He was subsequently transferred to our tertiary care institution 6 days later for a higher level of care. Radiographic evaluation (venous duplex ultrasonography and computed tomography angiography) revealed extensive acute thrombosis of the deep venous system extending from the left popliteal to the left

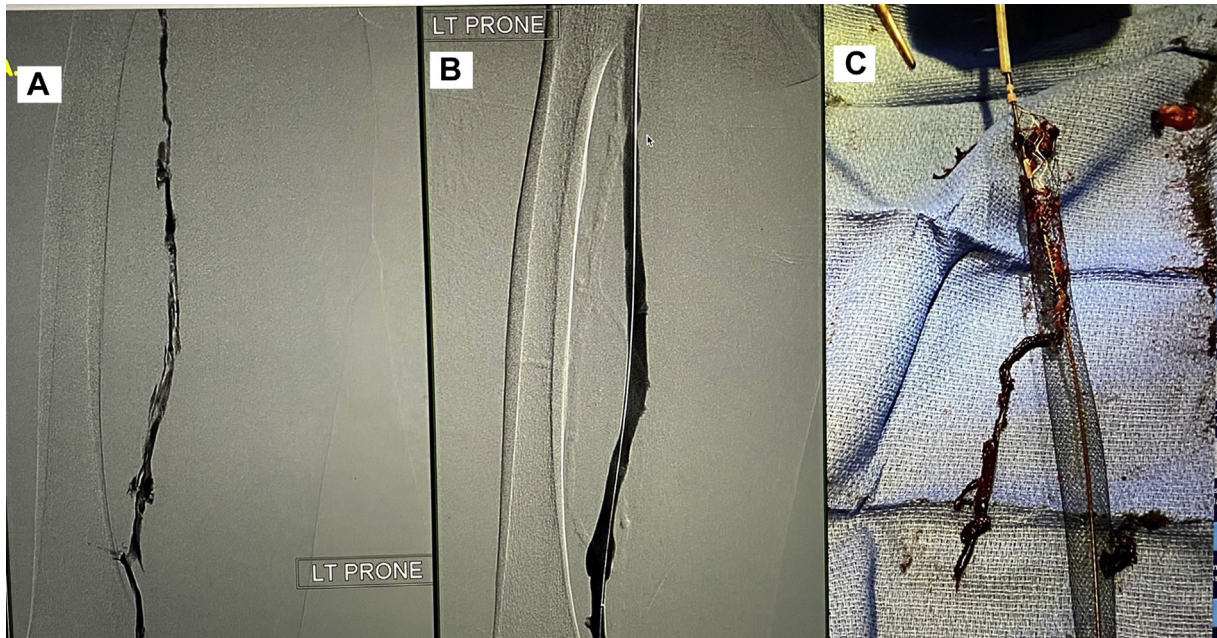


Fig 2. Venographic images of the left lower extremity showing extensive acute thrombosis in the femoral vein (**A**), post-thrombectomy patency of the femoral vein (**B**), and thrombus retrieved using the ClotTriever (**C**).

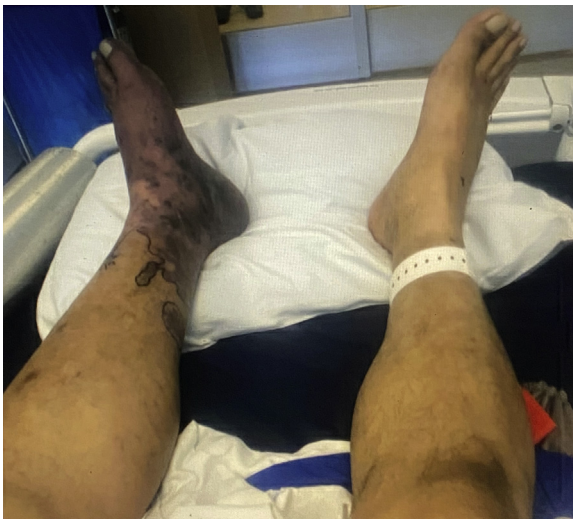

Fig 3. Affected leg compared with the right leg after mechanical thrombectomy.

external iliac vein. His left great and small saphenous veins were also occluded. His right popliteal, femoral, and common femoral veins were also thrombosed; however, his right leg remained asymptomatic. On physical examination, he continued to have audible Doppler signals over the dorsalis pedis artery and posterior tibial artery at the ankle. No evidence of left-sided arterial occlusion was present radiographically. Noninvasive imaging with arterial duplex ultrasonography revealed the presence of biphasic flow in the dorsalis pedis artery and posterior tibial artery in the left lower extremity. Also, an appropriately timed

computed tomography angiogram demonstrated the patency of the distal arterial circulation without irregularity or stenosis. Phlegmasia cerulea dolens (PCD) was diagnosed. The patient's anticoagulation therapy was maintained using a heparin drip protocol with a goal activated partial thromboplastin time of 86 to 110 seconds. On hospital day 1 after admission to our tertiary care center, the patient underwent lower extremity venography, placement of a retrievable filter, and mechanical thrombectomy with successful restoration of patency in the left popliteal, femoral, and iliac veins (Fig 2). The filter was subsequently removed 5 days after placement. The patient continued anticoagulation therapy with therapeutic dosing of enoxaparin sodium (Lovenox; Sanofi-Aventis, Paris, France). His D-dimer level had peaked at 21,450 ng/mL just before his transfer to our tertiary care center (5 days after his initial presentation). Additional hypercoagulable studies obtained on hospital day 1 after admission to our tertiary care center revealed detectable cardiolipin IgM antibodies (28.9 antiphospholipid antibodies), and his dilute Russel viper venom time was positive. The cardiolipin IgG and IgA and factor V and VIII levels were normal. After thrombectomy and restoration of deep venous flow, his thigh and upper calf swelling improved. However, his foot swelling and discoloration worsened despite continued anticoagulation therapy. The patient's foot was deemed clinically unsalvageable, and he eventually underwent a left below-the-knee amputation on hospital day 39. No evidence of myonecrosis was noted in his lower leg compartment musculature during the operation, and a long posterior flap closure was possible. He was discharged to home 9 days later, with warfarin therapy resumed with an INR goal of 2 to 3.

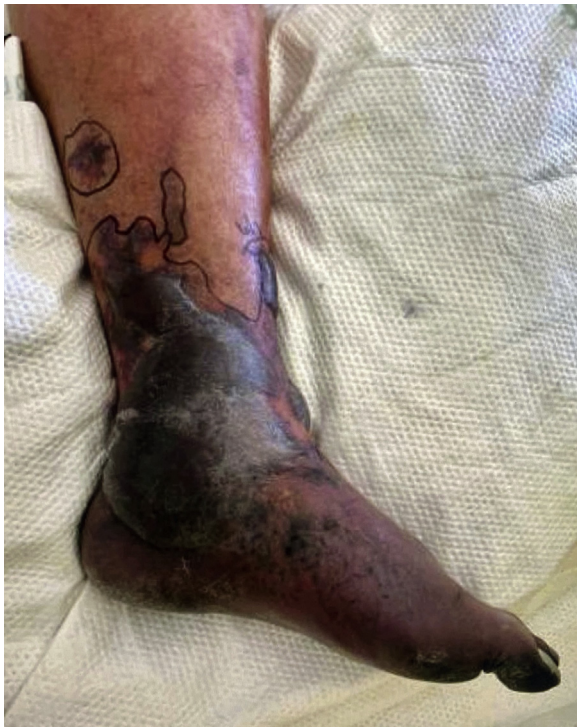

Fig 4. Progression to dry gangrene of the left foot despite restoration of deep venous patency.

The patient provided written signed consent for the report of the details and images from his case.

DISCUSSION

First described in the 16th century, PCD is a life- and limb-threatening condition characterized by irreversible tissue ischemia. Its etiology is extensive central and peripheral deep vein thrombosis with resultant severe venous outflow obstruction. Early signs include pain and edema, which can progress to cyanosis, bullae, sensory and motor impairment, and gangrene (Figs 3 and 4). Arterial occlusion and compartment syndrome might or might not be present.¹ Concomitant hypercoagulable conditions are frequently present and can include malignancy, inferior vena cava filters, and inherited thrombophilic conditions.² Immediate anticoagulation and rapid restoration of venous outflow in the affected extremity will usually be required for limb salvage.

Hypercoagulability and the potential for thromboembolic complications are clinical features of COVID-19 infection.³ Despite restoration of deep venous patency with percutaneous mechanical thrombectomy after PCD, our patient progressed to extensive dry gangrene of his left foot, which required below-the-knee amputation. Venous thromboembolic disease and significant coagulation impairments have been associated with $\leq 20\%$ of patients diagnosed with the novel COVID-19.⁴ Although the precise associated mechanisms are still unknown, COVID-19-related thromboembolic

complications have been associated with prothrombin time and activated partial thromboplastin time prolongation, an increase in fibrin degradation products, severe thrombocytopenia, and disseminated intravascular coagulation.⁵ Our patient was receiving lifelong therapeutic anticoagulation with stable INR levels of 2 to 3 at the time of his acute COVID-19 upper respiratory infection and PCD. Serum antiphospholipid antibodies have been associated with COVID-19 patients with thromboembolic complications.^{6,7} In our patient, the combination of cardiolipin IgM antibody detection in the serum and a positive dilute Russel viper venom time suggested antiphospholipid syndrome as the cause of his hypercoagulopathy associated with his acute COVID-19 infection.

Because our patient presented with PCD associated with COVID-19 infection despite chronic warfarin therapy and a supratherapeutic INR, the conventional anticoagulant algorithms for treatment might not be protective against venous thromboembolism. Because D-dimer elevation has been found to predict for the risk of venous thromboembolism, a more aggressive treatment paradigm for anticoagulation using higher doses of heparin with the D-dimer level as guidance might be required.⁸ A high index of suspicion for acute thromboembolic events should be maintained by vascular surgeons and interventionalists for patients presenting with COVID-19 respiratory infection. Although anticoagulation or enhanced levels of anticoagulation will often be adequate for treatment, aggressive endovascular intervention could sometimes be necessary for limb salvage. However, the decision to proceed with an urgent intervention should be weighed against the potential for postoperative cardiopulmonary complications and death in patients with active COVID-19 respiratory illness.⁹ In the present case, mechanical thrombectomy and restoration of venous patency likely allowed for successful below-the-knee amputation, instead of above-the-knee amputation owing to the decrease in calf muscle edema. In some cases, four-compartment fasciotomies could be indicated after recanalization of the deep veins. Clinical evidence of muscle perfusion and viability demonstrated that lower leg compartment syndrome did not likely occur in our present patient.

CONCLUSION

We have presented this case to highlight the unique challenge of treating patients with lower extremity PCD from hypercoagulopathy associated with acute COVID-19 infection.

REFERENCES

1. Lai HT, Huang SH. Phlegmasia cerulea dolens with compartment syndrome. *N Engl J Med* 2018;15:658.
2. Chinsakchai K, Ten Duis K, Moll FL, deBorst GJ. Trends in management of phlegmasia cerulea dolens. *Vasc Endovasc Surg* 2011;45:5-14.

3. Levi M, Thachil J, Iba T, Levy JH. Coagulation abnormalities and thrombosis in patients with COVID-19. *Lancet Hematol* 2020;7:e438-40.
4. Zhai Z, Chenghong L, Yaolong C, Gerotziafas G, Zhang Z, Wan J, et al. Prevention and treatment of venous thromboembolism associated with coronavirus disease 2019 infection: a consensus statement before guidelines. *Thromb Haemost* 2020;120:937-48.
5. Terpos E, Ntanasis-Stathopoulos I, Elalamy I, Kastritis E, Sergentanis TN, Politou M, et al. Hematological findings and complications of COVID-19. *Am J Hematol* 2020;95: 834-47.
6. Connell NT, Battinelli EM, Connors JM. Coagulopathy of COVID-19 and antiphospholipid antibodies. *J Thromb Haemost* 2020 May 7. [E-pub ahead of print].
7. Zhang Y, Xiao M, Zhang S, Xia P, Cao W, Jiang W, et al. Coagulopathy and antiphospholipid antibodies in patients with COVID-19. *N Engl J Med* 2020;23:e38.
8. Artifoni M, Danic G, Gautier G, Gicquel P, Boutoille D, Raffi F, et al. Systematic assessment of venous thromboembolism in COVID-19 patients receiving thromboprophylaxis: incidence and role of D-dimer as predictive factors. *Thromb Thrombolysis* 2020;50:211-6.
9. Aminian A, Safari S, Razeghian-Jahromi A, Ghorbani M, Delaney CP. COVID-19 outbreak and surgical practice: unexpected fatality in perioperative period. *Ann Surg* 2020;272: e27-9.

Submitted Jul 26, 2020; accepted Oct 1, 2020.