

UCLA

UCLA Previously Published Works

Title

Intravascular ultrasound imaging of human coronary arteries in vivo. Analysis of tissue characterizations with comparison to in vitro histological specimens.

Permalink

<https://escholarship.org/uc/item/1h99n0q0>

Journal

Circulation, 83(3)

ISSN

0009-7322

Authors

Tobis, JM
Mallery, J
Mahon, D
et al.

Publication Date

1991-03-01

DOI

10.1161/01.cir.83.3.913

Copyright Information

This work is made available under the terms of a Creative Commons Attribution License, available at <https://creativecommons.org/licenses/by/4.0/>

Peer reviewed

Intravascular Ultrasound Imaging of Human Coronary Arteries In Vivo

Analysis of Tissue Characterizations With Comparison to In Vitro Histological Specimens

Jonathan M. Tobis, MD, FACC; John Mallery, MD; Don Mahon, MD;
Kenneth Lehmann, MD; Paul Zalesky, PhD; James Griffith, PhD; James Gessert, BS;
Masahito Moriuchi, MD; Michael McRae, MD; Mary-Lynn Dwyer, RN;
Nancy Greep, MD; and Walter L. Henry, MD

Background. Intravascular ultrasound imaging was performed in 27 patients after coronary balloon angioplasty to quantify the lumen and atheroma cross-sectional areas.

Methods and Results. A 20-MHz ultrasound catheter was inserted through a 1.6-mm plastic introducer sheath across the dilated area to obtain real-time images at 30 times/sec. The ultrasound images distinguished the lumen from atheroma, calcification, and the muscular media. The presence of dissection between the media and the atheroma was well visualized. These observations of tissue characterization were compared with an in vitro study of 20 human atherosclerotic artery segments that correlated the ultrasound images to histological preparations. The results indicate that high-quality intravascular ultrasound images under controlled in vitro conditions can provide accurate microanatomic information about the histological characteristics of atherosclerotic plaques. Similar quality cross-sectional ultrasound images were also obtained in human coronary arteries in vivo. Quantitative analysis of the ultrasound images from the clinical studies revealed that the mean cross-sectional lumen area after balloon angioplasty was $5.0 \pm 2.0 \text{ mm}^2$. The mean residual atheroma area at the level of the prior dilatation was $8.7 \pm 3.4 \text{ mm}^2$, which corresponded to 63% of the available arterial cross-sectional area. At the segments of the coronary artery that appeared angiographically normal, the ultrasound images demonstrated the presence of atheroma involving $4.7 \pm 3.2 \text{ mm}^2$, which was a mean of $35 \pm 23\%$ of the available area bounded by the media.

Conclusions. Intravascular ultrasound appears to be more sensitive than angiography for demonstrating the presence and extent of atherosclerosis and arterial calcification. Intracoronary imaging after balloon angioplasty reveals that a significant amount of atheroma is still present, which may partly explain why the incidence of restenosis is high after percutaneous transluminal coronary angioplasty. (*Circulation* 1991;83:913-926)

Atherosclerosis produces a complex histological pattern composed of fibrotic thickening, thrombosis, calcification, and necrosis of the arterial wall. No presently available diagnostic method allows this process to be completely characterized in human coronary arteries in vivo. Contrast

coronary angiography provides an image of lumen contour, but it gives no information about either the volume or composition of the atheroma present.¹ A mild degree of lumen narrowing on angiography may, in reality, represent a large atheroma volume.² Chest fluoroscopy provides a crude estimate of the degree of calcification present in an artery, but it is difficult to quantify, and the specific location of the calcification within the artery wall cannot be discerned. If a method were developed that could predict the histological tissue characteristics of a specific atheroma, characterizing atherosclerotic plaques in vivo according to their contents may then be possible. This would facilitate the study of the nature of how

From the Division of Cardiology/Department of Pathology (M.M.), University of California, Irvine; Veterans Administration Hospital (J.M.T., J.M., D.M., K.L., M.M., M-L.D., N.G., W.L.H.), Long Beach; and InterTherapy Inc. (P.Z., J.G., J.G.), Costa Mesa, Calif.

Address for reprints: Jonathan M. Tobis, MD, FACC; Division of Cardiology, University of California, Irvine Medical Center, P.O. Box 14091, Route 81, Orange, CA 92613-4091.

Received December 27, 1989; revision accepted November 6, 1990.

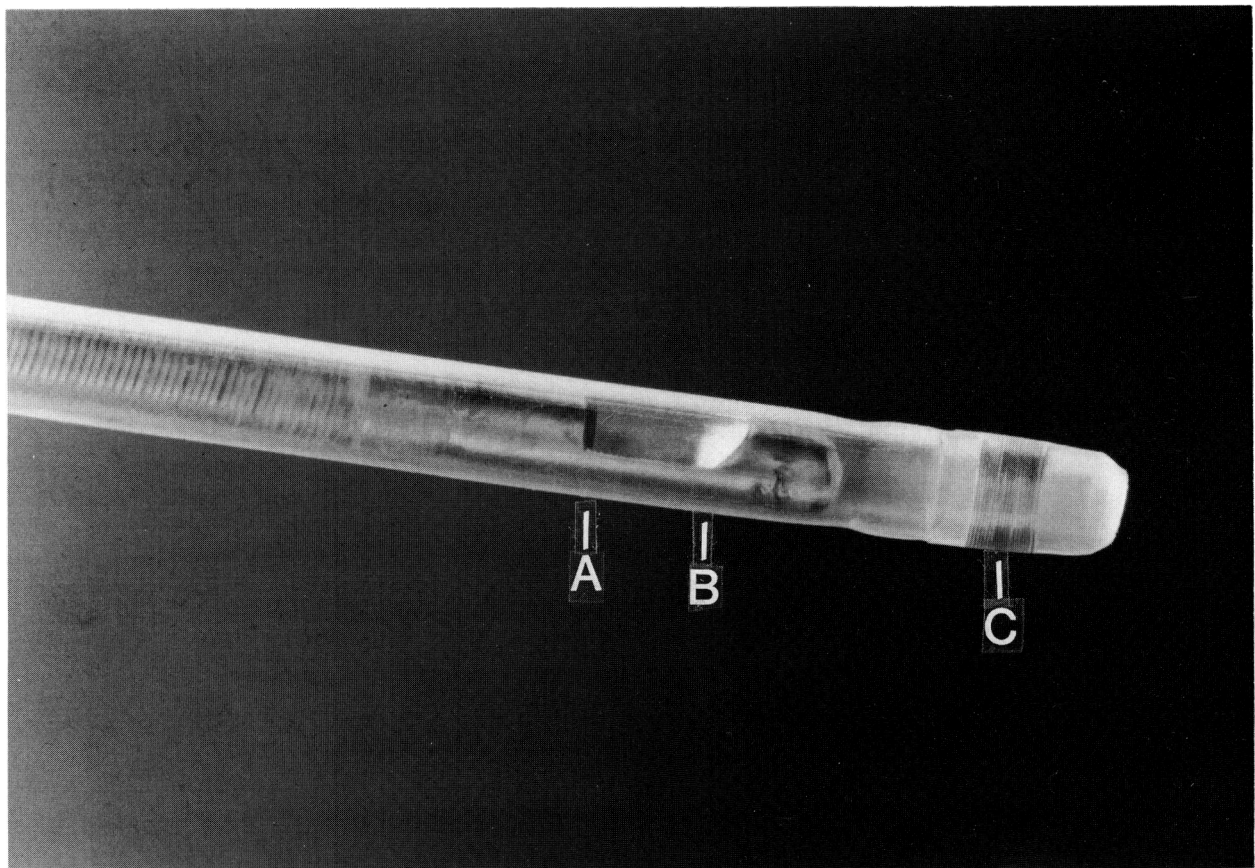


FIGURE 1. Intravascular ultrasound imaging subassembly inserted inside the 1.6-mm diameter plastic sheath. The 7-mm rigid end of the ultrasound subassembly includes the 20-MHz ultrasound transducer (A) and the reflective mirror (B) that deflects the ultrasound beam perpendicular to the long axis of the catheter. Distal end of the plastic sheath has a radiopaque marker (C).

plaques change over time and would possibly provide information useful for interventional procedures.

Ultrasound imaging offers the potential for evaluating arterial wall thickness.^{3,4} Carotid arteries have been extensively studied with external real-time B mode ultrasound imaging.⁵ A relatively high degree of accuracy in measurement of lumen dimension compared with angiography and reasonable reproducibility in the measurement of the extent of atherosclerosis in the artery wall has been established.⁶ In addition, coronary artery images have been obtained with conventional 12-MHz external ultrasound imaging devices in vitro or at the time of open heart surgery on exposed epicardial coronary arteries.⁷ Such external ultrasound devices have obvious limitations for evaluating human coronary arteries in vivo. An intravascular ultrasound transducer placed on the end of a catheter has been used in vitro and in vivo in animals and humans to image coronary and peripheral arteries.⁸⁻¹¹ This approach allows the arterial wall to be imaged from inside the artery, opening the possibility of imaging human coronary arteries in the catheterization laboratory as a routine complement to diagnostic angiography as well as before, during, and after balloon angioplasty, laser, or atherectomy intervention.

The purpose of this study was to identify human arterial atherosclerotic plaque constituents using a miniature intravascular ultrasound imaging catheter. A clinical series of intracoronary ultrasound imaging was performed in 27 patients after balloon angioplasty to determine the morphological appearance of atherosclerosis by ultrasound in living patients. In addition, an in vitro study was performed to correlate the images obtained by intravascular ultrasound with the vessel anatomy as determined by histological cross-section. The questions that were asked in the in vitro study were: How accurately does high-frequency intravascular ultrasound imaging determine the presence of normal arterial wall layers, the presence of calcification within plaques, the presence of fibrotic noncalcified plaques, and the identification of necrotic echolucent spaces within plaques?

Methods

In Vivo Clinical Study

Twenty-seven patients who were undergoing coronary angioplasty for symptomatic angina were asked to participate, and they signed the Human Subjects Review Committee Consent Form. Coronary angioplasty was performed in a standard manner from the

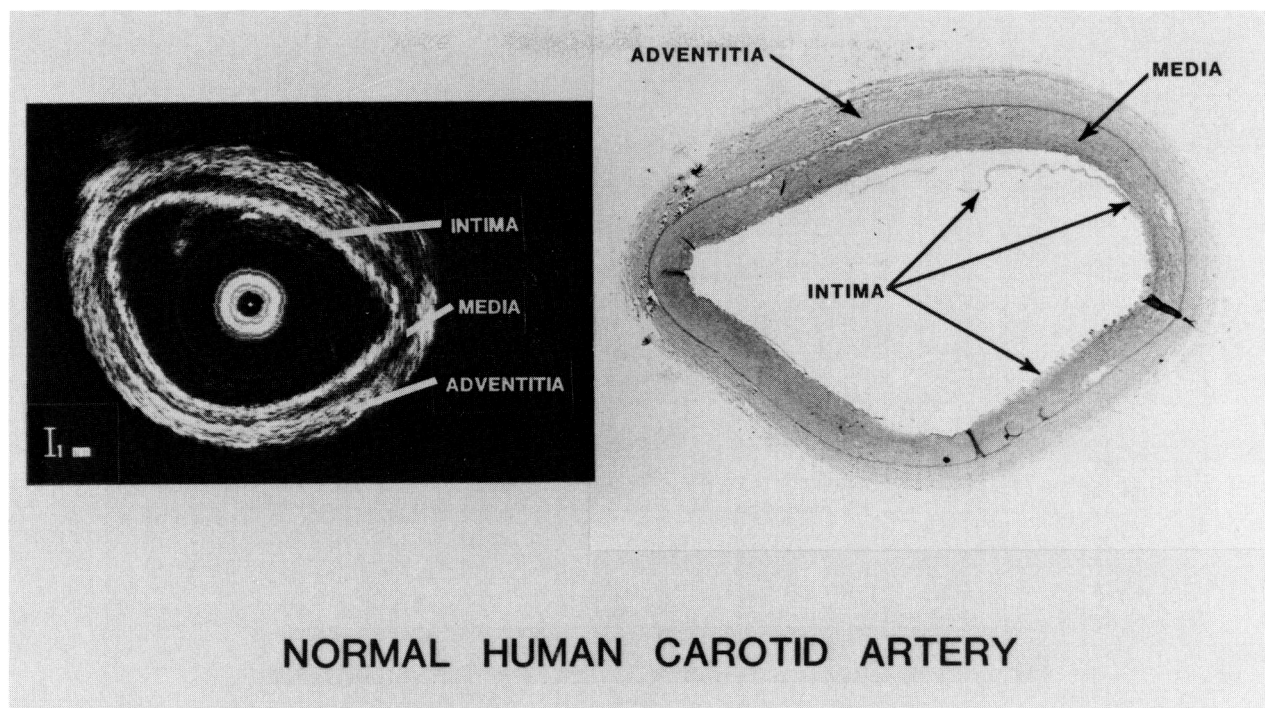


FIGURE 2. Intravascular ultrasound image and histological section of a normal human carotid artery. Characteristic three-layer appearance on the intravascular ultrasound image is seen. Muscular medial layer of the artery was relatively echolucent and provided a reference point in the arterial cross-section separating intima from adventitia. Intima extended from the lumen-tissue interface to the echolucent media. Adventitia consists of all echoes originating peripherally to the media.

femoral artery approach. The ultrasound device consists of a 1.2-mm diameter cable with a 20-MHz transducer on the distal end with a mirror at 45° that reflects the beam perpendicular to the long axis of the catheter. This design permitted imaging up to the surface of the catheter because the initial transducer oscillations (which produce ring-down artifact with loss of image information) occurred in the space between the transducer and the mirror. The catheter is rotated by a motor at 1,800 rpm to produce real-time cross-sectional images at 30 times/sec. To protect the arterial lumen during the movement of the catheter, the ultrasound subassembly is inserted through a 1.6-mm plastic introducing sheath (Figure 1). After balloon angioplasty, the guiding catheter was replaced with a 9F guiding catheter to accommodate passage of the inflexible, 7-mm long, distal section of the ultrasound device. The previously dilated section of the artery was recrossed with a 0.014-in. guide wire, over which the plastic introducer sheath was positioned distal to the dilated segment. The guide wire was removed, and the ultrasound subassembly cable was inserted under fluoroscopic control to the distal end of the introducing sheath. The motor drive unit was then engaged, and continuous images of the coronary artery were obtained as the ultrasound subassembly was withdrawn through the plastic sheath (which remained stationary in the artery beyond the area of dilatation). Ultrasound images were recorded on super VHS videotape as were fluoroscopic sequences to

document the position of the ultrasound transducer within the artery. The fluoroscopic position of the ultrasound catheter was used to correlate the angiographic appearance of the lumen and the cross-sectional ultrasound images obtained at the same position. A continuous flush of warmed normal saline was used to dislodge any bubbles from adhering to the imaging components. This also prevented any blood from coming into prolonged contact with the space between the transducer and the mirror that could lead to thrombus formation and image degradation. Intermittent saline flushes were also performed by hand injection with a 3-ml syringe into a three-way stopcock inserted into the flush line to help dislodge air bubbles from adhering to the transducer. After the ultrasound images were obtained, the ultrasound subassembly and introducer sheath were removed, and a follow-up angiogram was obtained to determine continued patency of the vessel.

Quantitative Analysis

After the angioplasty and ultrasound imaging procedures were performed, arterial lumen diameters from the coronary angiograms were measured with digital calipers from the digitally acquired studies. Measurements were made at the level of the balloon dilatation and at apparently uninvolved areas (by visual assessment of the angiogram) proximal or distal to the dilatation.

The ultrasound images were recalled from computer memory, and appropriate images were chosen

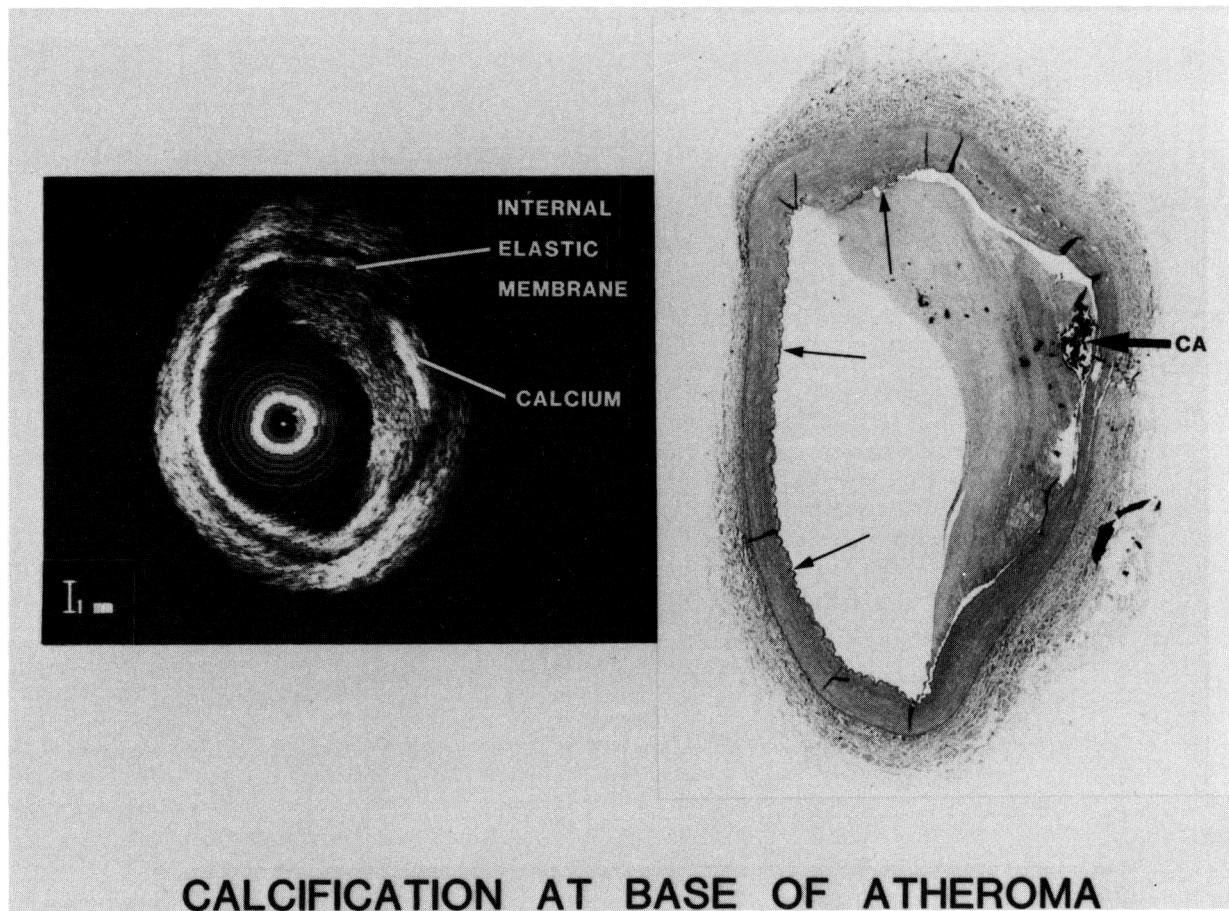


FIGURE 3. *Ultrasound image and histological section of a diseased human carotid artery. Eccentric intimal plaque contains a small region of calcification at its base that causes shadowing or dropout of echo information. Echolucent media is seen circumferentially. Corresponding histological section demonstrates the small area of dense calcium (thick arrow). Thin internal elastic membrane (thin arrows) generates a highly echogenic signal that overestimates the true thickness of this echo-reflective structure.*

that corresponded to the areas of interest on the angiogram. The position of the ultrasound catheter was recorded during fluoroscopy on the videotape so that the ultrasound images could be matched with the corresponding arterial segment using thoracic landmarks and the guiding catheter position on fluoroscopy. The major and minor axes of the lumen were measured, and the perimeter of the lumen and the atheroma cross-sectional area were outlined. The outer boundary of the atheroma was outlined at the interface between the echo densities of the central plaque and the echolucency of the media. Statistical comparison was performed by a linear regression analysis between the measurements from angiography and those from ultrasound imaging.

In Vitro Study

The *in vitro* study used an imaging catheter with a single 20-MHz ultrasound transducer similar to the design of the catheter used *in vivo*, except that the *in vitro* study was performed with a hand-rotated device.¹² The catheter, 1.2 mm in diameter, was devel-

oped by Intertherapy Inc., Costa Mesa, Calif. To construct an image, the catheter was hand rotated through 360° inside an artery. During rotation, the B-mode ultrasound representation was painted as a circle on the video screen using position information provided by an angular potentiometer attached to the proximal end of the catheter. The resulting image provided a cross-section of the lumen and artery wall.

For the *in vitro* study, the catheter was mounted in a precision positioning device that was used during imaging to control the height, angle, and rotation of the catheter. The mounting device prevented distortion from nonuniform rotational speeds. Human artery segments were positioned vertically in a beaker filled with saline. With the positioning device, the catheter was advanced along the course of the artery. At each 1-mm increment, the catheter was rotated 360° to construct a separate cross-sectional image on a video monitor. An oscilloscope displayed the sound intensity as a function of distance, assuming the velocity of sound is 1,540 m/sec in biological tissue.

Twenty refrigerated human arterial segments were obtained from coronary, carotid, iliac, and femoral

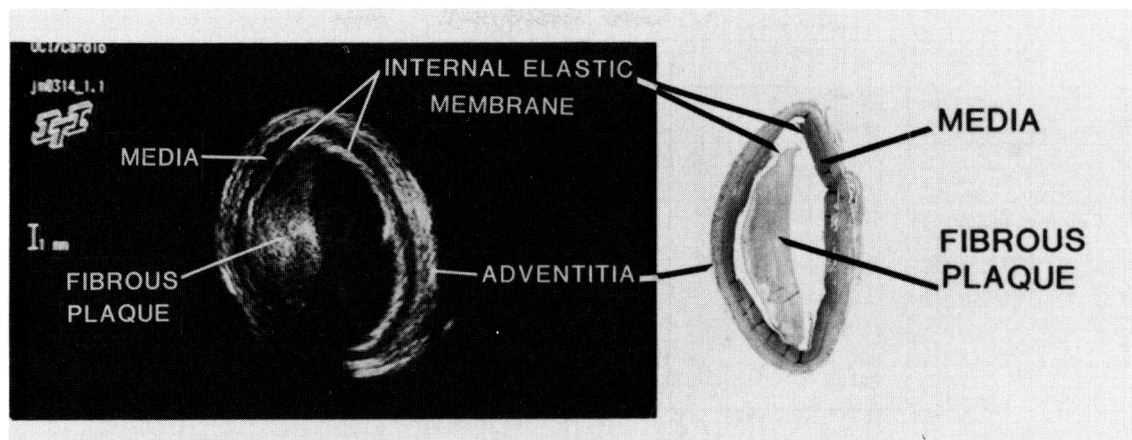


FIGURE 4. Ultrasound image and histological section of a human carotid artery shows fibrous intimal thickening but no calcification. Fibrous plaque is a good echo reflector but is not as brightly reflective as calcification, and no shadowing is observed. Companion histological section shows the eccentric fibrous plaque but no calcification. Intimal plaque has been separated artificially during histological preparation from the media, and lumen shape is distorted. Internal elastic membrane is represented by a thicker echo-reflective line that extends behind the atheroma.

arteries and were imaged at room temperature in a saline bath. Only arteries preserved by refrigeration in saline were used in this study because we have observed changes in ultrasound reflectivity in formalin-preserved specimens. Observations were made of intimal, medial, and total arterial wall thickness from the ultrasound images and distinctions in echo-reflectivity were correlated with the corresponding arterial segment observed on hematoxylin and eosin or trichrome-stained histological sections. The media was identified as a circumferential, uniform echolucent zone 0.3–1.0 mm thick. Tissue echoes arising central to the media were defined as intima; those arising peripheral to the media were defined as adventitia. The histological sections were used to determine the true type of tissue represented by the echo characteristics seen in the ultrasound images.

Arterial specimens were imaged in 1-mm increments with the ultrasound device; histological sections were likewise made in 1-mm increments from the specimen. Thus, a given ultrasound image corresponded within 0.5 mm to the histological section. In addition, internal markers, such as pieces of calcium, and an external marker with a surgical needle were used to confirm that ultrasound images and histological sections were aligned.

Twenty-three images from the 20 different arteries were selected because of their high quality and were paired with their corresponding histological slides. The ultrasound images were reviewed to determine 1) whether the artery was normal or abnormal (i.e., contains atheroma), 2) whether calcification was present, 3) whether the circumference of the muscular media was seen well enough to distinguish the atheroma thickness, and 4) whether regions of echolucent lipid or liquid material were present within the intimal plaque. The criterion used to identify calcification was very intense echo reflections of ultrasound with shadowing of the distal wall. Fibrotic, noncalcified plaques

were identified as intimal thickening of at least 0.25 mm without echo shadowing. Regions of lipid or necrotic liquid were identified as large echolucent areas (“lakes”) within the plaque and were distinguished from calcium-induced echo dropout because the echolucent lipid area was surrounded centrally and peripherally by tissue reflections.

Results

In Vitro Study

Twenty of the 23 arterial images evaluated in this study had intimal thickening according to histological examination; three did not (Figure 2). Eleven (55%) of the artery sections were calcified on the histological sections, and all were correctly categorized by ultrasound (Figure 3). One noncalcified artery was incorrectly categorized because the ultrasound image of a highly fibrotic plaque resembled calcification with shadowing in the ultrasound image. All 20 arteries with atheroma demonstrated some degree of fibrosis on histology that corresponded to moderate echo intense reflections medial to the internal elastic membrane (Figure 4). Three liquid regions (“lakes”) in this series of ultrasound images were correctly identified by all observers, and there were no false-positive images (Figure 5).

The ability of an observer to identify the echolucent media was also evaluated. Fourteen of the 23 (61%) images contained identifiable lucent media in all four quadrants that would permit measurement of intimal plaque thickness. This capability to identify the echolucent media is important because it allows measurement of the circumferential intimal plaque thickness separately from total wall thickness, thus permitting determination of atherosclerotic plaque cross-sectional area. In addition, in 70% of the segments in which the media was not visualized on ultrasound, histology revealed destruction of the

NECROTIC LIQUID IN PLAQUE

HUMAN ILIAC ARTERY

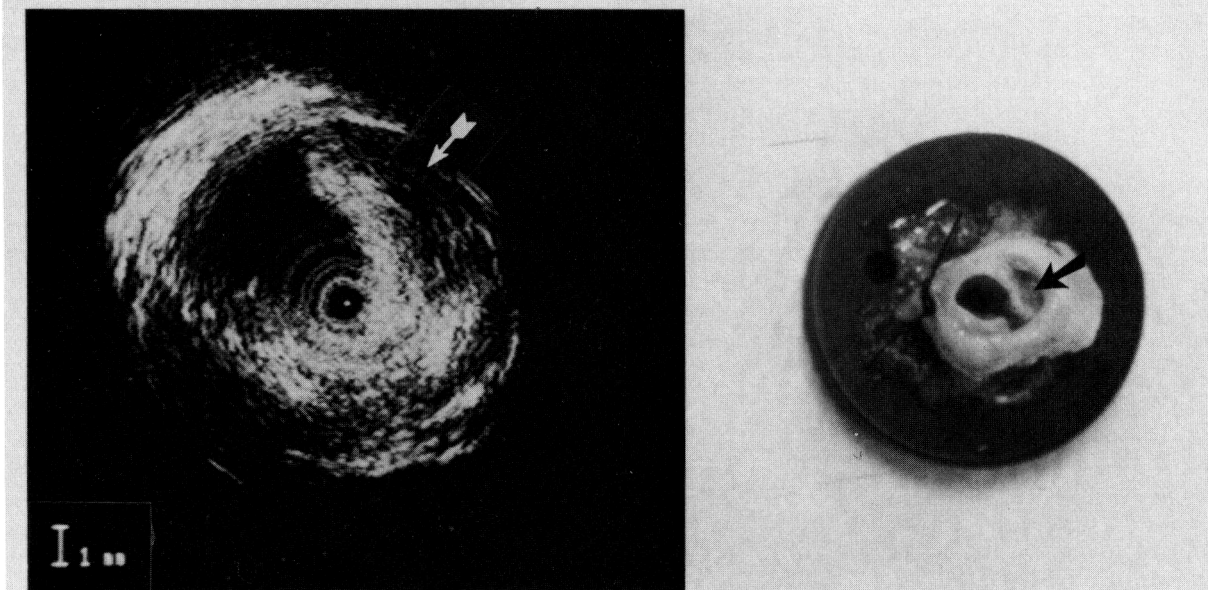


FIGURE 5. *Ultrasound image and gross specimen from a severely diseased human iliac artery illustrates a large echolucent region ("lake") that contained liquid necrotic material on gross examination (arrow). Corresponding gross specimen section shows a large space to the right of the lumen (arrow) that contained liquid necrotic material.*

media by the atherosclerotic process. The quantitative analysis of arterial wall thickness compared with histology from a different series of arterial sections has been reported separately.¹³

In Vivo Clinical Study

Intracoronary ultrasound images were obtained in 22 of the 27 patients after balloon angioplasty. Ultrasound images were not obtained in five patients because of technical difficulty in placing the introducer sheath into the coronary artery. In three patients, the sheath or transducer did not pass through the bends in the guiding catheter. There was a "learning curve" phenomenon in the use of the ultrasound sheath and imaging subassembly. In the last 19 patients, there has been no difficulty in placing the sheath and transducer into the coronary artery. In two patients, the sheath was pulled back proximal to the dilated site because the patient developed ischemia, but the proximal artery was imaged. In the 22 patients studied, nine right coronary arteries, five circumflex, seven left anterior descending (LAD) coronary arteries, and one saphenous vein bypass graft were interrogated by the intravascular ultrasound imaging catheter. The ultrasound images that were obtained in vivo in human coronary arteries had

a general appearance similar to the images obtained during the in vitro studies.

A representative intravascular ultrasound cross-sectional image from the midportion of the LAD is shown in Figure 6. The central black area represents the ultrasound catheter. Surrounding the black circle is a white band that corresponds to the echo reflection from the 1.6-mm plastic sheath. Around the plastic sheath is the lumen of the artery represented by a dark echolucent area with occasional small echogenic reverberations. The atheroma is exposed as a mildly eccentric plaque around the entire circumference of the artery with more intense echo reflections between 9 and 12 o'clock and at 5 o'clock. Based on the prior observations from the in vitro histological studies, these intense echo reflections probably represent calcification within a fibrous matrix. The dropout of echoes behind the echo-dense material at 5 and 12 o'clock is typical of calcification. Surrounding the echogenic atheroma is a black band of echolucent area (approximately 0.2 mm in width) that corresponds to the media. Despite the dropout of some echos behind the small area of calcium, the boundary of the atheroma-media interface can still be determined for quantitative purposes. Beyond the media are echogenic structures corresponding to

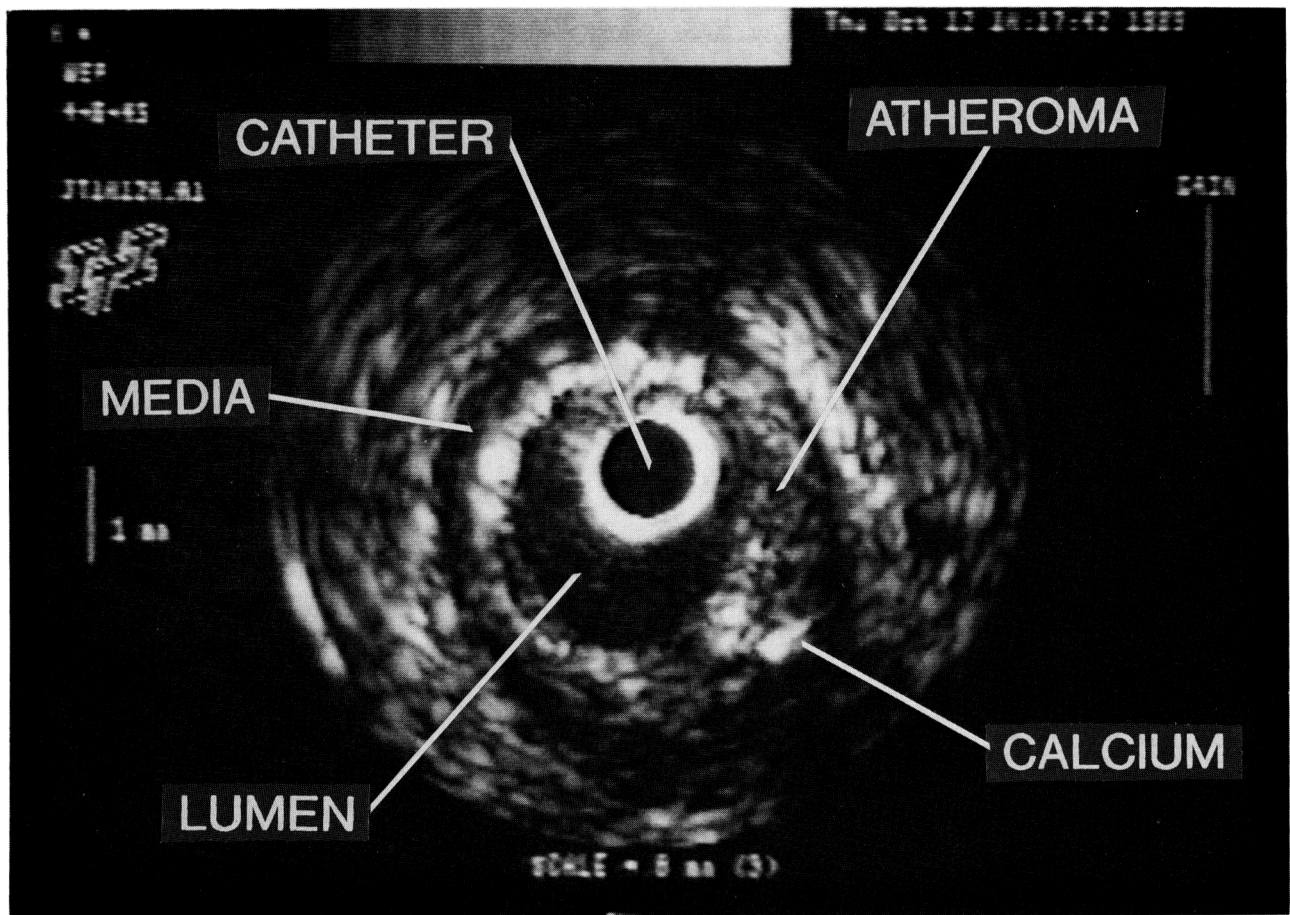
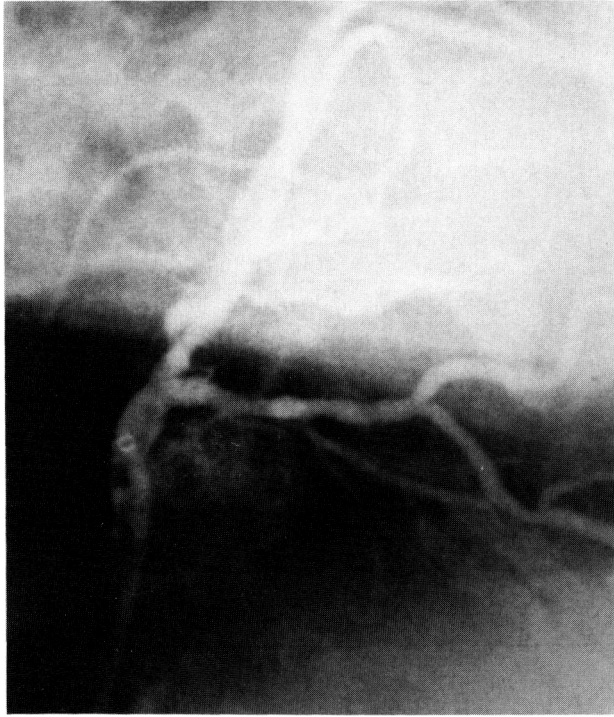

FIGURE 6. Representative intravascular ultrasound image from the midportion of the left anterior descending coronary artery from a patient who had balloon angioplasty. Ultrasound image was taken from a section of the artery that appeared normal on angiography.

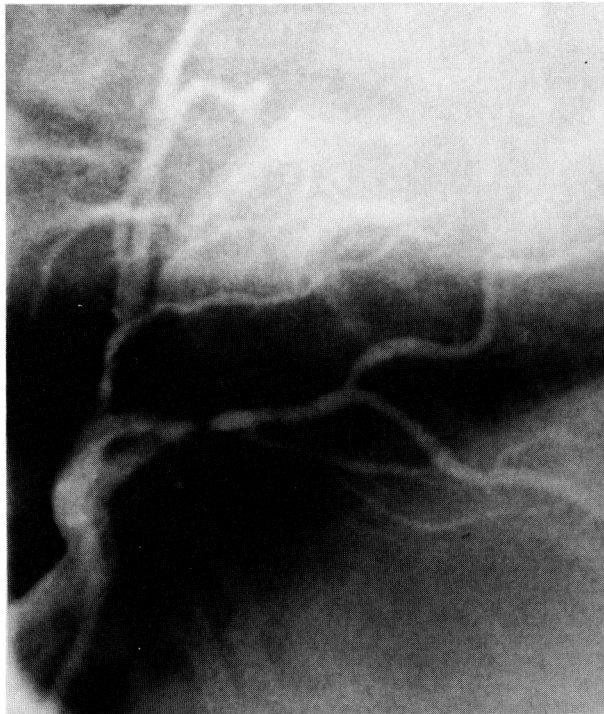
adventitia with poor distinction between the adventitia and surrounding tissues. The dimensions of the lumen are 2.3×2.8 mm, and the cross-sectional luminal area is 5.1 mm^2 . The total cross-sectional area within the boundary of the media is 12.2 mm^2 . The atheroma subtends an area of 7.1 mm^2 or 58% of the available arterial area.

Figure 7A shows a coronary angiogram in the left anterior oblique projection from a patient with a severe stenosis in the proximal LAD. After balloon dilatation (Figure 7B), there is still a hazy appearance to the segment of the artery that was dilated. The ultrasound imaging device was inserted through a 9F multipurpose guiding catheter, and multiple images were obtained as the ultrasound subassembly was advanced and withdrawn. Figure 7C shows the ultrasound subassembly within the left coronary artery at the level of the previously dilated section of the LAD. The ultrasound images obtained from the various segments of the left main and LAD are shown in Figure 7D. The left main coronary artery lumen was 23.5 mm^2 in cross-section with evidence of minimal atheroma (6.6 mm^2) involving the intimal surface. The atheroma area was 22% of the left main arterial cross-section. Distal to the level of balloon

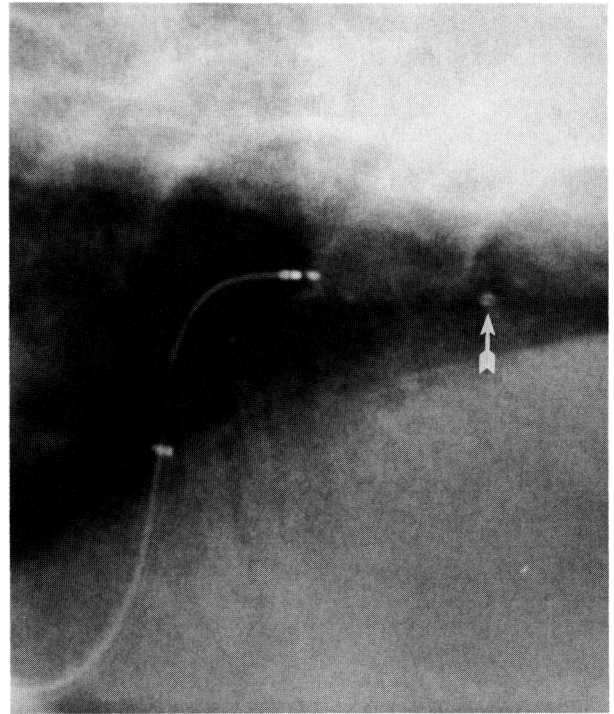
dilatation, the ultrasound cross-sectional image demonstrated a residual lumen that was 2.3×2.1 mm in diameter or 3.7 mm^2 in cross-sectional area. The external surface of the atheroma is clearly defined circumferentially by the echolucent band that corresponds to the media. In addition, a dense area of calcification is observed that had the characteristic of being highly echo reflective with dropout of ultrasound information distal to the calcium. As the ultrasound subassembly catheter was withdrawn to the level of the previously dilated segment, a loosely speckled echo-reflective structure was noted to take up most of the central-inferior portion of the artery cross-section around the plastic introducer sheath. There was a moderate-sized dissection of the echo-dense atheroma along the line of the media between 3 and 9 o'clock on the ultrasound image. The criterion used to define a dissection on the ultrasound image was a wide echolucency (>0.3 mm) between the atheroma and the media, which was twice as wide as the remaining intact media. The mildly echoreflective density within the central lumen of the artery corresponded to the hazy appearance on angiography, but it is unclear whether this represents thrombus formation or residual atheroma. This central



B



A



C

FIGURE 7. Panel A: Angiogram of the left coronary artery in the left anterior oblique projection with cranial angulation demonstrates severe stenosis of the proximal left anterior descending coronary artery. Panel B: Angiogram after balloon dilatation with a 4.0-mm balloon catheter demonstrates an enlarged diameter of the vessel; however, persistent haziness occurs in the contrast media at the level of the previous dilatation. Panel C: Ultrasound imaging subassembly has been inserted into the left anterior descending artery and is at the level of the previous dilatation. Radiopaque marker on the distal tip of the plastic introducing sheath can be observed (arrow).

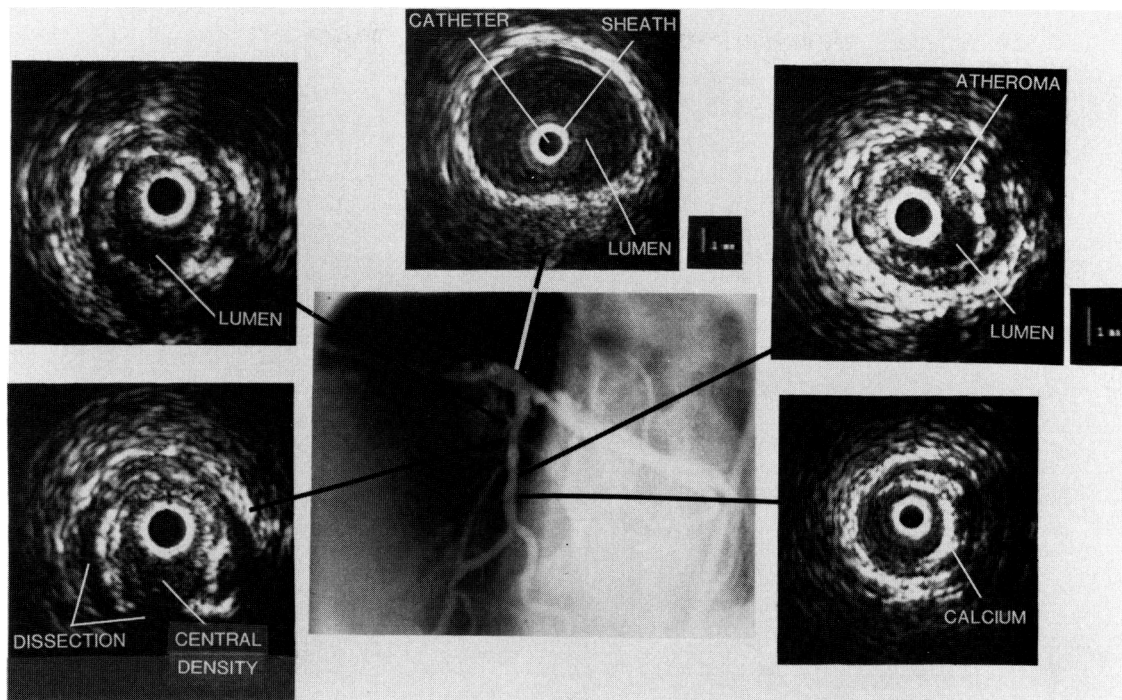


FIGURE 7 (Continued). Panel D: *Ultrasound images obtained from the various levels of the left coronary artery. Moving in the proximal to distal direction down the artery, 1) left main coronary artery shows a large cross-sectional area with mild atheroma involvement (22% of the cross-sectional area); 2) proximal to the dilated stenotic segment, significant atheroma occupied 61% of the cross-sectional area; and 3) ultrasound image corresponds to the level of the balloon dilatation. Lumen is compromised with a large atheroma mass occupying 78% of the cross-sectional area. Calcification occurs within this atheroma with echo dropout peripherally, which was not observed on fluoroscopy. Patchy echo-reflective structure in the central-inferior region could represent residual atheroma or thrombus. This central echo-reflective structure was not observed in the lumen of the artery, a few millimeters in proximal or distal directions. 4) Distal to the original stenosis, angiogram demonstrates a segment with a 20% diameter stenosis. By ultrasound, atheroma involvement is 64% of the cross-sectional area of the artery at this level. 5) Ultrasound image was taken at a more distal level that appeared normal by angiography. Ultrasound image reveals a relatively large lumen, 3.4×3.3 mm in diameter and 8.9 mm^2 in cross section. However, an eccentric atheroma occupies 9.3 mm^2 or 51% of the total cross-sectional area and had intense echoes consistent with calcification.*

echo-reflective material and the atheroma occupied 12.4 mm^2 , which was a significant portion of the arterial cross-section (78%) but was not occlusive because the dissection had enlarged the pathway for blood. The material was only a few millimeters in length and was not observed in the cross-sectional images just proximal or distal. Based on the angiographic appearance, a clinical decision was made not to redilate the artery or to give thrombolytic therapy. The patient did not have an acute ischemic event after balloon angioplasty, and it was concluded that there was residual blood flow in the dissection plane as well as through the relatively small lumen taken up by the ultrasound transducer catheter. A follow-up angiogram obtained 3 weeks later demonstrated resolution of the previous hazy segment. This angiographic finding is more consistent with a thrombus that was lysed than with residual atheroma.

A second patient with significant obstruction in the proximal and distal portions of the circumflex coronary artery (Figure 8A) had successful balloon angioplasty of both sections of the artery (Figure 8B). The introducing sheath was positioned in the mid-

portion of the circumflex coronary artery because of concern that the 1.6-mm sheath may be occlusive in the distal segment of the artery. The ultrasound image obtained at the proximal stenosis after dilatation is demonstrated in Figure 8C. Despite an adequate appearance of the lumen diameter on the angiogram, the ultrasound image revealed a dense, extensive residual atheroma of 16.5 mm^2 in cross-sectional area. A rim of calcification is apparent at the base of the atheroma (from 12 to 4 o'clock) with dropout of echo reflections in the distal portion. There is a circumferential dissection from 5 to 11 o'clock that may explain why the angiogram appeared to show a larger lumen diameter. The lumen width would appear to be 4.1×2.4 mm by projection image angiography, but in cross-sectional ultrasound imaging, this "lumen" actually corresponds to the dissection plane slit.

Calcium was present by ultrasound in 16 of 22 (73%) arteries. The incidence of calcium was underestimated by angiography determined by visual inspection on fluoroscopy or the cinefilm. The angiogram demonstrated the presence of calcium at the

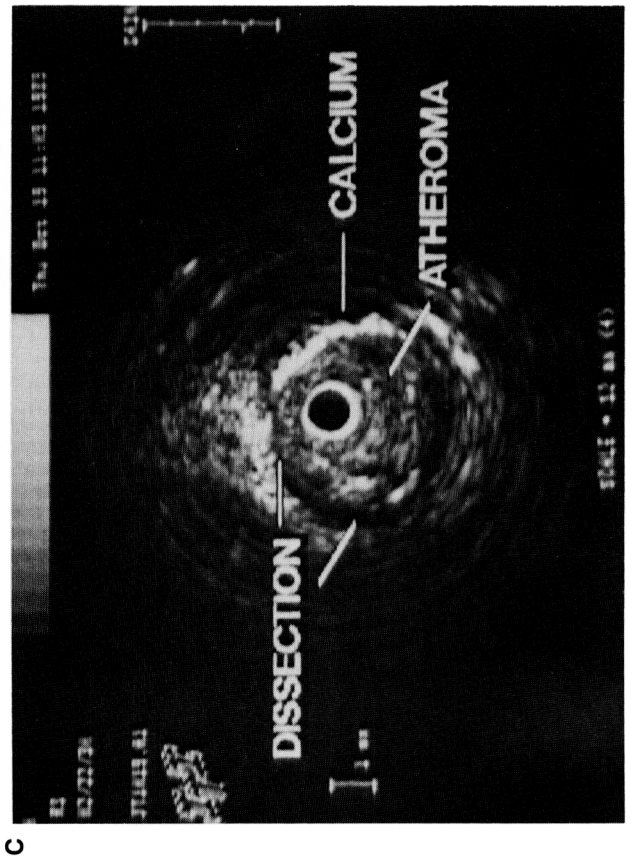
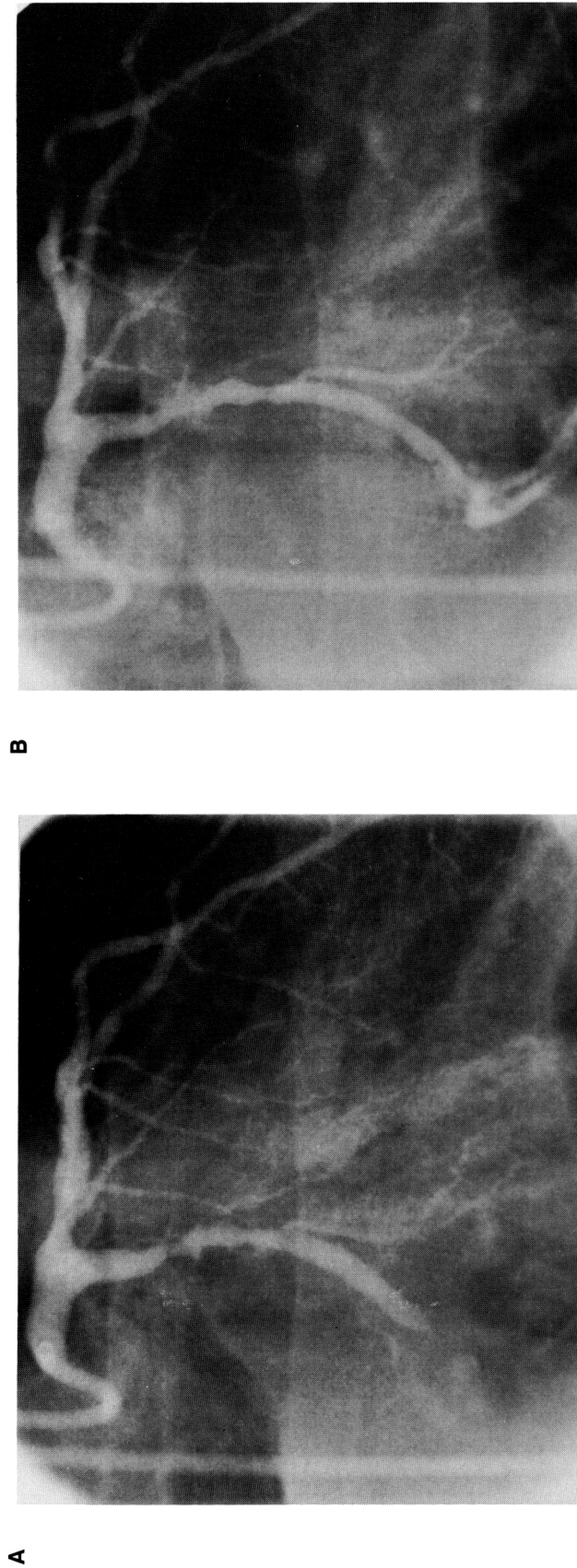


FIGURE 8. Panel A: Angiogram in the right anterior oblique projection demonstrates a 50% diameter narrowing of the proximal circumflex coronary artery and subtotal occlusion of the distal circumflex vessel. These obstructions were opened with a 3.0-mm angioplasty balloon. Panel B: Angiogram demonstrating a successful angiographic result. Panel C: Intravascular ultrasound image at the level of the proximal stenosis after balloon dilatation shows extensive residual atheroma with calcification that was not visualized on fluoroscopy. In addition, a dissection is present that is almost completely circumferential that could account for the apparent increase in width of the artery. Of note, a tear is not apparent in the atheroma at this level even though the atheroma is separated from the media.

TABLE 1. Coronary Artery Lumen Measurements

Ultrasound			Angiography		
Diameters (mm)		Lumen area (mm ²)	Diameters (mm)		Lumen area (mm ²)
Major	Minor		RAO	LAO	
At the previously dilated segment					
2.7±0.7	2.2±0.6	5.0±2.0*	2.0±0.6	1.9±0.5	3.3±1.3*
At the angiographically normal segments					
3.4±1.2	3.0±1.1	9.2±4.6†	3.0±1.0	3.1±0.9	7.1±2.5†

Data are mean±SEM.
 RAO, right anterior oblique; LAO, left anterior oblique.
 *p<0.01; †p<0.05.

level where the ultrasound images were obtained in only one of the 22 (5%) arteries (p<0.05), although calcium was observed in more proximal segments in six other patients. The intense echo reflections that were interpreted as demonstrating calcium almost always occurred at the outer perimeter of the atheroma adjacent to the media.

Quantitative Analysis

The lumen cross-sectional areas and diameters measured directly from the ultrasound images and the lumen diameters measured by angiography (which was used to calculate cross-sectional area) are shown in Table 1 for both the angiographically uninvolved segments and for the site of the prior balloon dilation. The mean lumen cross-sectional area on the ultrasound images (9.2±4.6 mm²) was larger than the mean area from angiography (7.1±2.5 mm²) for the angiographically normal segments (p<0.05). Moreover, the mean lumen area at the previously dilated site by ultrasound (5.0±2.0 mm²) was larger than the mean area calculated by angiography (3.3±1.3 mm², p<0.01). In addition, a poor correlation was found between the individual measurements of the dilated area by ultrasound and by

angiography as demonstrated in Figure 9. When only the normal segments were compared, the correlation was still poor between the ultrasound images and angiography for measuring the arterial lumen (Y=0.48X+5.8, r=0.26) (Figure 10).

Atheroma cross-sectional areas determined from the ultrasound images are presented in Table 2. A significant amount of atheroma was observed on the ultrasound images that was not discernible by angiography at both the previously dilated sites and the apparently normal (by angiography) segments. The ability to obtain adequate images of the atheroma area during the in vivo studies was enhanced by the motor drive unit that obtained cross-sectional images at 30 times/sec compared with the hand-rotated device used during the in vitro studies. Therefore, the anatomic landmarks of the atheroma and arterial wall were discernible in a higher percentage of images than in the in vitro studies.

There were few complications created by the use of the ultrasound imaging device. One patient with a right coronary stenosis and small dissection after balloon angioplasty had an extension of the original dissection by the plastic sheath when it was inadvert-

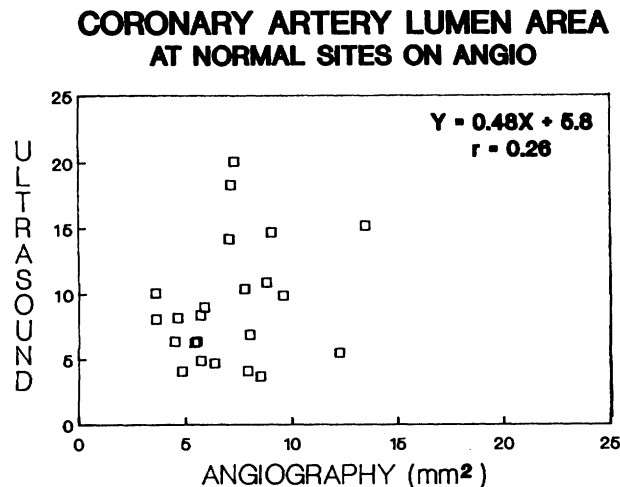


FIGURE 9. Plot of cross-sectional lumen area at the level of balloon dilatation. Cross-sectional areas measured directly on the ultrasound images are compared with lumen diameters calculated from orthogonal angiograms.

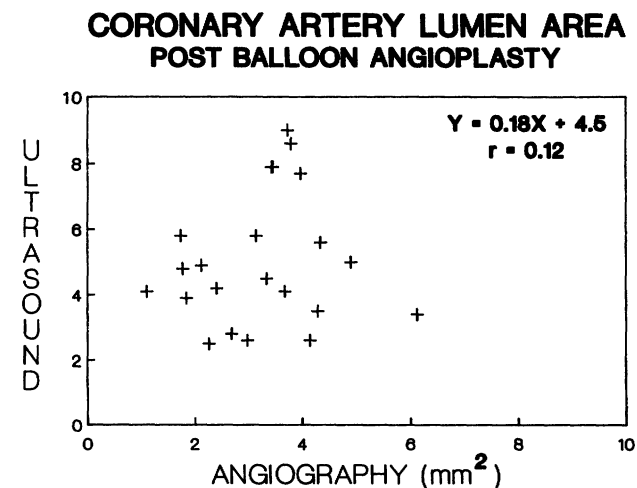


FIGURE 10. Plot of cross-sectional lumen area at the level of angiographically normal segments of the arteries proximal or distal to the balloon dilatation. Cross-sectional areas measured directly from the ultrasound images compared with lumen diameters calculated from orthogonal angiograms.

TABLE 2. **Coronary Artery Atheroma Area by Ultrasound**

	Atheroma cross-sectional area (mm ²)	Percent of area within media filled with atheroma (%)
At the previously dilated site	8.7±3.4	63.1±12.7
At the angiographically normal segments	4.7±3.2	34.6±23.2

Data are mean±SEM.

ently advanced into the coronary artery after the guide wire had been removed. This occurred when the guiding catheter was manipulated without first withdrawing the introducing plastic sheath. The patient's dissection was treated with repeated balloon angioplasty to tack up the torn atheroma against the arterial wall. The patient had no sequelae from this and was discharged the following day. Another four patients experienced angina (two with ischemic ST segment changes on the electrocardiogram) that was relieved when the introducing sheath was withdrawn more proximally. This event was presumably caused by the 1.6-mm diameter of the introducing sheath that became occlusive in the distal portion of the artery and limited blood flow. Three patients had spasm of the previously dilated segment after the introducing sheath was removed. The arterial spasm resolved with the administration of 150 μ g i.c. nitroglycerin.

Discussion

This preliminary study demonstrates the capability of intravascular ultrasound for providing real-time cross-sectional images of the coronary arterial lumen and wall in vivo. High-resolution imaging is feasible with a miniaturized ultrasound transducer. The device was passed safely into relatively small coronary arteries in 24 patients and successfully imaged the atheroma plaque at the level of the prior balloon angioplasty in 22 patients. From these intravascular images, it is possible to calculate the lumen geometry and the atheroma plaque cross-sectional area. In addition, the eccentricity of the plaque can be clearly defined relative to the entire cross-sectional image of the artery. The ultrasound images are also capable of distinguishing certain characteristics such as fibrous tissue, calcification, and lipid or necrotic material within the atheroma plaque. This type of cross-sectional image is unobtainable from angiographic studies. Atheromatous involvement of the arterial wall can be discerned on the ultrasound images even in the segments that appear normal on angiography. Small areas of calcification within the atheroma were visualized by ultrasound but not by angiography. Our impression is that the information provided by intravascular ultrasound at areas of dissection is complementary to angiography and often provides more detail about plaque morphology than is visualized by angiography.

The angiographic appearance of a hazy, contrast-filled lumen after angioplasty often corresponds to an iodine-filled dissection plane and may represent a

much smaller cross-sectional lumen on ultrasound imaging than was believed to be present by angiography. The observation that contrast angiography may overestimate the residual lumen after balloon angioplasty is exemplified by the study shown in Figure 8. Although the width of the contrast-filled lumen on the angiogram appears adequate with only a 30% residual diameter stenosis, the ultrasound image reveals a large atheromatous mass that comprises 80% of the available cross-sectional area within the boundary of the media. The balloon angioplasty appeared to be successful by angiographic criteria because contrast media filled the crescentic dissection plane, which resulted in overestimating the true lumen area during projection imaging. The correlation between the lumen area measured by ultrasound and angiography was very poor (Figure 9). This erratic correlation was due, in part, to the dissections from balloon dilatation that resulted in irregular crescentic pathways with unclear borders to the lumen on angiography. However, even in the angiographically normal segments, the correlation was poor between the measurements from angiography and ultrasound ($r=0.26$). This may be explained, in part, by the difficulty in using the catheter tip to calibrate the magnification factor, but it raises the question whether the angiogram or the ultrasound measurement is the more accurate method. Nissen and coworkers,¹⁴ comparing intravascular ultrasound images with angiography, found a much closer correlation ($r=0.88$) between the two measurements of lumen diameter. However, their study was performed in artery segments before dilatation, which suggests that some of the scatter in our data may be due to the effect of tears in the atheroma after dilatation on cross-sectional measurements by intravascular ultrasound compared with projection image angiography.

In the cases where the angiogram and the ultrasound images correlate poorly, two sources of in vitro data suggest that the ultrasound images provide the more accurate representation. Several studies have shown excellent correlations between the lumen cross-sectional area measured from ultrasound images compared with direct measurements from histological cross-sections.^{11-13,15} In addition, an in vitro study using acrylic casts of a phantom model has demonstrated that contrast angiography overestimates the true lumen cross-sectional area compared with intravascular ultrasound when the lumen is not elliptical but irregular.¹⁶ This can result in an underestimation of lesion stenosis on diagnostic angiography or, as seen in the present study, an overestimation of the beneficial results after balloon angioplasty.

During these preliminary studies, our intent was not to use the information derived from the ultrasound images to alter the operator's decision about the need for further intervention. However, there were two occasions in which the ultrasound images were measured and interpreted as showing a more compromised lumen than was apparent on angiogra-

phy, and additional balloon dilatation was performed. In addition, we were impressed by the large amount of residual atheroma that remains at the site of balloon angioplasty. The mean cross-sectional area of the atheroma after dilatation was $8.7 \pm 3.4 \text{ mm}^2$, which represented $63.1 \pm 12.7\%$ of the available arterial cross-sectional area inside the media. Although the pathogenesis of restenosis may have many components, given these ultrasound observations on the mass of residual atheroma, it is not surprising that acute occlusion or restenosis occur; it is intriguing that the incidence of these events is not higher.

Of particular concern is the observation that the amount of atheroma was underestimated by angiography compared with the cross-sectional ultrasound images. In the segments of the artery that were considered angiographically normal, the ultrasound images revealed that atheroma plaque encompassed a mean of 35% of the cross-sectional area. This finding from the ultrasound images in vivo is consistent with previous pathological studies that suggested that angiography underestimates the amount of atherosclerosis present in coronary arteries.¹⁷ In addition, the results of these intravascular ultrasound studies may explain why angiography is not reliable in predicting the progression of atherosclerosis in patients with mild-to-moderate disease as defined by angiography.¹⁸ What appears as minimal disease by angiography may, in fact, correspond to atheroma subtending 35% of the cross-sectional area. This degree of plaque may not be morphologically stable and could appear to progress rapidly or proceed to occlusion despite the apparently benign angiogram. These preliminary observations raise the question whether intravascular ultrasound imaging should challenge contrast angiography as the standard for quantitative analysis of the extent of atherosclerotic involvement of coronary arteries. This early hypothesis based on the initial observations in this study will require confirmation by other researchers and longitudinal studies. The ability to make accurate measurements of the lumen and atheroma require high-quality images. Just as with transthoracic echocardiography, if a poor-quality study is obtained, then the quantitative measurements and diagnostic conclusions must be reserved. However, with the real-time imaging intravascular ultrasound devices, the catheter can be advanced and retracted slowly until an adequate image is obtained that demonstrates the atheroma and media such that quantitative measurements can be made at several positions along the length of the artery.

There is some potential risk in performing these intravascular imaging procedures. During the present study, a 9F guiding catheter was used, which could potentially dissect the arterial ostium or occlude blood flow despite the presence of side holes. The procedures were performed after balloon dilation and required that the dilated area was recrossed with the guide wire, which has the potential of lifting an intimal flap and creating a large dissection. The need to recross the area of dilation is now obviated be-

cause the ultrasound subassembly was made smaller so that it can fit through an 8F guiding catheter. At the present time, the guide wire and guiding catheter can be left in place after balloon angioplasty, and the introducing sheath can be inserted over an exchange wire. There are several limitations with the present configuration of the intravascular imaging device. The total diameter is currently 1.6 mm, which is adequate for imaging small structures such as coronary arteries after balloon dilatation. However, this device would be occlusive for most symptomatic stenoses before dilatation. Furthermore, adequate visualization is severely impaired if any thrombus or air bubbles get caught between the transducer and the mirror. To prevent adherence of air bubbles, intermittent flushes with saline are required. An important adjunct to correlative studies between angiography and ultrasound will be the capacity to record the position of the ultrasound subassembly on fluoroscopy while the ultrasound images are obtained simultaneously on the same videotape.

The clinical significance of these preliminary observations remains to be determined by large clinical studies that will follow patients for clinical correlations. These ongoing studies will determine whether the information obtained by intravascular ultrasound can predict which patients may develop acute occlusion or which subset of patients is likely to develop restenosis. Because the human arteries in this clinical series that were imaged by ultrasound were not available for histological comparison, the in vitro study results were used to demonstrate that plaque morphology and tissue characterization from the intravascular ultrasound images correspond closely with histological samples. The in vitro histological sections presented in this paper were not fixed under pressure, which could result in differences between quantitative measurements of lumen area or qualitative examination of wall morphology compared with the ultrasound images. The present study demonstrates that the high-quality ultrasound images obtained during in vitro studies can also be obtained during in vivo studies in human coronary arteries.

We conclude that intra-arterial ultrasound imaging appears feasible and shows promise as a method for identifying normal and diseased arterial wall structures. These high-quality ultrasound images allow quantitative assessment of the extent of atheromatous involvement of the artery as well as the morphology and character of the atheroma tissue. Such an approach, performed percutaneously in the catheterization laboratory, represents a fundamental and important departure from traditional angiographic methods for assessing the severity of coronary, carotid, or peripheral arterial disease.

References

1. Euserman JH, Achor RWP, Kincaid OW, Brown AL Jr: Atherosclerotic disease of the coronary arteries: A pathologic-radiologic study. *Circulation* 1962;26:1288-1295

2. Vlodayer Z, Frech R, Van Tassel RA, Edwards JE: Correlation of the antemortem coronary arteriogram and the post-mortem specimen. *Circulation* 1973;47:162-169
3. McPherson DD, Hiratzka LF, Lamberth WC, Brandt B, Hunt M, Kieso RA, Marcus ML, Kerber RE: Delineation of the extent of coronary atherosclerosis by high-frequency epicardial echocardiography. *N Engl J Med* 1987;316:304-309
4. Sahn DJ, Barratt-Boyes BG, Graham K, Kerr A, Roche A, Hill D, Brandt PW, Copeland JG, Mammanna R, Temkin LP, Glenn W: Ultrasonic imaging of the coronary arteries in open-chest humans: Evaluation of coronary atherosclerotic lesions during cardiac surgery. *Circulation* 1982;66:1034-1044
5. Yao JS, Flinn WR, Bergan JJ: Noninvasive vascular diagnostic testing: Techniques and clinical applications. *Prog Cardiovasc Dis* 1984;26:459-494
6. Sumner DS, Russell JB, Miles RD: Pulsed-Doppler arteriography and computer assisted imaging of the carotid bifurcation, in Bergan JJ, Yao JST (eds): *Cerebrovascular Insufficiency*. New York, Grune & Stratton, 1983;115-135
7. Johnson MR, McPherson DD, Fleagle SR, Hunt MM, Hiratzka LF, Kerber RE, Marcus ML, Collins SM, Skorton DJ: Videodensitometric analysis of human coronary stenoses: Validation in vivo by intraoperative high-frequency epicardial echocardiography. *Circulation* 1988;77:328-336
8. Mallery JA, Gregory K, Morcos NC, Griffith J, Henry WL: Evaluation of an ultrasound balloon dilatation imaging catheter (abstract). *Circulation* 1987;76(suppl IV):IV-371
9. Yock PG, Johnson EL, Linker DT: Intravascular ultrasound: Development and clinical potential. *Am J Cardiac Imaging* 1988;2:185-193
10. Pandian N, Kreis A, Desnoyers M, Isner J, Salem D, Sacharoff A, Boleza E, Wilson R, Caro R: In vivo ultrasound angiography in humans and animals: Intraluminal imaging of blood vessels using a new catheter-based high resolution ultrasound probe (abstract). *Circulation* 1988;78(suppl II):II-22
11. Gussenhoven EJ, Essed CE, Lancee CT, Mastik F, Frietman P, Van Egmond FC, Reiber J, Bosch H, Van Urk H, Roelandt J, Bom N: Arterial wall characteristics determined by intravascular ultrasound imaging: An in vitro study. *J Am Coll Cardiol* 1989;14:947-952
12. Tobis JM, Mallery JA, Gessert J, Griffith J, Mahon D, Bessen M, Moriuchi M, McLeay L, McRae M, Henry WLH: Intravascular ultrasound cross-sectional arterial imaging before and after balloon angioplasty in vitro. *Circulation* 1989;80:873-882
13. Mallery JA, Tobis JM, Griffith J, Gessert J, McRae M, Moussabeck O, Bessen M, Moriuchi M, Henry WL: Assessment of normal and atherosclerotic arterial wall thickness with an intravascular ultrasound imaging catheter. *Am Heart J* 1990;119:1392-1400
14. Nissen SE, Grines CL, Gurley JC, Sublett K, Haynie D, Diaz C, Booth DC, DeMaria AN: Application of a new-phased-array ultrasound imaging catheter in the assessment of vascular dimensions: In vivo comparison to cineangiography. *Circulation* 1990;81:660-666
15. Potkin BN, Bartorelli AL, Gessert JM, Neville RF, Almagor Y, Roberts WC, Leon MB: Coronary artery imaging with intravascular high-frequency ultrasound. *Circulation* 1990;81:1575-1585
16. Moriuchi M, Tobis JM, Gordon I, Bergman A, Griffith J, Henry WL: Functional significance of arterial stenoses predicted by angiography and intravascular ultrasound imaging catheter (abstract). *J Am Coll Cardiol* 1990;15:106A
17. Waller BF, Roberts WC: Amount of narrowing by the atherosclerotic plaque in 44 non-bypassed and 52 bypassed major epicardial coronary arteries in 32 necropsy patients who died within one month of aortocoronary bypass grafting. *Am J Cardiol* 1980;46:956-962
18. Little WC, Constantinescu M, Applegate RJ, Kutcher MA, Burrows MT, Kahl FR, Santamore WP: Can coronary angiography predict the site of a subsequent myocardial infarction in patients with mild-to-moderate coronary artery disease? *Circulation* 1988;78:1157-1166

KEY WORDS • arterial wall structure • atherosclerosis • ultrasound imaging, intravascular