

UC Irvine

UC Irvine Previously Published Works

Title

Not All That Wheezes Is AsthmaA Case Report of an Endobronchial Tumor in a Child

Permalink

<https://escholarship.org/uc/item/1ck6t2fq>

Journal

Pediatric Allergy Immunology and Pulmonology, 17(3)

ISSN

2151-321X

Authors

Moser, Chuanpit

Maggi, Carlos

Bethencourt, Daniel

et al.

Publication Date

2004-09-01

DOI

10.1089/pai.2004.17.204

Copyright Information

This work is made available under the terms of a Creative Commons Attribution License, available at

<https://creativecommons.org/licenses/by/4.0/>

Peer reviewed

Case Report

Not All That Wheezes Is Asthma— A Case Report of an Endobronchial Tumor in a Child

CHUANPIT MOSER, M.D.,^{1,2} CARLOS MAGGI, M.D.,^{1,2}
DANIEL BETHENCOURT, M.D.,¹ STEPHEN ROMANSKY, M.D.,¹
and ELIEZER NUSSBAUM, M.D.^{1,2}

ABSTRACT

An endobronchial mass was found in a main-stem bronchus of a 13-year-old girl with a new-onset “asthma.” Biopsy of the mass revealed mucoepidermoid carcinoma. The condition was completely cured using a sleeve tumor resection and bronchoplasty. Endobronchial tumors are extremely rare in children. Their presentations often mimic asthma, which could lead to misdiagnosis and delayed treatment. High index of suspicion in cases with unusual or “atypical” asthma necessitating diagnostic bronchoscopy and biopsy is the key to an early surgical intervention, which generally results in a favorable outcome.

CASE PRESENTATION

A PREVIOUSLY HEALTHY 13-year-old girl presented with a 2-month history of persistent cough and dyspnea on exertion that was unresponsive to asthma therapy. There was no history suggestive of foreign body aspiration. Family history was significant for asthma. Remarkable signs on physical exam were expiratory wheezes and diminished breath sound in the left lung. Plain chest radiographs were essentially normal, without any air trapping. A bronchoscopic exam demonstrated a near complete occlusion of the left main stem bronchus by an intraluminal soft tissue mass (Fig. 1). Tissue biopsy revealed mucoepidermoid carcinoma (Fig. 2). A magnetic resonance image of the chest showed that the mass was well confined in the left main stem bronchial lumen (Fig. 3). The patient underwent a sleeve tumor resection and bronchoplasty.¹ The borders of the resected specimen were free from carcinoma cells. Follow-up bronchoscopic exams and bronchial biopsies at 3, 6, and 12 months post-operatively revealed no recurrence of the tumor.

BRIEF DISCUSSION

Endobronchial tumors are extremely rare in children.²⁻⁷ Among many different types of tumors are benign (papilloma, hemangioma, leiomyoma), or malignant (mucoepidermoid carcinoma, adenoid cystic carcinoma / cylindroma, carcinoid). Early presenting symptoms often masquerade asthma. If the tumor is left unremoved, compression atelectasis or recurrent pneumonia usually follows.⁸

¹Miller Children’s Hospital at Long Beach Memorial Medical Center, Long Beach, CA 90806, and ²University of California, Irvine.

ENDOBRONCHIAL TUMOR

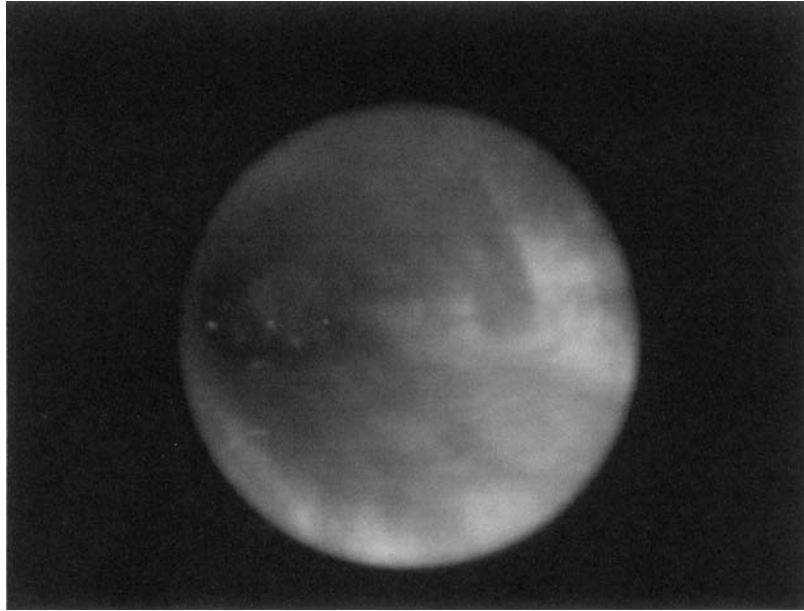


FIG. 1. A bronchoscopic view of an endobronchial mucoepidermoid carcinoma in the left main stem bronchus of a 13-year-old girl.

Mucoepidermoid carcinoma most commonly affects salivary glands. Its pathological characteristics are intracellular and extracellular accumulation of acid mucopolysaccharides. The origin of this transformation seems to be located within the cells of a glandular duct.⁹ The virulence of its malignancy varies from grade I (least virulent), to grade III (most virulent).¹⁰ Although surgical resection only is required to cure a grade

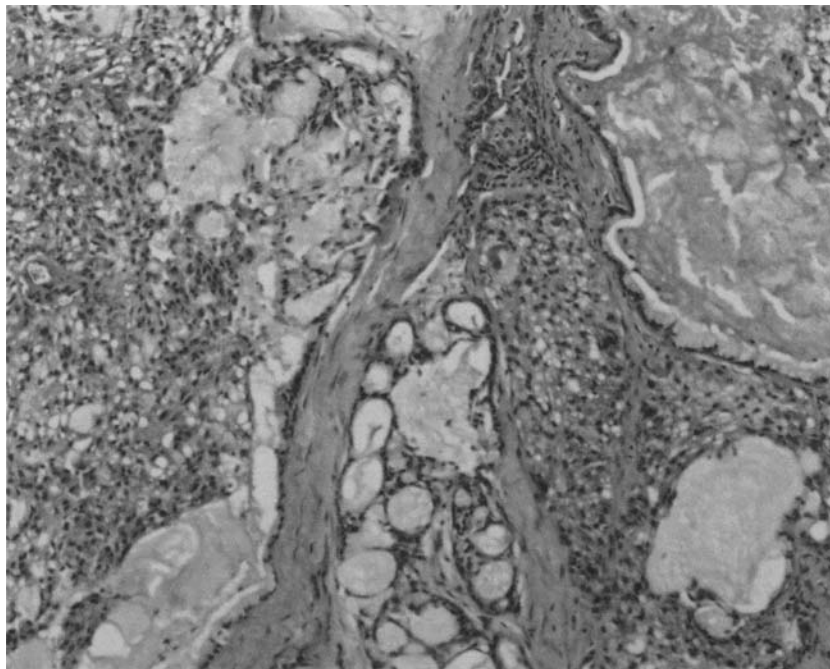


FIG. 2. Hematoxylin and eosin stain of an endobronchial mass showing mucoepidermoid carcinoma.

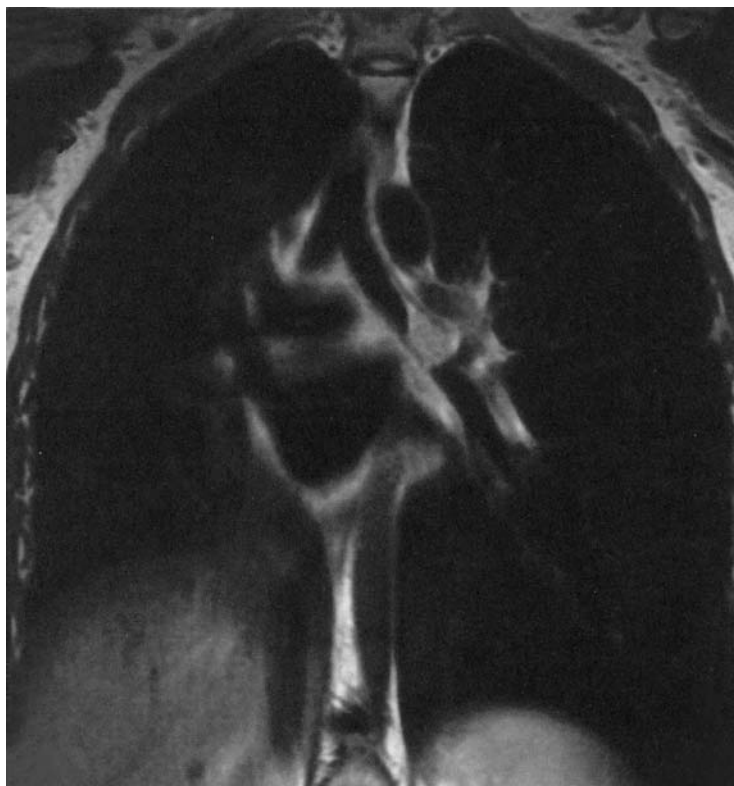


FIG. 3. A magnetic resonance image of the chest showing an endobronchial mass in the left main stem bronchus.

I mucoepidermoid carcinoma, optimal treatment for grade II and III tumors continues to be problematic in spite of combined surgery and radiotherapy. Prognosis is much more favorable in children than in adults.

Early diagnosis of endobronchial tumors requires a high index of suspicion in children with atypical respiratory complaints or those who fail to respond to therapy. Further investigation, such as diagnostic bronchoscopy, is of paramount importance in ruling out or establishing anatomical pathology in the conducting airways. The presence of mechanical obstruction, which may be caused by a variety of pathology such as a foreign body, web, granuloma, or in our case, a tumor, may erroneously suggest asthma and lead to delayed diagnosis and care.

REFERENCES

1. Cerfolio RJ, Deschamps C, Allen MS et al. Main stem bronchial sleeve resection with pulmonary preservation. *Ann Thorac Surg* 1996; 61:1458–1462; discussion 1462–1463.
2. Scott KJ, Greinwald JH Jr, Darrow D et al. Endobronchial tumors in children: an uncommon clinical entity. *Ann Otol Rhinol Laryngol* 2001; 110:63–69.
3. Smiddy PF, Abdul Manaf ZM, Roberts IF et al. Endobronchial mucoepidermoid carcinoma in childhood: case report and literature review. *Clin Radiol* 2000; 55:647–649.
4. Curtis JM, Lacey D, Smyth R et al. Endobronchial tumors in childhood. *Eur J Radiol* 1998; 29:11–20.
5. Welsh JH, Maxson T, Jaksic T, et al. Tracheobronchial mucoepidermoid carcinoma in childhood and adolescence: case report and review of the literature. *Int J Pediatr Otorhinolaryngol* 1998; 45:265–273.
6. Barrett W, Heaps LS, Diaz S, et al. Mucoepidermoid carcinoma of the bronchus in a 15-year-old girl with complex cytogenetic rearrangement involving 11q and over-expression of cyclin D1. *Med Pediatr Oncol* 2002; 39:49–51.

ENDOBONCHIAL TUMOR

7. Niggemann B, Gerstner B, Guschmann M, et al. An 11-yr-old male with pneumonia and persistent airway obstruction. *Eur Respir J* 2002; 19:582–584.
8. Hartman GE, Shochat SJ. Primary pulmonary neoplasms of childhood: a review. *Ann Thorac Surg* 1983; 36:108–119.
9. Eskenasy A, Mangiulea V. Ultrastructure of a bronchial mucoepidermoid tumor of a seven-year-old boy. *Morphol Embryol* 1980; 26:335–340.
10. Conlan AA, Payne WS, Woolner LB et al. Adenoid cystic carcinoma (cylindroma) and mucoepidermoid carcinoma of the bronchus. Factors affecting survival. *J Thorac Cardiovasc Surg* 1978; 76:369–377.

Address reprint requests to:

*Chuanpit Moser, M.D.
Pediatric Pulmonary Division, 3rd Floor
Miller Children's Hospital
2801 Atlantic Avenue
Long Beach, CA 90806*

E-mail: CMoser@memorialcare.org