

UC Davis

Dermatology Online Journal

Title

A case of vancomycin-induced drug rash with eosinophilia and systemic symptoms (DRESS) syndrome with failure to respond to cyclosporine treatment

Permalink

<https://escholarship.org/uc/item/1bx778dt>

Journal

Dermatology Online Journal, 26(6)

Authors

Clark, Denise
Alomari, Ahmed K
Burton, Kyle
[et al.](#)

Publication Date

2020

DOI

10.5070/D3266049312

Copyright Information

Copyright 2020 by the author(s). This work is made available under the terms of a Creative Commons Attribution-NonCommercial-NoDerivatives License, available at <https://creativecommons.org/licenses/by-nc-nd/4.0/>

A case of vancomycin-induced drug rash with eosinophilia and systemic symptoms (DRESS) syndrome with failure to respond to cyclosporine treatment

Denise Clark MS, Ahmed K Alomari MD, Kyle Burton MD, Sahand Rahnama-Moghadam MD MS

Affiliations: Department of Dermatology, Indiana University School of Medicine, Indianapolis, Indiana, USA

Corresponding Author: Sahand Rahnama-Moghadam, Indiana University, 545 Barnhill Drive, Indianapolis, IN 46202, Tel: 317-274-7718, Email: srahnama@iupui.edu

Abstract

Drug rash with eosinophilia and systemic symptoms (DRESS) is a rare delayed drug reaction that often occurs 2-6 weeks after initiation of therapy and may develop into a life-threatening systemic reaction. Besides immediate discontinuation of the suspected inciting drug, initiation of high dose systemic corticosteroids has long been the mainstay of treatment for severe cases. Nevertheless, significant drawbacks associated with systemic corticosteroid therapy, such as the requirement of a long tapering period post resolution and extensive adverse side effects profile, have motivated clinicians to seek alternative treatment options. Over the past decade, an undisputed increasing number of favorable case reports has highlighted cyclosporine as an emerging, safe, and effective alternative despite inconsistent dosing regimens reported. Herein, we report a severe case of vancomycin-induced DRESS syndrome in which the patient failed initial intervention with cyclosporine and needed rescue with methylprednisolone. To the best of our knowledge, this constitutes the first unsuccessful report of cyclosporine treatment for DRESS syndrome.

Keywords: DRESS, cyclosporine, vancomycin, drug reaction, eosinophilia, corticosteroid, morbilliform, rash

Introduction

Drug rash with eosinophilia and systemic symptoms (DRESS) is a delayed drug reaction that generally occurs 2-6 weeks after initiation of therapy and may develop into a life-threatening systemic syndrome.

The syndrome is primarily characterized by severe skin eruption, fever, facial edema, lymphadenopathy, and hematologic abnormalities (eosinophilia or atypical lymphocytes). One or more internal organs are mildly to severely involved and complications such as hepatitis, carditis, interstitial nephritis, or interstitial pneumonitis lead to an approximate 10% mortality rate associated with this condition [1]. Among antibiotics, vancomycin is frequently associated with DRESS syndrome, with over 40 cases reported in the literature [2, 3].

Immediate discontinuation of the culprit drug and initiation of high dose systemic corticosteroids have been the mainstay of treatment for severe cases of DRESS syndrome [4, 5]. Significant drawbacks, such as the requirement of a long tapering period post-resolution along with the adverse side effect profile of corticosteroids, indicate that alternative treatments are needed [6]. Recently, there have been several reports of the successful use of cyclosporine for the treatment of DRESS syndrome in cases when corticosteroids have failed, are contraindicated, or undesired [6-8]. Such mounting evidence even motivated the mention of cyclosporine in recent review publications as an emerging, safe, and effective alternative to corticosteroid treatment, despite variability in dosing regimens reported [5, 9]. However, in the absence of prospectively designed valid studies, results provided in case reports may be subject to positive reporting/publication bias. Herein, we report a patient with vancomycin induced DRESS syndrome in which the patient failed initial intervention with cyclosporine and needed rescue with methylprednisolone.

Case Synopsis

A young woman with a history of intravenous methamphetamine and heroin use, presented to the emergency department with fevers, chills, and shortness of breath; she was ultimately diagnosed with methicillin resistant *Staphylococcal aureus* bacteremia and tricuspid valve endocarditis. She was initiated on a planned 6-week course of intravenous vancomycin treatment and experienced resolution of her bacteremia and constitutional symptoms. She underwent a minimally-invasive cardiovascular procedure for valve repair four weeks after hospital admission while continuing vancomycin, but on the first post-operative day the patient began complaining of facial edema and a pruritic morbilliform rash over her trunk. Owing to suspicion of a drug reaction, vancomycin was stopped the following day and daptomycin started instead (which was continued throughout her hospitalization).

In the subsequent days, the patient also developed a recurrence of low-grade fevers, chills, and rigors. Her mentation became lethargic and her white blood cell count remained mildly elevated, while the rash became more confluent and irritating. Eventually the eruption involved almost 90% of her skin surface. On the fourth day of her rash, eosinophilia developed and the diagnosis of probable DRESS syndrome was made. The patient was given a single dose of 40mg prednisone by her primary care team. Given her initially mild presentation and the desire to avoid a prolonged corticosteroid taper, the dermatology consultant-initiated cyclosporine therapy at 3mg/kg/day, divided twice daily, as described in prior reports of short courses of cyclosporine.

Despite initiation of treatment, the patient's condition continued to worsen. She grew increasingly uncomfortable and more lethargic. She exhibited diffuse generalized and tender lymphadenopathy and high-grade fevers (>102°F). At 6 days after the onset of the eruption and after four doses of cyclosporine, the patient's white blood cell count reached a peak of 31.5k/mm³, with an absolute eosinophil count of 6.9k/mm³ and she was transferred to the intensive care unit owing to clinical instability. Furthermore, she had worsening

shortness of breath with infiltrates on her chest X-ray, diarrhea, confusion, and a mild troponin elevation, although her creatinine and liver function enzymes remained within normal limits. At that point, two skin punch biopsies from the patient's right forearm and abdomen were collected for morphological analysis and the decision was made to switch the patient from cyclosporine to methylprednisolone 40mg twice daily. More blood cultures were drawn but remained negative. Cytomegalovirus, Epstein-Barr virus, and human herpes virus 6 PCR tests were also negative.

The pathology findings in both biopsies were similar and consistent with either a lymphomatoid drug eruption or a lymphoproliferative process. Both specimens were predominated by a dense perivascular and interstitial lymphocytic infiltrate showing epidermotropism, folliculotropism, and numerous large cells with irregular and hyperchromatic nuclei. Several eosinophils in the dermis and deep dermis were present. Additional findings included superficial papillary dermal edema and red blood cell extravasation (**Figure 1**). Owing to treatment failure and the possibility of a lymphoproliferative process, peripheral blood flow cytometry was ordered. No immunophenotypic evidence of a T cell lymphoproliferative process or increased number of blasts was found. Such results, when correlated with morphology and clinical presentation, strongly suggested DRESS syndrome with a pseudolymphomatous drug eruption histology as the most likely diagnosis, despite cyclosporine treatment failure. The diagnosis of definite DRESS syndrome was further supported by a RegiSCAR score of 9 (**Table 1**), [10]. Additional T cell gene rearrangement studies were considered at the time. However, they were deferred given the clinical presentation being much more suggestive of a drug reaction over a de novo lymphoproliferative process.

Within 24 hours of initiation of methylprednisolone treatment patient showed dramatic improvement. The patient's fever resolved, as did her facial edema, rash, and lymphadenopathy. In the next several days her white blood cell and eosinophil counts consistently trended down to normal. At day 5 since starting methylprednisolone, the patient was

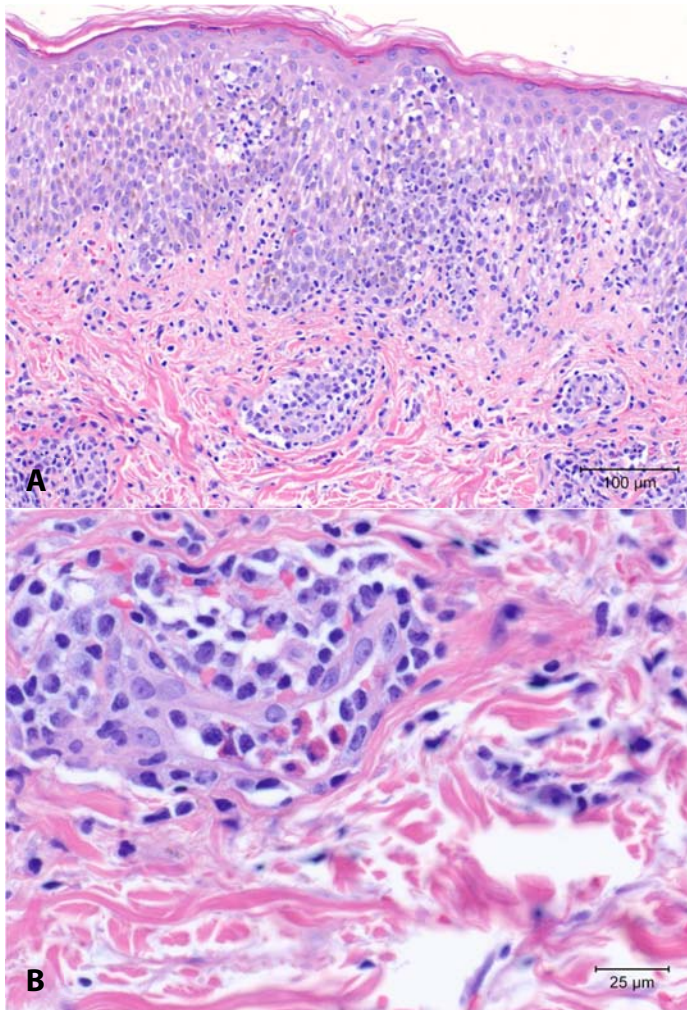


Figure 1. H&E histopathology image from forearm skin punch biopsy **A)** taken at 200× magnification, shows a relatively dense lymphocytic infiltrate with prominent exocytosis and mild dermal edema, and **B)** taken at 600× magnification, highlights the scattered eosinophils within the infiltrate.

transitioned to 40mg of oral prednisone twice daily and prescribed a 10-week tapering course. Unfortunately, the patient left against medical advice the following day, just four days prior to completing her six-week course of antibiotic treatment and was lost to follow up.

Case Discussion

The use of cyclosporine as our first choice of treatment was motivated by the growing number of reports demonstrating quick and uniformly positive results in severe DRESS syndrome cases (**Table 2**). In the case described above, the reported rapid and durable response to a short non-tapered course of

Table 1. Application of RegiSCAR criteria for Drug Rash with Eosinophilia and Systemic Symptoms and Drug-Induced Hypersensitivity Syndrome to our case [10].

Regiscar criteria	
Fever $\geq 38.5^{\circ}\text{C}$	Yes (1)
Enlarged lymph nodes	Yes (1)
Eosinophilia	
Eosinophils $\geq 0.7 \times 10^9/\text{L}$	Yes (1)
Eosinophils $\geq 1.5 \times 10^9/\text{L}$	Yes (1, additional point for total of 2))
Atypical lymphocytes	Yes (1)
Skin involvement	
Skin rash extent > 50%	Yes (1)
Skin rash suggesting dress	Yes (1)
Biopsy suggesting dress	Yes (0)
Internal organ involvement	Yes (1)
≥ 3 investigations negative for other potential causes	Yes (1)
Total score	9 Definite DRESS

cyclosporine was especially desirable given the high risk of outpatient access limitations, patient non-compliance, and overall risk of loss to follow up, challenges which would only be magnified with the required long taper of prednisone. Additionally, even in cases in which full treatment and follow up can be reliably secured, both patients and physicians may wish to refrain from using a long course of systemic corticosteroids owing to its risk of severe adverse side effects, including psychosis, diabetes, glaucoma, cataracts, osteoporosis, peptic ulcers, osteonecrosis, venous thromboembolism, and infection.

We initiated treatment with 3mg/kg/day of cyclosporine, a dose consistent with the effective range suggested in the literature of 3-5mg/kg/day (**Table 2**). The fact that our patient's condition continued to deteriorate in the three days following initiation of adequate cyclosporine therapy, but showed immediate positive response to methylprednisolone is surprising. To the best of our knowledge, this has not been reported before. Reports of the use of cyclosporine in the management of severe DRESS syndrome are anecdotal in nature and described with varying dosing regimens. With the exclusion of instances of multi-treatment resistant fatal disease, almost all

Table 2. Published case reports of cyclosporine use as monotherapy in the management of Drug Rash with Eosinophilia and Systemic Symptoms.

Reference	Causative Agent	RegiSCAR criteria Additional organ involvement		Dosage and length of treatment	Response
Harman et al. (2003), [11]	Phenytoin	Definite DRESS	Liver, questionable Lungs	4mg/kg/day for approximately 6 months	Full resolution, stable at 9-month follow up
Zulani et al. (2005), [13]	Vancomycin	Definite DRESS	Liver and kidneys	100mg, twice daily, for five days	Full resolution of skin rash after two mild recurrences and recovery of renal function, stable at 20-month follow up
Kirchhof et al. (2016), [6]	Carbamazepine	Probable DRESS	Kidneys and lungs	100mg, twice daily, for seven days	Full resolution and no recurrence
Kirchhof et al. (2016), [6]	Minocycline	Definite DRESS	Liver	5mg/kg/day divided into twice-daily dosing, for five days	Full resolution within 3 days of treatment, no recurrences
Zhang et al (2017), [12]	Mexiletine	Definite DRESS	Liver	5mg/kg/day divided into twice-daily dosing, for seven days, followed by 100mg twice daily for fourteen days and then 150 mg daily for 20 days	Full resolution and stable at 6-month follow up
Kuchel and Reedy (2018), [8]	trimethoprim/sulfamethoxazole	Definite DRESS	Liver	5mg/kg/day for a seven-day course	Improvement of the rash and normalized liver enzymes after three weeks
Hashizume et al. (2018), [7]	lamotrigine	Definite DRESS	No	3mg/kg/day for a seven-day course	Rapid resolution without relapse thereafter
Hashizume et al. (2018), [7]	Vancomycin	Definite DRESS	Yes, but not specified	3mg/kg/day for a seven-day course	Rapid resolution without relapse thereafter
Tuqan et al. (2018), [14]	Carbamazepine	Definite DRESS	Liver and colon	50mg, twice daily for an unspecified amount of days	No improvement. Once DRESS diagnosis was confirmed, treatment was transitioned to prednisone 40 mg three times a day, tapered slowly over 4 weeks. Within 2 days of starting steroids, the patient's bloody diarrhea resolved and liver enzymes declined significantly. Patient continued to recover but was lost to follow-up.

cases described of cyclosporine use as monotherapy resulted in rapid improvement and long-term resolution [6-8, 11-13].

Based on a comprehensive literature search that included PubMed, Embase and Cochrane libraries, Tuqan et al. [14] is the only other published report of a case which did not seem to respond to initiation of cyclosporine treatment but improved significantly

upon transition to prednisone. In that case, a definitive diagnosis of carbamazepine-induced DRESS syndrome in a 26-year-old man was delayed because of uncharacteristic initial presentation of subacute bloody diarrhea and concomitant treatment with lithium. A low dose of cyclosporine of 50mg twice daily was the initial choice based on a working diagnosis of lithium-induced erythrodermic psoriasis, but transition to systemic corticosteroids

occurred as soon as DRESS was confirmed by colonic biopsy. Although the authors did not recount any improvement with cyclosporine, the dose used was suboptimal, below the range of what is recommended typically for cyclosporine usage. In addition, the total number of doses the patient received was unspecified. Therefore, one may argue that this case did not represent a fair trial of cyclosporine as alternative monotherapy treatment for severe DRESS syndrome.

Although one may argue that not enough time was given to allow a response to initial cyclosporine treatment or that increased doses were not tried, we find it concerning that the patient rapidly decompensated on a previously described adequate dose of cyclosporine. Drug rash with eosinophilia and systemic symptoms may have an undulant and prolonged course, which is precisely why descriptions of cyclosporine's rapid response without need for a long course are so enticing to practitioners. Additionally, the subsequent rapid improvement in all facets of our patient's illness to corticosteroids in a dose-response type pattern strains the limits of coincidence and should be noted.

References

- Husain Z, Reddy BY, Schwartz RA. DRESS syndrome: Part I. Clinical perspectives. *J Am Acad Dermatol*. 2013;68:693 e1-14; quiz 706-8. [PMID: 23602182].
- Lam BD, Miller MM, Sutton AV, et al. Vancomycin and DRESS: A retrospective chart review of 32 cases in Los Angeles, California. *J Am Acad Dermatol*. 2017;77:973-5. [PMID: 29029908].
- Madigan LM, Fox LP. Vancomycin-associated drug-induced hypersensitivity syndrome. *J Am Acad Dermatol*. 2019;81:123-8. [PMID: 30738120].
- Criado PR, Criado RF, Avancini JM, Santi CG. Drug reaction with Eosinophilia and Systemic Symptoms (DRESS) / Drug-induced Hypersensitivity Syndrome (DIHS): a review of current concepts. *An Bras Dermatol*. 2012;87:435-49. [PMID: 22714760].
- Husain Z, Reddy BY, Schwartz RA. DRESS syndrome: Part II. Management and therapeutics. *J Am Acad Dermatol*. 2013;68:709 e1-9; quiz 18-20. [PMID: 23602183].
- Kirchhof MG, Wong A, Dutz JP. Cyclosporine Treatment of Drug-Induced Hypersensitivity Syndrome. *JAMA Dermatol*. 2016;152:1254-7. [PMID: 27438540].
- Hashizume H, Kageyama R, Kaneko Y. Short course of cyclosporin A as a treatment option for drug-induced hypersensitivity syndrome: Case reports and review of the published work. *J Dermatol*. 2018;45:e169-e70. [PMID: 29315746].
- Kuschel SL, Reedy MS. Cyclosporine treatment of drug reaction with eosinophilia and systemic symptoms (DRESS) syndrome: a case report and brief review of the literature. *Pract Dermatol*. 2018;2018:41-3. [PMID: 30574026].
- Bommersbach TJ, Lapid MI, Leung JG, et al. Management of Psychotropic Drug-Induced DRESS Syndrome: A Systematic Review. *Mayo Clin Proc*. 2016;91:787-801. [PMID: 27126302].
- Kardaun SH, Sidoroff A, Valeyrie-Allanore L, et al. Variability in the clinical pattern of cutaneous side-effects of drugs with systemic symptoms: does a DRESS syndrome really exist? *Br J Dermatol*. 2007;156:609-11. [PMID: 17300272].
- Harman KE, Morris SD, Higgins EM. Persistent anticonvulsant hypersensitivity syndrome responding to cyclosporin. *Clin Exp Dermatol*. 2003;28:364-5. [PMID: 12823292].
- Zhang ZX, Yang BQ, Yang Q, et al. Treatment of drug-induced hypersensitivity syndrome with cyclosporine. *Indian J Dermatol Venereol Leprol*. 2017;83:713-7. [PMID: 28984626].
- Zuliani E, Zwahlen H, Gilliet F, Marone C. Vancomycin-induced hypersensitivity reaction with acute renal failure: resolution following cyclosporine treatment. *Clin Nephrol*. 2005;64:155-8. [PMID: 16114793].
- Tuqan W, Lee S, Hanson J, McCarthy D. Carbamazepine-Associated Hypersensitivity Colitis. *Dig Dis Sci*. 2018;63:334-7. [PMID: 29238897].

Conclusion

When outcomes from individual cases represent the only source of information available to inform evidence-based management, the risk of positive bias is pronounced. Therefore, it is imperative that an attempt is made to distribute publication efforts equitably between successful and failed responses to treatment. The weight of the available evidence is still favorable to cyclosporine as a potentially effective monotherapy treatment for severe DRESS cases, particularly in cases in which long term use of systemic corticosteroids is of significant concern. However, our case suggests that the appropriate circumstances surrounding cyclosporine use to treat DRESS syndrome, effective dosage of the medication, and timing of improvement are still to be explored. Further research is required and clinical prudence is still necessary in selecting optimal treatment for DRESS syndrome.

Potential conflicts of interest

The authors declare no conflicts of interests.