

# UC Irvine

## Clinical Practice and Cases in Emergency Medicine

### Title

A Giant Vocal Cord Polyp Mimics Asthma Attack

### Permalink

<https://escholarship.org/uc/item/19x573kd>

### Journal

Clinical Practice and Cases in Emergency Medicine, 2(4)

### Authors

Chida, Yasayuki  
Inokuchi, Ryota  
Kumada, Yoshibumi  
[et al.](#)

### Publication Date

2018

### DOI

10.5811/cpcem.2018.7.38347

### Copyright Information

Copyright 2018 by the author(s). This work is made available under the terms of a Creative Commons Attribution License, available at <https://creativecommons.org/licenses/by/4.0/>

Peer reviewed

# A Giant Vocal Cord Polyp Mimics Asthma Attack

Yasuyuki Chida, MD\*  
 Ryota Inokuchi, MD, PhD†  
 Yoshibumi Kumada, MD, PhD\*  
 Kazuaki Shinohara, MD, PhD\*

\*Ohta Nishinouchi Hospital, Department of Emergency and Critical Care Medicine, Koriyama, Fukushima, Japan

†The University of Tokyo Hospital, Department of Emergency and Critical Care Medicine, Bunkyo-ku, Tokyo, Japan

Section Editor: Rick McPheeters, DO

Submission history: Submitted March 18, 2018; Revision received June 15, 2018; Accepted July 3, 2018

Electronically published August 15, 2018

Full text available through open access at [http://escholarship.org/uc/uciem\\_cpem](http://escholarship.org/uc/uciem_cpem)

DOI: 10.5811/cpem.2018.7.38347

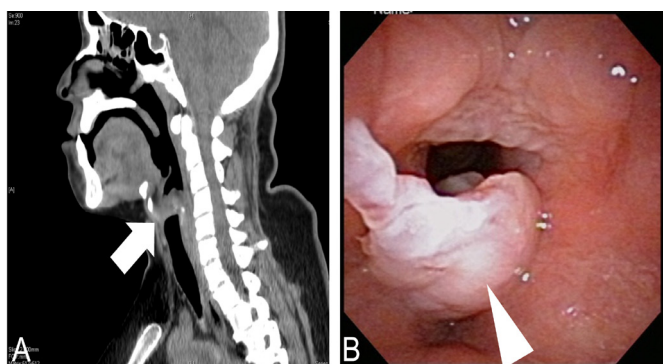
[Clin Pract Cases Emerg Med. 2018;2(4):361-362.]

## CASE PRESENTATION

A 38-year-old Japanese housewife who was a heavy smoker was admitted to our hospital because of upper respiratory distress that developed half a year prior to admission. She had no past medical history. On admission, her vital signs were normal. Physical examination showed hoarseness, stridor, wheezing, and orthopnoea, but no swelling of the tonsils, thyroid, or lymph nodes. A computed tomography of the neck revealed an enlarged tumor (Image A).

## DIAGNOSIS

Laryngeal endoscopy revealed a giant vocal cord polyp (Image B). Direct laryngoscopic resection after tracheostomy



**Image. A)** Sagittal cervical computed tomography showing a hypodense mass below the epiglottis (arrow). **B)** Laryngoscopy showing an elevated vocal polyp (arrowhead).

with local anesthesia was performed, which resulted in improved symptoms. After a week, the tracheal fenestra was closed and she was discharged without complication.

### *CPC-EM Capsule*

What do we already know about this clinical entity?  
*Vocal cord polyps are common lesions, and most are small; the common symptom is hoarseness.*

What is the major impact of the image(s)?  
*Giant vocal cord polyps can mimic asthma and may cause critical airway obstruction leading to sudden death.*

How might this improve emergency medicine practice?  
*Large vocal cord polyp can mimic asthma. Thus, physicians should consider the disease when patients present with a protracted upper respiratory distress history.*

Vocal cord polyps are common lesions, with a reported lifetime prevalence of 1.31% to 16.9% of the population.<sup>1</sup> Mechanical or chemical irritation caused by heavy smoking can result in vocal cord polyps.<sup>2</sup> Most vocal cord polyps are small lesions; thus, the common symptom is hoarseness. Occasionally, larger vocal cord polyps causing partial upper airway obstruction can mimic asthma.<sup>3,4</sup> However, giant vocal cord polyps may cause critical airway obstruction leading to sudden death.<sup>5</sup>

Documented patient informed consent and/or Institutional Review Board approval has been obtained and filed for publication of this case report.

---

**Address for Correspondence:** Ryota Inokuchi, MD, PhD, The University of Tokyo Hospital, Department of Emergency and Critical Care Medicine, 7-3-1 Hongo, Bunkyo-ku, Tokyo 113-8655, Japan. Email: inokuchir-icu@h.u-tokyo.ac.jp.

**Conflicts of Interest:** By the *CPC-EM* article submission agreement, all authors are required to disclose all affiliations, funding sources and financial or management relationships that could be perceived as potential sources of bias. The authors disclosed none.

**Copyright:** © 2018 Chida et al. This is an open access article distributed in accordance with the terms of the Creative Commons Attribution ([CC BY 4.0](http://creativecommons.org/licenses/by/4.0/)) License. See: <http://creativecommons.org/licenses/by/4.0/>

---

## REFERENCES

1. Won SJ, Kim RB, Kim JP, et al. The prevalence and factors associate with vocal nodules in general population: Cross-sectional epidemiological study. *Medicine (Baltimore)*. 2016;95(39):e4971.
2. Kusunoki T, Fujiwara R, Murata K, et al. A giant vocal fold polyp causing dyspnea. *Ear Nose Throat J*. 2009;88(12):1284-9.
3. Tsunoda A, Hatanaka A, Watabiki N, et al. Suffocation caused by large vocal cord polyps. *Am J Emerg Med*. 2004;22(1):63-4.
4. Lakin RC, Metzger WJ, Haughey BH. Upper airway obstruction presenting as exercise-induced asthma. *Chest*. 1984;86(3):499-501.
5. Tanguay J and Pollanen M. Sudden death by laryngeal polyp: a case report and review of the literature. *Forensic Sci Med Pathol*. 2009;5(1):17-21.