

UCLA

Proceedings of UCLA Health

Title

Coagulase-negative Staphylococcus Prosthetic Valve Endocarditis Complicated by Dehiscence and Abscess Formation

Permalink

<https://escholarship.org/uc/item/19v429gn>

Journal

Proceedings of UCLA Health, 25(1)

Author

Finch, William

Publication Date

2021-03-04

CLINICAL VIGNETTE

Coagulase-negative *Staphylococcus* Prosthetic Valve Endocarditis Complicated by Dehiscence and Abscess Formation

William Finch, MD

Case

A 62-year-old male with remote history of mechanical aortic valve replacement (AVR) 30 years prior, human immunodeficiency virus (HIV) infection (last viral load undetectable), hypertension, and cocaine abuse presented to the emergency department after a fall. He was unable to provide detail of the reason for the initial surgery, where it was performed, or what was done other than noting a valve was replaced. Cardiology was consulted due to concern for a possible syncopal episode leading to his fall, however the patient thought he tripped and denied loss of consciousness. His initial transthoracic echocardiogram noted systolic dysfunction (ejection fraction of 28%), a mechanical aortic valve that was not well visualized, and thickening of the ascending aorta.

After initial monitoring did not reveal a cause for syncope, discharge planning to a skilled nursing facility was initiated. However, before the patient could be discharged, he developed acute shortness of breath with fever, tachycardia, and tachypnea. Blood cultures were obtained and was started on broad-spectrum antibiotics. Within 24 hours, Gram-positive cocci were isolated from his cultures. Transesophageal echocardiography (TEE), revealed dehiscence of the mechanical valve as well as pseudoaneurysm and abscess of the mitral-aortic intervalvular fibrosa (Figure 1). There was not significant valvular insufficiency, however paravalvular flow was noted within the abscess and pseudoaneurysm. Cardiac Surgery was consulted to evaluate for re-do AVR and abscess debridement. Two weeks of antibiotic therapy was recommended prior to surgery. *Staphylococcus simulans* grew from the initial blood cultures, although the following day grew *Staphylococcus hominis* and *epidermidis*. Subsequent blood cultures were sterile.

Following antibiotic treatment, the patient underwent surgery. Surgical exploration, noted a bulging cavity below the aortic annulus between the aortic and mitral valves, consistent with an abscess cavity. The patient was placed on cardiopulmonary bypass and upon opening the aorta, graft material was seen. This was consistent with aortic root replacement at the time of his AVR. No communication between the root and the underlying cavity was noted on TEE. In order to debride and patch the abscess cavity, the entire old root needed to be dissected free and removed followed by redo aortic root replacement. Given the patient's severe systolic dysfunction, it was decided that the risks associated with this complex

operation was prohibitively high, and medical management was decided upon.

Following the operation, the Infectious Disease consultant recommended 6 weeks of vancomycin and rifampin, followed by lifelong oral levofloxacin as the initial isolate was sensitive to all tested antibiotics excepting oxacillin. He remained clinically stable without further signs of active infection, and was treated with optimal medical therapy for cardiomyopathy, aspirin and warfarin, and the above antibiotics. Following rehabilitation, he was discharged to a long-term care facility.

Discussion

We describe a case of coagulase-negative *Staphylococcus* endocarditis of a prosthetic aortic valve, resulting in root abscess formation and dehiscence of the prosthetic valve. The initial two cultures were incongruent as to whether the isolate was *S. hominis* or *S. simulans*. Prosthetic valve endocarditis is rare, occurring in 0.5% of patients in one series after a mean follow-up of 5 years, and valve dehiscence due to PVE even more rare.¹ While coagulase-negative *Staphylococcus* was the causative agent of 16% of prosthetic-valve endocarditis (PVE) cases in an international database, only a minority (18%) were caused by non-*epidermidis* CoNS.² *S. simulans* and *hominis* make up only a small proportion of non-*epidermidis* CoNS infective endocarditis.³ In CoNS prosthetic valve (PV) endocarditis, the aortic valve was involved in 47% of cases.² Prosthetic valve dehiscence was found in 17% of CoNS cases, and abscess formation in 38%, both exceeding the rates observed in *S. aureus* or *viridans* group streptococcal endocarditis. However, in-hospital mortality was the highest in patients with *S. aureus* prosthetic endocarditis, 36% compared to 24% with CoNS.

The American Heart Association and Infectious Diseases Society of America, recommend 6 weeks of vancomycin and rifampin therapy for CoNS prosthetic valve endocarditis.⁴ Surgery is often necessary. Surgical indications include heart failure resulting from dehiscence, fistula, or prosthetic valve dysfunction, persistent bacteremia after 5-7 days of antibiotics, annular abscess, high embolic risk or recurrent embolism, or fungal endocarditis. A systematic review of prosthetic valve endocarditis confirms that surgery is favored when possible.⁵ This analysis suggests the benefit of early surgery is strongest

with *S. aureus* prosthetic endocarditis and several studies reported carefully selected patients with non-*S. aureus* PVE can be treated non-surgically. Prosthetic valvular dehiscence is one of the indications for surgery in patients who are operative candidates. Dehiscence can result in severe paravalvular regurgitation, leading to heart failure.⁶ In the case described in this report, dehiscence of the valve was incomplete, therefore preventing the development of paravalvular regurgitation.

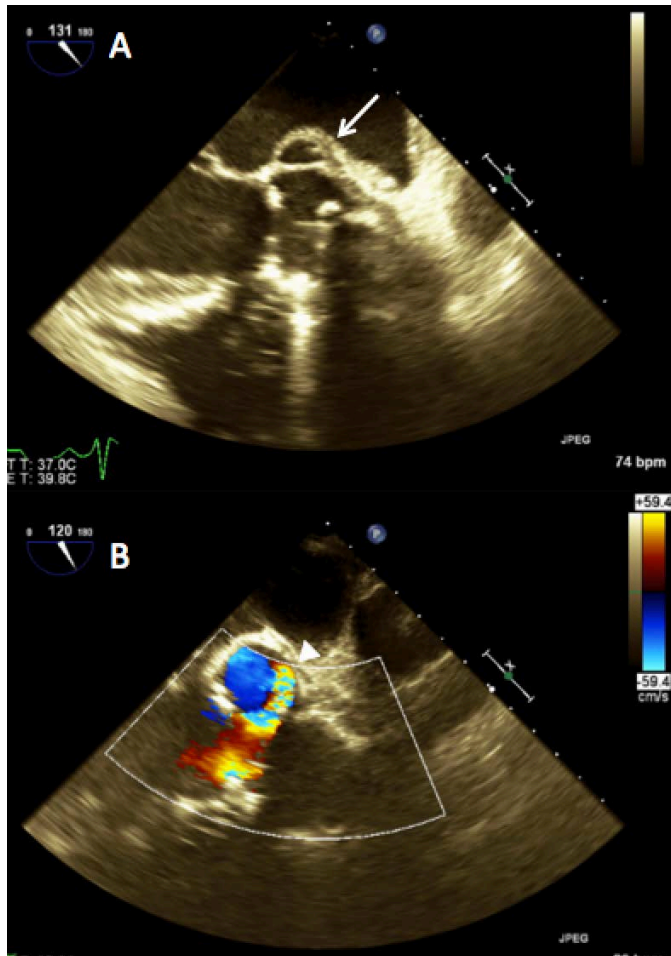


Figure 1: a) midesophageal long axis view of aortic valve with dehiscence of the mechanical valve, pseudoaneurysm and abscess of the mitral-aortic intervalvular fibrosa (arrow), b) color flow demonstrating flow within the pseudoaneurysm/abscess cavity (arrowhead)

REFERENCES

1. **Tominaga R, Kurisu K, Ochiai Y, Tomita Y, Masuda M, Morita S, Yasui H.** A 10-year experience with the Carbomedics cardiac prosthesis. *Ann Thorac Surg.* 2005 Mar;79(3):784-9. doi: 10.1016/j.athoracsur.2004.08.067. PMID: 15734377.
2. **Chu VH, Miro JM, Hoen B, Cabell CH, Pappas PA, Jones P, Stryjewski ME, Anguera I, Braun S, Muñoz P, Commerford P, Tornos P, Francis J, Oyonarte M, Selton-Suty C, Morris AJ, Habib G, Almirante B, Sexton DJ, Corey GR, Fowler VG Jr; International**

Collaboration on Endocarditis-Pro prospective Cohort Study Group. Coagulase-negative staphylococcal prosthetic valve endocarditis--a contemporary update based on the International Collaboration on Endocarditis: prospective cohort study. *Heart.* 2009 Apr;95(7):570-6. doi: 10.1136/hrt.2008.152975. Epub 2008 Oct 24. PMID: 18952633.

3. **Chu VH, Cabell CH, Abrutyn E, Corey GR, Hoen B, Miro JM, Olaison L, Stryjewski ME, Pappas P, Anstrom KJ, Eykyn S, Habib G, Benito N, Fowler VG Jr; International Collaboration on Endocarditis Merged Database Study Group.** Native valve endocarditis due to coagulase-negative staphylococci: report of 99 episodes from the International Collaboration on Endocarditis Merged Database. *Clin Infect Dis.* 2004 Nov 15;39(10):1527-30. doi: 10.1086/424878. Epub 2004 Oct 27. PMID: 15546091.
4. **Baddour LM, Wilson WR, Bayer AS, Fowler VG Jr, Tleyjeh IM, Rybak MJ, Barsic B, Lockhart PB, Gewitz MH, Levison ME, Bolger AF, Steckelberg JM, Baltimore RS, Fink AM, O'Gara P, Taubert KA; American Heart Association Committee on Rheumatic Fever, Endocarditis, and Kawasaki Disease of the Council on Cardiovascular Disease in the Young, Council on Clinical Cardiology, Council on Cardiovascular Surgery and Anesthesia, and Stroke Council.** Infective Endocarditis in Adults: Diagnosis, Antimicrobial Therapy, and Management of Complications: A Scientific Statement for Healthcare Professionals From the American Heart Association. *Circulation.* 2015 Oct 13;132(15):1435-86. doi: 10.1161/CIR.0000000000000296. Epub 2015 Sep 15. Erratum in: *Circulation.* 2015 Oct 27;132(17):e215. Erratum in: *Circulation.* 2016 Aug 23;134(8):e113. Erratum in: *Circulation.* 2018 Jul 31;138(5):e78-e79. PMID: 26373316.
5. **Attaran S, Chukwumeka A, Punjabi PP, Anderson J.** Do all patients with prosthetic valve endocarditis need surgery? *Interact Cardiovasc Thorac Surg.* 2012 Dec;15(6):1057-61. doi: 10.1093/icvts/ivs372. Epub 2012 Aug 24. PMID: 22922449; PMCID: PMC3501300.
6. **Krishna RK, Casanova P, Larrauri-Reyes M, Santana O.** Complete dehiscence and unseated prosthetic aortic valve causing severe aortic insufficiency: an unusual complication of prosthetic valve endocarditis. *BMJ Case Rep.* 2014 Oct 24;2014:bcr2014206925. doi: 10.1136/bcr-2014-206925. PMID: 25344381; PMCID: PMC4208107.