

# UC Davis

## UC Davis Previously Published Works

### Title

A Community Transmitted Case of Severe Acute Respiratory Distress Syndrome due to SARS CoV2 in the United States

### Permalink

<https://escholarship.org/uc/item/19r6g1qv>

### Journal

Clinical Infectious Diseases, 71(16)

### ISSN

1058-4838

### Authors

Sanville, Bradley  
Corbett, Rebecca  
Pidcock, Wesley  
et al.

### Publication Date

2020-11-19

### DOI

10.1093/cid/ciaa347

Peer reviewed

# **A Community Transmitted Case of Severe Acute Respiratory Distress Syndrome due to SARS CoV2 in the United States**

Bradley Sanville, M.D.<sup>1</sup>

Rebecca Corbett, D.O.<sup>1</sup>

Wesley Pidcock, D.O.<sup>1</sup>

Kaitlyn Hardin, M.D.<sup>2</sup>

Christian Sebat, D.O.<sup>1</sup>

Minh-Vu Nguyen, M.D., M.Sc.<sup>2</sup>

George R. Thompson III, M.D.<sup>2</sup>

Angela Haczku, M.D., Ph.D.<sup>1\*</sup>

Michael Schivo, M.D.<sup>1\*</sup>

Stuart Cohen, M.D.<sup>2\*</sup>

\*Co-Senior authors

<sup>1</sup>University of California, Davis, School of Medicine

Division of Pulmonary, Critical Care, and Sleep Medicine

<sup>2</sup>University of California, Davis, School of Medicine

Division of Infectious Disease

Corresponding author:

Dr. Haczku or Dr. Schivo at the Division of Pulmonary, Critical Care, and Sleep Medicine,

[haczku@ucdavis.edu](mailto:haczku@ucdavis.edu), [mschivo@ucdavis.edu](mailto:mschivo@ucdavis.edu) or Dr. Cohen at the Division of Infectious

Disease, [stcohen@ucdavis.edu](mailto:stcohen@ucdavis.edu)

## **Summary**

The current novel coronavirus (SARS CoV2) outbreak, which was identified in December 2019 in Wuhan, Hubei, China has spread rapidly causing a significant public health crisis worldwide <sup>1</sup>. The focus of public health measures in the United States has been on individuals with known at risk travel or contacts with at risk individuals <sup>2</sup>. While person-to-person transmission without clear exposure has been observed in other countries <sup>3</sup>, we present a case of the first community transmission of SARS CoV2 in the United States.

## History and Findings on Admission

A patient in their 40s presented to an outside facility with 3-4 days of flu-like symptoms. Chest x-ray upon admission showed a right upper lobe consolidative process with air-bronchograms (Figure 1). Computed tomography revealed a dense consolidation with air-bronchograms in the right upper lobe with minimal areas of ground glass, primarily in the right middle lobe. The remaining lung parenchyma was normal in appearance. Within 24 hours of admission, her respiratory status deteriorated, and she required intubation. Follow-up imaging showed bilateral dense alveolar filling.

She progressed to develop the acute respiratory distress syndrome (ARDS) with refractory hypoxemia requiring a fraction of inspired oxygen (FiO<sub>2</sub>) as high as 100% with a positive end expiratory pressure (PEEP) of 16 despite intermittent neuromuscular blockade. She developed septic shock requiring large volume crystalloid resuscitation and high dose norepinephrine. Antibiotics were expanded to linezolid, piperacillin-tazobactam, and azithromycin. She underwent bronchoscopy with report from the treatment team of negative bacterial cultures after two days. A respiratory viral panel was in process at time of transfer.

The patient was transferred to our facility for consideration of extracorporeal life support (ECLS) given refractory hypoxemia on hospital day 5. Upon arrival the patient had a heart rate of 123 beats per minute and a temperature of 36.9°C. The blood pressure was 117/61, which was maintained by a norepinephrine drip at 0.5 mcg/kg/min. Peripheral saturation of oxygen was 91% on an FiO<sub>2</sub> of 90%, respiratory rate of 26 breaths per minute, a PEEP of 16 cmH<sub>2</sub>O and tidal volumes set at 270 cc (6 cc/kg of ideal body weight), while sedated with propofol and fentanyl infusions. Plateau pressure was 28 cmH<sub>2</sub>O. Initial arterial blood gas showed a pH of 7.28, partial pressure of CO<sub>2</sub> of 55 mmHg, and partial pressure of O<sub>2</sub> of 67 mmHg with a PaO<sub>2</sub>/FiO<sub>2</sub> ratio of 74 consistent with severe ARDS. Chemistry panel showed hyponatremia of 126 mEq per liter, chloride of 94 mEq per liter, and bicarbonate level of 21 mEq per liter with all other values being within normal limits. Complete blood count showed a

white blood cell count of  $7.3 \times 10^3/\text{mm}^3$  and hemoglobin of 10.4 g per deciliter. Lactic acid was within normal limits.

### **Clinical Course**

The patient was immediately placed on droplet and contact precautions, and a respiratory viral panel, respiratory culture, and blood cultures sent. She underwent prone positioning and therapeutic paralysis with cisatracurium to maintain ventilator synchrony for treatment of her severe ARDS. A vasopressin infusion was started for further blood pressure support. Given her critical condition in light of the current outbreak, a suspicion for a potential SARS CoV2 infection was raised. But the patient had no travel to high-risk countries and no contact with an individual with high-risk travel thus, as she did not meet the current Centers for Disease Control (CDC) criteria, testing was not pursued by public health officials. A SARS CoV2 infection was therefore low on our initial differential diagnosis and a typical bacterial infection was thought to be more likely.

After 48-72 hours of admission, however, testing failed to indicate a clear infectious source with the final bronchoscopy cultures from the outside hospital and the viral panel and cultures sent from our hospital at admission all returning negative. Further history obtained through family interviews revealed that although she did not have known contact with any infected individual, the patient worked in a commercial facility with a high volume of customers within the same county as the facility that had been housing repatriated individuals with SARS CoV2 infection. This raised the possibility that SARS CoV2 could be acquired through community spread of the disease. Our speculation was supported by the concurrent publication of a locally transmitted COVID-19 case, reported from Taiwan<sup>3</sup>. For these reasons our patient was reviewed again and at that time COVID-19 testing was recommended by the CDC and the patient was placed under strict airborne and contact precautions. The SARS CoV2 test returned positive two days later (Figure 2). Remdesivir (an investigational anti-viral nucleotide analog prodrug) was started as an intravenous

infusion within 36 hours of diagnosis. No adverse events were observed in association with this treatment.

To date, no source of exposure has been identified for this patient. Therefore, we conclude that she must have had community acquired disease. Although her course was complicated by acute renal failure, dialysis was never required and she did not require ECLS. She improved clinically following a week of therapy, with a significant reduction in ventilator support and interval improvement in her oxygenation and chest radiograph findings (Figure 3). She was successfully extubated 14 days after her hospital transfer and is currently in stable condition.

As a result of the positive SARS CoV2 test, healthcare workers who were exposed to the patient were required to undergo home quarantine with symptom and fever monitoring. Two healthcare workers in contact with the patient at the outside hospital have subsequently tested positive for SARS CoV2. No transmission has been noted to healthcare workers at our institution.

## **Discussion**

This case represents the first known instance of community transmission of SARS CoV2 in the United States, with significant public health implications. Diagnosis of COVID-19 is currently confirmed with PCR based testing of appropriate respiratory samples. At the time of the patient's presentation, CDC guidelines restricted testing to those patients with mild to moderate symptoms who either travelled to Hubei Province, or had direct contact with a positive case, or those with severe symptoms who travelled to mainland China <sup>4</sup>. Despite our patient's severe disease, given the absence of travel or known exposure, she did not meet the criteria for testing. Since then, because of this case and other suspected community acquired SARS CoV2 cases, the CDC has updated these guidelines. Now any patient with severe disease (e.g. ARDS or pneumonia) requiring hospitalization without an explanatory diagnosis can be tested even if no clear source of exposure is identified. Several other high-

risk countries - Iran, South Korea, Italy, and Japan - have since been included into the epidemiological risk assessment in addition to China, which was the only one originally listed<sup>4</sup>.

Our case highlights significant knowledge gaps in the diagnosis and management of this disease. Without clear risk factors, the patient's infection first masqueraded as a community acquired pneumonia given the initial predominantly unilateral lobar involvement on chest imaging. This radiographic presentation is atypical. A recent article reviewing the CT scans of 21 Chinese patients infected with SARS CoV2 showed the predominant imaging finding in 18/21 patients to be a mix of consolidation and ground glass opacities involving two or more lobes with 76% of patients having bilateral involvement<sup>5</sup>. Single lobe opacities occurred in only 3/21 patients and consolidation alone without ground glass opacities occurred in no patients. In addition, a recent retrospective review of 1099 Chinese patients noted that the predominant radiographic findings were ground glass opacities without mention of dense consolidations being present<sup>6</sup>. Early identification is confounded by delayed radiographic presentations. Only 59% of patients subsequently diagnosed with COVID-19 had an abnormal radiograph on presentation in a review of 21 patients, with imaging findings reaching peak severity 10 days after symptom onset<sup>7</sup>. This was similarly noted in a review of 121 patients where bilateral lung involvement only presented in 10/36 patients in the first 0-2 days from symptom onset, but in 22/25 of patients who presented 6-12 days after symptom onset<sup>8</sup>. There are likely many patients that present early in their illness course with relatively normal or minimally abnormal imaging who may progress over time.

While the majority of COVID-19 cases were identified within our patient's age group (15-49 years), only 18.5% of severe cases were from this age group. Those over the age of 65 comprised 49.2% of severe cases<sup>6,9</sup>. In a large review of 73,314 cases from China the authors reported 5% of all cases meeting critical illness (i.e. shock, respiratory failure, and/or multi-organ failure) with a case-fatality rate of 49% in that subgroup<sup>9</sup>. Health care personnel that became infected suffered a similar amount of severe and critically ill cases as the

general population. Overall, these reviews note a case fatality rate of 1.40-3.46%, though this may be considerably lower when accounting for a likely large number of mild or asymptomatic patients that were not tested<sup>6,9,10</sup>. At present, information regarding the epidemiology and clinical features of pneumonia caused by SARS CoV2 is controversial. Similarly to other viral diseases, an early prediction model for COVID-19 mortality, the MuLBSTA (Multilobular infiltration, hypo-Lymphocytosis, Bacterial coinfection, Smoking history, hyper-Tension and Age>60 years), score was suggested<sup>11</sup>. Our patient however, being without comorbidities and of a relatively young age, falls outside of the most identified at-risk groups for severe disease indicating that the applicability of the MuLBSTA score for predicting the risk of mortality in 2019-nCoV infection requires further investigation<sup>12</sup>.

Once the diagnosis of COVID-19 was confirmed, our patient was placed on remdesivir infusion, an experimental drug, given under an Investigational New Drug (IND) program<sup>13</sup>, provided by Gilead for this purpose. Currently, there are no approved specific antiviral therapies for coronavirus infections in humans. Previous attempts at treating both SARS-CoV and MERS-CoV patients with approved antivirals (ribavirin and lopinavir-ritonavir), corticosteroids, or interferons, have not been effective in randomized controlled trials<sup>14</sup>. At UC Davis, our colleagues showed that the nucleoside ribose analogue GS-441524A and its prodrug GS-5734 (remdesivir) strongly inhibited coronavirus infection in cats<sup>15</sup>. Investigators at Gilead reported that GS-5734 suppressed both epidemic and zoonotic coronaviruses and DeWit and colleagues from the NIH, Gilead, and Columbia University successfully treated rhesus macaques against a model of MERS<sup>13</sup>. Whether remdesivir is effective against human COVID-19 is not known. The ability to provide early testing and diagnosis would certainly accelerate clinical trial efforts to investigate this compound.

As will any novel infection, our knowledge evolves over time as more data from affected individuals is collected and analyzed. Given changes in epidemiologic risk and potential for atypical presentations, the challenge for clinicians to identify whom to test becomes more difficult. This virus has a prolonged incubation time (2.1-11.1 days in the most optimistic



estimate of 88 Chinese patients) with a wide range of disease severity <sup>16</sup>. As we have reviewed, its radiographic appearance can be quite varied both in time from symptom onset and overall appearance. A wide variety of symptomology and radiographic appearances create difficulty for providers to identify COVID-19 and differentiate it from other more common respiratory infections. It has also been shown that human coronaviruses persist on inanimate surfaces for up to 9 days, thus, can be picked up without close contact to an infected person <sup>17</sup>. As noted in a recent editorial, diagnosis becomes even more difficult considering the likelihood of a large number of mild or asymptomatic patients who are not formally identified with a SARS CoV2 infection <sup>18,19</sup>. Because there are individuals in the community that are not manifesting severe enough symptoms to warrant presenting to healthcare providers, we should expect community spread to occur more frequently, challenging our ability to adequately contain the spread of SARS CoV2.

Our case has influenced national health policies for revising screening criteria. Nonetheless, to tackle the outstanding burning issues (true prevalence and mortality rate, impact on vulnerable populations, seasonality, vaccine and treatment development), there remains a desperate need for earlier detection and a more widespread, faster and cheaper availability of testing for COVID-19 patients.

**Potential conflicts of Interest:**

S.C.: Remdesivir was supplied via compassionate use protocol by Gilead Pharmaceuticals;  
A.H. reports grants from LignaMed, outside the submitted work; R.C., G.T., K.H., B.S., W.P.,  
M.-V.N., G.S., M.S., have no conflicts.

## References

1. WHO. Pneumonia of unknown cause – China. WHO Disease Outbreak News 2020;Emergencies preparedness, response:<https://www.who.int/csr/don/05-january-2020-pneumonia-of-unknown-cause-china/en/>.
2. CDC. Update and Interim Guidance on Outbreak of 2019 Novel Coronavirus (2019-nCoV). CDC Health Alert Network 2020;CDCHAN-00427:<https://emergency.cdc.gov/han/han00427.asp>.
3. Liu YC, Liao CH, Chang CF, Chou CC, Lin YR. A Locally Transmitted Case of SARS-CoV-2 Infection in Taiwan. N Engl J Med 2020.
4. CDC. Evaluating and Reporting Persons Under Investigation (PUI). Coronavirus Disease 2019 (COVID-19) 2020:<https://www.cdc.gov/coronavirus/2019-ncov/hcp/clinical-criteria.html>.
5. Chung M, Bernheim A, Mei X, et al. CT Imaging Features of 2019 Novel Coronavirus (2019-nCoV). Radiology 2020:200230.
6. Guan WJ, Ni ZY, Hu Y, et al. Clinical Characteristics of Coronavirus Disease 2019 in China. N Engl J Med 2020.
7. Pan F, Ye T, Sun P, et al. Time Course of Lung Changes On Chest CT During Recovery From 2019 Novel Coronavirus (COVID-19) Pneumonia. Radiology 2020:200370.
8. Bernheim A, Mei X, Huang M, et al. Chest CT Findings in Coronavirus Disease-19 (COVID-19): Relationship to Duration of Infection. Radiology 2020:200463.
9. Wu Z, McGoogan JM. Characteristics of and Important Lessons From the Coronavirus Disease 2019 (COVID-19) Outbreak in China: Summary of a Report of 72314 Cases From the Chinese Center for Disease Control and Prevention. JAMA 2020.
10. Wang Y, Wang Y, Chen Y, Qin Q. Unique epidemiological and clinical features of the emerging 2019 novel coronavirus pneumonia (COVID-19) implicate special control measures. J Med Virol 2020.

11. Khot WY, Nadkar MY. The 2019 Novel Coronavirus Outbreak - A Global Threat. *J Assoc Physicians India* 2020;68:67-71.
12. Chen N, Zhou M, Dong X, et al. Epidemiological and clinical characteristics of 99 cases of 2019 novel coronavirus pneumonia in Wuhan, China: a descriptive study. *Lancet* 2020;395:507-13.
13. de Wit E, Feldmann F, Cronin J, et al. Prophylactic and therapeutic remdesivir (GS-5734) treatment in the rhesus macaque model of MERS-CoV infection. *Proc Natl Acad Sci U S A* 2020.
14. Zumla A, Chan JF, Azhar EI, Hui DS, Yuen KY. Coronaviruses - drug discovery and therapeutic options. *Nat Rev Drug Discov* 2016;15:327-47.
15. Murphy BG, Perron M, Murakami E, et al. The nucleoside analog GS-441524 strongly inhibits feline infectious peritonitis (FIP) virus in tissue culture and experimental cat infection studies. *Vet Microbiol* 2018;219:226-33.
16. Backer JA, Klinkenberg D, Wallinga J. Incubation period of 2019 novel coronavirus (2019-nCoV) infections among travellers from Wuhan, China, 20-28 January 2020. *Euro Surveill* 2020;25.
17. Kampf G, Todt D, Pfaender S, Steinmann E. Persistence of coronaviruses on inanimate surfaces and their inactivation with biocidal agents. *J Hosp Infect* 2020;104:246-51.
18. Fauci AS, Lane HC, Redfield RR. Covid-19 - Navigating the Uncharted. *N Engl J Med* 2020.
19. Bai Y, Yao L, Wei T, et al. Presumed Asymptomatic Carrier Transmission of COVID-19. *JAMA* 2020.

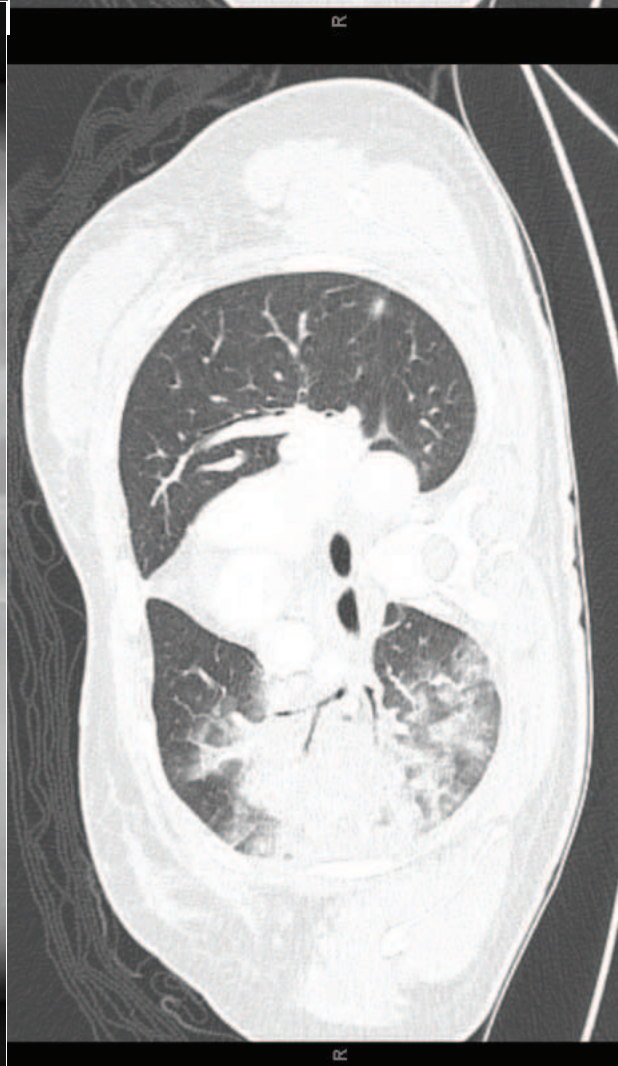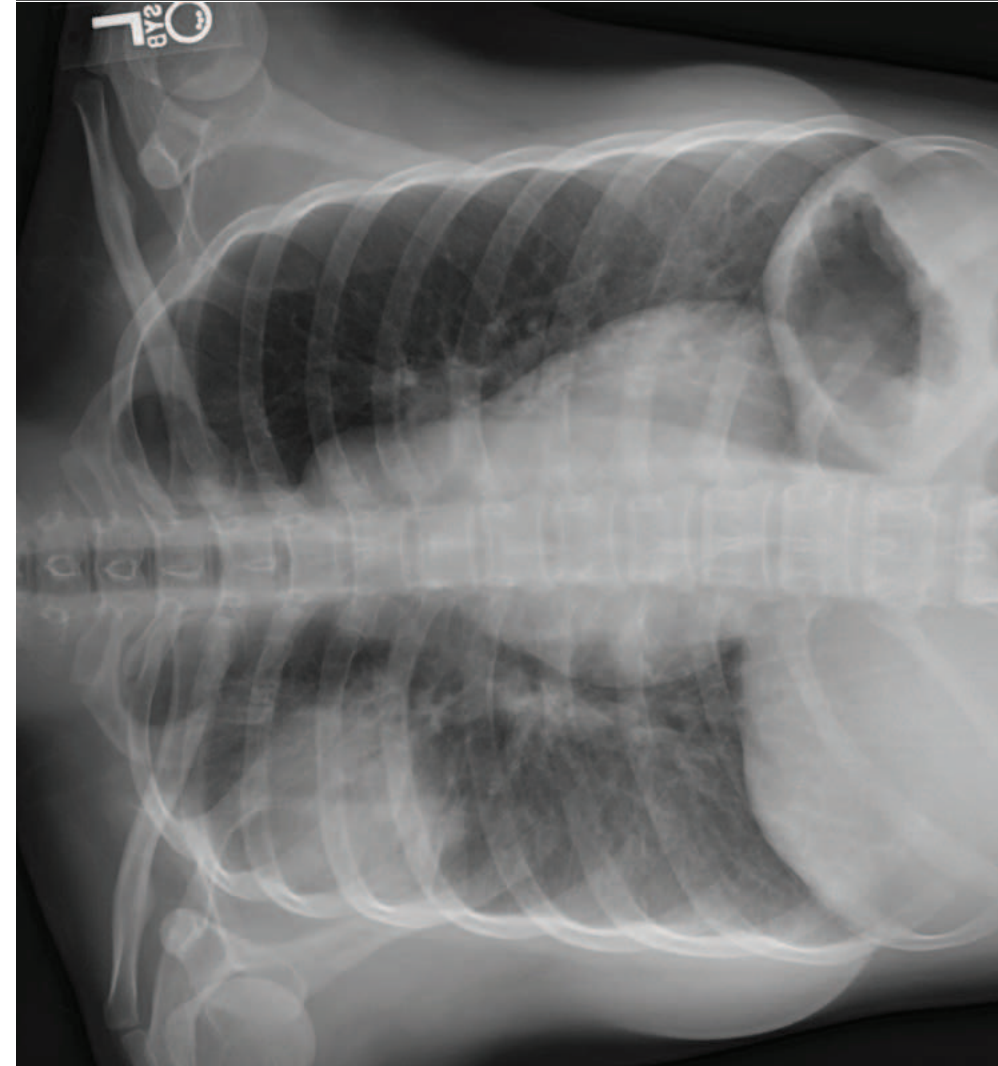
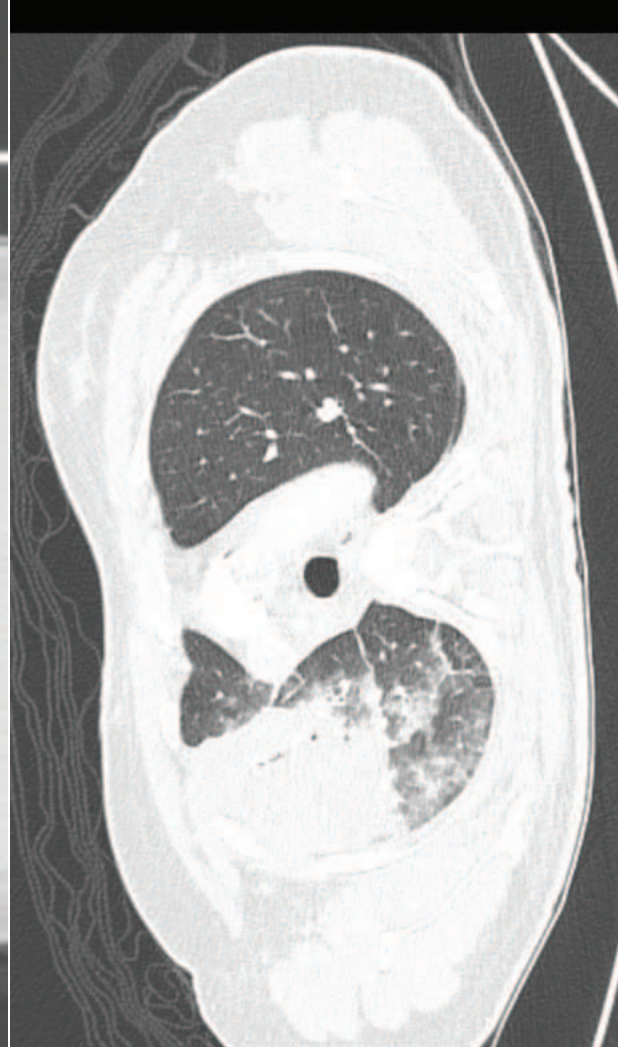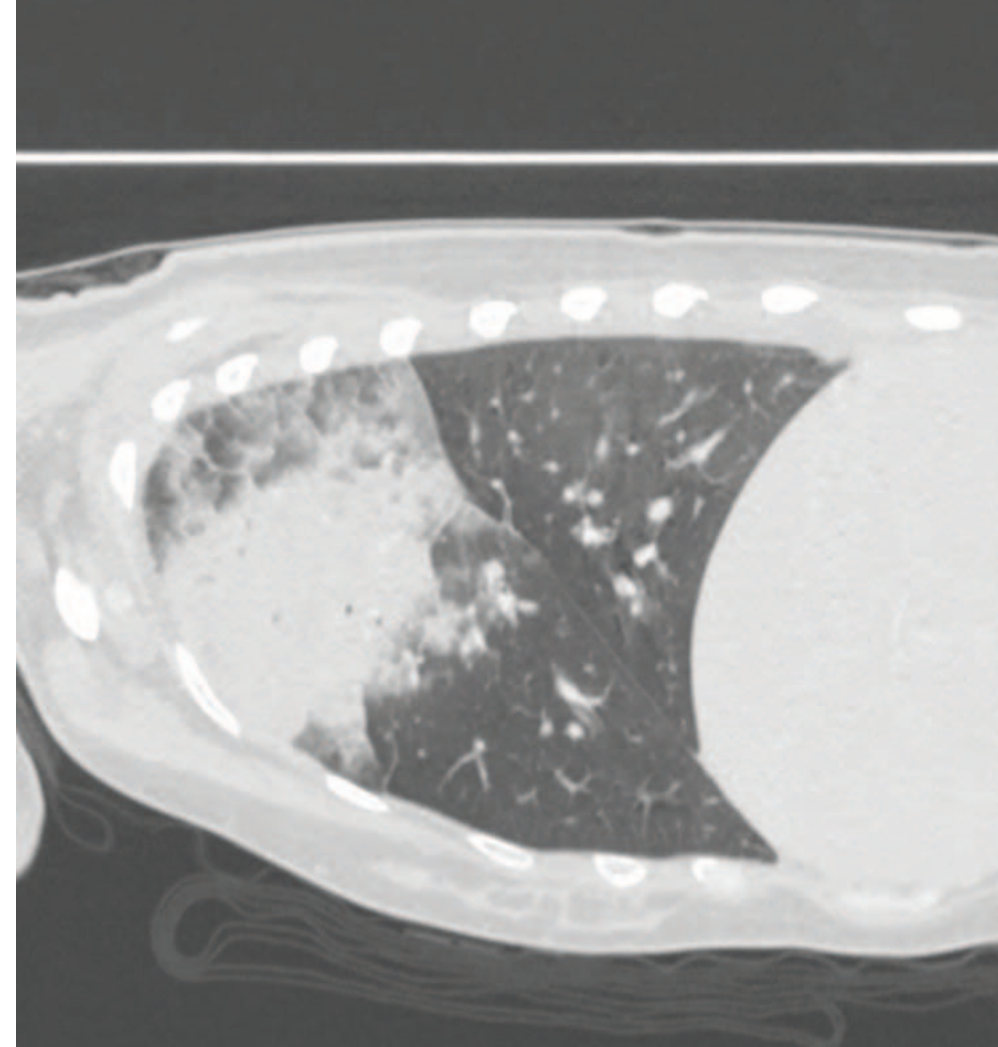
## Figure legends

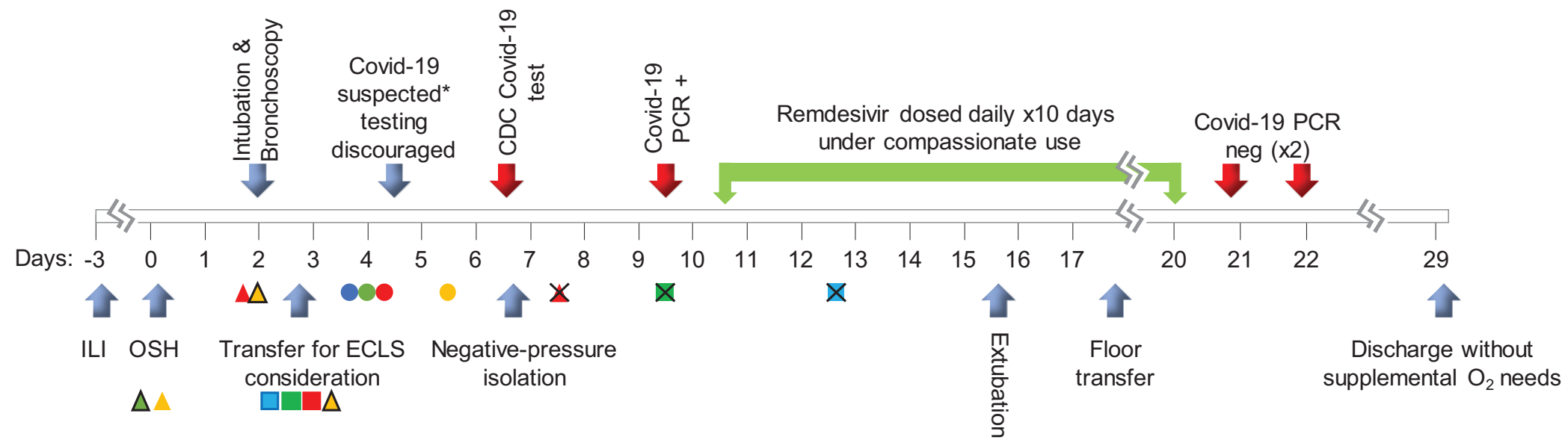
**Figure 1. Initial chest X-ray and axial and sagittal views from computed tomography scan.** The images show dense consolidation within the right upper lobe with air bronchograms with some peripheral ground glass opacity. There is a minimal extension into the right middle lobe.

**Figure 2. Timeline of US SARS CoV2 community transmission index case.**

Abbreviations: ILI, influenza-like illness; OSH, outside hospital admission; CT, computed tomography; RUL, right upper pulmonary lobe; ECLS, extra-corporeal life support; ARDS, acute respiratory distress syndrome; NMB, neuromuscular blocking agents; LTVV, low tidal volume ventilation; RVP, PCR-based respiratory viral panel; AKI, acute kidney injury; LFT, liver function tests; CDPH, California Department of Public Health; CDC, Centers for Disease Control \*Collateral information of possible exposure to a recently-cleared traveler from China, though testing discouraged due to a lack of primary travel history

**Figure 3. Chest radiographs from day of transfer (left) and 14 days later (right).** The images show a significant improvement in ARDS.





- ▲ CT Chest with a RUL consolidation
- ▲ Broad-spectrum antibiotics started
- ▲ Broad-spectrum antibiotics adjusted
- ▲ Shock requiring vasopressors (X Shock resolved)
- Prone positioning for severe ARDS (X Prone positioning stopped)
- NMB use ( X NMB use stopped)
- LTVV
- RVP negative
- AKI developing (and subsequently normalized)
- LFTs elevating (and subsequently normalized)
- Bacterial cultures negative

