

## **UC Irvine**

### **Journal of Education and Teaching in Emergency Medicine**

#### **Title**

Evaluation of Snake Bites with Bedside Ultrasonography

#### **Permalink**

<https://escholarship.org/uc/item/17z498q9>

#### **Journal**

Journal of Education and Teaching in Emergency Medicine, 3(2)

#### **Authors**

Jolissaint, Josef E  
Salerno, Alexis  
Sheets, Daniel

#### **Publication Date**

2018

#### **DOI**

10.5070/M532038693

#### **Copyright Information**

Copyright 2018 by the author(s). This work is made available under the terms of a Creative Commons Attribution License, available at <https://creativecommons.org/licenses/by/4.0/>

Peer reviewed

## Evaluation of Snake Bites with Bedside Ultrasonography

Josef E Jolissaint\*, Alexis Salerno, MD<sup>^</sup> and Daniel Sheets, MD<sup>^</sup>

\*University of Maryland School of Medicine, Baltimore, MD

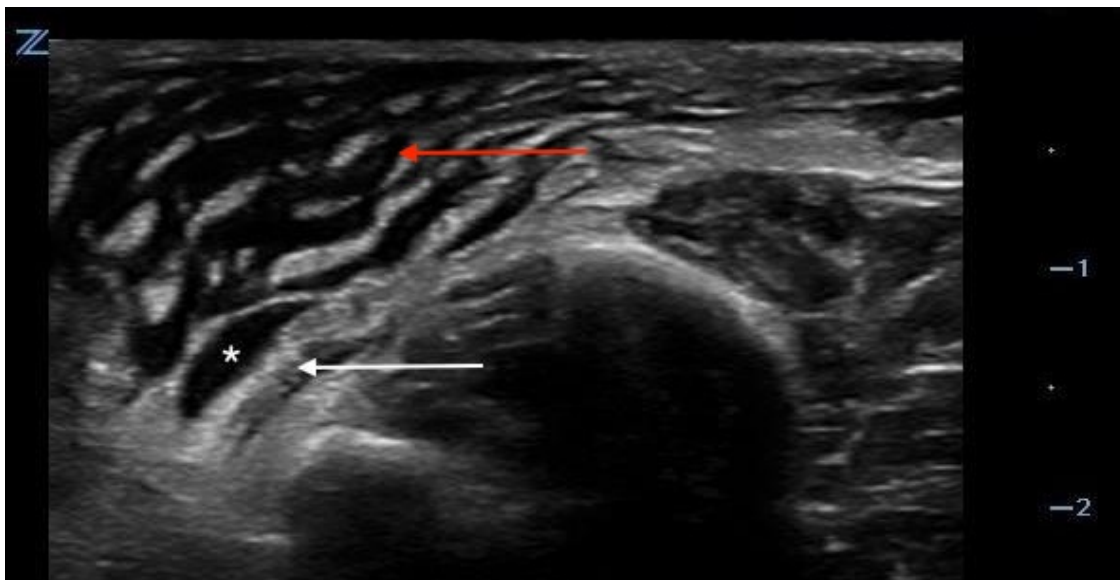
<sup>^</sup>University of Maryland, Department of Emergency Medicine, Baltimore, MD

Correspondence should be addressed to Daniel Sheets, MD at [dsheets@em.umaryland.edu](mailto:dsheets@em.umaryland.edu)

Submitted: October 25, 2017; Accepted: February 2, 2018; Electronically Published: April 15, 2018; <https://doi.org/10.21980/J84S7D>

Copyright: © 2018 Jolissaint, et al. This is an open access article distributed in accordance with the terms of the Creative Commons Attribution (CC BY 4.0) License.

See: <http://creativecommons.org/licenses/by/4.0/>



**History of present illness:** While watering his lawn, a 36-year-old man felt two sharp bites to his bilateral ankles. He reports that he then saw a light brown, 2-foot snake slither away from him. He came to the emergency department because of pain and swelling in his ankles and inability to bear weight. Physical examination revealed bilateral ankle swelling and puncture marks on his left lateral heel and medial right ankle. Palpation, passive flexion and extension elicited severe pain bilaterally. Blood work including prothrombin time (PT), partial thromboplastin time (PTT), international normalized ratio (INR), and fibrinogen were within normal limits. Consultation with Poison Control indicated the snake was likely a copperhead, which is a venomous snake whose bites rarely require antivenin.

**Significant findings:** In this case, ultrasonography of the lateral surface of the left foot revealed soft tissue edema (*red arrow*) and fluid collection (*white asterisk*) adjacent to the extensor tendon (*white arrow*). The edematous area resembles cobblestones, with hypoechoic areas of fluid spanning relatively hyperechoic fat

lobules. The tendon is surrounded by anechoic fluid, expanding the potential space in the sheath. No hyperechoic foreign objects were noted.

**Discussion:** The patient was diagnosed with soft tissue injury and extensor tenosynovitis after a snake envenomation. Snake venom contains metalloproteinases and other enzymatic proteins that cause local tissue edema and necrosis.<sup>1</sup> After a snake bite, ultrasound can be used to assess for retained fangs, soft tissue edema, tendon sheath fluid, muscle fasciculation, and injury to deeper musculature that may not be readily apparent on physical exam.<sup>2,3</sup> Most patients with tenosynovitis will recover with immobilization of the joint and non-steroidal anti-inflammatory medications.<sup>4</sup> Rarely, the tendon may become infected requiring antibiotics and surgical intervention.<sup>4</sup>

**Topics:** Ultrasound, snake envenomation, snake bite, tenosynovitis.

#### References:

1. Aggarwal P, Jamshed N. What's new in emergencies, trauma, and shock? Snake envenomation and organophosphate poisoning in the emergency department. *J Emergency Trauma Shock*. 2008;1(2):59-62. doi: 10.4103/0974-2700.43180
2. Voha R, Rangan C, Bengiamin R. Sonographic signs of snakebite. *Clin Toxicol*. 2014;52(9):948-951. doi: 10.3109/15563650.2014
3. Rushton WF, Vakkalanka JP, Moak JH, Charlton NP. Negative predictive value of excluding an embedded snake foreign body by ultrasonography. *Wilderness Environ Med*. 2015;26(2):227-231. doi: 10.1016/j.wem.2014.12.015
4. Tubbs RJ, Savitt DL, Suner S. Extremity Conditions. In: Knoop KJ, Stack LB, Storrow AB, Thurman R. eds. *The Atlas of Emergency Medicine*. 4<sup>th</sup> ed. New York, NY: McGraw-Hill; 2015:355-357.