

UC Davis
Dermatology Online Journal

Title

Candida parapsilosis of the nail-bed without onychomycosis

Permalink

<https://escholarship.org/uc/item/17v3f8mk>

Journal

Dermatology Online Journal, 20(12)

Authors

Rieder, Evan
Hu, Stephanie W
Meehan, Shane A
et al.

Publication Date

2015

DOI

10.5070/D32012025059

Copyright Information

Copyright 2015 by the author(s). This work is made available under the terms of a Creative Commons Attribution-NonCommercial-NoDerivatives License, available at <https://creativecommons.org/licenses/by-nc-nd/4.0/>

Peer reviewed

Case Presentation

Candida parapsilosis of the nail-bed without onychomycosis

Evan Rieder MD, Stephanie W. Hu MD, Shane A. Meehan MD, and Chris Adigun MD

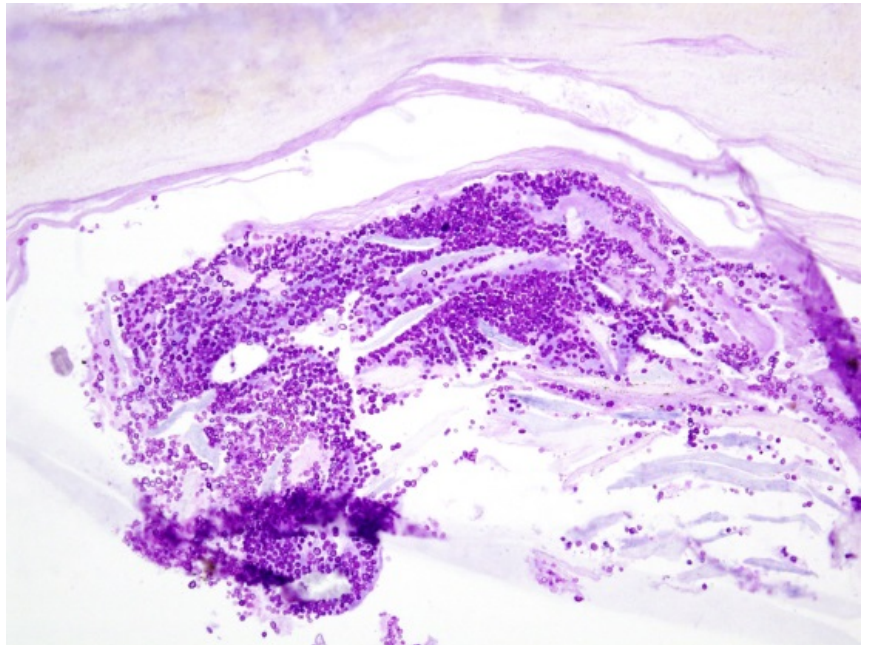
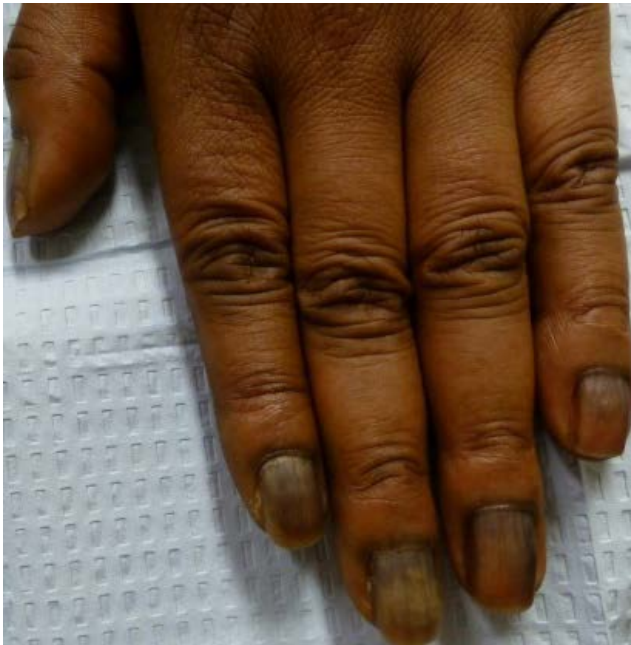Dermatology Online Journal 20 (12): 10

New York University School of Medicine

Special Guest Editor: Nicholas A. Soter, MD

Abstract

Candida parapsilosis is an emerging fungal pathogen that was once thought to be solely a colonizing organism. *C. parapsilosis* is increasingly becoming reported as the most common *Candida* species that causes onychomycosis. Clinical findings include typically severe dystrophy of the nail fold and plate as well as thickening and fragmentation of the plate, particularly in the distal plate. We present a unique case of *C. parapsilosis* infection of the nail bed without infection of the nail plate and with twenty-nail melanonychia



Case synopsis

History: A 54-year-old woman presented to New York University Dermatologic Associates with a six-month history of the acute onset of darkening of her fingernails. She had no antecedent trauma, no local or systemic symptoms, and no pain, erythema, or discharge periungually. She had seen another provider who obtained a negative periodic acid-Schiff (PAS) stain of a biopsied nail plate. Her nails demonstrated no improvement with one month of topical econazole and one month of daily oral terbinafine. Past medical history included celiac disease, hypertension, and hyperlipidemia. Her medications included diltiazem and ezetimibe/simvastatin, both of which had remained unchanged in dose for greater than five years. She denied any new medications or changes to her medication regimen. After fingernail and toenail cultures were sent, fluconazole 200 mg per week and ciclopirox cream were started.

Physical examination: Ten fingernails and ten toenails had diffuse hyperpigmentation of the plates plus overlying hyperpigmented and yellow bands and areas of pseudoleukonychia. In addition there was hyperpigmentation of the proximal nail folds. There was no visible distal onycholysis and onychocorneal bands were completely intact. However, there appeared to be onycholysis of the central region of the nail plate, with yellow discoloration.

Laboratory data: A PAS stain of the initial fingernail plate biopsy was negative. Initial culture of the nail plate alone was also negative. Two nail bed cultures were positive for *Candida parapsilosis*.

Histopathology: There is a nail plate with numerous fungal spores as highlighted by a PAS stain. No fungal hyphae are identified. There also are fine melanin granules as highlighted by a Fontana-Masson stain. A diaminobenzidine stain fails to show deposition of heme. Small, dendritic melanocytes are noted within the nail bed epithelium and there is focal fibrosing granulation tissue.

Discussion

Diagnosis: *Candida parapsilosis* of the nail-bed without onychomycosis

Comment: *Candida parapsilosis* is an emerging fungal pathogen. Since 1990 it has demonstrated the greatest increase in incidence of all *Candida* species [1]. *C. parapsilosis* has cells which are round or oval and does not form true hyphae but can exist as a yeast or as pseudohyphae. It is commonly isolated in the hospital environment and often colonizes the hands of health care workers, grows easily in parenteral nutrition, and readily forms biofilms on prosthetic materials and implanted devices. Clinical manifestations are varied, sometimes severe, and may include fungemia, endocarditis, meningitis, peritonitis, arthritis, otomycosis, vulvovaginitis, urinary tract infections, and onychomycosis [1].

Unlike other *Candida* species, *C. parapsilosis* is widely distributed in nature and is not an obligate human pathogen. It has been isolated from nonhuman sources, which include domestic animals, soil, and marine environments [1]. Not surprisingly, activities such as gardening and trauma can serve as risk factors for infection. As a commensal of human integument and one of the major types of flora of the subungual space in healthy individuals, *C. parapsilosis* often is isolated in nail cultures. It is typically isolated in association with other fungal pathogens. Until recently it was assumed merely to colonize the surface of the nail plate or nail bed, whereas other species of *Candida* caused infection. However, with the increasing prevalence of *C. parapsilosis*, especially in the context of reports of *C. parapsilosis* infection in the absence of other fungal agents, its role as a pathogen has been realized [2]. In fact, *C. parapsilosis* is increasingly being reported as the most common agent of *Candida* onychomycosis [1].

Candida species, which include *C. parapsilosis*, are responsible for nearly one-half of onychomycoses. Clinical manifestations usually consist of severe dystrophy of the nail fold and plate as well as thickening and fragmentation of the plate [3]. *C. parapsilosis*-specific observations have included distal nail plate disease in contrast to the proximal nail or total nail dystrophy that is more typical of *C. albicans* [1]. This case is particularly striking because of the lack of onychomycosis of the nail plate despite nail bed infection, dystrophic changes to the nail plate, and *C. parapsilosis* associated changes. The presence of melanonychia is atypical also. Whereas *C. albicans* [3] and *C. parapsilosis* [2] each have been reported to cause melanonychia once in a single affected digit, this is the first known report of twenty digit melanonychia in response to a *C. parapsilosis* infection.

Fungal melanin likely plays a role in the development of melanonychia in dematiaceous fungi. It has been demonstrated to protect against environmental stressors and host defense systems by acting as a free radical scavenger. In addition, it may play a role in enhancing fungal virulence [4]. However, melanonychia is not typical with nondematiaceous fungi, such as *Candida*, and the function of melanin in such infections is not well understood. Although *Candida* is capable of synthesizing melanin, melanonychia most commonly results from the activation of host melanocytes after inflammation of the nailfold [4]. It is curious that this patient did not have signs of paronychia yet still developed melanonychia. Since little is known about the virulence factors that are present in the pathogenesis of *C. parapsilosis*, the melanonychia demonstrated by this patient cannot be definitively explained. It seems plausible that she may have had a transient paronychia that induced melanocyte activation in both the proximal nail fold and the nail matrix. Another possibility is that the nail pigmentation related to melanin production from *C. parapsilosis*. This pigment may have been produced as a virulence mechanism in response to antifungal treatment. It is also worth considering that the nail bed infection may have triggered a physiologic melanonychia that occurs in most African Americans over the age of 50 [5].

There are no consensus guidelines for the treatment of *C. parapsilosis*. Owing to the historic view of *C. parapsilosis* as an incidental and not pathogenic organism in nail isolates, there are few recommendations for treating *C. parapsilosis* nail bed infections or onychomycoses. For systemic disease, amphotericin B historically has been the treatment of choice, although its use is limited by toxicity. Recently *Candida* has demonstrated resistance to alternative treatments, which include azole antifungals,

such as fluconazole and itraconazole, and echinocandins, such as caspofungin and micafungin. Trials are under way that are examining combination therapy [1]. For onychomycosis, topical antifungals are largely ineffective since drug penetration is low [6]. However, mild disease has responded to the topical antifungal amorolfine in several case reports, perhaps because its mechanism of action differs from that of the azoles and echinocandins [2, 6]. In general, topical agents are not recommended unless less than 50% of the nail surface is affected or less than three of ten digits are involved [7]. When several nails are involved, oral medications are indicated. Typically a minimum of six weeks is recommended to treat dermatophyte-related onychomycosis of the fingernails using terbinafine. Owing to our patient's lack of response to terbinafine, it seems plausible that our patient's infection was either resistant or dosed for an inadequate length of time. For multiple digit disease, we recommend initiating treatment with up to nine months of pulsed azole antifungals, which are particularly effective against yeast [7].

Our patient adds to a very small literature base that describes *Candida parapsilosis*-induced infections of the nail apparatus. This case is notable for the presence of nail-bed infection without overlying plate infection, atypical clinical findings in the nail folds and plate, and twenty nail melanonychia, which is the first case to our knowledge. Given the increasing incidence of *C. parapsilosis*, we believe there needs to be further investigation into more effective treatments for this emerging pathogen.

References

1. Trofa D, et al. *Candida parapsilosis*, an emerging fungal pathogen. *Clin Microbiol Rev* 2008;21:606 [PMID: 18854483]
2. Gautret P, et al. Case report and review: onychomycosis due to *Candida parapsilosis*. *Mycoses*. 2000;43:433 [PMID: 11204360]
3. Parlak A, et al. A case of melanonychia due to *Candida albicans*. *Clin Exp Dermatol*. 2006;31:398 [PMID: 16681587]
4. Finch J, et al. Fungal melanonychia. *J Am Acad Dermatol* 2012;66:830 [PMID: 22257832]
5. Lateur N, Andre J. Melanonychia: diagnosis and treatment. *Dermatol Ther* 2002;15:131
6. Jayatilake JAMS, et al. Candidal onychomycosis: a mini-review. *Mycopathologia* 2009; 168:165 [PMID: 19484505]
7. Tchernev G, et al. Onychomycosis: modern diagnostic and treatment approaches. *Wien Med Wochenschr* 2013; 163:1 [PMID: 23053563]