

UCLA

UCLA Previously Published Works

Title

Concomitant AngioVac thrombectomy and patent foramen ovale closure in a patient with a large right atrial thrombus and recent paradoxical embolic stroke.

Permalink

<https://escholarship.org/uc/item/16p6c390>

Authors

Callese, Tyler E
Yang, Eric H
Levi, Daniel
et al.

Publication Date

2021-02-18

Data Availability

The data associated with this publication are within the manuscript.

Peer reviewed

Concomitant AngioVac thrombectomy and patent foramen ovale closure in a patient with a large right atrial thrombus and recent paradoxical embolic stroke

Tyler E. Callese 

Eric H. Yang 

Daniel Levi 

Ravi N. Srinivasa 

John M. Moriarty 

ABSTRACT

A 59-year-old male with a history of gallbladder adenocarcinoma receiving chemotherapy and on therapeutic anticoagulation for portal vein thrombosis presented to the emergency department via ambulance after being found unresponsive and in cardiac arrest. Initial work-up upon return of spontaneous circulation revealed a large right atrial mass, patent foramen ovale (PFO), and bilateral acute cortical infarctions. This constellation of findings were concerning for PFO-related paradoxical embolic strokes. Given the risk of recurrent paradoxical embolic events and the absolute contraindication to thrombolysis due to recent cerebral infarction, the decision was made to proceed with percutaneous vacuum-assisted thrombectomy using the AngioVac device. To prevent intraoperative thrombus propagation, PFO-closure was performed immediately prior to thrombectomy. Aspiration thrombectomy and PFO-closure were successful with complete thrombus removal and no intraoperative thrombus propagation. This case presents a minimally invasive and rapid treatment for a complex problem. An efficient and effective interdisciplinary team-based approach allowed the patient to resume cancer treatment relatively unabated.

The AngioVac aspiration thrombectomy system (AngioDynamics, Inc.) is an approved device for the removal of intravascular thrombus, tumor, and foreign bodies. Management options for right heart clot-in-transit have broadened from pharmacologic or open surgical management to include aspiration thrombectomy with devices such as the AngioVac (1). Aspiration thrombectomy is a safe and effective option in cases where anticoagulation or thrombolytic therapy are contraindicated and in patients who are poor surgical candidates (2). The AngioVac device works by establishing a veno-venous bypass circuit with in-line aspiration filtration of autologous blood and reperfusion through a separate cannula (3).

One feared outcome of venous thromboembolism in the setting of patent foramen ovale (PFO) is paradoxical stroke (4). The present report describes a novel case of concomitant aspiration thrombectomy and PFO closure in a patient with a right atrial thrombus and paradoxical embolic stroke.

Technique

A 59-year-old man with a history of gallbladder adenocarcinoma complicated by portal vein thrombosis after one cycle of chemotherapy with cisplatin and gemcitabine, on therapeutic anticoagulation with edoxaban, and with no history of coronary artery disease presented to the emergency department via ambulance after being found unresponsive and in cardiac arrest. Subsequent return of spontaneous circulation was restored after 5 minutes of cardiopulmonary resuscitation by pre-hospital emergency medical service providers. Initial cardiac work-up included an electrocardiogram without evidence of ischemic changes, troponins which measured 0.55 ng/dL and continued to downtrend, and an echocardiogram which revealed a large right atrial mass and PFO. Computed tomography of the chest revealed segmental pulmonary emboli and magnetic resonance imaging of the brain revealed bilateral acute cortical infarctions concerning for embolic stroke. The combined findings of a large right atrial thrombus, pulmonary embolism, and multiple cortical infarcts were suggestive of PFO-related paradoxical embolic stroke.

From the Division of Interventional Radiology, Department of Radiology (T.E.C., R.N.S., J.M.M. ✉ jmoriarty@mednet.ucla.edu), UCLA Cardio-Oncology Program, Division of Cardiology, Department of Medicine (E.H.Y.), Division of Pediatric Cardiology, Department of Pediatrics (D.L.), University of California, Los Angeles, California, USA.

Received 5 May 2020; revision requested 9 May 2020; last revision received 30 May 2020; accepted 5 June 2020.

Published online 9 February 2021.

DOI 10.5152/dir.2021.20291

You may cite this article as: Callese TE, Yang EH, Levi D, Srinivasa RN, Moriarty JM. Concomitant AngioVac thrombectomy and patent foramen ovale closure in a patient with a large right atrial thrombus and recent paradoxical embolic stroke. *Diagn Interv Radiol* 9 February 2021 10.5152/dir.2021.20291 [Epub Ahead of Print]

Due to the risk of recurrent paradoxical embolic events and an absolute contraindication to thrombolysis due to recent cerebral infarction, the decision was made to proceed with percutaneous thrombectomy using the AngioVac device. Given the concern for intraoperative paradoxical embolus, the decision was made to proceed with PFO-closure intraoperatively, prior to thrombus extraction.

General anesthesia was induced with transesophageal echocardiography (TEE) monitoring throughout the procedure. TEE demonstrated a large irregular 3.8x3.3 cm heterogeneous mass that occupied much of the right atrium and the inferior cavo-atrial junction (Fig. 1a). A large mobile portion of the mass prolapsed through the tricuspid valve into the right ventricle during diastole (Fig. 1b).

Sheaths were placed in the right internal jugular vein (26 F Gore Dry Seal, W.L. Gore & Associates) and left common femoral vein (18 F Fem-Flex venous reperfusion catheter, Edwards Lifesciences). The patient was heparinized with a target activated clotting time range of 250–300 seconds.

An 8 F Amplatzer TorqVue delivery sheath (AGA Medical) was placed in the right common femoral vein and a 30 mm Amplatzer Cribriform Septal Occluder (AGA Medical) was advanced under TEE guidance to the left atrium. The device was carefully deployed to avoid caging off or trapping any of the right atrial thrombus in the device (Fig. 2a).

With the PFO successfully closed, the AngioVac aspiration cannula was advanced through the right internal jugular vein sheath into the right atrium. Contact with the right atrial mass was confirmed with TEE (Fig. 2b, 2c). The veno-venous bypass circuit

was initiated with immediate return of large amounts of thrombus (Fig. 3a). A 15 mm loop snare was introduced via the side port of the AngioVac cannula and used to manipulate and dislodge less mobile portions of thrombus under TEE guidance. Careful attention was made to avoid contact with the PFO closure device.

Sheaths were removed and hemostasis achieved via purse string sutures and

manual compression. TEE demonstrated >90% resection of the mass and intact PFO closure device (Fig. 3b). He was started on therapeutic enoxaparin and discharged on postoperative day two.

Discussion

The management of patients with right atrial thrombus, patent foramen ovale (PFO), and paradoxical embolic stroke pres-

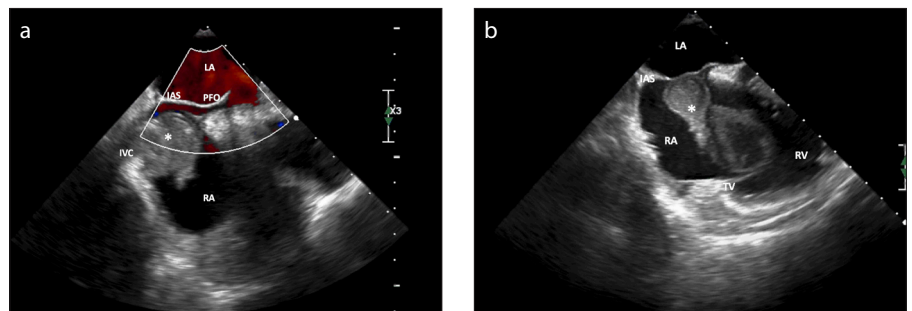


Figure 1. a, b. Midesophageal view at 93 degrees (a) and 0 degrees (b) transesophageal echocardiography of the right atrium and ventricle. Panel (a) demonstrate a large mobile mass (asterisk) and patent foramen ovale. Panel (b) shows the large mobile mass (asterisk) prolapsing across the tricuspid valve during diastole into the right ventricle. PFO, patent foramen ovale; LA, left atrium; IAS, interatrial septum; RA, right atrium; RV, right ventricle; IVC, inferior vena cava; TV, tricuspid valve.

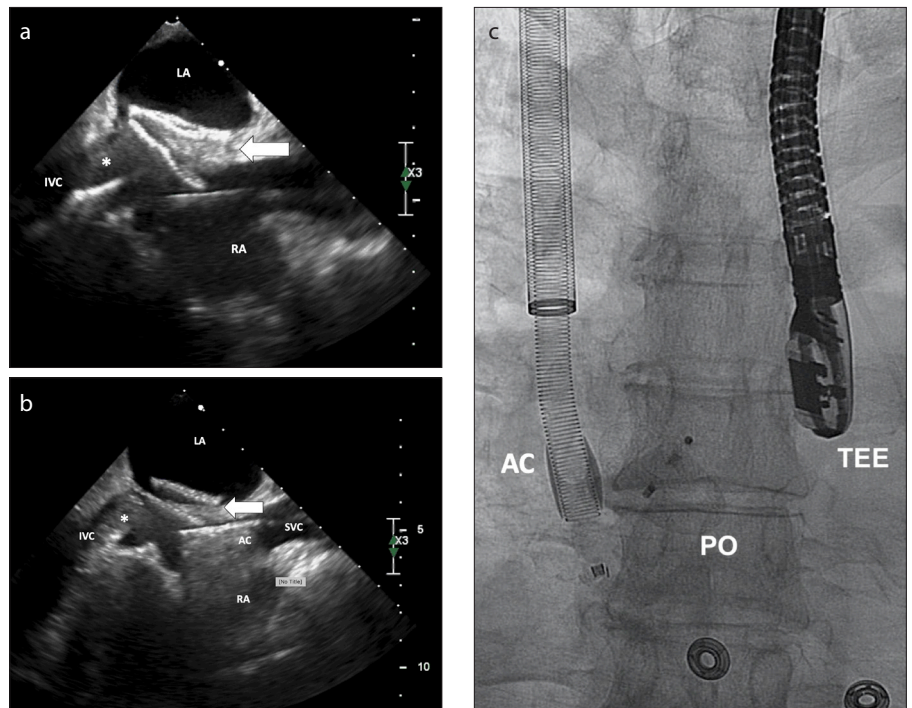


Figure 2. a–c. Midesophageal bicaval view at 95 degrees (a) and 98 degrees (b) transesophageal echocardiography and intraoperative fluoroscopy (c). Panel (a) demonstrates the deployment of the 30 mm Amplatzer Cribriform Septal Occluder (arrow) across the patent foramen ovale under echocardiographic guidance. The mobile mass (asterisk) in the inferior vena cava is seen adjacent to the delivery guide catheter. Panel (b) shows the AngioVac aspiration cannulae from the superior vena cava advancing inferiorly towards the mass (asterisk). Caution was given to avoid the Amplatzer Cribriform Septal Occluder (arrow). Panel (c) demonstrates echocardiographic guidance of the AngioVac cannula adjacent to the Cribriform Septal Occluder. LA, left atrium; RA, right atrium; IVC, inferior vena cava; AC, AngioVac cannulae; SVC, superior vena cava; PO, Cribriform Septal Occluder; TEE, transesophageal echocardiography.

Main points

- The AngioVac device allowed for minimally invasive and rapid aspiration thrombectomy of a right atrial thrombus in the setting of a patent foramen ovale and resultant paradoxical embolic strokes.
- Aspiration thrombectomy is an effective and safe option in patients in which anticoagulation and thrombolysis are contraindicated and who are poor surgical candidates.
- This case represents an efficient and effective interdisciplinary team-based approach to a complex problem which resulted in the successful minimally invasive treatment of this patient and allowed the patient to resume cancer therapy unabated.

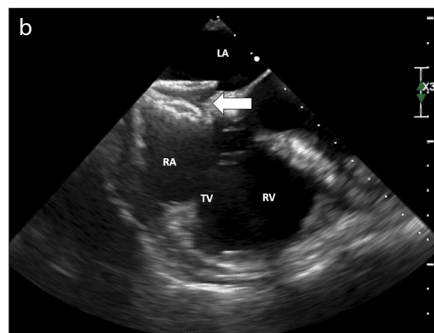
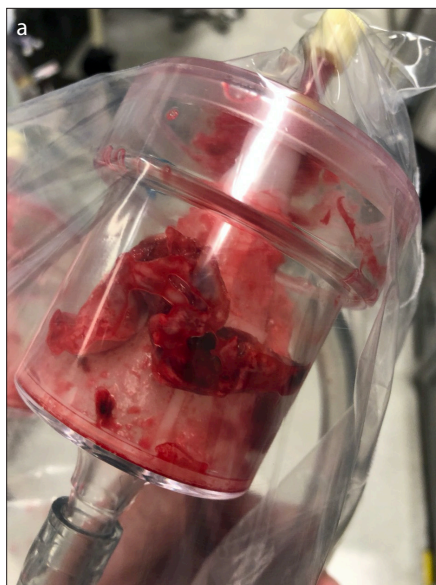

Figure 3. a, b. AngioVac canister (a) with evacuated thrombus. Midesophageal view at 0 degrees (b) transesophageal echocardiography shows the right atrium and ventricle post AngioVac thrombectomy demonstrating removal of most of the right atrial mass. The Amplatzer Cribriform Septal Occluder Device (arrow) remains in stable position across the interatrial septum. LA, left atrium; RA, right atrium; TV, tricuspid valve; RV, right ventricle.

ents a complex clinical challenge. Right atrial thrombus is associated with significant morbidity and mortality, including the risk of fatal pulmonary embolism. In the presence of an intracardiac right-to-left shunt, such as a PFO, the risks of a right atrial thrombus are greatly increased due to the potential for systemic embolization and resultant end-organ dysfunction (paradoxical embolic stroke, limb ischemia, and mesenteric ischemia).

There is little high-level evidence to guide management. As such, a multidisciplinary team discussion involving interventional radiology, interventional cardiology, and cardiothoracic surgery is essential. Treatment options include open thrombectomy, catheter-directed and systemic thrombolysis, and long-term anticoagulation. Catheter-directed and systemic thrombolysis was contraindicated in this case due to recent cerebral infarctions and concern for thrombus fragmentation and subsequent embolization. The evidence for long-term anticoagulation is insufficient to perform as the sole intervention.

There are several considerations that prompted the decision to perform endovascular thrombectomy instead of open atrial thrombectomy, given that both procedures demonstrate similar success rates in the appropriate clinical context. For this patient with gallbladder carcinoma on chemotherapy, the priority was urgent intervention with rapid recovery. Endovascular

thrombectomy using the AngioVac system is associated with decreased intensive care unit length of stay (and the associated invasive telemetry and post-median sternotomy chest tube management often required), decreased hospital length of stay, no need for the physical therapy or rehabilitation that follows major cardiac surgery, and overall decrease in morbidity and mortality. Key to these considerations was the need for the patient to resume chemotherapy as soon as possible postoperatively. These patients are subject to impaired wound healing and susceptibility to infectious complications. Utilizing the AngioVac approach, this patient was able to undergo a single-session endovascular thrombectomy with near-complete removal of the thrombus, rapid postoperative discharge, and uninterrupted chemotherapy.

In this case, PFO closure was performed prior to thrombectomy to decrease the risk of recurrent embolic events during intraoperative thrombus manipulation. The 30 mm Amplatzer Cribriform Septal Occluder was chosen because it has a larger disk on the left atrial side which has two key benefits. The first is that the larger left atrial disk can occlude the shunt while the right side is being deployed, preventing further embolization. And second, the larger left atrial disk is better at preventing further embolization once deployed, particularly in this case as operation of the AngioVac is associated with increased right atrial pressures.

There are several choices of devices to close PFOs (6). The Amplatzer PFO device is built to eliminate a right-to-left shunt and is adequate in most cases. The Amplatzer Cribriform and Gore Cardioform (Gore Medical) devices have equal size disks in both the left and right atrium and the Gore Cardioform could have also been used.

Two previously reported cases in the literature describe the management of a right atrial thrombus in the setting of PFO. Kassas (7) describes endovascular thrombectomy followed by PFO closure and Ray et al. (8) describe endovascular thrombectomy with intraoperative use of a cerebral protection system without PFO closure.

In conclusion, this case presents a minimally invasive and rapid treatment for a complex problem. An efficient and effective interdisciplinary team-based approach allowed the patient to resume cancer treatment relatively unabated.

Conflict of interest disclosure

The authors declared no conflicts of interest.

References

1. Hameed I, Lau C, Khan FM, et al. AngioVac for extraction of venous thromboses and endocardial vegetations: A meta-analysis. *J Card Surg* 2019; 34:170–180. [\[Crossref\]](#)
2. Rajput FA, Du L, Woods M, Jacobson K. Percutaneous vacuum assisted thrombectomy using AngioVac aspiration system. *Cardiovasc Revascularization Med* 2019. Available from: <https://doi.org/10.1016/j.carrev.2019.12.020>. [\[Crossref\]](#)
3. Nickel B, McClure T, Moriarty J. A novel technique for endovascular removal of large volume right atrial tumor thrombus. *Cardiovasc Intervent Radiol* 2015; 38:1021–1024. [\[Crossref\]](#)
4. Abdelghani M, El-Shedoudy SAO, Nassif M, Bouma BJ, De Winter RJ. Management of patients with patent foramen ovale and cryptogenic stroke: An Update. *Cardiol* 2019; 143:62–72. [\[Crossref\]](#)
5. Athappan G, Sengodan P, Chacko P, Gandhi S. Comparative efficacy of different modalities for treatment of right heart thrombi in transit: A pooled analysis. *Vasc Med* 2015; 20:131–138. [\[Crossref\]](#)
6. Collado FMS, Poulin MF, Murphy JJ, Jneid H, Kavinsky CJ. Patent foramen ovale closure for stroke prevention and other disorders. *J Am Heart Assoc* 2018; 7:1–22. [\[Crossref\]](#)
7. Kassas S. Catheter extraction of high risk right atrial clot, technical tips, and lessons learned. Successes and failures. *Catheter Cardiovasc Interv* 2014; 84:1197–1201. [\[Crossref\]](#)
8. Ray HM, Al Rstum Z, Saqib NU. Successful cerebral protection during removal of large right atrial thrombus with AngioVac in a patient with patent foramen ovale and recent embolic stroke. *J Vasc Surg Cases Innov Tech* 2019; 5:201–204. [\[Crossref\]](#)