

UC Irvine

UC Irvine Previously Published Works

Title

Gastric peroral endoscopic myotomy using a novel bipolar blade and the navigational tunnel technique.

Permalink

<https://escholarship.org/uc/item/1682408z>

Journal

Videogic, 9(1)

Authors

Khirfan, Khaldoon
Tavangar, Amirali
Samarasena, Jason
[et al.](#)

Publication Date

2024

DOI

10.1016/j.vgie.2023.09.013

Copyright Information

This work is made available under the terms of a Creative Commons Attribution-NonCommercial-NoDerivatives License, available at <https://creativecommons.org/licenses/by-nc-nd/4.0/>

Peer reviewed



Gastric peroral endoscopic myotomy using a novel bipolar blade and the navigational tunnel technique

Khaldoon Khirfan, MD, Amirali Tavangar, MD, Jason Samarasena, MD, MBA, Kenneth J. Chang, MD, MASGE, FACP, AGAF, FGJES

BACKGROUND

Gastric peroral endoscopic myotomy (G-POEM) is emerging as an endoscopic treatment option for gastroparesis. A novel multimodal cutting/cautery device has been reported for endoscopic submucosal dissection (ESD) and esophageal peroral endoscopic myotomy.¹⁻³ This device has not been reported for G-POEM, in which the unique shape and design may enhance submucosal dissection. We used this device, along with the navigational tunnel technique, in 3 G-POEM patients, and a representative case is presented here.

CASE PRESENTATION

A 43-year-old man with a history of GERD underwent multiple antireflux surgeries, complicated by refractory symptomatic gastroparesis. His Gastroparesis Cardinal Symptom Index (GCSI) was 35/45. The gastric emptying study showed 52% retained food at 4 hours.

ENDOSCOPIC METHODS

A single-channel therapeutic endoscope (1-T) was required for passage of the 3.7-mm bipolar device. Electrosurgical settings were used as follows: bipolar cutting mode at 25 W for mucosal incision, tunneling, and myotomy and microwave coagulation mode at 10 W for coagulation. Mucosal cautery markings were made to outline the tunnel, starting 3 cm proximal to the pylorus. After mucosal marking, the navigational tunnel was created by submucosal injection of carboxymethylcellulose with methylene blue

Abbreviations: ESD, endoscopic submucosal dissection; GCSI, Gastroparesis Cardinal Symptom Index; G-POEM, gastric peroral endoscopic myotomy.

Copyright © 2024 American Society for Gastrointestinal Endoscopy. Published by Elsevier Inc. This is an open access article under the CC BY-NC-ND license (<http://creativecommons.org/licenses/by-nc-nd/4.0/>). 2468-4481 <https://doi.org/10.1016/j.vgje.2023.09.013>

Digestive Health Institute, University of California, Irvine Medical Center, Orange, California.

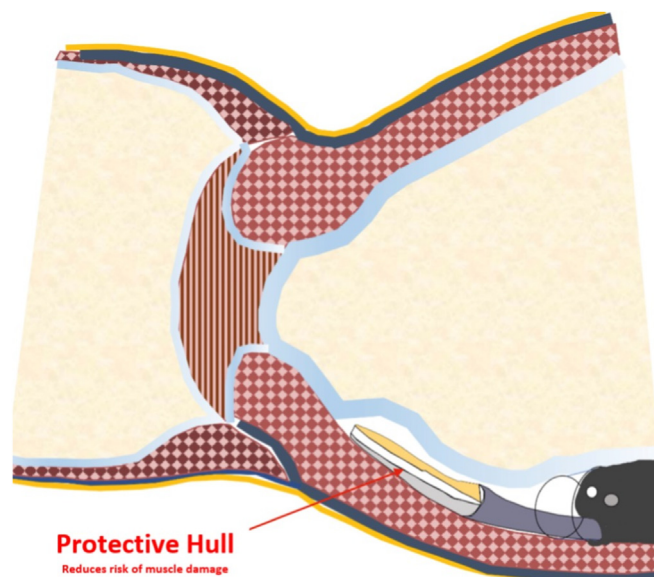


Figure 1. Illustration showing the endoscope bipolar blade creating a submucosal tunnel in preparation for endoscopic myotomy during the gastric peroral endoscopic myotomy procedure.

starting at the pylorus and extending backward to the incision point. The navigational tunnel technique, previously described,⁴ was used to facilitate submucosal dissection in the uphill direction toward the pylorus muscle and avoid misdirected tunneling.

The tip of the blade was used to start the mucosal incision. The incision was then extended fully to the right and left of the starting point. The submucosal tunnel was then extended toward the pylorus in an uphill direction. The protective hull at the bottom of the blade minimized inadvertent deep muscle injury (Fig. 1). The bipolar blade cut in both forward and lateral directions (Video 1, available online at www.videogie.org). Submucosal vessels were prophylactically coagulated using the white microwave portion of the blade (Fig. 2), a process that can take up to 10 seconds and is slower than conventional coagulation using the coagulation grasper. At the end of the tunnel, the pylorus was identified (Fig. 3). After starting the pyloro-myotomy, we switched to a thin right-angled tip knife to precisely cut all 3 muscle layers while minimizing serosal damage or exposing the peritoneum. We performed a second (double) myotomy to extend the opening of the




Figure 2. Bipolar knife and its components illustrated.

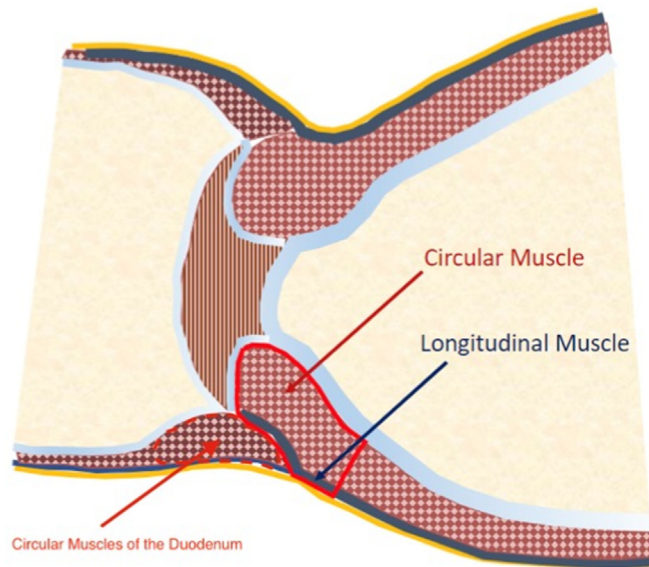


Figure 3. Illustration showing the circular and longitudinal muscles of the pylorus and duodenum.

sphincter. Closure of the tunnel’s opening was achieved by endoscopic suturing. The approximate time in minutes for various parts of the procedure was as follows: marking, 3; navigational tunnel preinjection, 5; mucosal incision, 3; submucosal tunneling, 9; and pyloromyotomy, 7.

RESULTS AND DISCUSSION

The patient did well after the procedure with no immediate or delayed adverse events. He also had significant

symptomatic improvements, and GCSI improved from 35 to 17 four weeks after the procedure.

The new knife mandates a larger therapeutic gastroscop because of a bigger-size knife compared with the other ESD knives that could be used with a regular adult gastroscop. Furthermore, the larger size of the knife impedes the suction capabilities during the procedure. This shortcoming could have been addressed if we had used a 2T therapeutic endoscope. The new device also needs a special electrosurgical generator. Additionally, the design of the new system does not allow hooking capabilities, which could make selective myotomy challenging. To overcome this shortcoming, we had to switch to a right-angle tip knife.

CONCLUSIONS

A novel multimodal bipolar device can be used for submucosal injection, mucosal incision, and submucosal tunneling without the need for coagulation graspers for the G-POEM procedure. The navigational tunneling technique helps guide the submucosal dissection toward the targeted pylorus and minimizes the need for additional intraprocedural injections. The bipolar blade for cutting combined with microwave for coagulation minimizes undesired tissue damage and may enhance safety. The unique protective hull of the device appears well-suited for G-POEM in which the tunnel is extended in an “uphill” direction.

DISCLOSURE

Dr Samarasena is a consultant for Neptune Medical, Steris, Microtech, Olympus, Pentax, Medtronic, US Endoscopy, Mauna Kea, Conmed, and Motus. He also has ownership in Docbot and an educational grant from Cook Medical. Dr Chang is a consultant for and has received educational grants from Apollo Endosurgery, Cook, Creo, Endogastric Solutions, Erbe, Medtronic, and Olympus. The other authors have no financial relationships to disclose.

REFERENCES

1. Nabi Z, Chavan R, Ramchandani M, et al. Endoscopic submucosal dissection and tunneling procedures using a novel all-in-one bipolar device. *Endosc Int Open* 2020;8:E1302-7.
2. McCarty TR, Aihara H. Endoscopic submucosal tunneling dissection: use of a novel bipolar radiofrequency and microwave-powered device for colorectal endoscopic submucosal dissection. *VideoGIE* 2020;5:335-8.
3. Patil G, Dalal A, Maydeo AP. Feasibility of Speedboat RS2 with bipolar radiofrequency energy for peroral endoscopic myotomy in patients with achalasia (with video). *Endosc Int Open* 2020;8:E998-1001.
4. Kolb JM, Sowa P, Samarasena J, et al. Navigational tunnel technique for gastric peroral endoscopic pyloromyotomy: getting straight to the point (pylorus). *VideoGIE* 2021;7:82-4.