

UC Davis

UC Davis Previously Published Works

Title

Malignant primitive epithelioid sarcoma with features of rhabdoid tumor presenting in utero with diffusely metastatic disease

Permalink

<https://escholarship.org/uc/item/15x7j5qq>

Authors

Theodorou, Christina M

Brown, Erin G

Saadai, Payam

et al.

Publication Date

2020-08-01

DOI

10.1016/j.epsc.2020.101484

Peer reviewed



Published in final edited form as:

J Pediatr Surg Case Rep. 2020 August ; 59: . doi:10.1016/j.epsc.2020.101484.

Malignant primitive epithelioid sarcoma with features of rhabdoid tumor presenting *in utero* with diffusely metastatic disease

Christina M. Theodorou*, Erin G. Brown, Payam Saadai, Shinjiro Hirose, Diana L. Farmer
University of California, Davis Medical Center. Department of Pediatric General, Thoracic and Fetal Surgery, United States

Abstract

Diagnosis of a tumor *in utero* is a rare occurrence and poses diagnostic and therapeutic challenges. In cases of tumor-associated hydrops, there is significant risk of fetal demise, and prenatal intervention may be considered to avoid this outcome when possible. When fetal intervention is unlikely to improve survival, information can be useful for counseling families. We present a rare case of fetal diagnosis of a primary renal malignancy with widespread metastases and hydrops, with unique immunohistochemical findings consistent with malignant primitive epithelioid sarcoma with features of rhabdoid tumor.

1. Introduction

Fetal tumors are rare. Autopsy evaluation of stillborn fetuses has revealed a 0.5% rate of fetal tumors [1]. Of liveborn children, prenatally diagnosed masses are most commonly lymphatic malformations [2] and sacrococcygeal teratomas [3,4]. Cervical teratomas, although accounting for only 3% of teratomas diagnosed in the neonatal period, can cause airway compromise and hydrops, and may be managed with ex-utero intrapartum treatment (EXIT) [4]. Fetal renal tumors are less common, occurring in 7 of 100,000 live births [5], and there have been reports of fetal neuroblastoma as well [6]. Fetal tumors with associated hydrops portend a particularly poor prognosis, with survival rates below 20% [7]. Early prenatal diagnosis is essential for identifying patients who may benefit from fetal, rather than postnatal intervention, as is the case for certain teratomas. However, in cases where fetal intervention is unlikely to improve survival, knowledge of the wide differential diagnosis of a fetal tumor can significantly improve education and counseling for families.

This is an open access article under the CC BY-NC-ND license (<http://creativecommons.org/licenses/by-nc-nd/4.0/>).

*Corresponding author. University of California, Davis Medical Center, 2335 Stockton Boulevard Room, 5107, Sacramento, CA, 95817, United States. ctheodorou@ucdavis.edu (C.M. Theodorou).

Authorship

All authors attest that they meet current ICMJE criteria for Authorship. CT, EB, PS, SH, DF.

Patient consent

Consent to publish the case report was obtained.

Declaration of competing interest

CT, EB: There is no conflict of interest, see funding disclosure for NIH financial support.

PS, SH, DF: There are no conflicts of interest and the authors have no financial disclosures.

We report a case of a fetus diagnosed with a large renal mass with diffuse metastatic lesions and hydrops.

2. Case report

A 34-year-old G5P2002 woman who presented to labor and delivery at 30 weeks and 4 days gestation with several days of abdominal pain and tightness. She had been referred for an ultrasound by her midwife after measuring larger than dates. The ultrasound was concerning for a fetal mass and polyhydramnios, and she was referred to Labor & Delivery for evaluation. Repeat ultrasound at our institution showed fetal hydrops with scalp edema, pericardial and pleural effusions, and a solid 10.4×8.2 cm mass with vascular flow extending from the right cheek into the right chest (Fig. 1). There was evidence of polyhydramnios with an amniotic fluid index (AFI) of 27.4 cm. The fetal stomach and airway were not visualized, raising concern for obstruction by the mass. Fetal magnetic resonance imaging (MRI) confirmed a large $9.8 \times 8.9 \times 8.4$ cm soft tissue mass involving the right lateral neck, right axilla, right upper extremity, and right chest wall (Fig. 1), with notable compression of the airway. Multiple additional small subcutaneous nodules were identified throughout the fetal torso and extremities, including a 1.8×2.8 cm lesion on the left thigh, a 2.7×2.5 cm lesion on the right cheek, and a 2.9×2.1 cm lesion on the right buttock. Hydrops was confirmed. A fetal echocardiogram was done which showed normal cardiac anatomy, normal biventricular systolic function, diffuse skin edema, bilateral pleural effusions, and a trivial pericardial effusion. The combined cardiac index was normal at 430 ml/min/kg.

The differential diagnosis for this large soft tissue tumor presenting in a fetus was broad (Table 1). Initially, there was concern primarily for a cervical teratoma or lymphatic malformation causing airway impingement and hydrops, and consideration was given to *in utero* resection to alleviate the hydrops. Ex-utero intrapartum treatment (EXIT) was also a potential management option. The findings of widely disseminated lesions on MRI, however, indicated that the fetus likely did not have a cervical teratoma or lymphangioma amenable to surgical resection. The multiplicity of the lesions raised concern for widely metastatic neoplasm or multiple vascular malformations. Although the fetus was not in imminent distress, the findings of fetal hydrops portended an extremely poor prognosis. In addition, the rapidly accumulating polyhydramnios was physically disabling for the mother. Given the severity of these findings, extensive multidisciplinary discussions were held between the patient, maternal fetal medicine, and the fetal surgery teams. There was no identifiable fetal or postnatal intervention for the fetus, and given the high likelihood of morbidity and fetal or neonatal death, it was decided to proceed with elective termination via intra-fetal cardiac potassium chloride injection followed by induction of labor to avoid the maternal morbidity of a Cesarean section.

On hospital day 3, the fetus was delivered vaginally. Immediately notable were innumerable subcutaneous masses (Fig. 2). On autopsy, the primary tumor was found to arise from the right kidney (2.3 cm) with extensive subcutaneous and internal metastatic disease. The largest metastatic focus was the originally identified tumor on the right chest, extending to the right back, measuring 10.5 cm in largest dimension. Additional metastatic subcutaneous

disease was identified on the face, extremities, and abdominal wall (Table 2). Microscopic examination revealed sheets of tumor cells invading the soft tissue, muscle, lymph nodes, right kidney, adrenal glands, thymus, heart, and liver. Tumor cells demonstrated epithelioid to spindle cell morphology in a loose fibrous stroma arranged in sheets and scattered nests. There were variable amounts of eosinophilic cytoplasm, round to oval nuclei, and prominent nucleoli. Additionally, rhabdoid cells were present with abundant eosinophilic cytoplasm, eccentric nuclei, and scattered intracytoplasmic inclusions. Intravascular and perineural tumor was noted in multiple sections.

Immunohistochemistry revealed near diffuse positivity for cytokeratin (AE1/AE3), diffuse positivity for vimentin, focal CD34 staining, retained SMARCA4 (patchy nuclear positive) and SMARCB1 (INI-1). However, within the tumor cells there was focal loss of SMARCB1/INI-1. Of note, WT1 had patchy positivity in the cytoplasm but was not found in the nucleus. Staining for synaptophysin, CD99, HMB45, myogenin, MYOD1, SMA, desmin, SALL4, Glypican-3, and PHOX2B were negative. The results of immunohistochemical analysis were consistent with the diagnosis of malignant primitive epithelioid sarcoma with features of malignant rhabdoid tumor.

3. Discussion

This is the first report of a fetal diagnosis of malignant primitive epithelioid sarcoma with features of malignant rhabdoid tumor in the literature. Additionally, retention of SMARCB1/INI-1 expression is exceedingly rare in epithelioid sarcoma. Congenital malignancies are extremely uncommon, affecting fewer than 13 per 100,000 live births, and the most prevalent etiologies include teratomas, neuroblastoma, soft tissue tumors, or leukemia [8]. Malignant sarcomas represent 3.5% of all neonatal tumors [9]. Epithelioid sarcoma is a rare malignant neoplasm of mesenchymal origin most commonly seen in young adults and occasionally young children. It is most often slow-growing, painless, and difficult to diagnose given its ambiguous nature. Histologically, it demonstrates epithelioid morphology with deletion of SMARCB1/INI-1 [10]. SMARCB1/INI-1 is a tumor suppressor gene. Its native function is poorly understood, although it is known to be a member of a family of genes encoding chromatin-remodeling complex. Loss of SMARCB1/INI-1 expression is seen in the majority of epithelioid sarcomas and the vast majority of rhabdoid tumors. In one series of rhabdoid tumors, only 16% had retained expression of SMARCB1/INI-1 [11]. Another series of two siblings with classic rhabdoid tumor also retained expression of SMARCB1/INI-1, suggesting that rhabdoid tumor may arise by a separate mutational locus [12]. One additional case of epithelioid sarcoma with retained SMARCB1/INI-1 expression has been reported in a 15-month old infant presenting with an isolated heel mass [10].

Malignant rhabdoid tumor is a highly aggressive subtype of sarcoma. It is most commonly seen in young children and originates in the kidneys, central nervous system (CNS), or soft tissue [10], but has been previously reported in fetal and neonatal patients. When diagnosed *in utero*, the mean gestational age is around 33 weeks [13]. Rhabdoid tumor is identified histologically by the presence of rhabdoid tumor cells with round vesicular nuclei, prominent nucleoli, and eosinophilic inclusions within the cytoplasm [13], and usually with deletion of the SMARCB1/INI-1 gene on chromosome 22q11 [14]. They exhibit positivity

for cytokeratins AE1/AE3, vimentin, and epithelial membrane antigen (EMA), although there is some variability [16,17]. In a 40-year review of the literature, 12 fetal cases and 60 neonatal cases were identified [13]. Most (45.8%) were of renal origin without CNS involvement, one-third were extrarenal tumors not involving the CNS, and 16.7% were of CNS origin. Overall survival was 9.7%. More than half (57%) had distant metastasis at diagnosis, and all patients with metastatic disease at diagnosis died. Multiple subcutaneous nodules resembling the “blueberry muffin” presentation of neuroblastoma were present in this case as well as several others [13]. Placental metastases may also be seen, but all reports describe placental metastases of the tumor without evidence of maternal disease [8,17,18]. This tumor is aggressive and rapidly fatal with survival ranging from a few minutes to 3 months in one case series of 8 fetuses and neonates with malignant rhabdoid tumor [17].

Treatment options are extremely limited. There is no known effective regimen for this rare malignancy. Several case reports describe treatment regimens involving surgical resection with adjuvant chemotherapy or radiation treatment; however, survival rates are exceedingly low [13]. The presence of disseminated metastases, present in many patients at diagnosis, precludes surgical resection, and in most cases no treatment is able to be offered due to the critical nature of the neonate [13–18].

4. Conclusion

We present the first known case of a fetal presentation of malignant primitive epithelioid sarcoma with features of malignant rhabdoid tumor with preserved expression of SMARCB1/INI-1. Like many cases in the literature, the fetus presented with widely metastatic disease and no viable treatment options. This presentation, in the setting of fetal hydrops, was incompatible with life. Although rare, this tumor should be on the differential for fetuses presenting with ultrasound findings concerning for mass lesions with disseminated metastases.

Funding

The project described was supported by the National Center for Advancing Translational Sciences, National Institutes of Health, through grant number UL1 TR001860 for authors CT and EB. The content is solely the responsibility of the authors and does not necessarily represent the official views of the NIH.

References

- [1]. McPherson E, Cold C, Johnson P, Schema L, Zaleski C. Neuroblastoma in a 17-week fetus: a stimulus for investigation of tumors in a series of 2786 stillbirth and late miscarriages. *Am J Med Genet* 2015;167A(1):246–9. [PubMed: 25339601]
- [2]. Gaffuri M, Torretta S, Iofrida E, et al. Multidisciplinary management of congenital giant head and neck masses: our experience and review of the literature. *J Pediatr Surg* 2019;54(4):733–9. [PubMed: 30955589]
- [3]. Farmer DL. Fetal surgery: a brief review. *Pediatr Radiol* 1998;28(6):409–13. [PubMed: 9634452]
- [4]. Hirose S, Sydorak RM, Tsao K, et al. Spectrum of intrapartum management strategies for giant fetal cervical teratoma. *J Pediatr Surg* 2003;38(3):446–50. [PubMed: 12632365]
- [5]. Ogawa S, Schlaepfer CH, Weaver J, et al. Antenatal presentation of wilms’ tumor. *Urology* 2019;134:225–7. [PubMed: 31421145]

- [6]. Gorincour G, Dugougeat-Pilleul F, Bouvier R, et al. Prenatal presentation of cervical congenital neuroblastoma. *Prenat Diagn* 2003;23(8):690–3. [PubMed: 12913877]
- [7]. Isaacs H Jr Fetal hydrops associated with tumors. *Am J Perinatol* 2008;25(1): 43–68. [PubMed: 18075961]
- [8]. Chaudet K, Kaimal A, Deshpande V, Roberts DJ. INI1 negative sarcoma diagnosed as malignant rhabdoid tumor presenting as hydrops fetalis metastatic to the placenta: a case report and review of the literature on congenital sarcomas. *J Matern Fetal Neonatal Med* 2019:1–4.
- [9]. Parkes SE, Muir KR, Southern L, Cameron AH, Darbyshire PJ, Stevens MC. Neonatal tumours: a thirty-year population-based study. *Med Pediatr Oncol* 1994; 22(5):309–17. [PubMed: 8127254]
- [10]. Srinivasan A, Liu M, Parham D, et al. Infantile epithelioid sarcoma with genomic segmental amplification of as double minutes plus trisomy 2: a case report. *Fetal Pediatr Pathol* 2019:1–11.
- [11]. Bourdeaut F, Fr eneaux P, Thuille B, et al. hSNF5/INI1-deficient tumours and rhabdoid tumours are convergent but not fully overlapping entities. *J Pathol* 2007; 211(3):323–30. [PubMed: 17152049]
- [12]. Frühwald MC, Hasselblatt M, Wirth S, et al. Non-linkage of familial rhabdoid tumors to SMARCB1 implies a second locus for the rhabdoid tumor predisposition syndrome. *Pediatr Blood Canc* 2006;47(3):273–8.
- [13]. Fetal Isaacs H. and neonatal rhabdoid tumor. *J Pediatr Surg* 2010;45(3):619–26. [PubMed: 20223330]
- [14]. Ferrari A, Orbach D, Sultan I, Casanova M, Bisogno G. Neonatal soft tissue sarcomas. *Semin Fetal Neonatal Med* 2012;17(4):231–8. [PubMed: 22633289]
- [15]. Yurdakul Z, Berrak SG, Bilgen H, et al. Congenital disseminated malignant rhabdoid tumor of the soft tissue. *Pediatr Blood Canc* 2007;49(3):364–5.
- [16]. Dominey A, Paller AS, Gonzalez-crussi F. Congenital rhabdoid sarcoma with cutaneous metastases. *J Am Acad Dermatol* 1990;22(5 Pt 2):969–74. [PubMed: 2335592]
- [17]. White F, Dehner L, Belchis D, et al. Congenital disseminated malignant rhabdoid tumor: a distinct clinicopathologic entity demonstrating abnormalities of chromosome 22q11. *Am J Surg Pathol* 1999;23(3):249–56. [PubMed: 10078913]
- [18]. Joueidi Y, Rousselin A, Rozel C, et al. Ultrasound presentation of a disseminated fetal and neonatal rhabdoid tumor. *Case Rep Obstet Gynecol* 2018;2018 Article ID: 6073204.

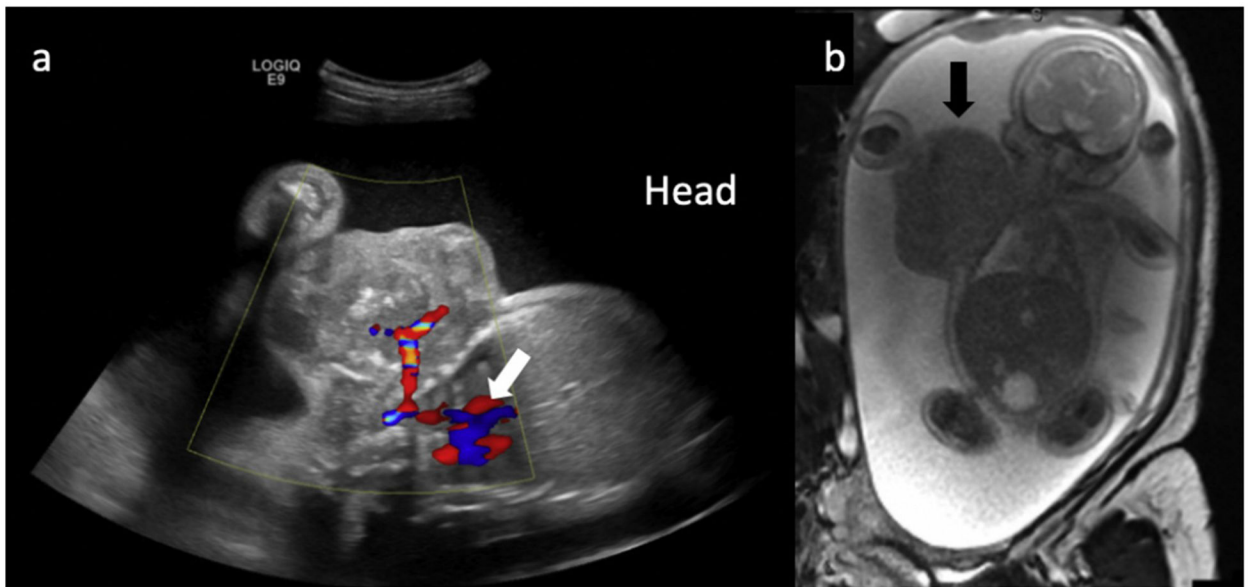


Fig. 1.
(a) Fetal ultrasound demonstrating vascular mass (white arrow) extending from right cheek to right chest wall. (b) Fetal MRI demonstrating mass (black arrow) arising from right chest wall.

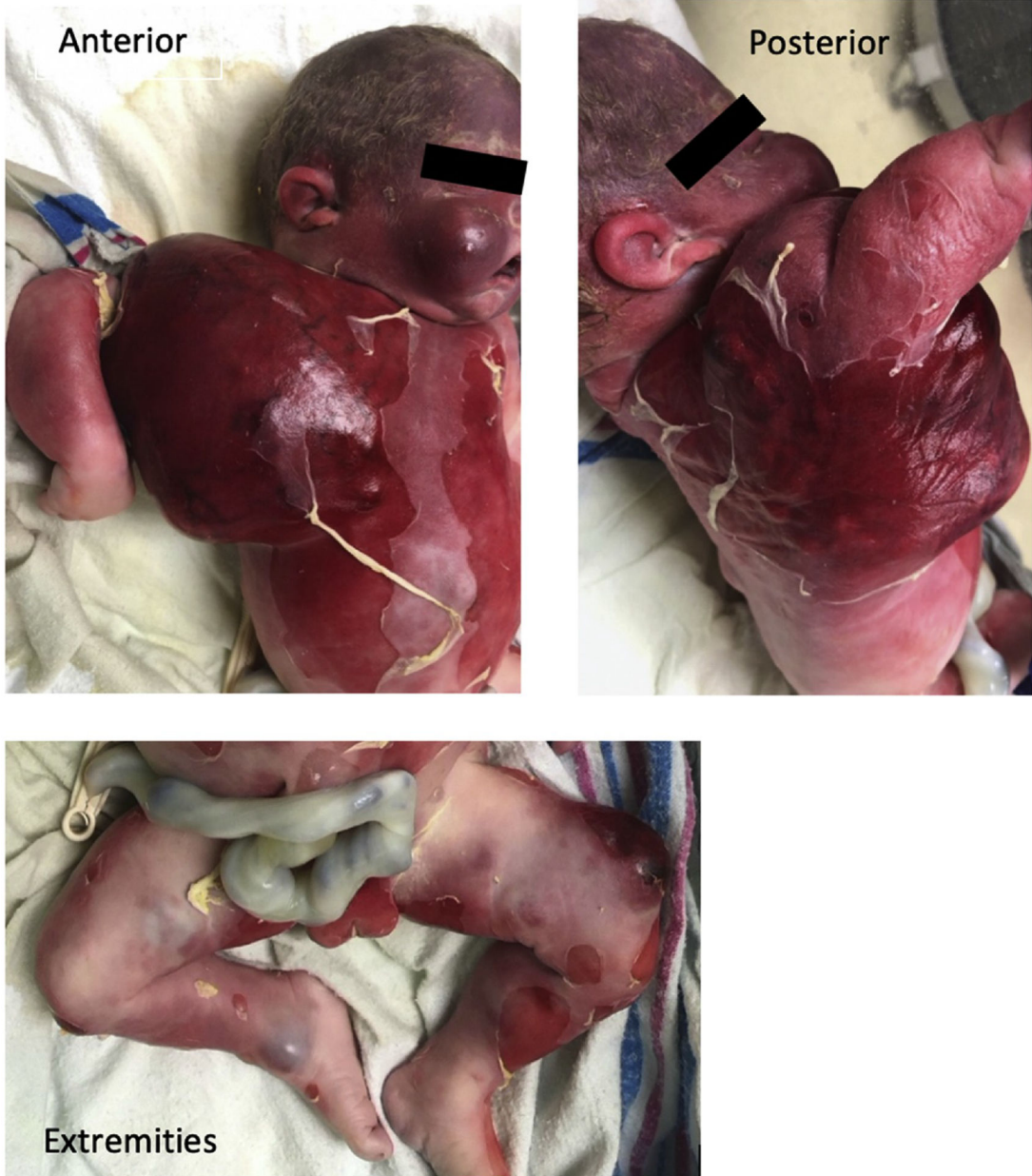

Fig. 2. Stillborn fetus demonstrating multiple subcutaneous nodules, largest arising from the right chest, as well as right cheek and bilateral lower extremities.

Table 1

Differential diagnosis.

Teratoma
Vascular lesions
Lymphatic malformation
Hemangioma
Lymphangioma
Neuroblastoma
Rhabdomyosarcoma
Metastatic neoplasm

Author Manuscript

Author Manuscript

Author Manuscript

Author Manuscript

Table 2

Locations of primary tumor and metastases.

Subcutaneous tumors		Internal tumors	
Location	Size	Location	Size
Right chest/back	10.5 cm	Right kidney (primary)	2.3 cm
Right forearm	4 cm	Thymus, multiple	0.1–0.8 cm
Anterior left thigh	3.5 cm	Bilateral adrenal glands	0.3–0.5 cm
Right cheek	3 cm	Liver, multiple	Up to .3 cm
Right buttock	2 cm	Left epicardium	0.3 cm
Midline upper abdominal wall	1.5 cm	Spinal column, peritoneal surface, multiple	Up to 0.3 cm
Posterior right thigh	1.5 cm	Diaphragm, bilateral, multiple	Up to 0.2 cm
Posterior left leg	1.5 cm		
Posterior right leg	1.2 cm		
Right palm	1 cm		

Author Manuscript

Author Manuscript

Author Manuscript

Author Manuscript