

UCSF

UC San Francisco Previously Published Works

Title

Chylous Leak During Posterior Approach to Juvenile Scoliosis Surgery: A Case Report.

Permalink

<https://escholarship.org/uc/item/1555t9z0>

Journal

JBS Case Connector, 10(1)

ISSN

2160-3251

Authors

Shah, Harsh A
Rynecki, Nicole
Vives, Michael J
[et al.](#)

Publication Date

2020

DOI

10.2106/jbjs.cc.19.00100

Peer reviewed

Chylous Leak During Posterior Approach to Juvenile Scoliosis Surgery

A Case Report

Harsh A. Shah, MD, Nicole Rynecki, BA, Michael J. Vives, MD, Daniel E. Choi, MD, Justin T. Sambol, MD, and Sanjeev Sabharwal, MD, MPH

Investigation performed at Rutgers New Jersey Medical School, Newark, New Jersey

Abstract

Case: We report the first documented case of chylous leak recognized intraoperatively during posterior spinal instrumentation and fusion for juvenile scoliosis in a female patient with a history of thoracotomy and decortication for an empyema.

Conclusions: Thoracic duct injury can lead to severe morbidity and mortality because of chylothorax formation. Although chylous leaks are a well-documented complication of the anterior approach to spine surgery, leaks during the posterior approach are rarely reported. When these chylous leaks are recognized intraoperatively, the likelihood of serious complications may be minimized by drain placement before closure.

Thoracic duct injury is commonly associated with chylous leaks and subsequent chylothorax^{1,2}. A chylothorax may lead to severe morbidity and mortality secondary to respiratory dysfunction, immune deficiency, and malnutrition². The cisterna chyli, a saclike confluence of lymphatics that receives chyle from small intestine lacteals, is located on the anterior surface of L2 medial to the abdominal aorta just beneath the diaphragm. The duct ascends from this level through the aortic hiatus into the right aspect of the thoracic cavity and continues through the thoracic inlet. The lymphatic fluid enters the venous system at the junction of the left subclavian and left internal jugular veins²⁻⁴. Anatomical variants of the thoracic duct add a layer of complexity to spinal procedures⁵.

Thoracic duct injury is a well-documented complication of anterior approach for correction of juvenile scoliosis. The lymphatic vessels can be damaged during the procedure because of their proximity to the anterior spine. The rate of chylothorax after anterior approach to the thoracic spine is estimated at 0.33%⁶. However, thoracic duct injury after posterior approach to the thoracic spine, specifically for the treatment of juvenile scoliosis, is rarely reported. A case reported in 1990 was diagnosed multiple days after surgery, and a more recent case in 2018 was also recognized postoperatively after the development of chyluria^{7,8}. We report the first-documented case of a chylous leak recognized intraoperatively during posterior spinal instrumentation and fusion for juvenile scoliosis in a female patient with a remote

surgical history of thoracotomy and decortication for an empyema.

The patient was informed that data concerning the case would be submitted for publication, and her parents provided consent.

Case Report

The patient is a 13-year-old postmenarchal girl who presented with progression of her right thoracic juvenile scoliosis. The patient was originally diagnosed with scoliosis at the age of 10 years when she presented with a chief concern of back pain. Radiographs from the previous year revealed a right thoracic 19° curve. Despite bracing, her major curve from T4 to T11 increased from 23° to 60° (Fig. 1). The patient has no family history of scoliosis. Surgical correction for treatment was advised, and informed consent was obtained. The patient had a surgical history of a right thoracotomy and decortication with chest tube placement for necrotizing pneumonia and empyema 7 years prior. There were no predisposing factors for this infection, and no organism was isolated.

A midline exposure was carried out from the upper thoracic to the mid lumbar region. Subperiosteal dissection was carried out from T2 distally to L2. During initial exposure of the spine, before any instrumentation, milky fluid was noted deep to the transverse processes of T10-T11 on the left side. The wound was irrigated with saline, and the anesthesia team ruled out pneumothorax. The fluid sample was sent for Gram staining and culture. An intraoperative thoracic surgery consult

Disclosure: The **Disclosure of Potential Conflicts of Interest** forms are provided with the online version of the article (<http://links.lww.com/JBJS/C/B64>).

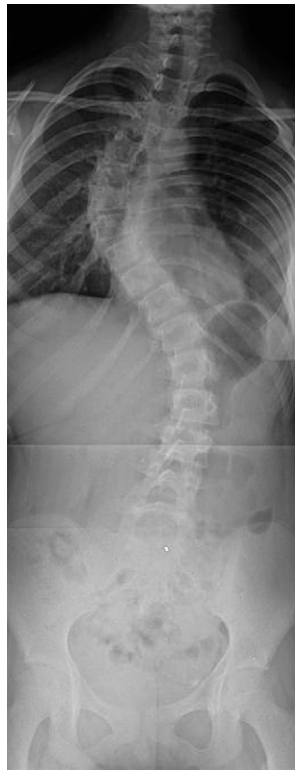

Fig. 1-A

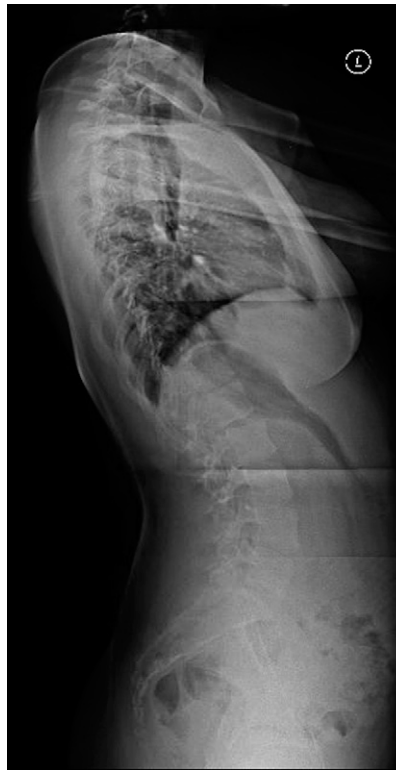

Fig. 1-B

Figs. 1-A and 1-B Preoperative standing (**Fig. 1-A**) posterior-anterior radiograph and (**Fig. 1-B**) lateral radiograph of the spine displaying the patient's juvenile scoliosis with 60° of curvature between T4 and T11.

was obtained, and a chylous leak was suspected. The thoracic surgery team recommended we place a deep drain in the leak area, as well as a routine superficial drain. The surgery continued uneventfully. Because drains were placed and there was no further evidence of chyle fluid, we progressed to instrumentation. Although there was an increased risk for postoperative infection of hardware, we believed that the placement of the deep drain minimized this risk. Therefore, we decided, with the support of the thoracic surgery team, to proceed with surgery.

Postoperatively, the patient denied respiratory symptoms. Daily drain outputs and triglyceride levels were monitored closely per thoracic surgery recommendations (Table I). Drain output was serosanguineous. On the first postoperative day, there was no evidence of pleural effusion or consolidation on chest radiographs (Fig. 2). Daily complete metabolic panels were obtained to monitor for electrolyte derangements. The patient was kept

nothing by mouth and started on octreotide 200 µg subcutaneously but that was discontinued on the second postoperative day. The patient's diet was advanced to a low-fat diet and then gradually to a regular fat diet, as tolerated. The modest level of triglycerides in the superficial drain suggests low-level residual leakage of chyle, mixed with serous fluid that commonly accumulates in the subfascial space, which was egressing through the fascial closure. Because the concentration and volume were relatively low, we did not feel the need to leave the superficial drain in place beyond postoperative day 3. On the fourth postoperative day, the patient began ambulating independently. Intraoperative cultures returned negative for any organisms. The deep drain was removed, and the patient was discharged home.

Nine days postoperatively, there was no drainage from the incision site and the patient did not have any respiratory

TABLE I Triglyceride Values of Drain Fluids

Drain	6 Hours After Surgery	Postoperative Day 1	Postoperative Day 2	Postoperative Day 3	Postoperative Day 4
Deep drain triglyceride level	>3,350 mg/dL	637 mg/dL	253 mg/dL	37 mg/dL	30 mg/dL
Deep drain output	60 cc	260 cc	280 cc	380 cc	170 cc
Superficial drain triglyceride level	186 mg/dL	125 mg/dL	132 mg/dL	—	—
Superficial drain output	0 cc	30 cc	15 cc	—	—

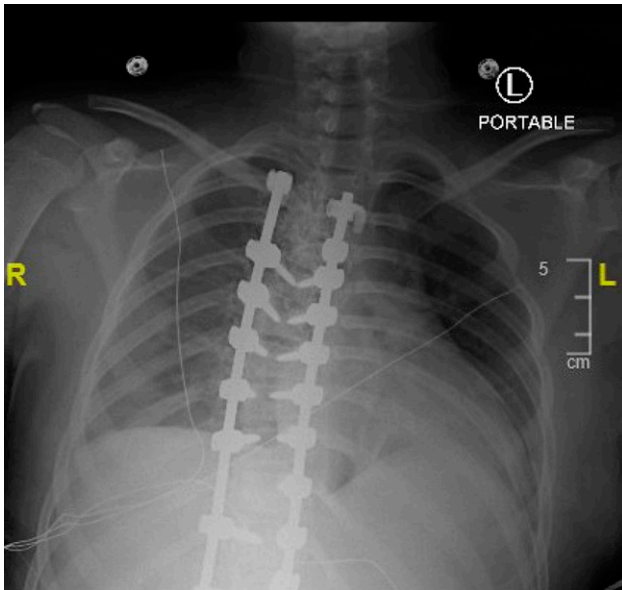


Fig. 2
Postoperative day 1 anterior-posterior chest radiograph to evaluate for pleural effusion or chylothorax. Mild bibasilar atelectasis is present but no pleural effusion or pneumothorax.

complaints. At the 1-year follow-up, the incision site was well healed and she still denied any respiratory complaints. The patient's major curve was measured to be 23°, an

overall curve correction of 65% (Fig. 3). At the 2-year follow-up, the patient had no midline back pain or respiratory complaints.

Discussion

Chylothorax is a type of pleural effusion that can occur secondarily to thoracic duct injury. A fluid triglyceride level greater than 110 mg/dL is supportive of the diagnosis, whereas less than 50 mg/dL makes thoracic duct injury unlikely⁹. Lipoprotein analysis of the pleural fluid can be helpful when triglyceride levels ambiguously fall in the 50 mg/dL to 110 mg/dL range. Fluid cholesterol to triglyceride ratio less than 1 is sensitive for a chylothorax¹⁰. Initial diagnosis can be challenging because of variable presentation. Patients may be entirely asymptomatic or present with symptoms of dyspnea and chest pain. Doerr et al. reported 37%¹ of patients with a chylothorax who presented without any respiratory symptoms, which was the case in our patient.

Chylous leaks can occur because of a variety of surgical or procedural manipulations in the thoracic cavity due to irritation of the pleura and thoracic duct¹¹. The analysis conducted by Doerr et al. of 11,315 cardiothoracic surgery patients at the Mayo Clinic revealed that postoperative chylothorax occurred in 0.42% of patients¹. However, our patient's thoracotomy and decortication with chest tube placement occurred on her contralateral side. In addition, the temporal relationship of her previous surgery is inconsistent with a traumatic etiology.

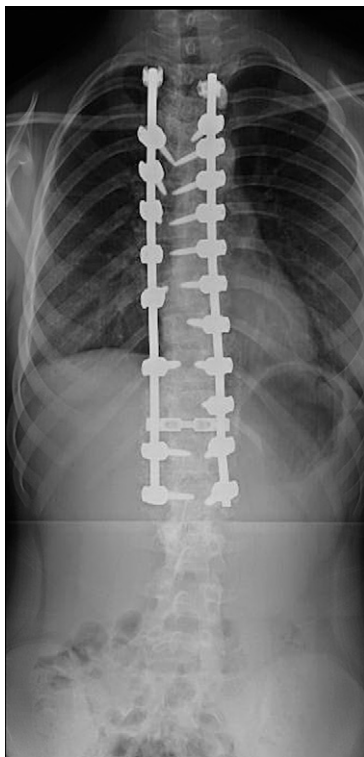


Fig. 3-A

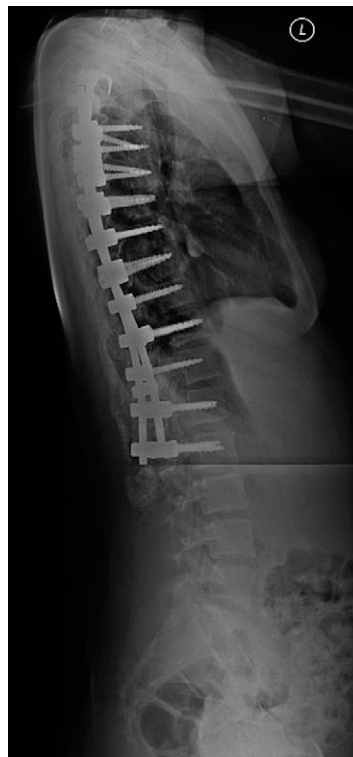


Fig. 3-B

Figs. 3-A and 3-B Postoperative standing (**Fig. 3-A**) posterior-anterior radiograph and (**Fig. 3-B**) lateral radiograph of the spine displaying correction to 23° of curvature between T4 and T11 with instrumentation.

Progressive scoliosis with an ipsilateral convex curve years after thoracotomy has been cited in the literature, many of which progresses rapidly at the time of adolescent growth spurts¹²⁻¹⁴. Definitive etiology of this patient's scoliosis is unknown, but it may be associated with her previous thoracotomy. Although the chylous leak was contralateral to her previous thoracotomy and convexity of the thoracic curve, it is possible that the decortication disrupted physiologic lymphatic flow by obliterating and damaging lymph capillaries and vessels, leading to a bilateral change in hydraulics. The loss of more proximal open-ended lymph capillaries connected in parallel, which feed into larger lymphatic vessels, could increase resistance to flow and thus increase the intraluminal pressure gradient based on Ohm's Law. In addition, it is also possible that the patient's scoliosis altered the ability of the skeletal muscles to efficiently contract, which is the mechanism responsible for forcing lymph unidirectionally against the force of gravity.

Few cases of chylous leaks during posterior spinal instrumentation have been reported. Rames et al.⁸ reported a case in which a curette was unintentionally inserted into the thorax, possibly injuring the lymphatics. Nakai and Zielke¹⁵ reported 2 cases of chylothorax after posterior instrumentation. Both patients underwent surgical correction of adolescent idiopathic scoliosis with subsequent chylothoraxes likely occurring because of adhesions from a previous thoracic duct ligation in one case and incorrect placement of a left-sided central venous catheter in the other. Our patient has no history of a previous thoracic duct ligation. However, the thoracotomy and decortication may have resulted in adhesions leading to kinks in the lymphatics. This may have further contributed to the pressure accumulation that led to a leak.

In the previously reported cases of chylous leak during posterior approach, there were no symptoms of chylothorax until many days after surgery. We hypothesize that because an intraoperative drain was placed once the chylous leak was identified, there was minimal initial accumulation of chyle, no subsequent chylothorax, and decreased morbidity and mortality⁷. The need for surgical intervention is dependent on the chyle volume. Chylous output >1 L/day typically necessitates thoracic duct embolization or surgical ligation. Chylous leaks of <1 L/day can be managed medically⁴. Nonoperative management includes a low-fat diet to minimize lymph production. Infusions of octreotide, a synthetic and long-acting somatostatin analog, have been shown to decrease absorption of triglycerides by decreasing splanchnic blood flow to the

intestines, thus decreasing lymph production^{2,16}. Theoretically, this should decrease the magnitude of the leak and assist spontaneous closure, but these possible benefits must be weighed against the drug adverse effects^{9,16,17}.

Conclusion

Although there have been cases of chylothorax reported because of posterior spinal instrumentation and fusion in patients with juvenile scoliosis, they were all recognized postoperatively and likely mechanisms of injury to the thoracic duct or lymphatics were clearly identified. To our knowledge, there is no previous report of a chylous leak recognized intraoperatively, which, in our case, enabled us to preemptively place a drain before closure. This may have contributed to avoidance of serious complications and lack of patient respiratory symptoms postoperatively. ■

Harsh A. Shah, MD¹
Nicole Rynecki, BA²
Michael J. Vives, MD²
Daniel E. Choi, MD³
Justin T. Sambol, MD⁴
Sanjeev Sabharwal, MD, MPH⁵

¹Department of Orthopaedic Surgery, University of Miami, Miami, Florida

²Department of Orthopaedic Surgery, Rutgers New Jersey Medical School, Newark, New Jersey

³Department of Orthopaedic Surgery, Zucker School of Medicine at Hofstra/Northwell, Hempstead, New York

⁴Department of Cardiothoracic Surgery, Rutgers New Jersey Medical School, Newark, New Jersey

⁵Department of Orthopaedic Surgery, University of California San Francisco, San Francisco, California

E-mail address for M.J. Vives: vivesmj@njms.rutgers.edu

ORCID iD for H.A. Shah: [0000-0001-8432-8094](https://orcid.org/0000-0001-8432-8094)

ORCID iD for N. Rynecki: [0000-0001-5565-3373](https://orcid.org/0000-0001-5565-3373)

ORCID iD for M.J. Vives: [0000-0002-2836-7504](https://orcid.org/0000-0002-2836-7504)

ORCID iD for D.E. Choi: [0000-0001-6230-5553](https://orcid.org/0000-0001-6230-5553)

ORCID iD for J.T. Sambol: [0000-0002-8012-7188](https://orcid.org/0000-0002-8012-7188)

ORCID iD for S. Sabharwal: [0000-0003-3779-1419](https://orcid.org/0000-0003-3779-1419)

References

- Doerr CH, Allen MS, Nichols FC III, Ryu JH. Etiology of chylothorax in 203 patients. *Mayo Clin Proc.* 2005;80(7):867-70.
- Tutor JD. Chylothorax in infants and children. *Pediatrics.* 2014;133(4):722-33.
- Pakula AM, Phillips W, Skinner RA. A case of a traumatic chyle leak following an acute thoracic spine injury: successful resolution with strict dietary manipulation. *World J Emerg Surg.* 2011;6:10.
- Johnson OW, Chick JF, Chauhan NR, Fairchild AH, Fan CM, Stecker MS, Killoran TP, Suzuki-Han A. The thoracic duct: clinical importance, anatomic variation, imaging, and embolization. *Eur Radiol.* 2016;26(8):2482-93.
- Akcali O, Kiray A, Ergur I, Tetik S, Alici E. Thoracic duct variations may complicate the anterior spine procedures. *Eur Spine J.* 2006;15(9):1347-51.
- Grossfeld S, Winter RB, Lonstein JE, Denis F, Leonard A, Johnson L. Complications of anterior spinal surgery in children. *J Pediatr Orthop.* 1997;17(1):89-95.
- Weening AA, Schurink B, Ruurda JP, van Hillegersberg R, Bleys RL, Kruyt MC. Chyluria and chylothorax after posterior selective fusion for adolescent idiopathic scoliosis. *Eur Spine J.* 2018;27(9):2088-92.
- Rames RD, Schoenecker PL, Bridwell KH. Chylothorax after posterior spinal instrumentation and fusion. *Clin Orthop Relat Res.* 1990(261):229-32.

- 9.** Smoke A, Delegge MH. Chyle leaks: consensus on management? *Nutr Clin Pract.* 2008;23(5):529-32.
- 10.** Staats BA, Ellefson RD, Budahn LL, Dines DE, Prakash UB, Offord K. The lipoprotein profile of chylous and nonchylous pleural effusions. *Mayo Clin Proc.* 1980;55(11):700-4.
- 11.** Limsukon A, Yick D, Kamangar N. Chylothorax: a rare complication of tube thoracostomy. *J Emerg Med.* 2011;40(3):280-2.
- 12.** Gilsanz V, Boechat IM, Birnberg FA, King JD. Scoliosis after thoracotomy for esophageal atresia. *AJR Am J Roentgenol.* 1983;141(3):457-60.
- 13.** Roclawski M, Pankowski R, Smoczynski A, Ceynowa M, Kloc W, Wasilewski W, Jende P, Liczbik W, Beldzinski P, Libionka W, Pierzak O, Adamski S, Niedbala M. Secondary scoliosis after thoracotomy in patients with aortic coarctation and patent ductus arteriosus. *Stud Health Technol Inform.* 2012;176:43-6.
- 14.** Roclawski M, Sabiniewicz R, Potaz P, Smoczynski A, Pankowski R, Mazurek T, Daibo B. Scoliosis in patients with aortic coarctation and patent ductus arteriosus: does standard posterolateral thoracotomy play a role in the development of the lateral curve of the spine? *Pediatr Cardiol.* 2009;30(7):941-5.
- 15.** Nakai S, Zielke K. Chylothorax—a rare complication after anterior and posterior spinal correction. Report on six cases. *Spine (Phila Pa 1976).* 1986;11(8):830-3.
- 16.** Roehr CC, Jung A, Proquitté H, Blankenstein O, Hammer H, Lakhoo K, Wauer RR. Somatostatin or octreotide as treatment options for chylothorax in young children: a systematic review. *Intensive Care Med.* 2006;32(5):650-7.
- 17.** Marcon F, Irani K, Aquino T, Saunders JK, Gouge TH, Melis M. Percutaneous treatment of thoracic duct injuries. *Surg Endosc.* 2011;25(9):2844-8.