

**UCLA**

**Proceedings of UCLA Health**

**Title**

Lemierre's Syndrome and Diagnostic Utility of Cell Free DNA Analysis

**Permalink**

<https://escholarship.org/uc/item/1223t0z9>

**Journal**

Proceedings of UCLA Health, 28(1)

**Authors**

Szatkowski, Jesse

Ly, Alexandra R.

**Publication Date**

2024-08-09

## CLINICAL VIGNETTE

# Lemierre's Syndrome and Diagnostic Utility of Cell Free DNA Analysis

Jesse Szatkowski, MD and Alexandra R. Ly, MD

### Introduction

Lemierre's syndrome is an uncommon condition. It typically begins as a bacterial infection of the oropharynx that leads to thrombophlebitis of the jugular vein with numerous potential complications. Lemierre's Syndrome can be challenging to diagnose and treat. We review the utility of cell free DNA analysis of patient serum to help identify infections that cannot or are difficult to detect via conventional methods.

### Case Summary

A 53-year-old female with no known medical history presented to the Emergency Department with two weeks of persistent headaches. She also complained of three days of progressively worsening dizziness, nausea, and vomiting. Two days prior to presentation, she developed neck pain, vision changes, fevers, chills, and diarrhea.

The physical exam was notable for fever along with nuchal rigidity. Her neurologic exam revealed bilateral dysmetria on finger to nose testing, abnormal finger tapping, and slowing and irregularity of rapid alternating movements. She also had an ataxic gait and was unable to ambulate independently. Laboratory testing was significant for a white count of 32.8. Given the concern for meningitis the patient underwent lumbar puncture. Cerebral spinal fluid (CSF) results included CSF red blood cell count of 83, CSF nucleated cell count of 296. The nucleated cell count differential was 86% segmented neutrophils and 11% lymphocytes. Additional CSF studies were significant for a CSF Glucose of 18mg/dL and a CSF Protein of 131mg/dL.

Given her neurologic symptoms, she underwent advanced imaging with a non-contrast CT head scan head showing no acute intracranial pathology. Subsequent contrast enhanced brain MRI of the brain which demonstrated a moderate area of reduced diffusion in the right superior and inferior cerebellar vermis as well as right cerebellar hemisphere. These findings were most compatible with an acute infarct, likely a venous infarct due to dural venous sinus thrombosis. Further CT scanning with CT angiography and venography of the head and neck with contrast showed a non-occlusive thrombus in the right internal jugular vein and right sigmoid sinus.

The patient was started on antibiotic treatment with high concern for bacterial meningitis given the abnormal CSF results. However, CSF and blood culture results were persistently

negative for growth of any organism. Infectious disease was consulted and recommended the use cell free DNA analysis of the patient's serum, given high concern for infection despite negative cultures. Cell free DNA analysis showed *Fusobacterium nucleatum* and *Porphyromonas gingivalis* and she was diagnosed with Lemierre's syndrome. Her antibiotics were tailored, and she received a 6-week course. The suspected source was two teeth with peri-apical lucencies and she subsequently underwent dental extraction. The patient developed significant neurologic deficits related to her cerebellar stroke. She needed significant assistance with transfers and ambulation and was discharged to an acute rehabilitation hospital for inpatient physical therapy. She improved with physical therapy but has long term deficits with gait and ambulation requiring the use of a front wheel walker.

### Discussion

Lemierre's syndrome is septic thrombophlebitis of the internal jugular vein which typically arises from an infection in the oropharyngeal cavity. This infection leads to inflammation of the surrounding tissue and walls of the vein resulting in an infected thrombus within the lumen of the jugular vein. Lemierre's syndrome is typically due to oropharyngeal flora, with the most common being *Fusobacterium necrophorum*.<sup>1</sup> *Fusobacterium necrophorum* is an anaerobic gram-negative bacillus and often takes over 5 days to grow on cultures if it does grow at all. Complications of Lemierre's syndrome include hematogenous spread commonly to the pulmonary system or large joints. Necrotic pulmonary cavitory lesions due to septic pulmonary emboli are commonly seen.<sup>2</sup> As described in our case meningitis and stroke are uncommon complications but have been reported.<sup>3</sup>

The mainstay of treatment of Lemierre's syndrome involves antibiotics. If the pathogen is isolated to be *Fusobacterium necrophorum* then the typical treatment is metronidazole monotherapy, as antimicrobial resistance is rare. Treatment is at least four weeks, but may be extended if treatment complications develop. Response to treatment can often be slow and deference can take over a week.

Because Lemierre's syndrome involves thrombosis of the internal jugular vein there is also discussion of the utility of anticoagulation. There are limited data to guide this decision, but most patients do not receive anticoagulation. Specifically

our patient's cerebellar infarcts were reviewed and did not provide her with anticoagulation.

We utilized cell-free DNA testing which has been used in a variety of clinical scenarios. The test uses fragments of DNA from the pathogen found in the patient's serum. These tests can identify microbial cell-free DNA from a wide range of bacteria, fungi, viruses, and parasites. This test was able to detect the suspected organism and confirm the diagnosis despite repeatedly negative blood cultures. Some barriers to use of cell-free DNA testing include: the turnaround time, cost, and inability to identify RNA viruses. The specificity of the test is also relatively low and can result in a significant number of false-positive results.<sup>4</sup>

### Conclusion

Lemierre's syndrome is a rare bacterial infection with thrombosis of the jugular vein that can result in serious complications. Our patient suffered severe neurologic complications with a cerebellar stroke due to her infection. It is important to treat Lemierre's syndrome with appropriate antibiotic therapy. Additionally, the utilization of cell-free DNA testing can be extremely helpful in the correct clinical situations to assist with diagnosis when culture data is persistently negative.

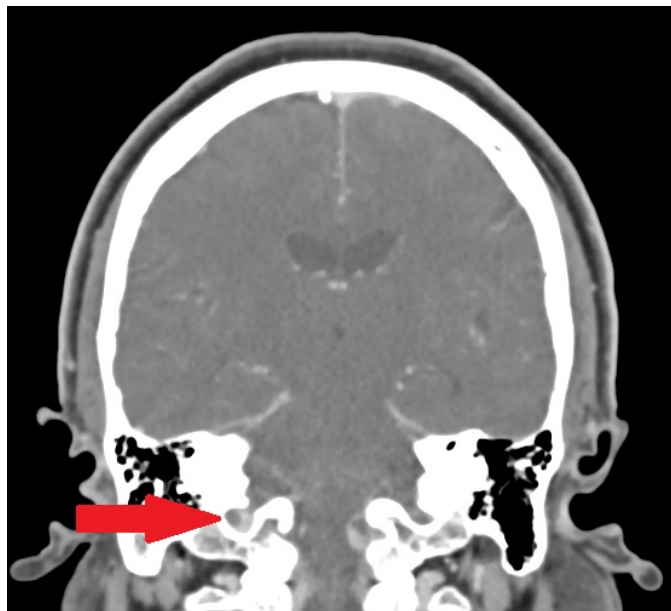


Figure 1. CT venography of the head showing a nonocclusive thrombus in the right sigmoid sinus.

### REFERENCES

1. **Riordan T.** Human infection with *Fusobacterium necrophorum* (Necrobacillosis), with a focus on Lemierre's syndrome. *Clin Microbiol Rev.* 2007 Oct;20(4):622-59. doi: 10.1128/CMR.00011-07. PMID: 17934077; PMCID: PMC2176048.

2. **Karkos PD, Asrani S, Karkos CD, Leong SC, Theochari EG, Alexopoulou TD, Assimakopoulos AD.** Lemierre's syndrome: A systematic review. *Laryngoscope.* 2009 Aug;119(8):1552-9. doi: 10.1002/lary.20542. PMID: 19554637.
3. **Aggarwal SK, Nath A, Singh R, Keshri A.** Lemierre's Syndrome presenting with neurological and pulmonary symptoms: Case report and review of the literature. *Ann Indian Acad Neurol.* 2013 Apr;16(2):259-63. doi: 10.4103/0972-2327.112489. PMID: 23956578; PMCID: PMC3724088.
4. **Blauwkamp TA, Thair S, Rosen MJ, Blair L, Lindner MS, Vilfan ID, Kawli T, Christians FC, Venkatasubrahmanyam S, Wall GD, Cheung A, Rogers ZN, Meshulam-Simon G, Huijse L, Balakrishnan S, Quinn JV, Holleman D, Hong DK, Vaughn ML, Kertesz M, Bercovici S, Wilber JC, Yang S.** Analytical and clinical validation of a microbial cell-free DNA sequencing test for infectious disease. *Nat Microbiol.* 2019 Apr;4(4):663-674. doi: 10.1038/s41564-018-0349-6. Epub 2019 Feb 11. PMID: 30742071.