

UCSF

UC San Francisco Previously Published Works

Title

Expanding Candidacy for Nipple-sparing Mastectomy in Women with Large or Ptotic Breasts: Staged Reconstruction Outcomes.

Permalink

<https://escholarship.org/uc/item/11t427z6>

Journal

Plastic and reconstructive surgery. Global open, 11(1)

ISSN

2169-7574

Authors

Barnes, Laura L

Foster, Rob

Mukhtar, Rita A

et al.

Publication Date

2023

DOI

10.1097/gox.0000000000004767

Copyright Information

This work is made available under the terms of a Creative Commons Attribution-NonCommercial-NoDerivatives License, available at

<https://creativecommons.org/licenses/by-nc-nd/4.0/>

Peer reviewed

Expanding Candidacy for Nipple-sparing Mastectomy in Women with Large or Ptotic Breasts: Staged Reconstruction Outcomes

Laura L. Barnes, MD*
 Rob Foster, MD*
 Rita A. Mukhtar, MD†
 Laura J. Esserman, MD, MBA†
 Cheryl Ewing, MD†
 Michael Alvarado, MD†
 Jasmine Wong, MD†
 Merisa Piper, MD*

Background: Development of the nipple-sparing mastectomy (NSM) technique has dramatically improved breast reconstruction, and preservation of the nipple–areolar complex (NAC) positively influences patient satisfaction. However, women with large, ptotic breasts have historically not been candidates for NAC preservation due to impaired perfusion of the NAC leading to NAC loss. Although reduction mammoplasty has been reported as a strategy to increase candidacy for NSM, success rates and surgical outcomes for this staged approach are not well described in heterogeneous clinical scenarios.

Methods: We performed a retrospective chart review of all patients who underwent reduction mammoplasty followed by NSM at our institution between January 2014 and September 2020. Clinical and surgical characteristics were collected. All surgical complications, including NAC loss rates, were analyzed.

Results: Forty-one patients (74 breasts) underwent staged NSM during the defined time period. The average time between breast reduction mammoplasty and NSM was 213 days. Overall, 94.6% of NSM resulted in successful nipple preservation. There was no significant difference in the time interval from breast reduction mammoplasty to NSM between patients who had NAC loss (208 days) and those who did not (213 days, $P = 0.87$). Increasing age was significantly associated with risk of NAC loss ($P = 0.002$) in our cohort.

Conclusions: In women with breast ptosis (which precludes safe NSM), it is possible to first offer reduction mammoplasty to preserve the NAC for future NSM. Our data suggest that 3 months between staged procedures is a safe time frame. (*Plast Reconstr Surg Glob Open* 2023; 11:e4767; doi: [10.1097/GOX.00000000000004767](https://doi.org/10.1097/GOX.00000000000004767); Published online 25 January 2023.)

INTRODUCTION

Over the last two decades, nipple-sparing mastectomy (NSM) has become a widely accepted technique for both therapeutic and prophylactic purposes, progressively gaining in popularity amongst oncologists, breast surgeons, reconstructive surgeons, and patients alike.^{1–6} Its oncologic safety has been established in women with stage I and II breast cancer excluding the nipple–areolar

complex (NAC) and in those whose tumors have been downstaged after neoadjuvant therapy.⁶ Breast surgeons and reconstructive surgeons have become progressively more comfortable with this technique, observing increasingly favorable outcomes with greater experience.² Objectively improved breast cosmesis and patient satisfaction have been demonstrated in breast reconstruction with preservation of the NAC.^{7–9} In conjunction with the evolving literature supporting the safety of and satisfaction from NSM in the therapeutic setting, a growing number of patients are seeking prophylactic NSM due to genetic cancer predispositions and for risk reduction in the contralateral breast.^{8–13}

As the demand for NSM has grown, we continue to work to expand candidacy for this technique from both

From the *Division of Plastic and Reconstructive Surgery, University of California, San Francisco, Calif.; and †Division of Breast Care Surgery, University of California, San Francisco, Calif. Received for publication July 21, 2022; accepted November 21, 2022.

Presented at Plastic Surgery The Meeting 2021, Atlanta, Georgia.

Copyright © 2023 The Authors. Published by Wolters Kluwer Health, Inc. on behalf of The American Society of Plastic Surgeons. This is an open-access article distributed under the terms of the [Creative Commons Attribution-Non Commercial-No Derivatives License 4.0 \(CCBY-NC-ND\)](https://creativecommons.org/licenses/by-nc-nd/4.0/), where it is permissible to download and share the work provided it is properly cited. The work cannot be changed in any way or used commercially without permission from the journal.

DOI: [10.1097/GOX.00000000000004767](https://doi.org/10.1097/GOX.00000000000004767)

Disclosure: The authors have no financial interest to declare in relation to the content of this article.

Related Digital Media are available in the full-text version of the article on www.PRSGlobalOpen.com.

an oncologic and reconstructive perspective. Women with large, ptotic breasts historically have not been considered candidates for this procedure due to concern for risk of NAC ischemia and loss. Many surgeons instead perform skin-sparing mastectomies in these patients, in which the nipple is removed.

Given that preservation of the NAC has a dramatic effect on cosmesis and a positive influence on patient satisfaction after reconstruction, we have undertaken the practice of staging NSM in select patients, with the goal of saving the NAC. Performing an NSM after a reduction mammoplasty is thought to improve NAC preservation by repositioning the NAC to a more favorable position on the breast mound, reducing the future mastectomy skin flap length, and improving blood supply to both the NAC and the skin flap through a delay-type phenomenon.^{14,15}

Few prior series have described outcomes in limited cohorts of patients who underwent staged NSM after mastopexy or breast reduction, reporting a 0% to 4% NAC loss rate.^{14,16,17} Here we aimed to further characterize the outcomes of NSM after breast reduction mammoplasty by evaluating complication profiles at each staged procedure and by determining clinical correlates with NAC loss.

METHODS

Study Design and Data Collection

A retrospective chart review was performed of all patients who underwent breast reduction mammoplasty followed by NSM at a single institution between January of 2014 and September of 2020. Data on patient demographics, comorbidities, body mass index (BMI), diagnosis, timing of operations, operative characteristics, and adjuvant therapies were collected and analyzed. Complication rates were collected, including partial or complete NAC loss, mastectomy flap necrosis, infection, need for re-admission or re-operation, and reconstructive failure.

Patient Selection

All women included in this study were deemed candidates for an NSM from an oncologic perspective, but not from a reconstructive perspective. All were documented to have pendulous breasts with at least grade 2 ptosis. All had either a breast malignancy or genetic breast cancer predisposition and were thus seeking therapeutic or prophylactic surgery at the time of the initial breast reduction. For patients who were planning to undergo mastectomy at the time of the initial plastic surgery consultation, clinical examination by the plastic surgeon determined the need for a staged procedure. In some women, breast conservation in conjunction with oncoplastic bilateral reductions was attempted first, but due to pathology findings, the oncologic plan was later converted to NSM.

Operative Technique

The first stage operation for all patients included in this study was a breast reduction mammoplasty. In women undergoing therapeutic operations, the first stage involved partial mastectomy and oncoplastic reduction with the expectation that the patients would return to the operating room in

Takeaways

Question: This study investigates how we can offer nipple-sparing mastectomies (NSM) to women with large, ptotic breasts.

Findings: In our retrospective review of 41 patients, we found that staged NSMs can be successfully performed in women with large, ptotic breasts, with low overall rates of nipple areolar complex (NAC) loss.

Meaning: In women with breast ptosis which precludes safe NSM, it is possible to first offer reduction mammoplasty in order to preserve the NAC for future NSM.

approximately 3 months for completion mastectomies and further reconstruction. The time interval between reduction mammoplasty and completion NSM was empirically chosen to be approximately 3 months, but in some cases was longer due to need for adjuvant therapy or patient desire. All patients underwent an NSM in the second stage operation. Reconstruction at the time of the NSM was performed using either a delayed-immediate implant-based approach, delayed-immediate autologous approach, or immediate autologous approach. Skin incision patterns and pedicle choices were based on a patient's oncologic characteristics and individual surgeon preferences.

Statistical Analysis

Clinical and operative variables were analyzed with respect to NAC loss, including age, BMI, indication for mastectomy, time interval between operations, reduction pedicle, mastectomy incision, and adjuvant therapies. Continuous variables were analyzed using a two-tailed *t* test, and dichotomous and categorical variables were analyzed using Fisher exact tests.

RESULTS

Patient and Tumor Characteristics

Forty-one patients (74 breasts) underwent breast reduction mammoplasty followed by NSM between January 2014 and September 2020. The average follow-up period was 21.7 ± 14.2 months. The average time between breast reduction mammoplasty and NSM was 213 days (range 70–1176 days, median 217 days). Staged procedures were planned in 32 patients (80%) and initially unplanned or coincidental in nine patients (20%).

Patient demographics, BMI, comorbidities, oncologic characteristics, and operative characteristics are described in Table 1. The average patient age at the time of breast reduction mammoplasty was 45.0 ± 9.3 years. The average patient BMI was 28.4 ± 4.9 . The average reduction weight was 291.1 ± 139.4 g (available for 30 breasts). The average mastectomy specimen weight was 620.5 ± 209.4 g (available for 34 breasts). Six patients (15%) had hypertension, five patients (12%) had hyperlipidemia, five patients (12%) had an autoimmune disease (15%), and three patients had diabetes (5%). No patients had coronary artery disease and no patients were current smokers. Mastectomies were therapeutic in 33 breasts (45%) and prophylactic in

Table 1. Patient Demographics, BMI, Comorbidities, Oncologic Characteristics, and Operative Characteristics

	Patient Age (y)	BMI (kg/m ²)	Comorbidities (%)	Therapeutic	Adjuvant Therapy	Time from Reduction to NSM (d)	Reduction Pedicle (%)	Reduction Incision (%)	Mastectomy Incision (%)	Mastectomy Weight (g)
Overall (n = 41 patients, n = 74 breasts)	45.0 ± 9.25	28.4 ± 4.9	Coronary artery disease (0) Diabetes (7.3) Hyperlipidemia (12.2) Hypertension (14.6) Autoimmune disease (12.2) Current smokers (0)	75.6% of patients, 44.6% of breasts	Chemotherapy: 41.4% of patients Radiation: 5.4% of breasts	213 ± 160	Inferior (71.6) Superomedial (23.0) Inferior and superior (4.1) Medial (1.4)	Wise pattern (81.1) Vertical pattern (18.9)	Inframammary fold (90.5) Periareolar (6.8) Vertical limb (2.7)	620.5 ± 209.4
Implant-based final reconstruction (n = 27 patients, n = 49 breasts)	43.5 ± 9.1	27.4 ± 4.4	Coronary artery disease (0) Diabetes (3.7) Hyperlipidemia (11.1) Hypertension (14.8) Autoimmune disease (14.8) Current smokers (0)	74.1% of patients, 44.9% of breasts	Chemotherapy: 48.1% of patients Radiation: 8.2% of breasts	226 ± 181	Inferior (81.6) Superomedial (16.3) Inferior and superior (2.0) Medial (0)	Wise pattern (83.7) Vertical pattern (16.3)	Inframammary fold (95.9) Periareolar (0) Vertical limb (4.1)	588.5 ± 182.8
Autologous final reconstruction (n = 15 patients, n = 25 breasts)	48.1 ± 9.0	30.4 ± 4.4	Coronary artery disease (0) Diabetes (13.3) Hyperlipidemia (26.7) Hypertension (20.0) Autoimmune disease (6.7) Current smokers (0)	66.7% of patients, 44.0% of breasts	Chemotherapy: 40% of patients Radiation: 0% of breasts	189 ± 101	Inferior (52.0) Superomedial (36.0) Inferior and superior (8.0) Medial (4.0)	Wise pattern (76.0) Vertical pattern (24.0)	Inframammary fold (80.0) Periareolar (20.0) Vertical limb (0)	637.4 ± 211.0

41 breasts (55%), with two patients undergoing bilateral NSM for malignancy, 28 patients undergoing unilateral NSM for malignancy, 20 also undergoing contralateral prophylactic mastectomy, and 10 undergoing bilateral risk-reducing NSM. Among those with malignancy, seven had stage I disease, 11 had stage II disease, seven had stage III disease, and eight had in situ disease only.

Surgical Techniques and Adjuvant Therapies

Figures 1 and 2 depict two patient cases from our series. An inferior reduction pedicle was used in 53 breasts (72%), a superomedial pedicle in 17 breasts (23%), both inferior and superior pedicles in three breasts (4%), and a medial pedicle in one breast (1%). The reduction incision utilized was Wise pattern in 60 breasts (81%) and vertical pattern in 14 breasts (19%). The mastectomy incision was made at the inframammary fold in 67 breasts (90%), periareolar in five breasts (7%), and at the vertical limb scar in two breasts (3%). The final stage of reconstruction was implant-based in 49 breasts (66%) and autologous in 25 breasts (34%). Three patients (six breasts) underwent immediate autologous reconstruction at the time of NSM. Nine patients (22.0%) received neoadjuvant chemotherapy, eight patients (19.5%) received adjuvant chemotherapy, and four breasts (5%) were treated with radiation therapy. Radiation was given after the lumpectomy with oncoplastic breast reduction mammoplasty in three cases, and after NSM in one case.

Outcomes

Complication rates by operation stage and type are described in Table 2. In this series of 41 patients who underwent 74 staged NSM, a total of 19 patients (46.3%) had any surgical complication. Complications were most common at the time of NSM, and occurred in 8% of breasts after reduction, 21% of breasts after NSM with tissue expander, 26% of breasts after autologous reconstruction, and 12% of breasts after expander exchange. After initial reduction, the most common complication was infection (4%) followed by seroma (3%) and hematoma (1%). After NSM with tissue expander placement, the most common complication was infection (16%), two of which led to implant loss (3%). The overall complication rate after the implant exchange procedure was 12%, with an infection rate of 6%, all of which led to implant loss. Rate of capsular contracture requiring operative correction was 6%. One patient who underwent implant-based reconstruction experienced partial NAC loss (2%).

The overall complication rate after immediate-delayed autologous reconstruction was 26%. One breast experienced complete flap loss (5%) and one breast had partial flap loss (5%). Two NACs were completely lost (11%) and one was partially lost (5%). One of the six breasts that underwent immediate autologous reconstruction after NSM experienced an infection (17%).

Complication rates for each stage in patients who underwent bilateral prophylactic mastectomies were compared to those in patients who had cancer in at least

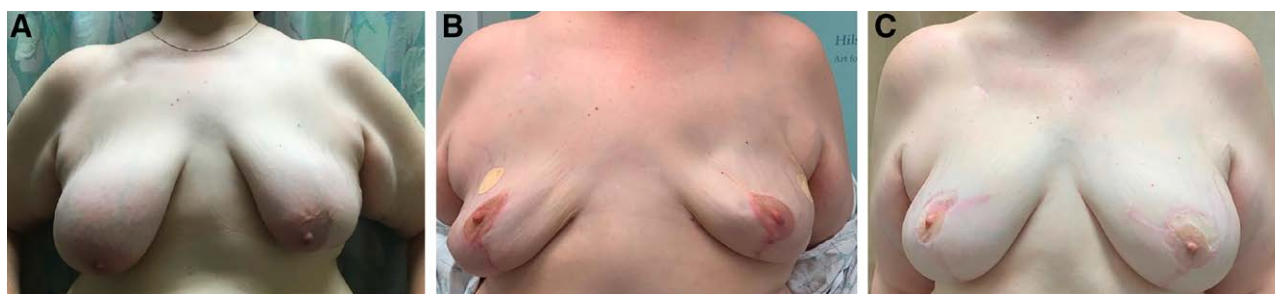

Fig. 1. This case is a 53-year-old woman with a known BRCA1 pathogenic variant who underwent staged bilateral risk-reducing mastectomies, starting with bilateral breast reduction with superomedial pedicles and vertical pattern incisions. Five months later, she underwent bilateral nipple-sparing mastectomies via inframammary fold incisions with tissue expander placement. She then underwent bilateral delayed autologous breast reconstruction 6 months later. After her final stage operation, she experienced partial right NAC necrosis (upper outer NAC). (A) Preoperative photograph. (B) Post-NSM with tissue expander placement outcome. (C) Final reconstruction outcome.

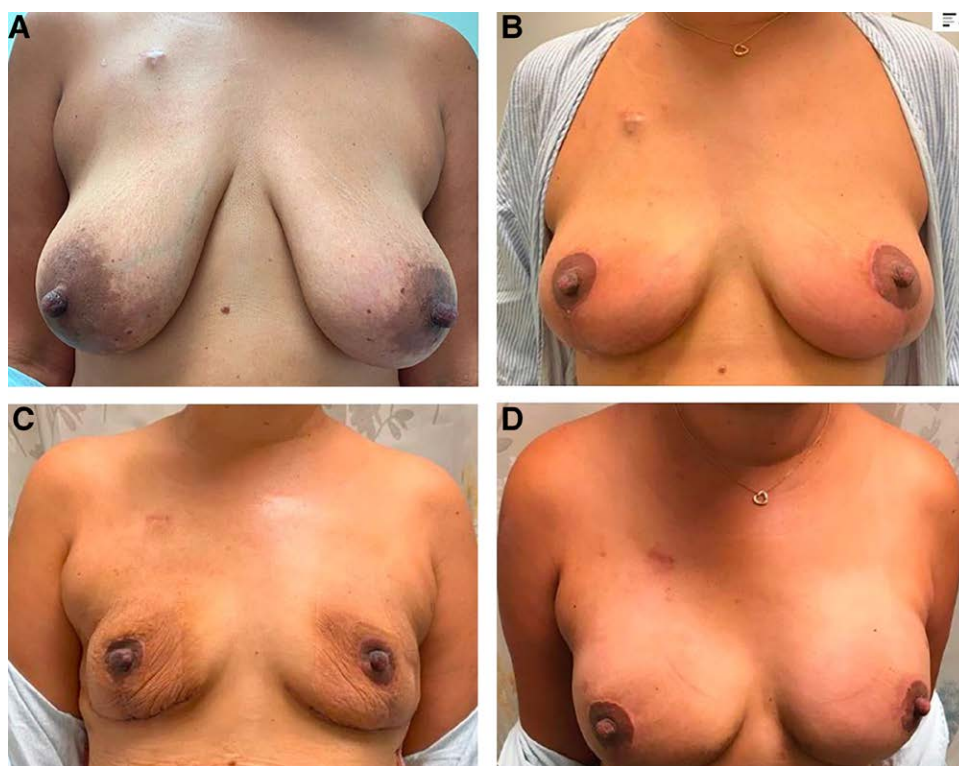


Fig. 2. This case is a 48-year-old woman with a right-sided breast cancer and known BRCA2 pathogenic variant. She underwent a right partial mastectomy with bilateral oncoplastic breast reduction with inferior pedicles and wise pattern incisions. Three months later, she underwent bilateral nipple-sparing mastectomies via inframammary fold incisions with tissue expander placement. She then underwent final exchange of tissue expanders for permanent implant 6 months later. (A) Preoperative photograph. (B) Postreduction outcome. (C) Post-NSM with tissue expander placement outcome. (D) Final reconstruction outcome.

one breast. (See table 1, Supplemental Digital Content 1, which displays complication rates by operation stage, comparing prophylactic to therapeutic cases. <http://links.lww.com/PRSGO/C354>). There were no significant differences between these groups.

Complication rates in patients who underwent NSM less than 100 days after breast reduction mammoplasty are compared with rates in patients who had their second

operation more than 100 days after breast reduction. (See table 2, Supplemental Digital Content 2, which displays complication rates by operation stage, comparing cases in which NSM was performed less than 100 days after breast reduction to those performed more than 100 days after breast reduction. <http://links.lww.com/PRSGO/C355>). There were no significant differences between these groups.

Table 2. Complication Rates by Operation Stage and Type

Complication	Reduction (n = 74), n (%)	NSM with Tissue Expanders (n = 68), n (%)	Implant Exchange (n = 49), n (%)	Delayed Autologous (n = 19), n (%)	Immediate Autologous (n = 6), n (%)
Overall	6 (8.1)	14 (20.6)	6 (12.2)	5 (26.3)	1 (16.7)
Return to OR	1 (1.4)	4 (5.9)	6 (12.2)	3 (15.8)	0 (0.0)
Readmission	0 (0.0)	2 (2.9)	3 (6.1)	1 (5.3)	0 (0.0)
IR intervention	2 (2.7)	3 (4.4)	0 (0.0)	0 (0.0)	0 (0.0)
Wound requiring OR	0 (0.0)	2 (2.9)	2 (4.1)	3 (15.8)	0 (0.0)
Infection requiring PO antibiotics	3 (4.1)	11 (16.2)	3 (6.1)	1 (5.3)	1 (16.7)
Infection requiring IV antibiotics	0 (0.0)	3 (4.4)	3 (6.1)	1 (5.3)	0 (0.0)
Infection leading to explant	N/A	2 (2.9)	3 (6.1)	N/A	N/A
Hematoma	1 (1.4)	0 (0.0)	0 (0.0)	0 (0.0)	0 (0.0)
Seroma	2 (2.7)	4 (5.9)	0 (0.0)	0 (0.0)	0 (0.0)
Capsular contracture	N/A	0 (0.0)	4 (8.2)	N/A	N/A
Nipple loss (partial)	0 (0.0)	1 (1.4)	1 (2.0)	2 (10.5)	0 (0.0)
Nipple loss (full)	0 (0.0)	0 (0.0)	0 (0.0)	1 (5.3)	0 (0.0)
Flap loss (full)	N/A	N/A	N/A	1 (5.3)	0 (0.0)
Flap loss (partial)	N/A	N/A	N/A	1 (5.3)	0 (0.0)

IV, intravenous; NSM, nipple-sparing mastectomy; OR, operating room; PO, per oral.

Table 3. Demographics, BMI, Comorbidities, Oncologic Characteristics, and Operative Characteristics in Patients with NAC Loss Compared with Those without NAC Loss

	NAC Loss	No NAC Complication	P
Age (y)	59.1 ± 7.7	44.3 ± 8.8	0.002
BMI (kg/m ²)	31.3 ± 4.8	28.2 ± 4.9	0.239
Therapeutic indication	1/33 breasts	32/33 breasts	0.623
Interval between operations (d)			
BRM and NSM	208 ± 136	213 ± 162	0.869
NSM and final reconstruction	133 ± 34	129 ± 115	0.914
Reduction pedicle			
Inferior	2/53 breasts	51/53 breasts	0.318
Superomedial	2/17 breasts	15/17 breasts	0.224
Mastectomy incision			
IMF	3/67 breasts	64/67 breasts	0.334
Periareolar	1/5 breasts	4/5 breasts	0.249
Mastectomy weight (g)	617.5 ± 151.0	620.9 ± 218.0	0.976
Adjuvant therapy			
Chemotherapy	2/31 breasts	29/31 breasts	1.000
Radiation	1/4 breasts	3/4 breasts	0.203

BRM, breast reduction mammoplasty; IMF, inframmary fold; NSM, nipple-sparing mastectomy.

In total, any NAC loss occurred in four breasts (5%), with two out of 74 breasts experiencing partial NAC loss and two of 74 breasts having total NAC loss. One NAC also required resection for positive margins. No patients had mastectomy skin flap necrosis. The characteristics of the patients who experienced NAC loss are shown in Table 3.

The only factor significantly associated with nipple loss was age, with patients experiencing nipple loss being significantly older than those who did not (mean age 59.1 versus 44.3 years respectively, $P = 0.002$). (See table 3, Supplemental Digital Content 3, which displays characteristics of patients who experienced NAC loss. <http://links.lww.com/PRSGO/C356>). Although the average BMI was greater in patients who had NAC loss (31.3 kg/m²) compared to those who did not (28.2 kg/m²), this was not

statistically significant ($P = 0.24$). There was no significant difference in the time interval from breast reduction mammoplasty to NSM between patients who had NAC loss (208 days) and those who did not (213 days, $P = 0.87$). Likewise, there was no significant difference in the time interval from NSM to final reconstruction between patients who had NAC loss (133 days) and those who did not (129 days, $P = 0.73$). Therapeutic indication, reduction pedicle, mastectomy incision, mastectomy weight, and receipt of adjuvant chemotherapy or radiation were not significantly associated with NAC loss. Notably, patients who received radiation after their breast reduction had a significantly greater duration from breast reduction mammoplasty to NSM (436.3 ± 185.5 versus 235.6 ± 155.3 days, $P = 0.033$). Patients who received adjuvant chemotherapy had similar durations from breast reduction mammoplasty to NSM (203.0 ± 37.8 versus 254.1 ± 177.3 days, $P = 0.273$).

All cases of partial or complete NAC loss were initially managed with local wound care. One of the complete NAC loss cases had a tenuous NAC completely removed after an autologous flap was lost in the setting of venous thrombosis. The other complete NAC loss case was entirely managed in clinic with wound care and debridement. One partial NAC loss case developed cellulitis requiring admission for IV antibiotics, and went on to be definitively debrided in the operating room. One partial NAC loss case was entirely managed in clinic with wound care and debridement.

DISCUSSION

This series describes the largest cohort to date of patients with macromastia and/or grade 2 or 3 ptosis who have undergone a staged NAC repositioning procedure before NSM in an effort to preserve the NAC. We showed that by first performing reduction mammoplasty, mastectomy with successful preservation of the NAC was possible in 94.6% of breasts that were otherwise deemed at risk for NAC ischemia after NSM.

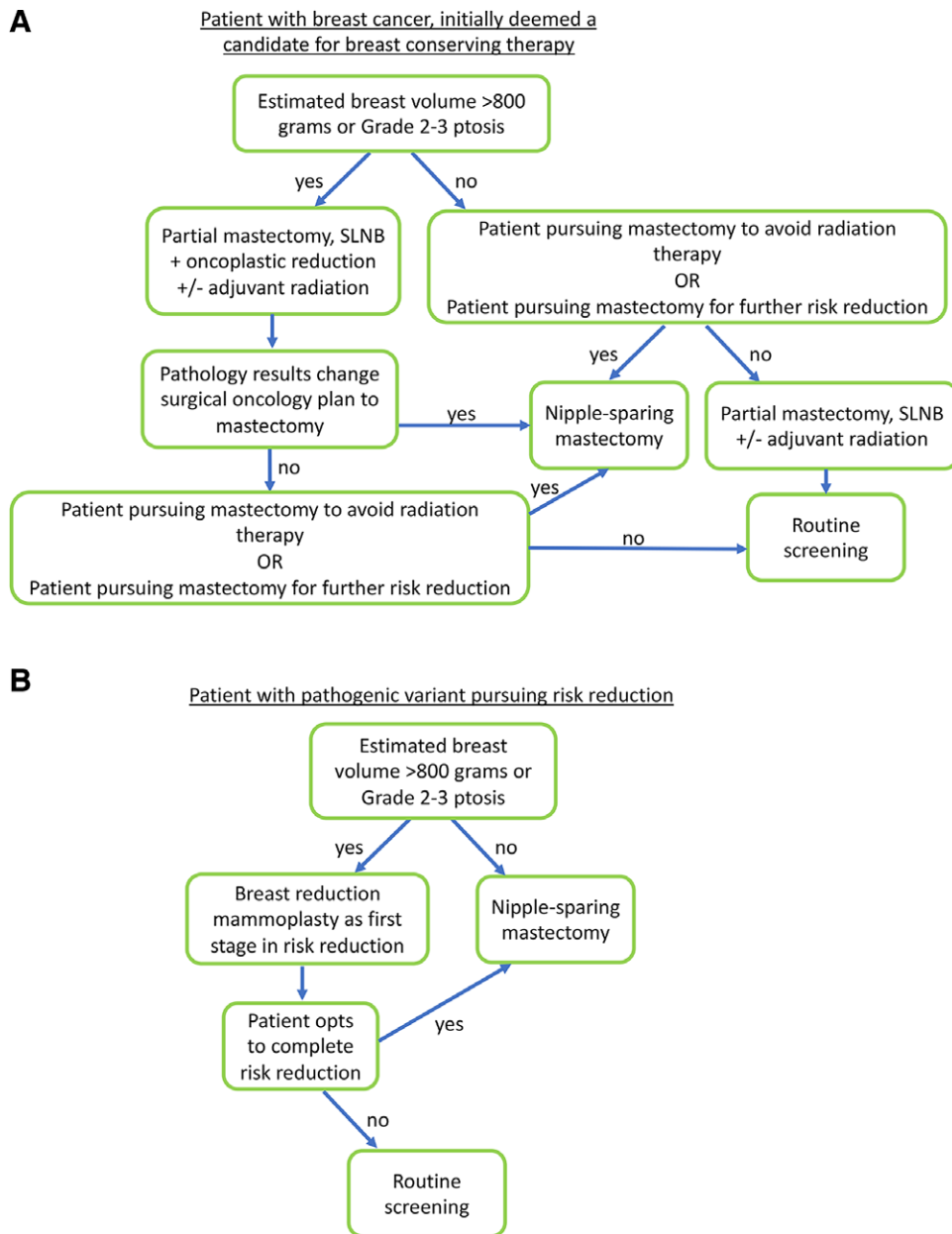


Fig. 3. Decision algorithm for women with large or ptotic breasts. A, Decision algorithm for a patient with breast cancer who is deemed a candidate for breast conserving therapy. B, Decision algorithm for a patient with a pathogenic variant who is pursuing risk reduction.

Given our favorable results in this population, we have developed an algorithm in which we use an estimated breast volume greater than 800g or ptosis grades 2–3 as measures to guide the plastic surgeon to stage the NSM (Fig. 3). This algorithm was determined by considering our cohort’s average reduction weights (291.1 ± 139.4 g) and average mastectomy weights (620.5 ± 209.4 g).

Prior studies reviewing traditional candidate patients undergoing an NSM report NAC loss rates of 0.7% to 18%.^{2–4,6,8,18–21} Two case series and a matched cohort study reviewing the outcomes in patients who had initially undergone a breast reduction or mastopexy followed later by an NSM (either planned or unplanned) report NAC

loss rates of 0% to 5.6%.^{14–16,22} The matched cohort study compared patients who underwent staged breast reduction before NSM with those who underwent nonstaged NSM with similar risk profiles, and demonstrated a significant decrease in major mastectomy flap necrosis rates with the staged approach, as well as a trend toward improved partial NAC loss rates in those patients.¹⁵ Given the relatively rare occurrence of nipple loss, even in this series, which is the largest of its kind, our results may not be adequately powered to determine all predictors of NAC loss. Still, we did find that patients who experienced nipple loss were significantly older at the time of the initial stage of breast reduction mammoplasty, suggesting that aging may

be associated with impairment in the neovascularization process required for a surgical delay to be successful.

A limited series of eight patients (13 breasts) who had previously undergone a reduction mammoplasty or mastopexy and then coincidentally later required an NSM did not have any incidences of NAC loss.²³ The large time interval between the two procedures for patients in that study has been postulated to suggest a relationship between time interval between procedures and NAC loss.¹⁵ However, our results do not indicate a significant relationship between the time interval from breast reduction mammoplasty to NSM and NAC loss, suggesting that a time interval as short as 70 days (the shortest time interval for a patient in this series) is safe. We typically aim to perform the second stage operation of NSM at 3 months, allowing for healing and commencement of cancer treatment, including chemotherapy, in the interim.

A prior study investigating correlates with NAC loss in traditional NSM patients found that patients who developed mastectomy skin flap necrosis had a significantly higher BMI than those who did not.²⁴ It is reasonable to extrapolate these data on mastectomy skin flap necrosis to NAC loss as the same mechanism of ischemia causes both outcomes. The population represented in our study had a higher average BMI than any prior studies reviewing outcomes after NSM. The average BMI in patients who had nipple loss (31.3 kg/m^2) was greater than those who did not (28.3 kg/m^2); however, this was not statistically significant ($P = 0.24$). Although we unfortunately do not consistently have breast reduction weights or mastectomy weights recorded at our institution, we did have mastectomy weights recorded in 34 patients, including those of the four breasts that had NAC loss. The mastectomy weights of breasts that had NAC loss were comparable to those without this complication (617.5 versus 620.9 g , $P = 0.976$).

The impact of mastectomy incision choice on outcomes in NSM has been well studied. Inframammary fold (IMF) incisions have broadly been found to be protective²⁴ for NAC perfusion, while periareolar incisions have been associated with increased complication rates²⁴ and increased rates of NAC ischemia.²⁵ Our study did not find protection against NAC loss with IMF incisions, ($P = 0.33$) nor did it find increased NAC loss with periareolar incisions ($P = 0.25$).

Prior research has also demonstrated increased NAC necrosis with therapeutic operations and with receipt of radiation.^{24,25} Neither of these factors were found to be associated with increased risk of NAC loss in our population ($P = 0.62$ and $P = 0.20$, respectively). However, with only three patients receiving radiation between breast reduction mammoplasty and NSM in our study, it is possible we are not powered to determine increased risk of NAC loss from this therapy. Given that the average duration between these stages was significantly greater in the patients who received radiation in the interim, it may be advisable to delay NSM for greater than 100 days in patients requiring radiation therapy after oncoplastic breast reduction.

The literature on breast reductions supports the safety of using both an inferior pedicle with Wise pattern incisions and a superomedial pedicle with vertical pattern incisions, with exceedingly low rates of NAC loss and

equivalent complication rates.²⁶ Neither inferior pedicle nor superomedial pedicle choice for breast reduction mammoplasty were associated with increased risk of NAC loss in our study ($P = 0.32$ and $P = 0.22$, respectively).

NAC loss occurred in the final stage of reconstruction in all of the four cases. In one case, the NAC was tenuous after NSM and finally lost after autologous reconstruction as the third stage in the operative course. In this case, the flap itself was also lost due to venous thrombosis. The weight of the autologous flap in summation with postoperative swelling and especially with venous congestion could further compromise a threatened NAC. Two of these four patients had a new incision pattern used in the final reconstruction stage. It is possible that these new incisions and further dissection during the final operation compromised the remaining blood supply to the NAC in these cases.

Our complication profile for the breast reduction stage is comparable to outcomes in the largest retrospective review of oncoplastic breast reduction outcomes, in which an infection rate of 5.4%, hematoma rate of 0.8%, and seroma rate of 1.1% are reported.²⁷ Similarly, our expander-to-implant and autologous reconstruction outcomes are comparable to a large multicenter prospective cohort study investigating various forms of postmastectomy breast reconstruction.²⁸ Our cumulative reconstructive failure rate after implant-based reconstruction was 7.4%, compared with 7.1% reported in the study.²⁸

It is important for patients to be aware of the risk an additional operation adds when they consider pursuing an oncoplastic breast reduction as a first stage towards an NSM in order to preserve the NAC. Additionally, patients must consider the additional time to definitive reconstruction that is involved when pursuing staged operations (on average 213 days in our series). Some patients may not find the value of preserving the NAC worth the added risk and added time, and it is therefore critical to understand an individual patient's goals and values when counseling them for reconstructive surgery. Further studies including patient reported outcomes are warranted.

There have been reports in the literature of the success of a formal NAC delay procedure two weeks prior to a definitive NSM.^{29,30} While it would add yet another surgery for patients, in those at particularly high risk for nipple loss, such as those with advanced age or a history of radiation, this may be a worthwhile endeavor.

At our institution, we have not experienced difficulty in obtaining insurance coverage for oncoplastic reductions. For prophylactic cases, we document that the patient has physical examination findings of ptosis (grade 2 or 3), is a candidate for a bilateral breast reduction as a risk reduction measure given her genetic mutation, and we may document the volume of tissue expected to be removed with the reduction. In therapeutic cases, we often initially document that the patient has been deemed a candidate for breast conservation and that the plan is a breast reduction mammoplasty.

Limitations of our study include its retrospective nature, leading to variations in management strategies. However, this heterogeneity is also a strength of the study, as our findings demonstrate real world application

of this technique to a diverse group of patients. Our series includes patients representing a wide range of ages and BMIs, with various indications for mastectomies and diverse adjuvant treatment profiles. This series represents the work of three plastic surgeons and five breast surgeons, as well as the outcomes from four breast reduction pedicle choices, two reduction incision patterns, and three mastectomy incision choices. Therefore, our results demonstrate that it is possible to have successful outcomes from staging an NSM in the described patient population in a variety of clinical scenarios.

CONCLUSIONS

Staged breast reconstruction is a safe option for women who desire NSM but are not candidates due to breast size or ptosis. Our complication profile is acceptable, with low rates of NAC loss. We generally aim to wait 3 months between breast reduction mammoplasty and NSM, and our data suggest that this is a safe time frame with respect to preserving the NAC. Increasing age was significantly associated with risk of NAC loss ($P = 0.002$) in our cohort.

Merisa Piper, MD

505 Parnassus Ave, Suite M593

San Francisco, CA 94143

E-mail: merisa.piper@ucsf.edu

REFERENCES

- Krajewski AC, Boughey JC, Degnim AC, et al. Expanded indications and improved outcomes for nipple-sparing mastectomy over time. *Ann Surg Oncol*. 2015;22:3317–3323.
- Wang F, Peled AW, Garwood E, et al. Total skin-sparing mastectomy and immediate breast reconstruction: an evolution of technique and assessment of outcomes. *Ann Surg Oncol*. 2014;21:3223–3230.
- Coopey SB, Tang R, Lei L, et al. Increasing eligibility for nipple-sparing mastectomy. *Ann Surg Oncol*. 2013;20:3218–3222.
- Peled AW, Foster RD, Stover AC, et al. Outcomes after total skin-sparing mastectomy and immediate reconstruction in 657 breasts. *Ann Surg Oncol*. 2012;19:3402–3409.
- de Alcantara Filho P, Capko D, Barry JM, et al. Nipple-sparing mastectomy for breast cancer and risk-reducing surgery: the memorial sloan-kettering cancer center experience. *Ann Surg Oncol*. 2011;18:3117–3122.
- Boneti C, Yuen J, Santiago C, et al. Oncologic safety of nipple skin-sparing or total skin-sparing mastectomies with immediate reconstruction. *J Am Coll Surg*. 2011;212:686–693; discussion 693.
- Djohan R, Gage E, Gatherwright J, et al. Patient satisfaction following nipple-sparing mastectomy and immediate breast reconstruction: an 8-year outcome study. *Plast Reconstr Surg*. 2010;125:818–829.
- Yueh JH, Houlihan MJ, Slavin SA, et al. Nipple-sparing mastectomy: evaluation of patient satisfaction, aesthetic results, and sensation. *Ann Plast Surg*. 2009;62:586–590.
- Hoskin TL, Hieken TJ, Degnim AC, et al. Use of immediate breast reconstruction and choice for contralateral prophylactic mastectomy. *Surgery*. 2016;159:1199–1209.
- Evans DG, Wisely J, Clancy T, et al. Longer term effects of the Angelina Jolie effect: increased risk-reducing mastectomy rates in BRCA carriers and other high-risk women. *Breast Cancer Res*. 2015; 17:143.
- Kummerow KL, Du L, Penson DF, et al. Nationwide trends in mastectomy for early-stage breast cancer. *JAMA Surg*. 2015;150:9–16.
- Habermann EB, Thomsen KM, Hieken TJ, et al. Impact of availability of immediate breast reconstruction on bilateral mastectomy rates for breast cancer across the United States: data from the nationwide inpatient sample. *Ann Surg Oncol*. 2014;21:3290–3296.
- Tuttle TM, Habermann EB, Grund EH, et al. Increasing use of contralateral prophylactic mastectomy for breast cancer patients: a trend toward more aggressive surgical treatment. *J Clin Oncol*. 2007;25:5203–5209.
- Spear SL, Rottman SJ, Seiboth LA, et al. Breast reconstruction using a staged nipple-sparing mastectomy following mastopexy or reduction. *Plast Reconstr Surg*. 2012;129:572–581.
- Salibian AA, Frey JD, Karp NS, et al. Does staged breast reduction before nipple-sparing mastectomy decrease complications? A matched cohort study between staged and nonstaged techniques. *Plast Reconstr Surg*. 2019;144:1023–1032.
- Economides JM, Graziano F, Tousimis E, et al. Expanded algorithm and updated experience with breast reconstruction using a staged nipple-sparing mastectomy following mastopexy or reduction mammoplasty in the large or ptotic breast. *Plast Reconstr Surg*. 2019;143:688e–697e.
- Vaughn C, Peled A, Esserman L, Foster R. Feasibility of performing total skin-sparing mastectomy in patients with prior circumareolar mastopexy or reduction mammoplasty incisions [published online ahead of print June 19, 2013]. *Ann Plast Surg*. 2013.
- Wapnir I, Dua M, Kierny A, et al. Intraoperative imaging of nipple perfusion patterns and ischemic complications in nipple-sparing mastectomies. *Ann Surg Oncol*. 2014;21:100–106.
- Moyer HR, Ghazi B, Daniel JR, et al. Nipple-sparing mastectomy: technical aspects and aesthetic outcomes. *Ann Plast Surg*. 2012;68:446–450.
- Spear SL, Willey SC, Feldman ED, et al. Nipple-sparing mastectomy for prophylactic and therapeutic indications. *Plast Reconstr Surg*. 2011;128:1005–1014.
- Crowe JP, Kim JA, Yetman R, et al. Nipple-Sparing mastectomy technique and results of 54 procedures. *Arch Surg*. 2004;139:148–150.
- Gunnarsson GL, Bille C, Reitsma LC, et al. Prophylactic nipple-sparing mastectomy and direct-to-implant reconstruction of the large and ptotic breast: is preshaping of the challenging breast a key to success? *Plast Reconstr Surg*. 2017;140:449–454.
- Alperovich M, Tanna N, Samra F, et al. Nipple-sparing mastectomy in patients with a history of reduction mammoplasty or mastopexy: how safe is it? *Plast Reconstr Surg*. 2013;131:962–967.
- Colwell AS, Tessler O, Lin AM, et al. Breast reconstruction following nipple-sparing mastectomy: predictors of complications, reconstruction outcomes, and 5-year trends. *Plast Reconstr Surg*. 2014;133:496–506.
- Carlson GW, Chu CK, Moyer HR, et al. Predictors of nipple ischemia after nipple sparing mastectomy. *Breast J*. 2014;20:69–73.
- Antony AK, Yegiyants SS, Danielson KK, et al. A matched cohort study of superomedial pedicle vertical scar breast reduction (100 breasts) and traditional inferior pedicle wise-pattern reduction (100 breasts): an outcomes study over 3 years. *Plast Reconstr Surg*. 2013;132:1068–1076.
- Losken A, Hart AM, Broecker JS, et al. Oncoplastic breast reduction technique and outcomes: an evolution over 20 years. *Plast Reconstr Surg*. 2017;139:824e–833e.
- Bennett KG, Qi J, Kim HM, et al. Comparison of 2-year complication rates among common techniques for postmastectomy breast reconstruction. *JAMA Surg*. 2018;153:901–908.
- Jensen JA, Lin JH, Kapoor N, et al. Surgical delay of the nipple-areolar complex: a powerful technique to maximize nipple viability following nipple-sparing mastectomy. *Ann Surg Oncol*. 2012;19:3171–3176.
- Martinovic ME, Pellicane J, Blanchet NP. Surgical delay of the Nipple-Areolar complex in high-risk Nipple-sparing mastectomy reconstruction. *Plast Reconstr Surg Global Open*. 2016;4: e760.