

UC Davis

Dermatology Online Journal

Title

An elderly Filipino woman with follicular papules of the face and chest

Permalink

<https://escholarship.org/uc/item/11p6g3x4>

Journal

Dermatology Online Journal, 23(3)

Authors

Ascha, Mona
Irfan, Mahwish
Billings, Steven D

Publication Date

2017

DOI

10.5070/D3233034291

Copyright Information

Copyright 2017 by the author(s). This work is made available under the terms of a Creative Commons Attribution-NonCommercial-NoDerivatives License, available at <https://creativecommons.org/licenses/by-nc-nd/4.0/>

Peer reviewed

An elderly Filipino woman with follicular papules of the face and chest

Mona Ascha BS¹, Mahwish Irfan MD¹, Steven D Billings MD^{1,2}

Affiliations: ¹Department of Dermatology, Cleveland Clinic Foundation, Cleveland, Ohio, ²Department of Pathology, Cleveland Clinic Foundation, Cleveland, Ohio

Corresponding Author: Mona Ascha, BS, Cleveland Clinic Foundation, 9500 Euclid Ave, Cleveland, OH. Tel. (440) 724-6245, E-mail: mona.ascha@case.edu

Abstract

An elderly woman developed pruritic follicular papules over a period of 5 years. A biopsy revealed focal intraepidermal eosinophilic pustules, leading to the diagnosis of Ofuji disease or eosinophilic pustular folliculitis. A discussion of this condition is presented.

Keywords: Ofuji disease, eosinophilic pustular folliculitis, eosinophilia

Case Synopsis

An elderly Filipino woman previously diagnosed with chronic actinic dermatitis presented with a five-year history of extremely pruritic follicular papules of the face and chest (**Figure 1** and **Figure 2**). She denied any photosensitivity or systemic symptoms. She had not started any new medications recently. Prior treatment with prednisone, dapsone, and methotrexate had afforded some improvement, but she continued to have breakthrough flares.

Her review of systems was otherwise negative. Her past medical history was unremarkable and she was up-to-date on colonoscopy and mammography. She denied any recent travel.

On physical exam, her face had an edematous, infiltrated appearance with multiple red-brown scaly papules and plaques admixed with pustules. Her chest had similar perifollicular papules and pustules. Laboratory values were remarkable for IgE of 2079 and complete blood count with 20.9% eosinophils.

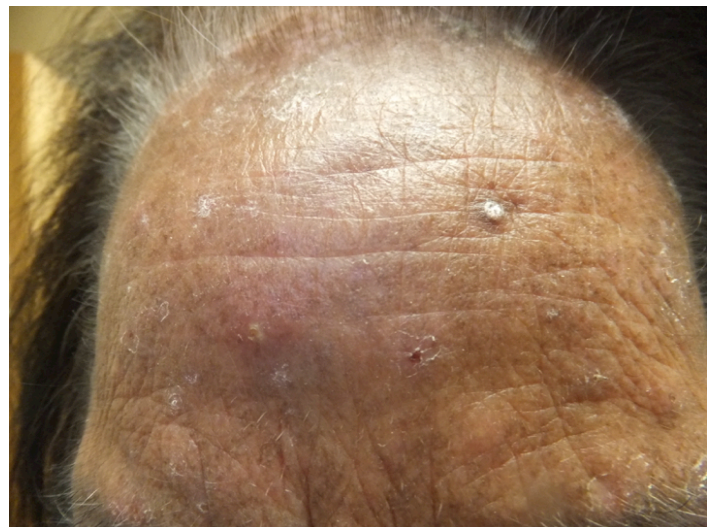

Figure 1. Ofuji disease. Multiple scaly erythematous papules and one pustule coalescing into a larger plaque on the forehead.

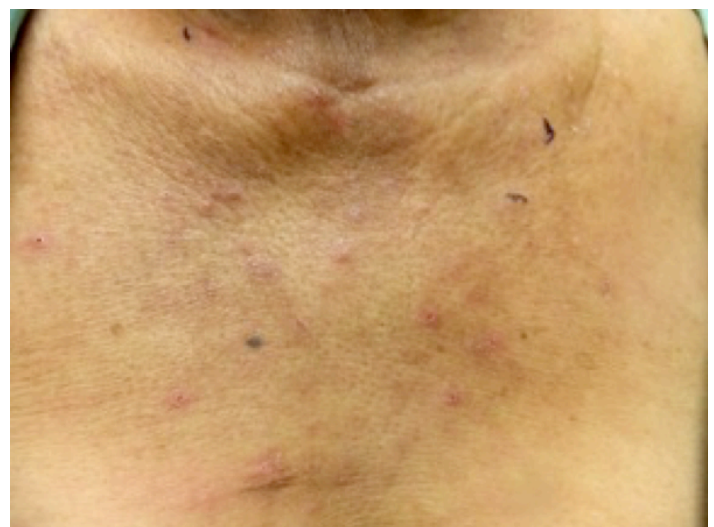

Figure 2. Ofuji disease. Scattered perifollicular scaly erythematous papules and pustules, few with excoriation on the chest. Pen markings indicate biopsy sites.

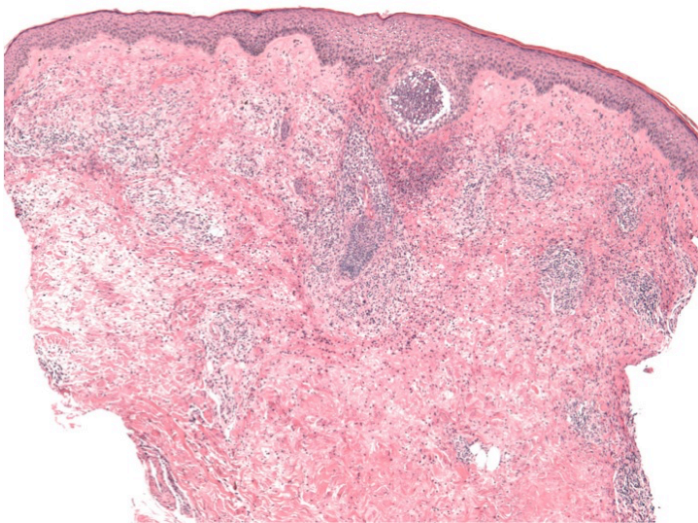


Figure 3. Ofuji disease. Low power image showing mild spongiosis with a follicular eosinophilic pustule and perifollicular inflammatory infiltrate. H&E, 4x.

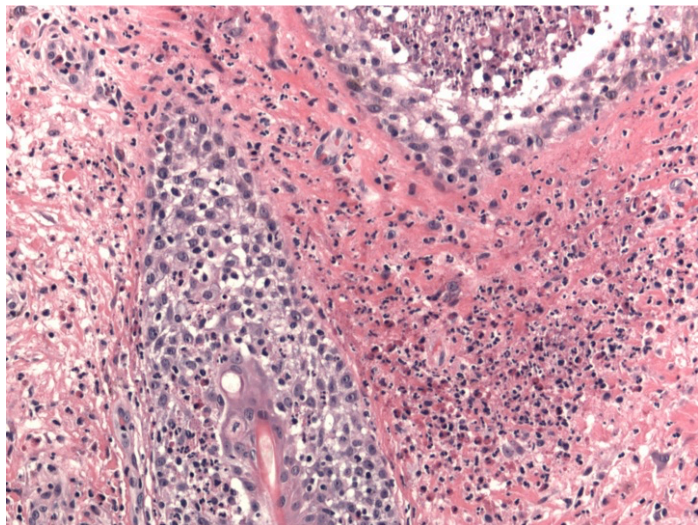


Figure 4. Ofuji disease. The high power image shows a dense perifollicular infiltrate neutrophils and numerous eosinophils. There are also eosinophils within the follicular epithelium. H&E, 100x.

Her tests for parasites and ova, HIV, and ANA were negative. Three punch biopsies were performed for histologic examination and tissue cultures (**Figure 3** and **Figure 4**). A punch biopsy at the right clavicle revealed mild spongiosis with focal intraepidermal eosinophilic pustules. The dermis had a dense folliculocentric eosinophilic infiltrate. There was no increased mucin. Direct immunofluorescence was negative. Bacterial, fungal and acid-fast cultures were negative.

The patient was subsequently diagnosed with classic eosinophilic pustular folliculitis, also known as Ofuji disease. The differential included subacute cutaneous

lupus erythematosus, chronic actinic dermatitis, and mycosis fungoides.

In this patient, methotrexate and dapsone were discontinued. Indomethacin was offered but the patient declined. She was subsequently treated with triamcinolone 0.1% cream twice daily as needed and experienced mild improvement.

Case Discussion

Eosinophilic pustular folliculitis (EPF), first described by Ofuji in 1970, is a rare non-infectious pruritic inflammatory disease characterized by a predilection for seborrheic areas of the skin with a chronic and relapsing course [1]. The four variants of EPF include classical EPF (Ofuji disease), immunosuppression-associated EPF (HIV-related), infancy-associated EPF, and EPF associated with miscellaneous causes [2, 3]

The etiology is unknown, but an autoimmune process directed against sebocytes has been hypothesized. Patients with EPF have been found to have anti-basal keratinocyte antibodies, pemphigus-like antibodies, chemotactic factors, and nitrous oxide produced by eosinophils [3]. Increased expression of various adhesion molecules for eosinophils around hair follicles has been reported in patients with EPF [3-5]. It has also been shown that prostaglandin D2 stimulates sebocytes to produce eotaxin-3, a chemoattractant for eosinophils, resulting in accumulation of eosinophils in the pilosebaceous unit; this can explain why indomethacin, which inhibits prostaglandin formation, is an effective treatment [6]. Furthermore, the association between EPF and HIV also confirms an immunologic component to its pathogenesis. In advanced HIV infection, Th2 cells predominate; when stimulated by antigens, Th2 cells release interleukins 4, 5, and 13, recruiting and activating eosinophils. This immunologic pathogenesis is supported by a study that found therapy with interferon-gamma, which suppresses Th2 differentiation, could induce remission of EPF and decrease mRNA levels of IL-5 [7].

EPF is more common in Asian individuals and is highly prevalent in Japan. Classical EPF has a male to female ratio of 5:1 and peak occurrence is in the third and fourth decades of life. In the classic form, patients develop recurrent crops of sterile papules and pustules on the face and neck, which can be

severely pruritic; about 20% of patients have been reported to have lesions on the palms and soles [8]. These papulopustules may coalesce into plaques to form annular lesions. Lesions usually resolve spontaneously months to years after onset with residual hyperpigmentation and scaling. Patients rarely present with systemic symptoms. Lab testing demonstrates leukocytosis with peripheral eosinophilia; serum IgE levels may also be elevated. In patients with HIV-associated EPF, CD4 counts are typically below 300 [3]. EPF has also been associated with drugs such as allopurinol and timepidium, hematologic malignancies, and silicone injections [3].

The diagnosis of EPF is based on clinical and histopathological findings. Other lesions containing eosinophilic infiltrate include arthropod bite reactions, fungal skin infections, and suppurative folliculitis. However, unlike other eosinophilic dermatoses, the eosinophilic infiltrate in EPF tends to be predominantly folliculocentric in distribution, as was seen in our patient. Infectious causes may also be distinguished from EPF owing to concomitant neutrophilic infiltrate and evidence of bacterial or fungal organisms. Cutaneous T-cell lymphoma such as mycosis fungoides (MF) is an important differential diagnosis for EPF, as the initial lesions of mycosis fungoides appear almost identical to EPF, both histologically and clinically [8]. Folliculotropic MF also demonstrates spongiosis of the hair follicle epithelium and mucinous degeneration of the follicles [8]. Initial MF lesions have been misdiagnosed as EPF; thus, periodic follow up to monitor signs of malignancy in EPF patients is crucial. Our patient's striking findings on histopathology and laboratory values of increased IgE and eosinophilia along with her clinical manifestations secured the diagnosis of EPF.

Management includes both topical and systemic modalities; a wide range of treatments have been used. Topical steroids or topical calcineurin inhibitors are the mainstay of treatment. Oral prednisone, oral retinoids, and cyclosporine have also been used for more severe disease. Additionally, oral indomethacin or other NSAIDs are effective, particularly for classical EPF [2, 8]. Other described treatment options include colchicine, minocycline,

oral metronidazole, permethrin, cyproheptadine, UVB therapy (particularly for the HIV variant), PUVA therapy, interferon α -2b, tacrolimus, doxycycline, and radiation therapy. A recent study reported safe and effective use of transdermal nicotine patches in treating EPF [9]. Due to the elusive pathogenesis of EPF, no established treatment algorithm exists.

We believe our case highlights a unique and uncommon disease that may initially be misdiagnosed. Our patient underwent unnecessary treatments for incorrect diagnoses for many years prior to receiving her final diagnosis of classic EPF. Furthermore, this patient's presentation is not classic: although she is of Asian descent, she is female and was beyond the fourth decade of life. It is important for EPF to be included in the differential diagnosis for patients presenting with pruritic lesions and negative cultures, in order to prevent delay in diagnosis and unwarranted therapy.

References

1. Ofuji S, Ogino A, Horio T, Oseko T, Uehara M. Eosinophilic pustular folliculitis. *Acta Derm Venereol.* 1970;50(3):195-203. [PMID: 4193219]
2. Katoh M, Nomura T, Miyachi Y, Kabashima K. Eosinophilic pustular folliculitis: a review of the Japanese published works. *J Dermatol.* 2013;40(1):15-20. [PMID: 23083212]
3. Sufyan W, Tan KB, Wong ST, Lee YS. Eosinophilic pustular folliculitis. *Arch Pathol Lab Med.* 2007;131(10):1598-601. [PMID: 17922601]
4. Takematsu H, Tagami H. Eosinophilic pustular folliculitis. Studies on possible chemotactic factors involved in the formation of pustules. *Br J Dermatol.* 1986 Feb. 114(2):209-15. [PMID: 3511943]
5. Scavo, S., Magro, G. and Caltabiano, R. (2010), Clinicopathologic challenge: Erythematous and edematous eruption of the face. *International Journal of Dermatology*, 49: 975-977. [PMID: 20883260]
6. Nakahigashi K, Doi H, Otsuka A, et al. PGD2 induces eotaxin-3 via PPAR γ from sebocytes: a possible pathogenesis of eosinophilic pustular folliculitis. *J Allergy Clin Immunol.* 2012;129(2):536-43. [PMID: 22206772]
7. Fushima M, Tokura Y, Sachi Y, et al. Eosinophilic pustular folliculitis effectively treated with recombinant interferon-gamma: suppression of mRNA expression of interleukin 5 in peripheral blood mononuclear cells. *Br J Dermatol.* 1996; 134: 766-772. [PMID: 8733389]
8. Fujiyama T, Tokura Y. Clinical and histopathological differential diagnosis of eosinophilic pustular folliculitis. *J Dermatol.* 2013;40(6):419-23. [PMID: 23488969]
9. Yoshifuku A, Higashi Y, Matsushita S, Kawai K, Kanekura T. Transdermal nicotine patches for eosinophilic pustular folliculitis. *J Dermatol.* 2013;40(9):711-4. [PMID: 23802575]