

UC San Diego

UC San Diego Previously Published Works

Title

A Case of Covid-19 Diagnosed at Home With Portable Ultrasound and Confirmed With Home Serology Test

Permalink

<https://escholarship.org/uc/item/11j964c5>

Journal

Journal of Emergency Medicine, 60(3)

ISSN

0736-4679

Authors

Aminlari, Amir
Quenzer, Faith
Hayden, Stephen
[et al.](#)

Publication Date

2021-03-01

DOI

10.1016/j.jemermed.2020.10.022

Peer reviewed



Since January 2020 Elsevier has created a COVID-19 resource centre with free information in English and Mandarin on the novel coronavirus COVID-19. The COVID-19 resource centre is hosted on Elsevier Connect, the company's public news and information website.

Elsevier hereby grants permission to make all its COVID-19-related research that is available on the COVID-19 resource centre - including this research content - immediately available in PubMed Central and other publicly funded repositories, such as the WHO COVID database with rights for unrestricted research re-use and analyses in any form or by any means with acknowledgement of the original source. These permissions are granted for free by Elsevier for as long as the COVID-19 resource centre remains active.

A CASE OF COVID-19 DIAGNOSED AT HOME WITH PORTABLE ULTRASOUND AND CONFIRMED WITH HOME SEROLOGY TEST

Amir Aminlari, MD, Faith Quenzer, DO, Stephen Hayden, MD, Jennifer Stone, MD, Charles Murchison, MD, and Colleen Campbell, MD

Department of Emergency Medicine, University of California, San Diego School of Medicine, San Diego, California

Reprint Address: Charles Murchison, MD, Department of Emergency Medicine, University of California, San Diego School of Medicine, 1750 Kettner Boulevard, Unit 406, San Diego, CA 92101

Abstract—Background: The coronavirus disease 2019 (COVID-19) pandemic has pushed us to find better ways to accurately diagnose what can be an elusory disease, preferably in a way that limits exposure to others. The potential for home diagnosis and monitoring could reduce infectious risk for other patients and health care providers, limit use of finite hospital resources, and enable better social distancing and isolation practices. **Case Report:** We report a case of an otherwise healthy emergency physician diagnosed with COVID-19 at home using portable ultrasound, pulse oximetry, and antibody testing. Her clinical picture and typical lung findings of COVID-19 on ultrasound, combined with a normal echocardiogram and negative deep vein thrombosis study, helped inform her diagnosis. She then monitored her clinical course using pulse oximetry, was able to self-isolate for 4 weeks, and had an uneventful recovery. Her diagnosis was confirmed with a positive IgG antibody test after 3 weeks. **Conclusions:** Novel times call for novel solutions and our case demonstrates one possible path for home diagnosis and monitoring of COVID-19. The tools used, namely ultrasound and pulse oximetry, should be familiar to most emergency physicians. Ultrasound in particular was helpful in eliminating other potential diagnoses, such as pulmonary embolus. © 2020 Elsevier Inc. All rights reserved.

Keywords—COVID-19; emergency ultrasound; point-of-care ultrasound; pulmonary ultrasound; echocardiography

INTRODUCTION

The coronavirus disease 2019 (COVID-19) pandemic, caused by the severe acute respiratory syndrome coronavirus 2 (SARS-CoV-2) virus, has created unique challenges for emergency physicians and emergency department (ED) patient flow. There has been a great deal of effort to create processes that conform to infection-control standards, protect both patients and health care providers, and allow for appropriate testing of individuals suspected of being infected with the SARS-CoV-2 virus.

Portable ultrasonography has been shown to be a valuable adjunct tool, along with pulse oximetry and physical examination, in diagnosing both COVID-19 and its associated severe cardiopulmonary complications, such as pneumonia and cardiomyopathy (1). The convenience of antibody tests, pulse oximetry, and portable ultrasounds can help avoid exposing others to COVID-19 by monitoring at home for complications.

Johri et al. reported a case of an emergency physician diagnosed with COVID-19 in the clinical setting with a rapid polymerase chain reaction test, who then used a portable ultrasound and home pulse oximetry to monitor the course of illness (2). We present a unique case of an emergency physician who contracted SARS-CoV-2 and

was diagnosed in the home setting with a combination of portable ultrasound, home pulse oximetry, and home serology testing. This case is one of the first to be reported to use all of these tools in the home setting to diagnose and manage COVID-19. It allowed the patient to remain in home quarantine without presenting to the hospital or to her physician's office.

Although these resources are not available to all patients or in many acute care settings, use of such processes and resources might have the potential to improve patient and health care provider safety by keeping some patients with mild cases of COVID-19 out of the ED.

CASE PRESENTATION

A 42-year-old woman with no medical history developed diarrhea, followed by dry cough, severe myalgias, mild exertional dyspnea, and fatigue in March 2020 after a trip to Cancun with a layover in Mexico City. The patient and her husband, both emergency physicians, suspected that she had contracted SARS-CoV-2. They used a thermometer, a borrowed portable pulse oximeter, a portable ultrasound machine, and a home serology test to confirm the diagnosis.



Figure 1. Initial pulse oximeter reading showing tachycardia to 112 beats/min and hypoxia to 88% with patient breathing room air.

Her temperature was 100.6°F, heart rate was 118 beats/min, pulse oximeter was 88% on room air (Figure 1), and ultrasound of the lungs showed B-lines in the right posterior lung fields and A-lines in all other lung fields (Figure 2). An echocardiogram showed normal cardiac function with normal left ventricular ejection fraction, no pericardial effusion, and no right heart strain. A bilateral venous ultrasound of her legs were negative for deep venous thrombosis. A SARS-CoV-2 home serology test 3 weeks later was positive for IgG, but negative for IgM (Figure 3). After 2 weeks of symptoms, her condition improved slowly, vital signs normalized, and her symptoms resolved. She remained in home quarantine for 4 weeks.

DISCUSSION

This is a case highlighting some of the tools that are at the disposal of the general population to monitor their COVID-19 symptoms at home, thereby preserving resources and potentially helping to prevent overburdening

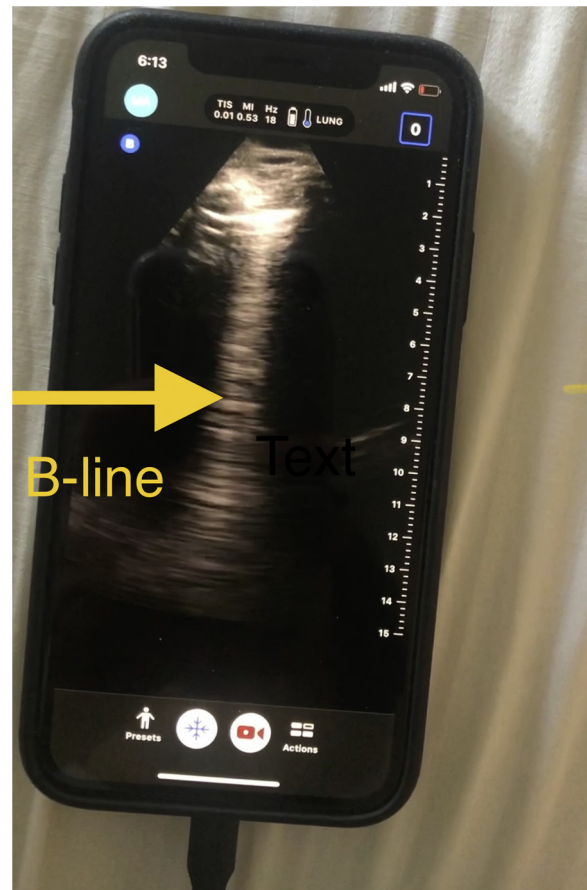


Figure 2. Non-confluent B-line seen in the right posterior lung field, a common ultrasound finding in COVID-19 infection.




Figure 3. Antibody test revealing positive IgG with a negative IgM, indicating prior infection.

the health care system. The patient's presentation was concerning primarily for COVID-19, but given her recent travel, pulmonary embolus was also on the differential. With a negative venous ultrasound, a bedside echocardiogram showing no right heart strain, and a lung ultrasound showing focal B-lines in the posterior right lung base, with A-lines in all other lung fields, her tachycardia and hypoxemia was thought to be much less likely due to pulmonary embolus. Multi-organ ultrasound in the evaluation of suspected pulmonary embolus is quite sensitive, about 90%, and the sensitivity increases to 100% when an alternative diagnosis is identified, such as the focal B lines in our case (3). Focal B-lines in the right posterior lung base is a common finding in the ultrasound diagnosis of COVID-19, along with thickened and irregular pleural lines, which we did not see in our case (4).

The decision to keep her at home in spite of the mild hypoxemia of 88% was influenced by the fact that she was able to receive continuous pulse-oximeter monitoring, providing confidence that worsening hypoxemia would be detected. The home serology test, which is approved by the U.S. Food and Drug Administration,

was convenient and reassuring that the correct diagnosis was made (5). The patient was able to stay in home quarantine, continue observation of vital signs, and treat herself symptomatically until the resolution of her illness.

This case was particularly unique in that the patient and her husband were both emergency physicians with the requisite skill set to perform a portable point-of-care ultrasound at home to make the correct diagnosis and also to rule out other worrisome conditions, such as deep vein thrombosis, right heart strain from a massive pulmonary embolus, pericardial effusion, and lobar pneumonia. We recognize that a portable ultrasound machine and the skill set required for its use outside of the hospital setting is uncommon, and this is a limitation to this approach. We are not suggesting that this pathway be used as a standard protocol to evaluate patients with symptoms of COVID-19.

CONCLUSIONS

We argue that in these unprecedented times of the pandemic, with winter fast approaching, we must be willing to consider all treatment options and pathways that are available to us, some of which might be unconventional. In addition, we believe that for select patients in the general population, the combination of a pulse oximeter and home serology test is useful to diagnose and monitor COVID-19, and decide whether and when to go to the ED, thereby alleviating stress on our health care system.

REFERENCES

1. Johri AM, Galen B, Kirkpatrick JN, Lanspa M, Mulvagh S, Thamman R. ASE statement on point-of-care ultrasound (POCUS) during the 2019 novel coronavirus pandemic. 2020 American Society of Echocardiography. Available at: https://www.asecho.org/wp-content/uploads/2020/04/POCUS-COVID_FINAL2_web.pdf. Accessed June 1, 2020.
2. Pablos T. Doctors in Italy, Spain using ultrasound for COVID-19. 2020. Available at: <https://www.auntminnie.com/index.aspx?sec=sup&sub=ult&pag=dis&ItemID=128525>. Accessed June 1, 2020.
3. Peng Q, Wang X, Zhang L. Findings of lung ultrasonography of novel corona virus pneumonia during the 2019–2020 epidemic. *Intensive Care Med* 2020;46:849–50.
4. Nazerian P, Vanni S, Volpicelli G, et al. Accuracy of point-of-care multiorgan ultrasonography for the diagnosis of pulmonary embolism. *Chest* 2014;145:950–7.
5. Hahn S. FDA statement. Coronavirus (COVID-19) update: serological test validation and education efforts. 2020. Available at: <https://www.fda.gov/news-events/press-announcements/coronavirus-covid-19-update-serological-test-validation-and-education-efforts>. Accessed June 1, 2020.