

UC Davis

Dermatology Online Journal

Title

Congenital erythropoietic porphyria (Gunther disease) - long-term follow up of a case and review

Permalink

<https://escholarship.org/uc/item/10n7k90g>

Journal

Dermatology Online Journal, 23(2)

Authors

Howard, Matthew
Hall, Anthony
Ramsay, Donald

Publication Date

2017

DOI

10.5070/D3232033965

Copyright Information

Copyright 2017 by the author(s). This work is made available under the terms of a Creative Commons Attribution-NonCommercial-NoDerivatives License, available at <https://creativecommons.org/licenses/by-nc-nd/4.0/>

Peer reviewed

Congenital erythropoietic porphyria (Gunther disease) – long-term follow up of a case and review

Matthew Howard¹, Anthony Hall², Donald Ramsay²

Affiliations: ¹St Vincent's Hospital, Melbourne, Victoria, Australia, ²Baycity Dermatology, Geelong, Victoria, Australia

Corresponding Author: Matthew Howard, 39 Highland Way, Leopold, Victoria, Australia. Postcode 3224, Email address: matthew.david.howard@gmail.com

Abstract

Patients with the rare genodermatosis congenital erythropoietic porphyria (CEP, Gunther disease) develop erosions and scarring on sun-exposed sites caused by phototoxin mediated damage. Compromised skin barrier function places patients at higher risk of infection and long term sequelae include scarring. We report a long term follow up of a 60 year old patient born with CEP and provide an extensive literature review of CEP including recent updates on potential management options. Multiple patient interviews and collection of biochemistry data were conducted for the case discussion. All Australian pathology laboratories in each state performing porphyria testing were surveyed in mid 2015 to verify existence of other cases of CEP in Australia with only one case of true congenital porphyria identified and one adult onset case. Congenital erythropoietic porphyria is a rare condition with no cure currently available. It is important to diagnose patients early to prevent and minimize complications such as scarring and secondary infection, provide long term skin checks, and advise patients about lifestyle modification.

Keywords: Gunther disease, CEP, congenital erythropoietic porphyria, genodermatosis, uroporphyrinogen III co-synthase

Introduction

This case report details the long term followup of a patient with congenital erythropoietic porphyria (CEP) who was initially misdiagnosed with EB and subsequently PCT before the diagnosis was correctly made as CEP in his adolescence. It details the patients'

biochemistry results over this forty year followup, provides clinical pictures, details trials of treatment that were used for the patient and finishes with a discussion and literature review of the rare condition of CEP

Case Synopsis

A 60 year-old man with CEP or Gunther disease demonstrated lifelong photosensitivity resulting in blistering and crusted erosions with subsequent severe scarring of sun-exposed sites. He reported recurrent "biting" sensation after sun-exposure followed by blistering 1-2 days later. Vesiculo-bullous lesions varied from few millimeters in diameter on his face up to two centimeters on his neck, which then slowly became crusted erosions persisting for up to 6 months. He was the second child to non-consanguineous parents. At birth dark urine with neonatal jaundice was noted and subsequent treatment with phototherapy resulted in marked blistering. Increased skin fragility of his lower legs with blistering on sun exposure as a child led to a diagnosis of epidermolysis bullosa (EB) at 4 years of age. "Vitamin therapy" provided no benefit. At 12 years of age he was diagnosed as having porphyria cutanea tarda (PCT) and erroneously treated with zinc tablets, topical preparations, and strict sun protection.

Throughout adolescence he recalls severe photosensitivity with redness and severe itching followed by blistering. His diagnosis was revised to congenital erythropoietic porphyria (CEP) based on raised red blood cell coproporphyrin (13.5 µg/100 mL) (normal range 0-1 µg/100 mL), raised urinary uroporphyrin (9100 µg/L), and raised fecal coproporphyrin (205 µg/g dry weight). Both his

parents and a maternal uncle were tested during this time but porphyrin levels were normal. However the patient recalls he was still treated as having PCT into his third decade by venesection with no clinical improvement. Charcoal powder mixed with milk provided no improvement. Pre-treatment eye testing for antimalarial therapy resulted in persistently severe painful eyes for two months with no permanent decrease in visual acuity.

By 40 years of age his photosensitivity worsened with progressive scarring of exposed skin. After an episode of life-threatening cellulitis of his face treated with intravenous antibiotics, skin colonization with multi-resistant staphylococcus aureus (MRSA) was detected. At this stage the diagnosis of CEP was confirmed by porphyrin testing. His three children were also tested and found to be asymptomatic carriers of CEP. At 44 years of age his genotype was determined to be compound heterozygote (-86A/398insG) demonstrating a promoter sequence transversion and a frameshift mutation in uroporphyrinogen III synthase exon 7 (reported as proband 5 by Solis et al [1]). These two mutations are uncommon occurring in around 2 and 3 percent respectively of mutated alleles [2].

A trial of afamelanotide (an analogue of melanocyte stimulating hormone) subcutaneous implants 2-monthly for 1 year resulted in significant darkening of his skin and a much better tolerance to sunlight, but afforded no protection in previously scarred regions of the face and hands. Bleach baths with sodium hypochlorite were suggested to reduce recurrent skin infections, but proved inconvenient owing to the soaking time and its impracticality for treating the head and face. A novel topical hypochlorous acid preparation was utilized for reducing the bacterial burden of erosions and minimizing infections with great success. The formulation of the preparation is described in our letter to the editor due to be published [3].

Presently he is still troubled by scarring (**Figure 1**) and recurrent skin infections and recent chronic osteomyelitis of terminal phalanges (**Figure 2**). Other medical problems include hypertension, coronary artery disease, (stented twice), impaired renal function and vitamin D deficiency. Clinically

he demonstrates eroded sclerodermoid scarring of face, neck, and hands with loss of finger tips up to the distal interphalangeal joint, and scarring alopecia. Our patient has also lost his nasal tip and both pinna have been deformed from heavy scarring. Widespread erosions cover his skin in a photodistribution with some becoming superficial ulcers such as demonstrated on the patient's right hand. Healed erosions on his face in particular

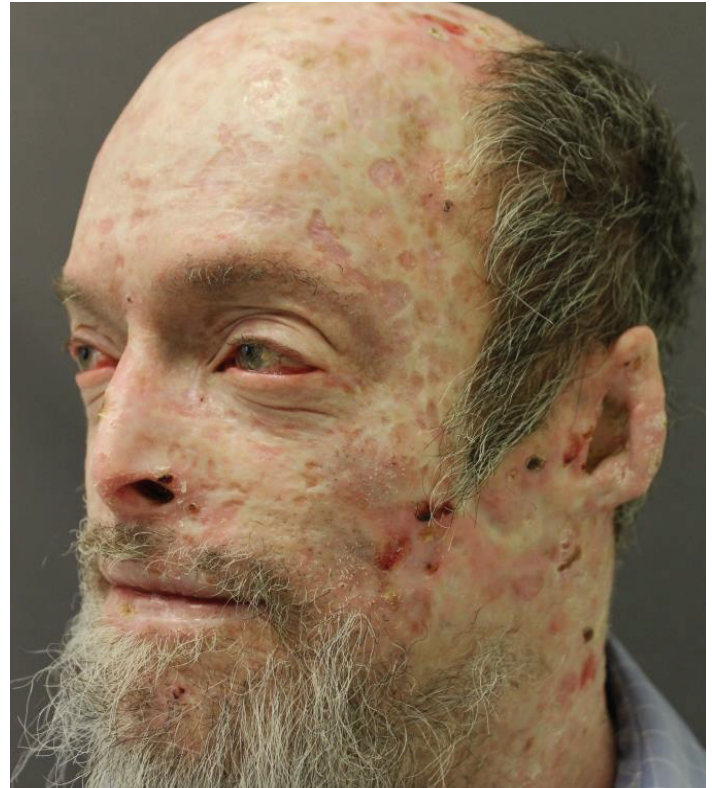


Figure 1. Clinical photograph demonstrating sclerodermoid scarring of face of patient.

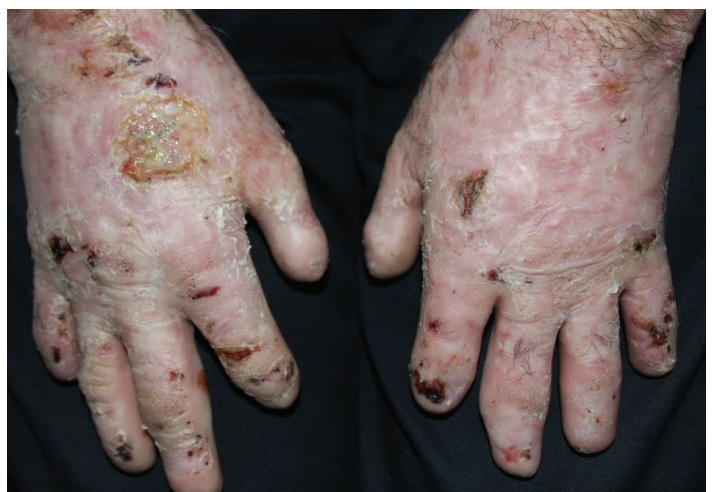

Figure 2. Clinical photograph of patient depicting shortening and scarring of fingers.

have left behind depressed scar tissue. Pus can be discharged chronically from the tips of digits owing to chronic infection with possible underlying osteomyelitis, which has been reduced with the use of hypochlorous acid soaks. Our patient does not have palpable hepatosplenomegaly and hemoglobin is maintained within normal limits without regular transfusions. Investigations collected over the period from his initial change in diagnosis from PCT to CEP are listed below with reference ranges supplied where available from the reporting laboratory (**Table 1**). All urine porphyria results were collected over 24 hours.

Case Discussion

Congenital erythropoietic porphyria (CEP), also known as Gunther disease, is a rare autosomal recessive condition with approximately 200 cases documented worldwide [4, 5]. This condition was first reported by Schultz in 1874 and further understanding of CEP was gained by Gunther who coined the term 'haematoporphyria congenita' [6]. Gunther was the first to describe CEP as an inherited metabolic disorder whereby deficiency of fourth enzyme in the heme synthesis pathway, uroporphyrinogen III co-synthase (UROIII), results in accumulation of porphyrin precursors such as hydroxymethylbilane (HMB) that is further non-enzymatically transformed into uroporphyrinogen I [7],[8]. Accumulation of porphyrin precursors results in overproduction and over-excretion of a precursor that is unable to perform a physiological role that underpins this metabolic disorder.

Multiple systemic manifestations occur in CEP as a consequence of accumulation of porphyrin precursors. Deposits of uroporphyrinogen I induce an intradermal photosensitivity reaction in the 400-420nm range of visible light with photoexcitation and creation of oxygen-dependent free radicals that cause local parenchymal damage [9]. CEP customarily presents during the newborn period with brown-red-pink colored amniotic fluid and dark purple urine caused by the excretion of porphyrin. The dark purple urine demonstrates pink fluorescence under Wood's lamp. Near ultraviolet and visible violet light exposure to the skin surface results in fragile, serous-containing bullae prone to rupture producing erosions.

Chronic photo-induced damage to the skin leads to scarring and mutilation of sun exposed structures, particularly nose, ears, fingers, and scalp [2, 4]. The compromised skin barrier function from the damage can then place patients at higher risk of developing secondary bacterial infections. Other complications of this condition include facial hypertrichosis, madarosis, scarring alopecia, and scleritis and corneal ulceration leading to blindness [4, 5, 10].

Systemic incorporation of circulating porphyrin precursors results in erythrodontia (red-brown staining of teeth that fluoresce pink under Wood's light), bone changes (osteodystrophia, osteolysis and osteoporosis), and bone marrow hyperplasia [5]. Hemolytic anemia and splenomegaly may develop with pronounced variability in phenotypic expression. Profound hemolytic anemia may result in hydrops fetalis or require lifelong blood transfusions [4].

Long term photo mediated damage can result in non melanomatous skin cancer in these patients with squamous cell carcinomas (SCCs) potentially difficult to detect owing to chronic skin damage, scarring, and inflammation [11]. Variable severity of manifestations is related to inheritance of different allelic variants that decrease activity of UROIII to different concentrations [12].

CEP can be differentiated from erythropoietic protoporphyria (EPP) by bullae formation and lack of paraesthesia typically experienced in CEP upon sun exposure. Hepatoerythropoietic porphyria (HEP) presents with similar symptoms in neonatal period but can be differentiated by absence of isocoproporphyrin in urine or feces [2]. Porphyria cutanea tarda (PCT) is much more common and usually with onset in adulthood with an acquired defect in uroporphyrinogen decarboxylase (UROD) associated with hepatitis C virus and HIV infection [13].

Laboratory diagnosis of CEP is confirmed biochemically by elevation of urine uroporphyrins and coproporphyrins. Fecal and erythrocyte samples contain high uroporphyrin, coproporphyrin, and protoporphyrin levels. Plasma analysis displays high uroporphyrin and coproporphyrin levels owing to

Table 1. Cumulative biochemistry results over 40 years for the case patient.

	initial biochemistry (1969, patient aged 12)	1994, patient aged 38	1998-2000, patient aged 45	2009-2010, patient aged 55	Reference ranges
Red cell total porphyrin	-	11.2 micro-mol/L	15.4 micromol/L	13.5 micromol/L	<1.8 micromol/L
Red cell coproporphyrin	13.5 micro-grams/100mL	-	-	-	0-1 micro-grams/100mL
Red cell protoporphyrin	17.0 micro-grams/100mL	10.2 micro-mol/L	-	11.1 micromol/L	<1.6 micromol/L 25-50 micro-grams/100mL
Plasma Total porphyrin	-	143 nmol/L	985 nmol/L	527 nmol/L	<10 nmol/L
Urinary δ-amino levulinic acid	4.0, 4.1mg/L	-	-	-	Not supplied
Urinary Porphobilinogen	0.98, 0.83mg/L	6 micromol/L	5 micromol/L	-	0-10 micromol/L
Urinary total porphyrin	5,600 micrograms/L	10,200 nmol/L	37575 nmol/L	58770 nmol/L	<300 nmol/L
Urinary Porphyrin/creatinine	-	1742	2333.9	4289.8	<35
Urinary coproporphyrin	1,400 microgram/L	3217 nmol/L	8267 nmol/L	5240 nmol/L	<150 nmol/L
Urinary Electrophoresis	Coproporphyrin 14% Pentacarboxylic 6% Hexacarboxylic 2% Heptacarboxylic 8% Uroporphyrin 71%	coproporphyrin 19% Pentacarboxylic acid 6% Hexacarboxylic acid 1% Heptacarboxylic acid 9% isocoproporphyrin 0% Uroporphyrin 64%	-	-	-
Faecal total porphyrin	-	-	1766 micromol/kg	4521 micromol/kg	<200 micromol/kg
Faecal protoporphyrin	81 micrograms/g dry weight	1 micromol/Kg	0 micromol/kg	45 micromol/kg	<180 micromol/kg
Faecal coproporphyrin	205 micrograms/g dry weight	818 micromol/Kg	1731 micromol/kg	4340 micromol/kg	<180 micromol/kg
Faecal electrophoresis	Dicarboxylic porphyrin 7% Coproporphyrin 92% Pentacarboxylic 2.5% Hexacarboxylic 0.3% Heptacarboxylic 0.2% Uroporphyrin 0.5%	Protoporphyrin 6% Coproporphyrin 94% Isocoproporphyrin 0% Pentacarboxylic acid 0% Hexacarboxylic acid 0% Heptacarboxylic acid 0% Uroporphyrin 0%	-	-	-

hemolysis of RBCs with high porphyrins fueling systemic deposition of porphyrins [5, 14].

Genetic testing can be performed to assess for bi-allelic mutations of the UROIII gene. There have been more than 40 distinct UROIII mutations listed in the human gene mutation database [15]. The most common mutation is substitution of amino acid C73R that is associated with severe phenotype [2].

Histopathology of photo-damaged skin reveals subepidermal bullae with upper dermal infiltrate of mononuclear cells. Increased connective tissue and hyalinization may be visualized in dermis, particularly perivascularly. Porphyrin perivascular infiltrate stains PAS positive [16].

Recently an association between CEP, Parkinson disease and cortico-basal syndrome has been proposed with belief that given sufficient lifespan of intracellular heme deficiency there may be potential for neuro-degeneration [17, 18]. Several cases of adult-onset CEP have been described associated with blood dyscrasias such as myelodysplasia and thrombocytopenia [19-21].

Increase in life expectancy for patients with Gunther disease beyond 60 years of age can be attributed to better supportive care with skin antiseptics, antibiotic use, sun exposure avoidance, more effective sun protection, better wound care, and regular blood transfusions if needed. Blood transfusions provide negative feedback to reduce endogenous porphyrin synthesis through raising heme levels in addition to correcting low hematocrit secondary to hemolysis [5, 22, 23]. The chemotherapeutic hydroxyurea has been used in some severe cases to reduce endogenous porphyrin production [24].

Education of patients is essential; they must understand that near ultraviolet light can penetrate window glass and artificial lighting should be filtered or covered with protective films [25]. Cautious use of medications that may induce cholestasis (including oral estrogens, terbinafine, azathioprine, erythromycin, clavulanic acid) is recommended for patients with porphyria [26-28]. Strict avoidance of sun exposure requires mandatory vitamin D supplementation to minimize risk of deficiency. Oral antioxidants such

as β -carotene and narrowband UVB phototherapy have been proposed but neither approach has shown reproducible benefits [25]. Similarly, reports of the use of oral charcoal, hydroxychloroquine, plasmapheresis, and intravenous hematin have not shown conclusive benefit either [5, 25, 29]. Splenectomy may be necessary for patients with splenomegaly and hemolytic anemia, leucopenia, or thrombocytopenia. Splenectomy may correct the blood dyscrasia, improve RBC lifespan and indirectly may reduce photosensitivity [21].

The sole curative treatment is allogenic bone marrow transplant (BMT), first described in use for CEP by Kauffman et al. [30]. Further articles have yielded favorable results from allogenic BMT culminating in a case series of six transplants in which management algorithms have been proposed [25, 31-35]. Only patients with severe Gunther disease are suitable for BMT after HLA matching early in the condition [4, 32, 33, 36].

A recent and novel approach is induction of iron deficiency in CEP patients, which contributes to symptom improvement with improved growth and erythroid differentiation in bone marrow [37]. Gene therapy has demonstrated promise with long term correction of the enzyme defect in a murine model, induced pluripotent stem cells, and RNA interference [38-40].

The use of proteasome inhibitors such as bortezomib (used in multiple myeloma) has inhibited accelerated degradation of UROIII caused by both C73R and P248Q mutations. Animal studies using bortezomib have shown reduced skin photosensitivity and reduced accumulation of porphyrins. However, long term use of bortezomib could lead to neuropathy in patients [41, 42]. Development of new proteasome inhibitors with less toxicity may be more applicable for use in CEP in the future.

Another promising agent is afamelanotide, a novel melanocortin stimulating hormone analogue with agonist properties at the melanocortin-1 receptor that has been demonstrated to promote melanin synthesis. Afamelanotide is approved in Europe for use in EPP and we postulate similar reproducible effects may be possible for patients with CEP such as

observed in our patient [43, 44].

Conclusion

This male patient is the only known person with true lifelong CEP in Australia (population 24 million) leading us to propose that this condition may be under/misdiagnosed. Our patient was misdiagnosed for many years. With severe cutaneous complications resulting from even brief sunlight exposure, patients with the condition often require significant lifestyle modifications. The treating dermatologist should be involved in making the diagnosis and advising on phototherapy, wound care, and choice of antibiotics. Hematologists, primary care physicians, and other specialists should work together as necessary to manage complications and ensure the best care. The need for continuous long term followup in these patients is emphasized. In particular, regular skin checks are necessary to assess erosions, ulceration, photodamage, scar tissue, secondary infections, and development of malignancies. Education is another key paradigm of management from the treating dermatologist in advising for strict photoprotection and use of topical antiseptic solutions where appropriate. Overall, further research into this rare condition is warranted, particularly into development of further management options. Development of an RCT to quantify benefit for afamelanotide in patients with CEP would be a step forward. We hope that with further ongoing research into promising gene therapy there is potential for a less invasive and complex cure than bone marrow transplantation for patients with CEP.

References

- Solis C, Aizencang GI, Astrin KH, et al. Uroporphyrinogen III synthase erythroid promoter mutations in adjacent GATA1 and CP2 elements cause congenital erythropoietic porphyria. *J Clin Invest*. 2001;107(6):753-62.<http://dx.doi.org/10.1172/jci10642> [PMID: 11254675]
- Desnick R, Astrin K. Congenital erythropoietic porphyria: advances in pathogenesis and treatment. *Br J Haematol*. 2002;117(4):779-95.<http://dx.doi.org/10.1046/j.1365-2141.2002.03557.x> [PMID: 12060112]
- Howard M, Hall A, Ramsay D. Beneficial use of a novel topical hypochlorous acid preparation for chronic dematoses at risk of secondary infection. *Australasian Journal of Dermatology*. 2016; Article accepted and awaiting publication
- Katugampola R, Badminton M, Finlay A, et al. Congenital erythropoietic porphyria: a single-observer clinical study of 29 cases. *Br J Dermatol*. 2012;167(4):901-13.[doi: 10.1111/j.1365-2133.2012.11160.x](http://dx.doi.org/10.1111/j.1365-2133.2012.11160.x). [PMID: 22816431]
- Fritsch C, Bolsen K, Ruzicka T, et al. Congenital erythropoietic porphyria. *J Am Acad Dermatol*. 1997;36(4):594-610.[http://dx.doi.org/10.1016/s0190-9622\(97\)70249-4](http://dx.doi.org/10.1016/s0190-9622(97)70249-4) [PMID: 9092747]
- Schultz J. Ein Fall von Pempbigus leprosus, compliziert dutch Lepta visceralis (thesis). Greifswald. 1874
- Gunther H. Die Haematoporphyrie. *Deutsches Archiv für klinische Medizin*. 1912;105(89-146)
- Lee W-H, Tai W-C, Wu P-Y. Congenital erythropoietic porphyria. *Dermatology Sinica*. 2012;30(2):62-5.<http://dx.doi.org/10.1016/j.dsi.2011.09.012>
- Bickers D. The dermatologic manifestations of human porphyria. *Ann N Y Acad Sci*. 1987;514:261-7.<http://dx.doi.org/10.1111/j.1749-6632.1987.tb48781.x> [PMID: 3327430]
- Veenashree M, Sangwan V, Vemuganti G, et al. Acute Scleritis as a Manifestation of Congenital Erythropoietic Porphyria. *Cornea*. 2002;21(5):530-1.<http://dx.doi.org/10.1097/00003226-200207000-00018> [PMID: 12072732]
- Pandhi D, Suman M, Khurana N, et al. Congenital erythropoietic porphyria complicated by squamous cell carcinoma. *Pediatr Dermatol*. 2003;20(6):498-501.<http://dx.doi.org/10.1111/j.1525-1470.2003.20609.x> [PMID: 14651569]
- To-Figueras J, Badenas C, Mascaro J, et al. Study of the genotype-phenotype relationship in four cases of congenital erythropoietic porphyria. *Blood Cells Mol Dis*. 2007;38(3):242-6.<http://dx.doi.org/10.1016/j.bcmd.2006.12.001> [PMID: 17270473]
- Bologna J, Jorrizo J, Schaffer J. *Dermatology*. 3rd ed: Elsevier Saunders; 2012.
- Fresemann A, Gross U, Bensidhoum M, et al. Immunological, enzymatic and biochemical studies of uroporphyrinogen III-synthase deficiency in 20 patients with congenital erythropoietic porphyria. *Eur J Biochem*. 1998;257(1):149-53.<http://dx.doi.org/10.1046/j.1432-1327.1998.2570149.x> [PMID: 9799113]
- Stenson P, Mort M, Ball E, et al. The Human Gene Mutation Database: building a comprehensive mutation repository for clinical and molecular genetics, diagnostic testing and personalized genomic medicine. *Human Genetics*. 2014;133(1):1-9 [PMID: 24077912]
- Maynard B, Peters M. Histologic and immunofluorescence study of cutaneous porphyrias. *J Cutan Pathol*. 1992;19(1):40-7 [PMID: 1556265]
- Sidorsky T, Christine C, Epstein J, et al. Development of corticobasal syndrome in a patient with congenital erythropoietic porphyria. *Parkinsonism Relat Disord*. 2014;20(3):349-50.<http://dx.doi.org/10.1016/j.parkreldis.2013.12.004> [PMID: 24388147]
- Darwich E, Guilabert A, Aceituno A, et al. Congenital erythropoietic porphyria and Parkinson's disease: clinical association in a patient with a long-term follow-up. *Eur J Dermatol*. 2011;21(4):613-4 [PMID: 21840789]
- Kontos A, Ozog D, Bichakjian C, et al. Congenital erythropoietic porphyria associated with myelodysplasia presenting in a 72-year-old man: report of a case and review of the literature. *Br J Dermatol*. 2003;148(1):160-4.<http://dx.doi.org/10.1046/j.1365-2133.2003.05040.x> [PMID: 12534613]
- Yamauchi K, Kushibiki Y. Pyridoxal 5-phosphate therapy in a patient with myelodysplastic syndrome and adult onset congenital erythropoietic porphyria. *Br J Haematol*. 1992;81(4):614-5.<http://dx.doi.org/10.1111/j.1365-2141.1992.tb03002.x> [PMID: 1390252]
- Murphy A, Gibson G, Elder G, et al. Adult-onset congenital erythropoietic porphyria (Günther's disease) presenting with thrombocytopenia. *J R Soc Med*. 1995;88(6):357P-8P. [PMID: 7629774]
- Piomelli S, Poh-Fitzpatrick M, Seaman C, et al. Complete suppression of the symptoms of congenital erythropoietic porphyria by long-term treatment with high-level transfusions. *N Engl J Med*. 1986;314(16):1029-31.<http://dx.doi.org/10.1056/nejm198604173141607> [PMID: 3960070]
- Dawe S, Peters T, Du Vivier A, et al. Congenital erythropoietic

- porphyria: dilemmas in present day management. *Clin Exp Dermatol.* 2002;27(8):680-3.<http://dx.doi.org/10.1046/j.1365-2230.2002.01166.x> [PMID: 12472546]
24. Guarini L, Piomelli S, Poh-Fitzpatrick M. Hydroxyurea in congenital erythropoietic porphyria. *N Engl J Med.* 1994;330(15):1091-2.<http://dx.doi.org/10.1056/nejm199404143301519> [PMID: 8127351]
25. Katugampola R, Anstey A, Finlay A, et al. A management algorithm for congenital erythropoietic porphyria derived from a study of 29 cases. *Br J Dermatol.* 2012;167(4):888-900.<http://dx.doi.org/10.1111/j.1365-2133.2012.11154.x> PMID: 22804244
26. Padda M, Sanchez M, Akhtar A, et al. DRUG INDUCED CHOLESTASIS. *Hepatology.* 2011;53(4):1377-87. [PMCID: PMC3089004]
27. Lazaros G, Papatheodoridis G, Delladetsima J, et al. Terbinafine-induced cholestatic liver disease. *J Hepatol.* 1996;23(6):753-6.[http://dx.doi.org/10.1016/s0168-8278\(96\)80273-x](http://dx.doi.org/10.1016/s0168-8278(96)80273-x) [PMID: 8835752]
28. Fernandes N, Geller S, Fong T-L. Terbinafine Hepatotoxicity: Case Report and Review of the Literature. *Am J Gastroenterol.* 1998;93(3):459-60.[http://dx.doi.org/10.1016/s0002-9270\(98\)00011-2](http://dx.doi.org/10.1016/s0002-9270(98)00011-2) [PMID: 9517658]
29. Minder E, Schneider-Yin X, Möll F. Lack of effect of oral charcoal in congenital erythropoietic porphyria. *N Engl J Med.* 1994;330(15):1092-4.<http://dx.doi.org/10.1056/nejm199404143301520> [PMID: 8127352]
30. Kauffman L, Evans D, Stevens R, et al. Bone-marrow transplantation for congenital erythropoietic porphyria. *Lancet.* 1991;337(8756):1510-1.[http://dx.doi.org/10.1016/0140-6736\(91\)93198-i](http://dx.doi.org/10.1016/0140-6736(91)93198-i) [PMID: 1675371]
31. Tezcan I, Xu W, Gurgey A, et al. Congenital erythropoietic porphyria successfully treated by allogeneic bone marrow transplantation. *Blood.* 1998;92(11):4053-8.<http://dx.doi.org/10.1038/sj.bmt.1702738> [PMID: 9834209]
32. Harada F, Shwayder T, Desnick R, et al. Treatment of severe congenital erythropoietic porphyria by bone marrow transplantation. *J Am Acad Dermatol.* 2001;45(2):279-82.<http://dx.doi.org/10.1067/mjd.2001.114730> [PMID: 11464191]
33. Shaw P, Mancini A, McConnell J, et al. Treatment of congenital erythropoietic porphyria in children by allogeneic stem cell transplantation: a case report and review of the literature. *Bone Marrow Transplantation.* 2001;27(1):101-5.<http://dx.doi.org/10.1038/sj.bmt.1702738> [PMID: 11244446]
34. Dupuis-Girod S, Akkari V, Ged C, et al. Successful match-unrelated donor bone marrow transplantation for congenital erythropoietic porphyria (Gunther disease). *Eur J Pediatr.* 2005;164(2):104-7.<http://dx.doi.org/10.1007/s00431-004-1575-x> [PMID: 15703981]
35. Martinez Peinado C, Diaz de Heredia C, To-Figueras J, et al. Successful treatment of congenital erythropoietic porphyria using matched unrelated hematopoietic stem cell transplantation. *Pediatr Dermatol.* 2013;30(4):484-9.<http://dx.doi.org/10.1111/pde.12117> [PMID: 23557135]
36. Taibjee S, Stevenson O, Abdullah A, et al. Allogeneic bone marrow transplantation in a 7-year-old girl with congenital erythropoietic porphyria: a treatment dilemma. *Br J Dermatol.* 2007;156(3):567-71.<http://dx.doi.org/10.1111/j.1365-2133.2006.07699.x> [PMID: 17300251]
37. Egan DN, Yang Z, Phillips J, et al. Inducing iron deficiency improves erythropoiesis and photosensitivity in congenital erythropoietic porphyria. *Blood.* 2015;126(2):257-61.<http://dx.doi.org/10.1182/blood-2014-07-584664> [PMID: 25972160]
38. Robert-Richard E, Moreau-Gaudry F, Lalanne M, et al. Effective gene therapy of mice with congenital erythropoietic porphyria is facilitated by a survival advantage of corrected erythroid cells. *Am J Hum Genet.* 2008;82(1):113-24.<http://dx.doi.org/10.1016/j.ajhg.2007.09.007> [PMID: 18179890]
39. Bedel A, Taillepierre M, Guyonnet-Duperat V, et al. Metabolic correction of congenital erythropoietic porphyria with iPSCs free of reprogramming factors. *Am J Hum Genet.* 2012;91(1):109-21.<http://dx.doi.org/10.1016/j.ajhg.2012.05.026> [PMID: 22795135]
40. Robert-Richard E, Lalanne M, Lamrissi-Garcia I, et al. Modeling of congenital erythropoietic porphyria by RNA interference: a new tool for preclinical gene therapy evaluation. *J Gene Med.* 2010;12(8):637-46 [PMID: 20586119]
41. Blouin J, Duchartre Y, Costet P, et al. Therapeutic potential of proteasome inhibitors in congenital erythropoietic porphyria. *Proc Natl Acad Sci USA.* 2013;110(45):18238-43.<http://dx.doi.org/10.1073/pnas.1314177110> [PMID: 24145442]
42. Mujtaba T, Dou Q. Advances in the understanding of mechanisms and therapeutic use of bortezomib. *Discov Med.* 2011;12(67):471-80 [PMID: 22204764]
43. Fabrikant J, Toulouei K, Brown S. A review and update on melanocyte stimulating hormone therapy: afamelanotide. *J Drugs Dermatol.* 2013;12(7):775-9. [PMID: 23884489]
44. Harms J, Lautenschlager S, Minder C, et al. Mitigating photosensitivity of erythropoietic protoporphyria patients by an agonistic analog of alpha-melanocyte stimulating hormone. *Photochem Photobiol.* 2009;85(6):1434-9.<http://dx.doi.org/10.1111/j.1751-1097.2009.00595.x> [PMID: 19656325]