

UC Davis

Dermatology Online Journal

Title

Erythematous papules on the penis as first manifestation of metastatic prostate adenocarcinoma

Permalink

<https://escholarship.org/uc/item/1059k69c>

Journal

Dermatology Online Journal, 27(1)

Authors

Sandoval-Clavijo, Alejandra
Castillo, Paola
Toll, Agustí

Publication Date

2021

DOI

10.5070/D3271052036

Copyright Information

Copyright 2021 by the author(s). This work is made available under the terms of a Creative Commons Attribution-NonCommercial-NoDerivatives License, available at <https://creativecommons.org/licenses/by-nc-nd/4.0/>

Peer reviewed

Erythematous papules on the penis as first manifestation of metastatic prostate adenocarcinoma

Alejandra Sandoval-Clavijo¹ MD, Paola Castillo² MD PhD, Agustí Toll¹ MD PhD

Affiliations: ¹Department of Dermatology, Hospital Clínic, Barcelona, Spain, ²Department of Pathology, Hospital Clínic, Institut d'Investigacions Biomèdiques August Pi i Sunyer (IDIBAPS), University of Barcelona, Barcelona, Spain

Corresponding Author: Alejandra Sandoval-Clavijo, Carrer Villarroel 170, 08036, Barcelona, Spain, Tel: 34-632692050, Email: alesancla@hotmail.com

Abstract

We report a 70-year-old man with asymptomatic reddish papules on the glans penis that histologically showed metastases of prostate adenocarcinoma. He had a medical history of a stage IV undifferentiated prostate adenocarcinoma that was currently being treated with chemotherapy. The medical history of advanced stage prostate adenocarcinoma associated with the clinical and pathological findings confirmed the diagnosis of penile metastatic prostate adenocarcinoma. This is an example of the relevance of a thorough history combined with histopathological and immunohistochemical correlation which allowed the diagnosis of a penile lesion that may be the first manifestation of prostate metastatic progression and should therefore be included among the differential diagnoses of penile tumors.

Keywords: prostate, adenocarcinoma, penis neoplasm

Introduction

Cutaneous metastases with the prostate as primary tumor are rare, corresponding to less than 0.5% of all metastases [1,2]. Skin manifestations of penile metastases include nodules or papules that may be isolated or multiple can involve the shaft, glans, or prepubial region [2]. The most common region affected is the shaft and the compromise of the glans penis as seen in our patient accounts for 24% of all penile metastases [1,3].

Case Synopsis

A male patient in his 70s presented with an 8-week history of asymptomatic reddish lesions on the glans

penis. Physical examination revealed indurated erythematous papules on the dorsal side of the glans corona (**Figure 1A**). Dermoscopic examination

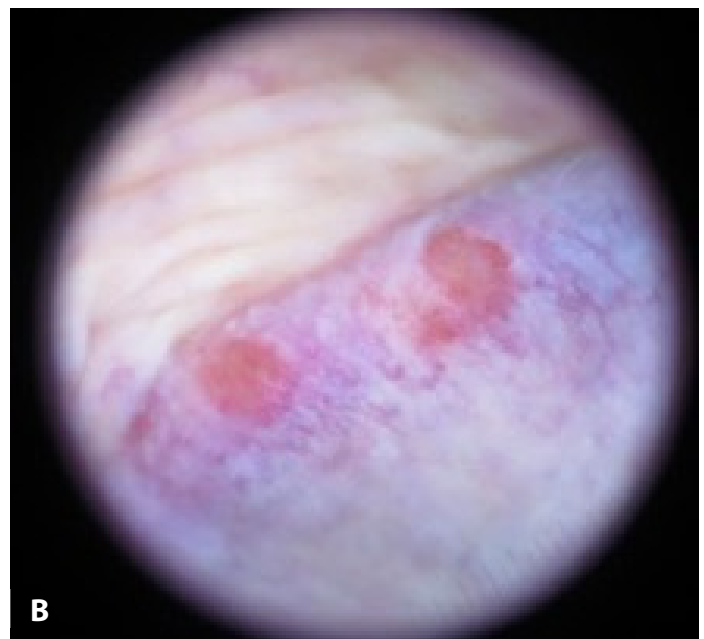
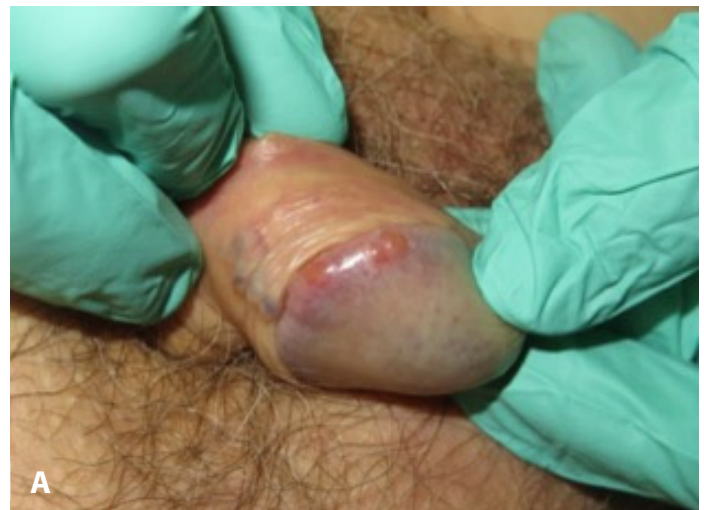

Figure 1. A) Clinical view. Erythematous, indurated papules as well as areas of diffuse erythema on the penile corona. **B)** Dermoscopy showing two red-yellowish lesions over a violet-erythematous area with small branched vessels.

showed two red-yellowish circumscribed papules (**Figure 1B**). There was a family history of urothelial carcinoma of the urinary bladder in his mother and breast cancer in his mother and sister. He had a medical history of hyperuricemia, a basal cell carcinoma, and a stage IV undifferentiated prostate adenocarcinoma that was currently being treated with chemotherapy.

An excisional biopsy from one papule of the glans corona was performed revealing an atypical proliferation of small poorly differentiated cells with a solid and focal glandular growth pattern that compromised the entire dermis (**Figure 2A**). Immunohistochemical staining showed diffuse cellular positivity for alpha-methylacyl-CoA racemase (**Figure 2B**) whereas cells were negative for prostate specific antigen (PSA).

Magnetic resonance imaging of the pelvis was performed revealing a prostatic infiltrating mass extending into the right lobe with extraprostatic infiltration of the rectal anterior wall, involvement of periosteal tissue in the right sacrum, and extension into bilateral pubic and coccygeal bone. In addition, there was a nodule in the right cavernous body. The medical history of advanced stage prostate adenocarcinoma associated with the clinical, radiological, and pathological findings confirmed the diagnosis of penile metastatic prostate adenocarcinoma.

Case Discussion

A wide spectrum of differential diagnoses has to be considered during examination of chronic erythematous indurated lesions on the penis (**Table 1**). Squamous cell carcinomas correspond to 95% of all primary tumors of the penis and are commonly associated with human papilloma virus (commonly genotypes 16 and 18). Squamous cell carcinoma can appear as painless nodules, with or without ulceration, typically located on the glans penis. Penile sarcoma represents less than 5% of penile tumors and manifests as an indurated mass without any specific location. B-cell lymphoma of the penis can manifest as a nodule, indurated plaque, diffuse penile swelling, or a non-healing ulcer that involves

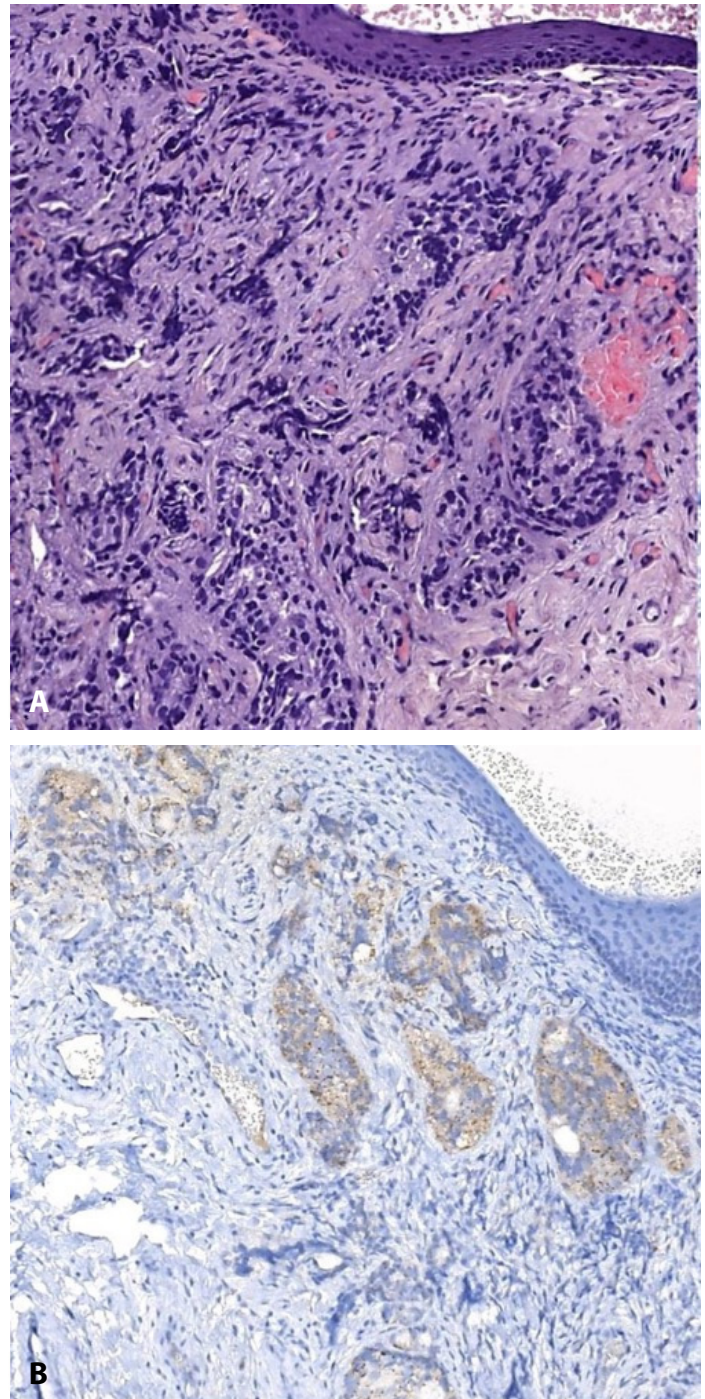


Figure 2 A) Histological image showing multiple poorly differentiated cells with a glandular pattern that compromised the entire dermis. H&E, 20x. **B)** Racemase immunostaining showing positivity, 20x.

the shaft or the glans associated with a peri-urethral abscess [4,5]. Penile involvement in prostate cancer is associated with a poor prognosis, with a four to 18-month period since the development of the metastatic lesions to death [3].

Table 1. Histopathological findings in tumoral differential diagnoses of indurated papules of the penis.

Tumor	Histopathological findings
Squamous cell carcinoma	Nests of atypical squamous cells with abundant eosinophilic cytoplasm Keratin pearls, vesicular nuclei
Penile Sarcoma	Mesenchymal spindle-shape cells Arise from smooth or striated muscle
Penile lymphoma	Diffuse large lymphoid cells with abundant cytoplasm and large nuclei Apoptotic bodies and multiple diffuse mitoses
Basal cell carcinoma	Large basaloid cells with oval nuclei that forms a palisade with a cleft from the tumoral stroma

The possible mechanisms of penile spread are hematogenous, retrograde venous, or lymphatic routes, local extension, and iatrogenic implantation [1,2]. The most likely mechanism is the retrograde venous route by communication between the dorsal venous system and the pelvic organs, generating a transportation route for malignant cells [2]. The immunohistochemical marker for PSA can guide whether the cells studied in a distant tumor are related to prostate cancer, however PSA may be negative in poorly differentiated and widespread metastatic prostate cancer as described in our patient [6].

Conclusion

Although penile metastases of prostate adenocarcinomas are infrequent, they must be

included in the differential diagnosis of penile tumors, especially considering that it can be the first manifestation of metastatic progression and that it is frequently associated with a poor prognosis [3].

Acknowledgements

We thank the patient for granting permission to publish this information and Juan Ferrando, MD PhD (Department of Dermatology, Hospital Clinic, Barcelona-Spain), for his valuable review of the article.

Potential conflicts of interest

The authors declare no conflicts of interests

References

1. Dijkstra S, Van Der Heijden AG, Schaafsma HE, et al. Synchronous penile metastasis from a high-grade adenocarcinoma of the prostate. *Case Rep Urol.* 2012;2012:193787. [PMID: 23119219].
2. Nason GJ, O'Reilly MK, Long RM, et al. A presentation of glandular penile metastases from prostate adenocarcinoma. *Scand J Urol Nephrol.* 2012;46:306-9. [PMID: 22486259].
3. Chau A, Amin M, Cubilla AL, et al. Metastatic tumors to the penis: a report of 17 cases and review of the literature. *Int J Surg Pathol.* 2011;19:597-606. [PMID: 20075023].
4. Wong HL, Shi H, Koh LT. Solitary metastasis to the penis from prostate adenocarcinoma - a case report. *J Radiol Case Rep.* 2019;13:20-28. [PMID: 32184925].
5. Stamatou K, Pierris N. Lymphoma presenting as cancer of the glans penis: a case report. *Case Rep Pathol.* 2012;2012:948352. [PMID: 23056979].
6. Bonk S, Kluth M, Hube-Magg C, et al. Prognostic and diagnostic role of PSA immunohistochemistry: a tissue microarray study on 21,000 normal and cancerous tissues. *Oncotarget.* 2019;10:5439-5453. [PMID: 31534629].