

UC San Diego

UC San Diego Previously Published Works

Title

Non-invasive evaluation of Achilles tendon and its enthesis using ultrashort echo time adiabatic T1 ρ (UTE-Adiab-T1 ρ) magnetic resonance imaging (MRI) in psoriatic arthritis

Permalink

<https://escholarship.org/uc/item/104198k7>

Authors

Moazamian, Dina

Mohammadi, Hamidreza Shaterian

Athertya, Jiyo

et al.

Publication Date

2025-02-01

DOI

10.1016/j.ejrad.2024.111841

Peer reviewed



Non-invasive evaluation of Achilles tendon and its enthesis using ultrashort echo time adiabatic $T_{1\rho}$ (UTE-Adiab- $T_{1\rho}$) magnetic resonance imaging (MRI) in psoriatic arthritis

Dina Moazamian^{a,1,*}, Hamidreza Shaterian Mohammadi^{a,1,*}, Jiyo Athertya^a, Mahyar Daskareh^a, Yajun Ma^a, Monica Guma^b, Dana C. Covey^c, Tony Yaksh^d, Abha Singh^b, Arthur Kavanaugh^b, Christine B. Chung^{a,e}, Jiang Du^{a,e}, Eric Y. Chang^{a,e,**}, Saeed Jerban^{a,*}

^a Department of Radiology, University of California, San Diego, CA, USA

^b Department of Rheumatology, University of California, San Diego, CA, USA

^c Department of Orthopaedic Surgery, University of California, San Diego, CA, USA

^d Department of Anesthesiology, University of California, San Diego, CA, USA

^e Radiology Service, VA San Diego Healthcare System, San Diego, CA, USA

ARTICLE INFO

Keywords:

Achilles tendon
Enthesis
Psoriatic arthritis
UTE-MRI
MRI

ABSTRACT

Purpose: This cross-sectional study investigates the utility of the quantitative ultrashort echo time (UTE) adiabatic $T_{1\rho}$ (UTE-Adiab- $T_{1\rho}$) magnetic resonance imaging (MRI) in detecting potential differences in Achilles tendons and entheses of patients with psoriatic arthritis disease (PsA) compared with asymptomatic volunteers.

Material and Method: The Achilles tendons of forty-four PsA patients (59 ± 15 years old, 38 % female) and thirty-seven asymptomatic volunteers (32 ± 10 years old, 51 % female) were scanned on a 3 T clinical scanner in the sagittal plane using a 3-inch surface coil. The 3D UTE-Adiab- $T_{1\rho}$ sequences with fat saturation (FS) were used to measure UTE-Adiab- $T_{1\rho}$, Tenderness of the tendons, the SF-12 health survey, and visual analog scale (VAS) were recorded for the patients. The Kruskal Wallis test was used to examine the differences in UTE-Adiab- $T_{1\rho}$ values between asymptomatic volunteers and patients, as well as subgroups of patients with pain in the Achilles tendon region and those treated with Biologics. Spearman's correlation coefficients were calculated between UTE-Adiab- $T_{1\rho}$ and patient evaluations. P values < 0.05 were considered significant.

Results: UTE-Adiab- $T_{1\rho}$ was significantly higher for the PsA group compared with the asymptomatic group in the enthesis (11.4 ± 2.6 ms vs. 10.4 ± 2.4 ms) and tensile tendon regions (9.8 ± 2.8 ms vs. 7.7 ± 1.7 ms). PsA patients with active Achilles pain showed significantly lower $T_{1\rho}$ in the entheses compared with other patients (10.7 ± 2.6 ms vs. 11.7 ± 2.5 ms). PsA patients treated with Biologics showed significantly lower $T_{1\rho}$ values in the tendon compared with other patients (9.5 ± 2.5 ms vs. 10.3 ± 3.3 ms). The VAS score of patients showed a significant negative but weak correlation ($R = -0.2$) with UTE-Adiab- $T_{1\rho}$ of the enthesis. Correlations with SF-12 scores were not significant.

Conclusion: This study highlighted the UTE-Adiab- $T_{1\rho}$ sequence capability in evaluating tendons and entheses and their potential involvement in PsA disease or response to therapies.

Abbreviations: MRI, magnetic resonance imaging; 3D, three-dimensional; UTE, ultrashort echo time imaging; RF, radiofrequency; FOV, field of view; ROI, region of interest; TE, echo time; TR, repetition time; FA, flip angle; PsA, psoriasis arthritis; SpA, spondyloarthropathies; qMRI, quantitative magnetic resonance imaging.

* Corresponding authors at: Department of Radiology, University of California, San Diego, 9500 Gilman Dr., La Jolla, CA 92093, USA.

** Corresponding author at: VA San Diego Healthcare System, San Diego, CA 92161, USA.

E-mail addresses: dmoazamian@health.ucsd.edu (D. Moazamian), hmohammadi@health.ucsd.edu (H.S. Mohammadi), eric.chang2@va.gov (E.Y. Chang), sjerban@health.ucsd.edu (S. Jerban).

¹ Dina Moazamian and Hamidreza Shaterian Mohammadi equally contributed to this research work.

<https://doi.org/10.1016/j.ejrad.2024.111841>

Received 13 August 2024; Received in revised form 27 October 2024; Accepted 18 November 2024

Available online 26 November 2024

0720-048X/© 2024 Elsevier B.V. All rights are reserved, including those for text and data mining, AI training, and similar technologies.

1. Introduction

Enthesis organs consist of periosteal fibrocartilages, bursae, and fat pads and play a critical role in stress resistance and anchorage [1]. Inflammation at the enthesal sites is common in the pathophysiology of psoriatic arthritis (PsA) [2,3], which follows an increase in synovial tissue proliferation, breakdown of fibrocartilaginous structures, and enhanced vascularization. Alterations in the entheses, manifest by fibrocartilage degeneration, bone marrow edema, and erosion at tendon insertion sites occur [4,5]. Therefore, identifying and assessing enthesitis involvement in PsA is crucial for understanding the disease progression and optimizing treatment strategies [1,6]. Assessment of the tenderness at the enthesal site in physical exams is the standard way to diagnose enthesitis clinically (i.e., inflammation in enthesitis). Tenderness, however, does not indicate inflammation in every instance, nor does its absence rule out enthesitis [3,7]. So, medical imaging plays an important role in the noninvasive and timely diagnosis of involvement of the enthesitis and tendon in PsA to avoid late chronic sequelae [8,9].

Magnetic resonance imaging (MRI) is the main imaging modality routinely used for the morphological evaluation of tendons and entheses [10]. Enthesitis is usually characterized by diffuse *peri*-enthesal soft tissue edema on MRI [1,11]. While conventional MRI, such as longitudinal relaxation time (T1)-weighted and fat-suppressed transverse relaxation time (T2) –weighted sequences, offer detailed morphological information, they may not be sensitive enough to detect early pathological changes in the enthesitis and tendon. Early pathological changes might be detectable using quantitative MRI if a high signal could be acquired from the tendon and enthesitis. Unfortunately, conventional MRI is not able to detect a considerable signal of tendon and enthesitis at the early stages of the disease or of the potentially involved fibrotic tissues because of the very short T2s in such tissues [6,12,13].

To address this limitation, innovative MRI approaches, such as ultrashort echo time (UTE) sequences, have been developed that can acquire high signals of both short and long T2 tissues and can provide quantitative assessments of such tissues [14–17]. Quantitative UTE-MRI biomarkers such as UTE T1, T2*, magnetization transfer ratio, and magnetization transfer modeling have been reported to correlate with microstructural and compositional changes in musculoskeletal tissues [13,17–23].

Among quantitative MRI techniques (qMRI), the longitudinal relaxation time in a rotating frame ($T_{1\rho}$) has been reported to be sensitive to compositional changes in cartilaginous tissues [24,25], which are similar to the enthesal fibrocartilage tissue. Three-dimensional Cones UTE MRI, combined with adiabatic inversion recovery spin-lock preparation (3D UTE-Adiab- $T_{1\rho}$) and fat-saturation (FS) preparation, has been utilized to measure $T_{1\rho}$ with low sensitivity to the magic angle effect [26,27]. This will likely result in more consistent quantification of tendons and entheses abnormalities, regardless of the tissue orientation inside the MR scanner. UTE-Adiab- $T_{1\rho}$ has been previously shown to have microstructural and mechanical properties of the entheses, tendons, ligaments, and articular cartilage [26,28,29].

This study aims to investigate the utility of the 3D UTE-Adiab- $T_{1\rho}$ in detecting the Achilles tendon and its enthesitis abnormalities in patients with PsA disease and to explore differences with asymptomatic volunteers.

2. Methods and Materials

2.1. Subjects

This cross-sectional study was approved by the institutional review board (IRB) at the University of California, San Diego. Written informed consent was obtained from all subjects. Between September 2021 and April 2023, adult participants between 19–90 years of age and without a history of trauma to the ankle were recruited. The asymptomatic cohort consisted of volunteers from the University campus with no ankle

symptoms of any sort. The PsA cohort consisted of consecutive volunteer patients referred from our rheumatology clinic with a diagnosis of PsA based on the Classification Criteria for Psoriatic Arthritis (CASPAR) [30]. Each patient completed the SF-12 health survey, which provides summary scores for physical and mental health, known as the Physical Component Summary (PCS) and Mental Component Summary (MCS) [31]. PCS and MCS scores above 50 indicate better physical and mental health than the average person in the general population, respectively. Additionally, the overall visual analog scale (VAS, pain intensity scale from 0 to 10) was recorded for each patient. The presence of pain or tenderness at Achilles tendon insertion was examined. The tenderness was also examined in the lateral elbow epicondyle and medial femoral condyle to examine the extent of the disease in recruited patients.

2.2. Image acquisition

One ankle of the participants was scanned using a 3 T clinical scanner (MR750, GE Healthcare Technologies, Milwaukee, WI) employing a 3-inch surface coil. The painful side was scanned for patients with unilateral pain. The participants' leg laterality was self-selected for patients with no pain or bilateral pain. The acquisition was performed in the sagittal plane using A) 3D UTE-Adiab- $T_{1\rho}$ FS images were acquired with echo time (TE) = 0.03 ms, repetition time (TR) = 450 ms, spin-locking time (TSL) = 0, 12, 24, and 48 ms (number of adiabatic full passage pulse = 0, 2, 4, and 8), flip angle (FA) = 10°, number of spokes = 21, slice thickness = 2.0 mm, number of slices = 36, field of view (FOV) = 100 mm², matrix size = 256 × 256 [15,26], B) clinical two-dimensional (2D) fat-suppressed (FS) T2-weighted fast spin echo (FS T2W-FES) sequence with a TE = 70 ms, TR = 4713 ms, slice thickness = 2.0 mm, FOV = 100 mm², number of slices = 17, matrix size = 512 × 512, and C) 2D proton-density weighted (PDW) FSE sequence with a TE = 31.9 ms, TR = 2000 ms, slice thickness = 2.0 mm, FOV = 100 mm², number of slices = 17, and matrix size = 512 × 512.

2.3. Image/Data analysis

For each patient, the image registration was performed using the Elastix software (<https://elastix.lumc.nl/>) based on the well-known Insight segmentation and registration toolkit (ITK) to compensate for potential subject motions between sequences. Specifically, a rigid transformation was applied for coarse registration between images, followed by affine and b-spline nonrigid transformations for more accurate registration.

Quantitative UTE analysis was performed on two sagittal slices 4 mm apart. On each slice, two different regions of interest (ROIs) were selected: first, in the tensile portion of the Achilles tendon and second, in the enthesitis covering the deep half of the tendon's longitudinal cross-section (approximated by the readers, near the calcaneus bone). The hypointense calcaneal cortex and its adjacent hyperintense layers were excluded in the enthesitis ROI section to avoid potential partial volume artifacts.

UTE-Adiab- $T_{1\rho}$ FS measurements were performed using a single-component exponential fitting model [15]. The data analysis and ROI selection were performed by an experienced postdoctoral scholar, blinded to the patient group and clinical data, using MATLAB software (2022, The MathWorks Inc., MA).

2.4. Statistical analysis

SPSS software (IBM, Armonk, NY, USA, version 28.0) was used for all statistical analyses. The Kolmogorov–Smirnov test was used to examine whether the results were normally distributed. The UTE-Adiab- $T_{1\rho}$ values in the Achilles tendons and entheses were compared between the asymptomatic volunteers and the PsA group. The Mann-Whitney-*U* test was used to examine the UTE-Adiab- $T_{1\rho}$ differences (not normally distributed) between groups. The UTE-Adiab- $T_{1\rho}$ values were also

compared between subgroups of the patients with and without pain in the Achilles tendon region and those treated and untreated with disease-modifying antirheumatic drugs (DMARDs) and/or Biologics medications with Kruskal Wallis test. Since the age was substantially different between the PsA and asymptomatic groups, the UTE-Adiab-T1 ρ correlation with the disease status was calculated while controlling for age differences using ranked spearman's partial correlation. The P-values less than 0.05 were considered statistically significant. Spearman's correlation coefficients were calculated between the UTE-Adiab-T1 ρ values against the SF-12 health survey scores (PCS and MCS) and VAS.

To assess intra-reader reliability, data from ten randomly selected participants were reanalyzed by a single reader on two separate days, approximately three weeks apart. The intraclass correlation coefficients (ICCs) were calculated between the two observations. To evaluate the inter-reader reliability, all data were reanalyzed by a second reader (an early career radiologist). ICCs were calculated between the results of the two readers. To evaluate the test-retest reliability (repeatability) of the scanning and data processing protocol, one asymptomatic volunteer was scanned three times on different days, and the coefficient of variation was calculated.

3. Results

Forty-nine patients were diagnosed with PsA, and thirty-eight asymptomatic volunteers were scanned. However, due to severe motion artifacts that could not be resolved with retrospective motion correction, our final cohorts consisted of forty-four PsA patients (59 \pm 15 years old, 38 % female) and thirty-seven asymptomatic volunteers (32 \pm 10 years old, 51 % female). Demographic findings, questionnaires, and physical exam results of the PsA patients are summarized in Table 1.

Fig. 1A and B show representative ankle images for an asymptomatic 35-year-old male volunteer acquired with FS T2W-FSE and PDW-FSE, respectively, which show no signal at the Achilles tendon (blue arrow) and enthesis (yellow arrow). Fig. 1C shows the UTE-T1 ρ image for the same participant, where the enthesis and Achilles tendon demonstrate a high signal. The captured high signal in the enthesis and Achilles tendon lets to measure the T1 ρ values which provides quantitative insights into the microstructural properties of these tissues. These values help to distinguish or interpret the MRI imaging findings and should be seen alongside each other.

Fig. 2A and B demonstrate the fitting curves of UTE-Adiab-T1 ρ for enthesis and the Achilles tendon of a 68-year-old male with PsA, respectively. Fig. 2C and D show the fitting curves of UTE-Adiab-T1 ρ for enthesis and the Achilles tendon of a 36-year-old male asymptomatic volunteer, respectively. Exponential curves fit the acquired data very well. Higher T1 ρ values were measured in PsA patients for both the

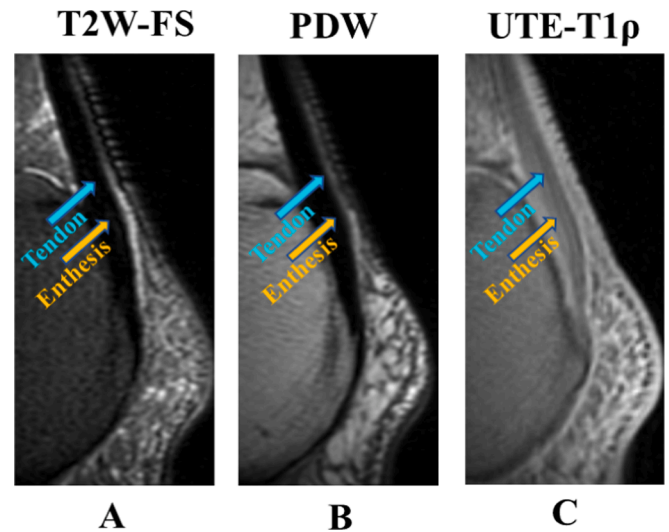


Fig. 1. (A) FS T2W-FES (B) PDW FSE (C) 3D UTE-T1 ρ images of the ankle for an asymptomatic 35-year-old male volunteer. Note that the Achilles tendon (blue arrow) and enthesis (yellow arrow) show no signal on conventional clinical MRI images (A and B). On the 3D UTE-T1 ρ image, the enthesis is evident as a region with a higher signal between the Achilles tendon and calcaneus (C). FS, fat-suppressed; FS T2W-FES, FS T2-weighted fast spin echo; PDW, Proton-density weighted; 3D, three-dimensional; UTE, ultrashort echo time; UTE-Adiab-T1 ρ , UTE-adiabatic T1 ρ .

Achilles tendon and its enthesis.

Fig. 3 demonstrates the difference between asymptomatic volunteers and all patients in the form of boxplots. UTE-Adiab-T1 ρ was significantly higher in the Achilles enthesis and tendon of the patients, compared with the asymptomatic volunteers (11.4 \pm 2.6 ms vs. 10.4 \pm 2.4 ms, p = 0.017 for the enthesis region, and 9.8 \pm 2.8 ms vs. 7.7 \pm 1.7 ms, p < 0.001 for the tendon region). The ranked spearman's correlations between UTE-Adiab-T1 ρ and PsA diagnosis was R = 0.20 (p = 0.016) and R = 0.44 (p < 0.001) in enthesis and tendon, respectively. Such correlations were similarly significant when controlled for age differences between the groups; R = 0.21 (p = 0.010) and R = 0.36 (p < 0.001) in enthesis and tendon, respectively.

Fig. 4 demonstrates the difference between asymptomatic volunteers and the Achilles-active patients (with Achilles tendon pain) and Achilles-inactive patients (without Achilles tendon pain). UTE-Adiab-T1 ρ showed significantly lower values in the entheses of the Achilles-active PsA patients compared with other patients (10.7 \pm 2.6 ms vs. 11.7 \pm 2.5 ms, P = 0.026). The UTE-Adiab-T1 ρ showed a non-significant lower trend in tendon regions of the Achilles-active PsA patients

Table 1
Demographic findings, questionnaires, and physical exam results of the PsA patients.

Demographic	Number	Sex			Age							
		44			38 % female					59 \pm 15		
Site of enthesopathy			Unilateral Pain N = 16			Bilateral Pain N = 8			No Pain N = 20			
		Number	VAS	PCS	MCS	Number	VAS	PCS	MCS	Number		
	Achilles Pain	8 Right 4 Left	4.92	36.70	50.08	2	4.5	36.05	41.32	20		
	Femoral Pain	7 Right 5 Left	3.42	38.85	51.37	6	4.2	30.50	45.26			
	Elbow Pain	2 Right 5 Left	5.14	29.45	46.94	4	5.5	25.31	48.59			
Medication History	NSAIDs		5			2			5			
	Corticosteroids		4			1			3			
	DMARDs/Biologics		8			2			13			
	N/A		8			6			5			

VAS, Visual Analog Scale; NSAID, Nonsteroidal anti-inflammatory drug; DMARD, Disease-modifying antirheumatic drugs; PCS, Physical Component Summary; MCS, Mental Component Summary; N/A, Not Applicable.

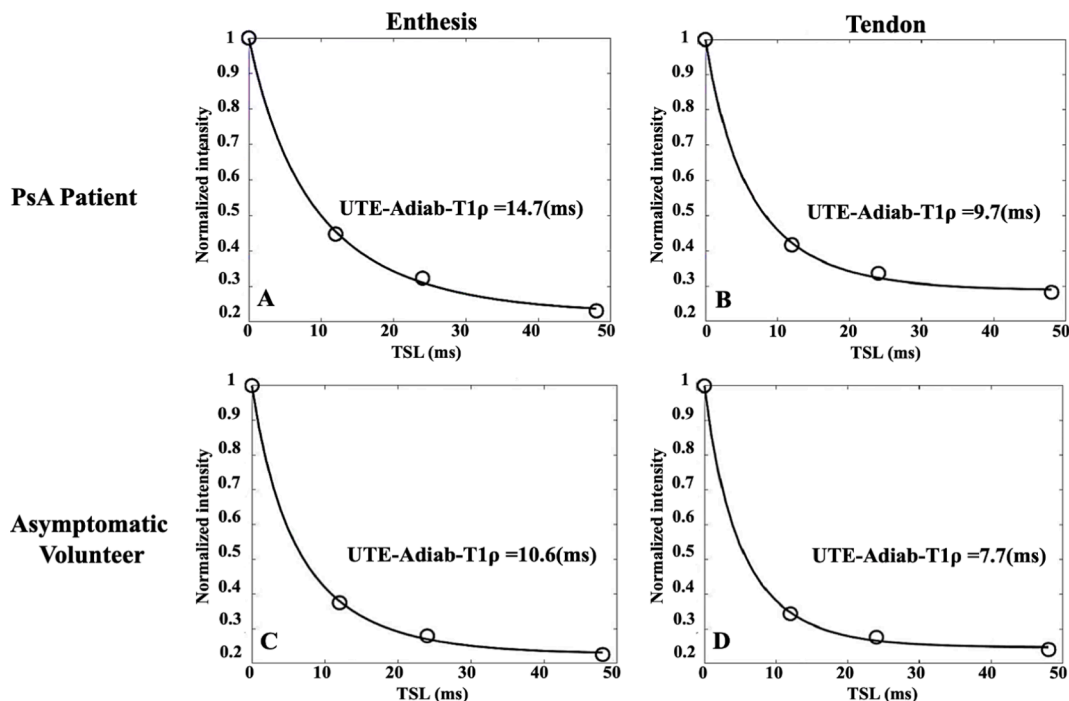


Fig. 2. Representative single-component fitting curve of normalized UTE-Adiab- $T_{1\rho}$ signal within (A) the entheses and (B) the tensile Achilles tendon regions of a 68-year-old male with PsA. The representative single-component fitting curve of normalized UTE-Adiab- $T_{1\rho}$ signal within (C) the entheses and (D) the tensile Achilles tendon regions of a 36-year-old male asymptomatic volunteer. A higher mean value of UTE-Adiab- $T_{1\rho}$ values was observed for the PsA patient (A, C) compared to the asymptomatic volunteer (B, D) in both entheses (14.7 ± 2.6 ms vs. 10.6 ± 2.4 ms) and Achilles tendon (9.7 ± 2.8 ms vs. 7.7 ± 1.6 ms). PsA, Psoriatic Arthritis; UTE, ultrashort echo time; UTE-Adiab- $T_{1\rho}$, UTE-adiabatic $T_{1\rho}$.

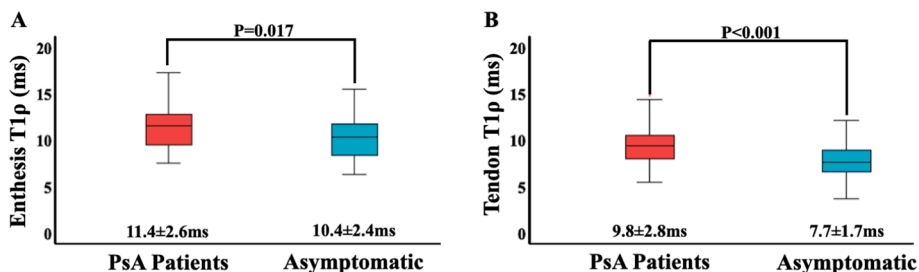


Fig. 3. (A) The boxplot of the $T_{1\rho}$ (ms) values in (A) entheses and (B) tensile tendon regions for PsA patients compared with the asymptomatic volunteers. The central line in each box indicates the median value, while the bottom and top edges of the box indicate the first and third IQR, percentiles, respectively. PsA patients showed significantly higher $T_{1\rho}$ values compared with the asymptomatic group (11.4 ± 2.6 ms vs. 10.4 ± 2.4 ms for entheses, and 9.8 ± 2.8 ms vs. 7.7 ± 1.7 ms for tensile tendon region). PsA, Psoriatic Arthritis; IQR, interquartile range.

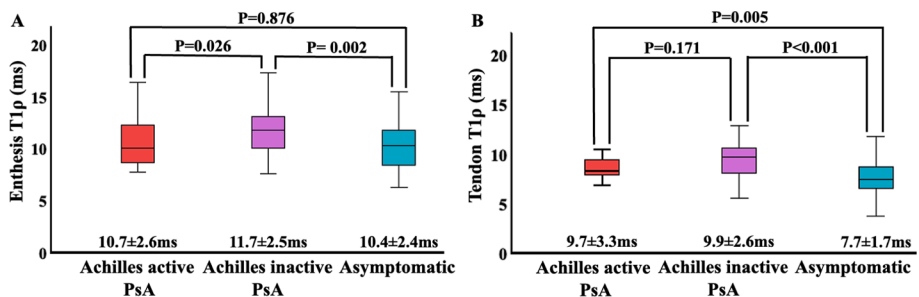


Fig. 4. (A) The boxplot of the $T_{1\rho}$ (ms) values in (A) entheses and (B) tensile tendon regions for Achilles active PsA patients (with painful ankle) compared with Achilles inactive PsA patients (without painful ankles) and the asymptomatic volunteers. The central line in each box indicates the median value, while the bottom and top edges of the box indicate the first and third IQR, percentiles, respectively. PsA, Psoriatic Arthritis; IQR, interquartile range.

compared with other patients for entheses (9.7 ± 3.3 ms vs. 9.9 ± 2.6 ms, $p = 0.171$). UTE-Adiab- $T_{1\rho}$ were higher in the entheses and the tendon of the Achilles-active PsA patients than in asymptomatic

volunteers, which was statistically significant in tendon regions (9.7 ± 3.3 ms vs. 7.7 ± 1.7 ms, $p = 0.005$), but non-significant for entheses region (10.7 ± 2.6 vs. 10.4 ± 2.4 ms $p = 0.876$).

Fig. 5 shows the UTE-Adiab-T1 ρ difference between the patients treated and untreated with DMARDs and/or Biologics. Most of the latter group was using NSAIDs and corticosteroids to manage PsA disease. UTE-Adiab-T1 ρ showed significantly lower T1 ρ values in the tendons of patients using DMARDs and/or Biologics compared with other patients (9.5 ± 2.5 ms vs. 10.3 ± 3.3 ms, $p = 0.026$). A non-significant trend of lower T1 ρ (11.4 ± 2.1 ms vs. 11.5 ± 3.2 ms, $p = 0.444$) was observed for the enthesis region of patients using DMARDs and/or Biologics. Additionally, significantly higher T1 ρ values were found in the tendon regions of PsA patients using DMARDs and/or Biologics compared with the asymptomatic volunteers (9.5 ± 2.5 ms vs. 7.7 ± 1.7 ms, $p < 0.001$). A non-significant higher trend of T1 ρ was observed in the enthesis region (11.4 ± 2.1 ms vs. 10.4 ± 2.4 ms, $p = 0.119$) of such patients compared with asymptomatic volunteers.

Fig. 6A and B show the UTE-Adiab-T1 ρ pixel map for a 68-year-old male patient and a 36-year-old male asymptomatic volunteer, respectively. Higher UTE-Adiab-T1 ρ values are obvious in the patient's pixel map for the Achilles tendon and its enthesis. Although pixel maps were not used in this study, they can be helpful if investigators are interested in localizing the enthesis abnormalities and their changes over time.

The overall VAS score of patients showed a significant negative but weak correlation ($R = -0.2$, $P < 0.04$) with UTE-Adiab-T1 ρ of the enthesis. The VAS score correlation with tendon UTE-Adiab-T1 ρ was also negative but not significant ($R = -0.1$, $P = 0.1$).

The SF-12 Health Survey PCS and MCS scores showed no significant correlations with UTE-Adiab-T1 ρ .

The ICCs for intra-reader reliability performed on the date of ten randomly selected participants were 0.96 (CI: 0.91–0.98) and 0.98 (CI: 0.96–0.99) for tendon and enthesis regions, respectively.

The ICCs for inter-reader reliability were 0.95 (CI: 0.94–0.98) and 0.85 (CI: 0.79–0.94) for the tendon and enthesis regions, respectively.

The coefficient of variation for test–retest reliability for one random asymptomatic volunteer who has been scanned three times was 3.6 % and 1.5 % for tendon and enthesis regions.

4. Discussion

This study employed quantitative UTE-Adiab-T1 ρ to evaluate the Achilles tendon and its enthesis in patients with PsA compared with asymptomatic volunteers. UTE-Adiab-T1 ρ was previously shown to have a low orientation sensitivity in the scanner [26,27], a critical advantage when utilized in cross-sectional and longitudinal clinical trials. PsA patients showed significantly higher UTE-Adiab-T1 ρ values than asymptomatic volunteers in both the Achilles tendon and its enthesis. Higher UTE-Adiab-T1 ρ in patients can be explained by potentially lower macromolecular content, such as proteoglycan (PG), less organized and softer fibers, or a higher water content [24,25,32]. These differences can be expected because of general PsA disease development and inflammation. However, such hypotheses should be examined in future pre-clinical studies by comparing them with ground-truth histological measures.

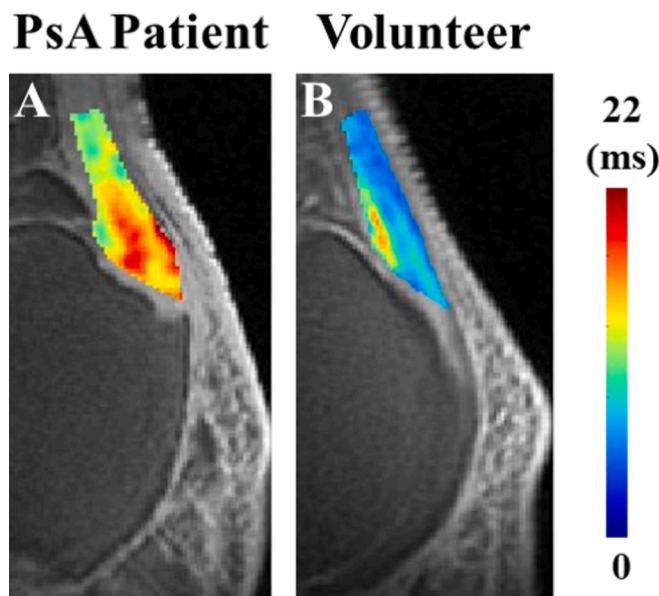


Fig. 6. Representative of (A) UTE-Adiab-T1 ρ pixel maps of covering the enthesis and tensile Achilles tendon regions of a 68-year-old male with PsA. (B) UTE-Adiab-T1 ρ pixel maps of covering the enthesis and tensile tendon regions for a 36-year-old male asymptomatic volunteer. A higher mean value of UTE-Adiab-T1 ρ values was observed for the PsA patient (A) compared to the volunteer (B) in both enthesis and Achilles tendon. PsA, Psoriatic Arthritis; UTE, ultrashort echo time; UTE-Adiab-T1 ρ , UTE-adiabatic T1 ρ .

Interestingly, the T1 ρ differences between patients and asymptomatic volunteers were lower for the Achilles-active patients. This likely suggests some levels of fibrosis development in the painful Achilles tendon, resulting in lower UTE-Adiab-T1 ρ . Notably, most of the studied patients were using medications to manage the pain and PsA development. One can hypothesize two competing mechanisms: first, enthesitis and inflammation leading to higher T1 ρ values, and second, fibrosis, which results in lower T1 ρ values. The fibrinous tissue typically associated with advanced enthesitis may demonstrate reduced vascularity, increased collagen deposition, reduced proteoglycan content, and the formation of dense connective tissue, which are difficult to quantify with current imaging techniques due to short T2 relaxation times. These changes may represent a transition from inflammatory to fibrotic pathology.

Moreover, the lower T1 ρ values in the enthesis and tendon of patients using DMARDs and/or Biologics likely indicate that such treatments have a measurable impact on the enthesis and tendon health, reversing the development of the enthesitis and inflammation. These findings suggest that UTE-Adiab-T1 ρ could serve as a valuable non-invasive tool for monitoring tendon pathology and treatment efficacy in clinical practice.

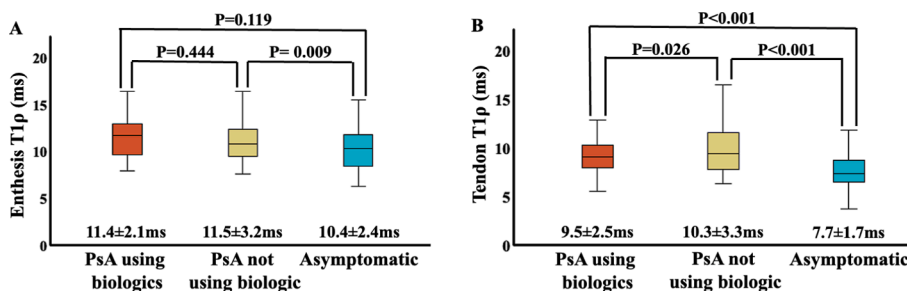


Fig. 5. (A) The boxplot of the T1 ρ (ms) values in (A) enthesis and (B) tensile tendon regions for PsA patients using DMARDs and/or Biologics compared with other patients and the asymptomatic volunteers. The central line in each box indicates the median value, while the bottom and top edges of the box indicate the first and third IQR, percentiles, respectively. PsA, Psoriatic Arthritis; IQR, interquartile range.

We observed negative correlations, though weak, between VAS score and UTE-Adiab-T1 ρ in patients, which was significant only in entheses. More painful tendons, despite the fact most patients were treated with antiinflammation medications, can be attributed to potentially more fibrotic tissues that likely demonstrate shorter relaxation times. Higher correlation levels might be achieved if only untreated PsA patients were included in the study, as PsA treatment has likely suppressed the pain level in several patients. The SF-12 Health Survey PCS and MCS scores showed no significant correlations with UTE-Adiab-T1 ρ , which also can be attributed to the treatments. Remarkably, 10 patients received a PCS score above 50, and 24 patients received an MCS score above 50, indicating better physical and mental health than the average healthy population.

MRI plays a cardinal role in the clinical diagnosis of enthesopathy due to its ability to visualize extra- and intraosseous inflammation in the entheses. Conventional T1-weighted and T2-weighted MRI images can show morphological changes in the Achilles tendon and surrounding tissues in an established enthesitis, such as the loss of the normal, flattened appearance, increased signal intensity, bone marrow edema, perienthesal inflammation, and distension of adjacent bursae [33–35]. Notably, semi-quantitative grading systems have been developed for morphological and structural evaluations of the entheses, such as the Outcome Measures in Rheumatology (OMERACT) score, which uses pre- and post-gadolinium T1-weighted and FS T2-weighted images [36]. However, early-stage enthesitis may not demonstrate substantial morphological changes to be considered in semi-quantitative grading systems. Moreover, such semi-quantitative morphological gradings are focused mainly on the surrounding tissues instead of the entheses themselves, which possess short T2s and show little or no signal with clinical sequences [37].

UTE sequences can acquire high signals and provide a quantitative assessment of tendons and entheses [12,17,37–40]. Among quantitative MRI techniques, the T1 ρ relaxation time may detect PG depletion [41,42], which likely happens in early-stage enthesitis. In a feasibility study, Du et al. used 2D-UTE-T1 ρ to examine six cadaveric ankle specimens and five healthy volunteers. The mean UTE-T1 ρ of the Achilles tendon ranged from 3.06 \pm 0.51 ms for healthy volunteers to 5.22 \pm 0.58 ms for cadaveric specimens. UTE –T1 ρ was higher (8.99 \pm 0.24 ms) in one specimen with tendon degeneration [14], which is aligned with the results of the current study. Nevertheless, 2D UTE-T1 ρ is sensitive to eddy currents, field homogeneity, and gradient nonlinearity and is susceptible to magic angle effects [14,43,44]. Later, 3D-UTE-T1 ρ was developed, providing higher anatomic coverage, thinner slices, higher signal-to-noise ratio, shorter scan time, and lower eddy current artifacts [45,46]. The 3D UTE-Adiab-T1 ρ was previously shown to significantly correlate with microstructural and mechanical properties of the entheses, tendons, ligaments, and articular cartilage [26,28,29]. Nevertheless, the current study was the first to examine 3D UTE-Adiab-T1 ρ for in vivo entheses evaluation, and we have also demonstrated its potential for distinguishing between patients with PsA and asymptomatic volunteers. Unfortunately, in vivo, 3D UTE-Adiab-T1 ρ has not been reported in the literature for Achilles tendons and entheses in PsA disease to be compared with the current study.

Other qMRI techniques have been used before to evaluate the Achilles tendon and entheses involvement in the PsA setting. Chen et al. demonstrated higher resolution of enthesitis at the Achilles tendon in healthy volunteers and patients with PsA using 3D UTE-cones sequences, compared to gradient recalled echo (GRE) and fast spin echo (FSE) sequences [47]. Moazamian et al. highlighted the potential of UTE-T1 and UTE-MT modeling for quantitative evaluation of entheses and tendons in PsA patients by finding significantly higher UTE-T1 and lower MMF values in the entheses and tendons of PsA patients compared with asymptomatic volunteers [17].

This study had a few limitations. First, there were a relatively small number of participants in this study. Based on the standard deviation and observed effect size of \sim 0.5 in the investigated variables in this

preliminary study, we had \sim 60 % statistical power to detect a difference between the groups. Around 72 patients should be recruited for future research to have 80 % power in detecting the differences, a commonly used level in study designs. Second, although our statistical analysis shows that the MRI differences between the groups are mainly PsA related, an age-, gender-, and body-mass-index (BMI) matched comparison between PsA patients and the control group should be performed in a future study to examine this hypothesis systematically. Third, the increase in UTE-Adiab-T1 ρ values in the patient group may reflect differences in the macromolecule and water components of the entheses compared to the control group. To evaluate this hypothesis, biopsies would be required, which is one of the limitations of our study and can be addressed in future research. Fourth, individuals undergoing treatment for PsA were not compared with those prior to treatment. This likely undermined the achievable correlations with the clinical outcomes, such as the VAS. It is recommended that future research endeavors consider evaluating PsA patients before initiating treatment and after receiving interventions to comprehensively examine the sensitivity and specificity of the presented quantitative UTE MRI.

5. Conclusions

The 3D UTE-Adiab-T1 ρ was used in vivo for Achilles tendon and entheses evaluation and for distinguishing between patients with PsA and asymptomatic volunteers. Significantly higher UTE-Adiab-T1 ρ values were found in the entheses and tendons of PsA patients compared with an asymptomatic group. This study highlights the potential of 3D UTE-Adiab-T1 ρ for quantitative evaluation of entheses and tendons in PsA patients. The mechanisms underlying these relaxation differences should be investigated thoroughly in future studies.

CRedit authorship contribution statement

Dina Moazamian: Writing – review & editing, Writing – original draft, Visualization, Investigation, Formal analysis, Data curation, Conceptualization. **Hamidreza Shaterian Mohammadi:** Writing – review & editing, Writing – original draft, Visualization, Investigation, Data curation. **Jiyo Athertya:** Validation, Software, Data curation. **Mahyar Daskareh:** Formal analysis, Data curation. **Yajun Ma:** Validation, Software, Methodology, Investigation, Data curation, Conceptualization. **Monica Guma:** Writing – review & editing, Investigation. **Dana C. Covey:** Writing – review & editing, Investigation. **Tony Yaksh:** Writing – original draft, Investigation. **Abha Singh:** Writing – review & editing, Investigation. **Arthur Kavanaugh:** Writing – review & editing, Investigation, Validation. **Christine B. Chung:** Investigation, Conceptualization. **Jiang Du:** Investigation, Methodology, Conceptualization, Supervision. **Eric Y. Chang:** Investigation, Validation, Supervision, Conceptualization. **Saeed Jerban:** Writing – review & editing, Writing – original draft, Visualization, Validation, Supervision, Software, Resources, Methodology, Investigation, Data curation.

Declaration of competing interest

The authors declare that they have no known competing financial interests or personal relationships that could have appeared to influence the work reported in this paper.

Acknowledgments

The authors acknowledge grant support from the National Institutes of Health (R01AR075825, R01AR068987, R01AR062581, K01AR080257, 5P30AR073761, and R01AR078877) and Veterans Affairs (I01CX001388, 1I01BX005952, and I01CX000625).

References

- [1] A. Watad, R.J. Cuthbert, H. Amital, D. McGonagle, Enthesitis: much more than focal insertion point inflammation, *Curr. Rheumatol. Rep.* 20 (7) (2018) 41, <https://doi.org/10.1007/s11926-018-0751-3>.
- [2] R. Scarpa, A. Cuocolo, R. Peluso, et al., Early psoriatic arthritis: the clinical spectrum, *J. Rheumatol.* 35 (1) (2008) 137–141.
- [3] G. Schett, R.J. Lories, M.A. D'Agostino, D. Elewaut, B. Kirkham, E.R. Soriano, D. McGonagle, Enthesitis: from pathophysiology to treatment, *Nat Rev Rheumatol.* 13 (12) (2017) 731–741, <https://doi.org/10.1038/nrrheum.2017.188>.
- [4] E.G. Araujo, G. Schett, Enthesitis in psoriatic arthritis (Part 1): pathophysiology, *Rheumatol Oxf Engl.* 59 (Suppl 1) (2020) i10–i14, <https://doi.org/10.1093/rheumatology/keaa039>.
- [5] C. Perrin, Focal Synovial Inflammation Versus Enthesitis Theory in Distal Psoriatic Arthritis: A Pioneer Histopathologic Study, *Am J Dermatopathol.* 43 (12) (2021) 898–902, <https://doi.org/10.1097/DAD.0000000000001947>.
- [6] S. Jerban, Y. Ma, A. Kasibhatla, et al., Ultrashort echo time adiabatic T1 ρ (UTE-Adiab-T1 ρ) is sensitive to human cadaveric knee joint deformation induced by mechanical loading and unloading, *Magn Reson Imaging.* 80 (2021) 98–105, <https://doi.org/10.1016/j.mri.2021.04.014>.
- [7] A. Iagnocco, S. Antonio, M. Antonio, et al., Power Doppler ultrasonographic evaluation of enthesitis in psoriatic arthritis, A multi-center study, *Joint Bone Spine.* 79 (3) (2012) 324–325, <https://doi.org/10.1016/j.jbspin.2011.10.005>.
- [8] R.J. Hodgson, P.J. O'Connor, A.J. Grainger, Tendon and ligament imaging, *Br J Radiol.* 85 (1016) (2012) 1157–1172, <https://doi.org/10.1259/bjr/34786470>.
- [9] A. Watad, I. Eshed, D. McGonagle, Lessons learned from imaging on enthesitis in psoriatic arthritis, *Isr Med. Assoc. J. IMAJ.* 19 (11) (2017) 708–711.
- [10] R.J. Hodgson, N. Menon, A.J. Grainger, et al., Quantitative MRI measurements of the Achilles tendon in spondyloarthritis using ultrashort echo times, *Br J Radiol.* 85 (1015) (2012) e293–e299, <https://doi.org/10.1259/bjr/13555456>.
- [11] A.S. Kehl, M. Corr, M.H. Weisman, Review: Enthesitis: New Insights Into Pathogenesis, Diagnostic Modalities, and Treatment, *Arthritis Rheumatol.* 68 (2) (2016) 312–322, <https://doi.org/10.1002/art.39458>.
- [12] J. Du, A.J.T. Chiang, C.B. Chung, et al., Orientational analysis of the Achilles tendon and enthesitis using an ultrashort echo time spectroscopic imaging sequence, *Magn Reson Imaging.* 28 (2) (2010) 178–184, <https://doi.org/10.1016/j.mri.2009.06.002>.
- [13] V. Juras, S. Zbyn, C. Pressl, L. Valkovic, P. Szomolanyi, I. Frollo, S. Trattnig, Regional variations of T $_2^*$ in healthy and pathologic achilles tendon in vivo at 7 Tesla: Preliminary results, *Magn Reson Med.* 68 (2012) 1607–1613, <https://doi.org/10.1002/mrm.24136>.
- [14] J. Du, M. Carl, E. Diaz, et al., Ultrashort TE T1 ρ (UTE T1 ρ) imaging of the Achilles tendon and meniscus, *Magn Reson Med.* 64 (3) (2010) 834–842, <https://doi.org/10.1002/mrm.22474>.
- [15] Y.J. Ma, M. Carl, H. Shao, A.S. Tadros, E.Y. Chang, J. Du, Three-dimensional ultrashort echo time cones T1 ρ (3D UTE-cones-T1 ρ) imaging, *NMR Biomed.* 30 (6) (2017) <https://doi.org/10.1002/nbm.3709>.
- [16] M. Wu, Y.J. Ma, M. Liu, et al., Quantitative assessment of articular cartilage degeneration using 3D ultrashort echo time cones adiabatic T1 ρ (3D UTE-Cones-AdiabT1 ρ) imaging, *Eur. Radiol.* 32 (9) (2022) 6178–6186, <https://doi.org/10.1007/s00330-022-08722-6>.
- [17] D. Moazamian, J.S. Athertya, S. Dwek, et al., Achilles tendon and enthesitis assessment using ultrashort echo time magnetic resonance imaging (UTE-MRI) T1 and magnetization transfer (MT) modeling in psoriatic arthritis, *NMR Biomed.* 37 (1) (2024) e5040, <https://doi.org/10.1002/nbm.5040>.
- [18] Y.P. Xue, Y.J. Ma, M. Wu, et al., Quantitative 3D ultrashort echo time magnetization transfer imaging for evaluation of knee cartilage degeneration in vivo, *J. Magn. Reson Imaging JMRI.* 54 (4) (2021) 1294–1302, <https://doi.org/10.1002/jmri.27659>.
- [19] A.M. Afsahi, S. Sedaghat, D. Moazamian, G. Afsahi, J.S. Athertya, H. Jang, Y.J. Ma, Articular Cartilage Assessment Using Ultrashort Echo Time MRI: A Review, *Front Endocrinol (Lausanne)* 26 (13) (2022) 892961, <https://doi.org/10.3389/fendo.2022.892961>.
- [20] A.M. Afsahi, Y. Ma, H. Jang, S. Jerban, C.B. Chung, E.Y. Chang, J. Du, Ultrashort Echo Time Magnetic Resonance Imaging Techniques: Met and Unmet Needs in Musculoskeletal Imaging, *J. Magn. Reson. Imaging* 55 (6) (2022) 1597–1612, <https://doi.org/10.1002/jmri.28032>.
- [21] G.H. Filho, J. Du, B.C. Pak, et al., Quantitative characterization of the Achilles tendon in cadaveric specimens: T1 and T2* measurements using ultrashort-TE MRI at 3 T, *AJR Am J. Roentgenol.* 192 (3) (2009) W117–W124, <https://doi.org/10.2214/AJR.07.3990>.
- [22] B. Chen, Y. Zhao, X. Cheng, et al., Three-dimensional ultrashort echo time cones (3D UTE-Cones) magnetic resonance imaging of entheses and tendons, *Magn Reson Imaging.* 49 (2018) 4–9, <https://doi.org/10.1016/j.mri.2017.12.034>.
- [23] X. Li, E.T. Han, C.B. Ma, T.M. Link, D.C. Newitt, S. Majumdar, In vivo 3T spiral imaging based multi-slice T1 ρ mapping of knee cartilage in osteoarthritis, *Magn. Reson. Med.* 54 (4) (2005) 929–936, <https://doi.org/10.1002/mrm.20609>.
- [24] U. Duvvuri, R. Reddy, S.D. Patel, J.H. Kaufman, J.B. Kneeland, J.S. Leigh, T1 ρ -relaxation in articular cartilage: effects of enzymatic degradation, *Magn. Reson. Med.* 38 (6) (1997) 863–867, <https://doi.org/10.1002/mrm.1910380602>.
- [25] U. Duvvuri, S.R. Charagundla, S.B. Kudchodkar, J.H. Kaufman, J.B. Kneeland, R. Rizi, J.S. Leigh, R. Reddy, Human knee: in vivo T1(rho)-weighted MR imaging at 1.5 T—preliminary experience, *Radiology* 220 (3) (2001) 822–826, <https://doi.org/10.1148/radiol.2203001662>.
- [26] Y.J. Ma, M. Carl, A. Searleman, X. Lu, E.Y. Chang, J. Du, 3D adiabatic T1 ρ prepared ultrashort echo time cones sequence for whole knee imaging, *Magn. Reson. Med.* 80 (4) (2018) 1429–1439, <https://doi.org/10.1002/mrm.27131>.
- [27] X. Li, E.T. Han, C.B. Ma, T.M. Link, D.C. Newitt, S. Majumdar, In vivo 3T spiral imaging based multi-slice T1(rho) mapping of knee cartilage in osteoarthritis, *Magn. Reson. Med.* 54 (4) (2005) 929–936, <https://doi.org/10.1002/mrm.20609>.
- [28] X. Li, E.T. Han, R.F. Busse, S. Majumdar, In vivo T1(rho) mapping in cartilage using 3D magnetization-prepared angle-modulated partitioned k-space spoiled gradient echo snapshots (3D MAPSS), *Magn. Reson. Med.* 59 (2) (2008) 298–307, <https://doi.org/10.1002/mrm.21414>.
- [29] M.T. Löffler, Z. Akkaya, R. Bhattacharjee, T.M. Link, Biomarkers of cartilage composition, *Semin. Musculoskelet. Radiol.* 28 (1) (2024) 26–38, <https://doi.org/10.1055/s-0043-1776429>.
- [30] W. Tillett, L. Costa, D. Jadon, D. Wallis, C. Cavill, J. McHugh, E. Korendowych, N. McHugh, The CLASSification for Psoriatic ARthritis (CASPAR) criteria—a retrospective feasibility, sensitivity, and specificity study, *J. Rheumatol.* 39 (1) (2012) 154–156, <https://doi.org/10.3899/jrheum.110845>.
- [31] S.S. Farivar, W.E. Cunningham, R.D. Hays, Correlated physical and mental health summary scores for the SF-36 and SF-12 Health Survey, *Health Qual Life Outcomes.* 5 (1) (2007) 54, <https://doi.org/10.1186/1477-7525-5-54>.
- [32] S. Jerban, A.M. Afsahi, Y. Ma, et al., Correlations between elastic modulus and ultrashort echo time (UTE) adiabatic T1 ρ relaxation time (UTE-Adiab-T1 ρ) in Achilles tendons and entheses, *J. Biomech.* 160 (2023) 111825, <https://doi.org/10.1016/j.jbiomech.2023.111825>.
- [33] L. Barozzi, I. Olivieri, M. De Matteis, A. Padula, P. Pavlica, Seronegative spondylarthropathies: imaging of spondylitis, enthesitis and dactylitis, *Eur. J. Radiol.* 27 (1998) S12–S17, [https://doi.org/10.1016/S0720-048X\(98\)00037-0](https://doi.org/10.1016/S0720-048X(98)00037-0).
- [34] I. Eshed, M. Bollow, D.G. McGonagle, A.L. Tan, C.E. Althoff, P. Asbach, K. G. Herrmann, MRI of enthesitis of the appendicular skeleton in spondyloarthritis, *Ann. Rheum. Dis.* 66 (12) (2007) 1553–1559, <https://doi.org/10.1136/ard.2007.070243>.
- [35] D. McGonagle, H. Marzo-Ortega, P. O'Connor, W. Gibbon, C. Pease, R. Reece, P. Emery, The role of biomechanical factors and HLA-B27 in magnetic resonance imaging-determined bone changes in plantar fascia enthesopathy, *Arthritis Rheum.* 46 (2) (2002) 489–493, <https://doi.org/10.1002/art.10125>.
- [36] A.J. Mathew, M. Østergaard, Magnetic Resonance Imaging of Enthesitis in Spondyloarthritis, Including Psoriatic Arthritis-Status and Recent Advances, *Front Med. (Lausanne)* 30 (7) (2020) 296, <https://doi.org/10.3389/fmed.2020.00296>.
- [37] M. Benjamin, G.M. Bydder, Magnetic resonance imaging of entheses using ultrashort TE (UTE) pulse sequences, *J Magn Reson Imaging JMRI.* 25 (2) (2007) 381–389, <https://doi.org/10.1002/jmri.20825>.
- [38] A. Polachek, S. Li, V. Chandran, D.D. Gladman, Clinical enthesitis in a prospective longitudinal psoriatic arthritis cohort: incidence, prevalence, characteristics, and outcome, *Arthritis Care Res.* 69 (11) (2017) 1685–1691, <https://doi.org/10.1002/acr.23174>.
- [39] Malhi BS, Jang H, Malhi MS, Berry DB, Jerban S. *Frontiers | Tendon evaluation with ultrashort echo time (UTE) MRI: a systematic review.* doi:10.3389/fmscd.2024.1324050.
- [40] Cheng KY, Jerban S, Bae WC, Fliszar E, Chung CB. High-Field MRI Advantages and Applications in Rheumatology. *Radiol Clin North Am.* Published online May 19, 2024. doi:10.1016/j.rcl.2024.03.006.
- [41] H. Nishioka, J. Hirose, E. Nakamura, Y. Oniki, K. Takada, Y. Yamashita, H. Mizuta, T1 ρ and T2 mapping reveal the in vivo extracellular matrix of articular cartilage, *J. Magn. Reson. Imaging.* 35 (1) (2012) 147–155, <https://doi.org/10.1002/jmri.22811>.
- [42] B. Jobke, R. Bolbos, E. Saadat, J. Cheng, X. Li, S. Majumdar, Mechanism of disease in early osteoarthritis: application of modern MR imaging techniques – a technical report, *Magn. Reson Imaging* 31 (1) (2013) 156–161, <https://doi.org/10.1016/j.mri.2012.07.005>.
- [43] J. Du, S. Statum, R. Znamirovski, G.M. Bydder, C.B. Chung, Ultrashort TE T1 ρ magic angle imaging, *Magn. Reson. Med.* 69 (3) (2013) 682–687, <https://doi.org/10.1002/mrm.24296>.
- [44] H. Shao, C. Pauli, S. Li, Y. Ma, A.S. Tadros, A. Kavanaugh, E.Y. Chang, G. Tang, J. Du, Magic angle effect plays a major role in both T1 ρ and T2 relaxation in articular cartilage, *Osteoarthritis Cartilage* 25 (12) (2017) 2022–2030, <https://doi.org/10.1016/j.joca.2017.01.013>.
- [45] Y.J. Ma, E.Y. Chang, M. Carl, J. Du, Quantitative magnetization transfer ultrashort echo time imaging using a time-efficient 3D multislice Cones sequence, *Magn Reson Med.* 79 (2) (2018) 692–700, <https://doi.org/10.1002/mrm.26716>.
- [46] M. Carl, G.M. Bydder, J. Du, UTE imaging with simultaneous water and fat signal suppression using a time-efficient multislice inversion recovery pulse sequence, *Magn Reson Med.* 76 (2) (2016) 577–582, <https://doi.org/10.1002/mrm.25823>.
- [47] B. Chen, Y. Zhao, X. Cheng, Y. Ma, E.Y. Chang, A. Kavanaugh, S. Liu, J. Du, Three-dimensional ultrashort echo time cones (3D UTE-Cones) magnetic resonance imaging of entheses and tendons, *Magn Reson Imaging* 49 (2018) 4–9, <https://doi.org/10.1016/j.mri.2017.12.034>.