

UC San Diego

UC San Diego Previously Published Works

Title

Lateral Canthotomy and Cantholysis: Emergency Management of Orbital Compartment Syndrome

Permalink

<https://escholarship.org/uc/item/0zn3n1dd>

Journal

Journal of Emergency Medicine, 48(3)

ISSN

0736-4679

Authors

Rowh, Adam D
Ufberg, Jacob W
Chan, Theodore C
et al.

Publication Date

2015-03-01

DOI

10.1016/j.jemermed.2014.11.002

Peer reviewed

Case Presentations of the Harvard Affiliated Emergency Medicine Residencies



LATERAL CANTHOTOMY AND CANTHOLYSIS: EMERGENCY MANAGEMENT OF ORBITAL COMPARTMENT SYNDROME

Adam D. Rowh, MD,* Jacob W. Ufberg, MD,* Theodore C. Chan, MD,† Gary M. Vilke, MD,† and
Richard A. Harrigan, MD*

*Department of Emergency Medicine, Temple University School of Medicine, Philadelphia, Pennsylvania and †Department of Emergency
Medicine, University of California, San Diego, California

Reprint Address: Adam D. Rowh, MD, Department of Emergency Medicine, Temple University School of Medicine,
7043 McCallum St., Philadelphia, PA 19119

Abstract—Background: Orbital compartment syndrome is a sight-threatening emergency. Vision may be preserved when timely intervention is performed. **Objective:** To present a case of orbital compartment syndrome caused by traumatic retrobulbar hemorrhage and the procedure of lateral canthotomy and cantholysis, reviewed with photographic illustration. **Discussion:** Lateral canthotomy and cantholysis are readily performed at the bedside with simple instruments. The procedure may prevent irreversible blindness in cases of acute orbital compartment syndrome. **Conclusions:** Emergency physicians should be familiar with lateral canthotomy and cantholysis in the management of orbital compartment syndrome to minimize the chance of irreversible visual loss. © 2015 Elsevier Inc.

Keywords—lateral canthotomy; canthotomy; cantholysis; orbital compartment syndrome; retrobulbar hemorrhage; ocular trauma

INTRODUCTION

Facial and ocular trauma can result in retrobulbar hemorrhage, which can cause rapid vision loss that can be permanent if not aggressively managed. Significant hemorrhage in an enclosed orbital space may result in an orbital compartment syndrome (OCS). Resultant retinal ischemia produces rapid and irreversible visual loss. Although emergent ophthalmologic consultation and

intervention is ideal, often, emergency physicians will not have access to an ophthalmologist in the timeframe required to treat OCS arising from traumatic retrobulbar hemorrhage.

Lateral canthotomy and cantholysis (LCC) is a simple procedure, which, when performed expeditiously, can be vision saving (1–5). A case report is presented, followed by a review of the relevant anatomy, pathophysiology, technique, and potential complications of the procedure.

CASE REPORT

A 45-year-old man presented to the Emergency Department (ED) after being assaulted with a blunt object. He sustained multiple facial injuries, including a severe eye injury. He complained of decreased visual acuity and severe pain in the right eye. A grade IV (100%) hyphema and 360° subconjunctival hemorrhage were noted, together with proptosis and restricted extraocular movements (Figure 1).

As part of initial trauma management, an unenhanced computed tomography scan of the head was obtained, which demonstrated retrobulbar hemorrhage on the right side without evidence of globe rupture. Visual acuity testing revealed no light perception in the affected eye, and intraocular pressure (IOP) was measured to be 79 mm Hg. Ophthalmology was emergently consulted, but

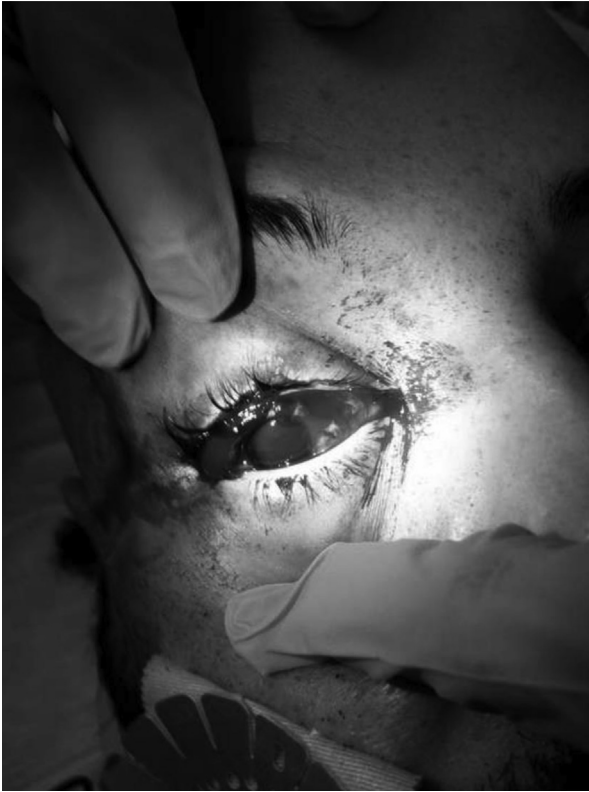

Figure 1. Gross appearance of the patient's eye after blunt trauma. There is marked soft tissue swelling, 100% (grade IV) hyphema, and 360° subconjunctival hemorrhage.

the physician was nearly 2 h away. The decision was made to proceed with emergent LCC.

After LCC, the patient's pain immediately improved and IOP decreased to 35 mm Hg. His ocular injuries were managed as an inpatient by Ophthalmology, and at time of discharge, he had regained a visual acuity of 20/40 in the affected eye.

DISCUSSION

Anatomy of the Relevant Orbital Structures

The articular edges of the eyelids form the palpebral fissure (the natural shape of the open eyelids). The canthi are the anatomic junctions of the upper and lower lids at the medial and lateral extremes of the palpebral fissure. Subcutaneously, the structure of each lid is formed by the tarsal plates, dense fibrous bands that run from medial bony orbit to lateral bony orbit (Figure 2). Posteriorly, each tarsus is attached to the conjunctiva. Together, the globe, the tarsal plates, and their insertions (fascial septae) form the anterior anatomic border of the orbit. The orbit is bounded posteriorly and on all sides by the bony skull (6). The volume of a normal adult orbit is approximately 30 mL (7).

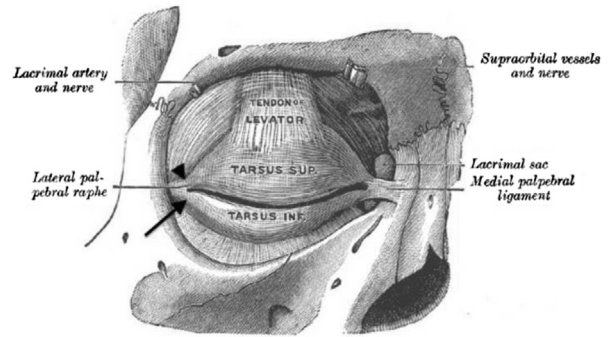


Figure 2. The fibrous tarsal plates, joining medially and laterally to form the canthal tendons, also known as palpebral ligaments (arrow, inferior crus of lateral canthal tendon; arrowhead, superior crus). Reproduced from *Gray's Anatomy*, public domain.

Laterally, the superior and inferior tarsal plates join to form the lateral canthal tendon, which inserts just posterior to the rim of the bony orbit at Whitnall's tubercle. This canthal tendon is distinct from the fascial orbital septum, which is located more superficially (8).

Arterial circulation to the eye is via the ophthalmic artery and its branches, which arises from the internal carotid. Venous drainage is into the ophthalmic veins, which merge and join the cavernous sinus, the pterygoid plexus, and the facial vein (9).

Pathophysiology of Orbital Compartment Syndrome

Normal intraorbital pressure is 3–6 mm Hg (10,11). Normal intraocular pressure is 10–20 mm Hg (12). Blunt trauma to the face or globe can cause bleeding in the retrobulbar space, which quickly causes an increase in retrobulbar pressure due to the lack of distensibility of the surrounding structures. Retinal ischemia results, and vision loss can be permanent after as little as 60–100 min of ischemia (13). Arterial blood flow has been demonstrated to cease at tissue pressures significantly lower than diastolic blood pressure (14,15). When the vasa nervorum are affected by increased intraorbital pressure, optic nerve ischemia will result. When the central retinal artery is affected by increased intraocular pressure, retinal ischemia will result. The orbit lacks lymphatic drainage, so the only drainage is via the compressible ophthalmic veins (7). As little as 7 mL of fluid experimentally injected into the orbit can produce persistent retinal changes (16).

Although trauma is the most common etiology of acute OCS among ED patients, other causes may include orbital cellulitis/abscess, tumor, spontaneous hemorrhage, massive fluid resuscitation, or prolonged hypoxemia (7,17).

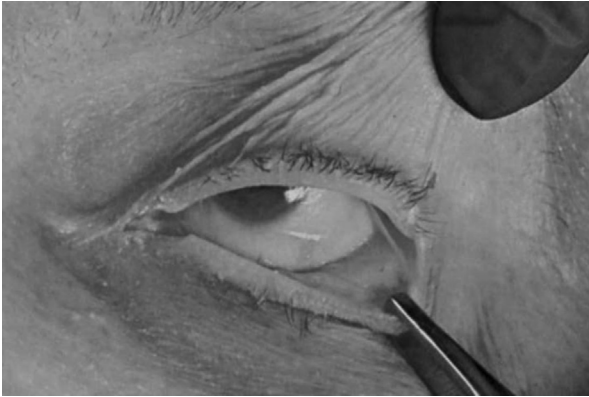

Figure 3. Normal anatomy of the lateral canthus. With forceps distracting the lower lid, the reflection of the conjunctiva is visible.

Indications for Emergent Lateral Canthotomy and Cantholysis

Emergent LCC is indicated when retrobulbar hemorrhage is accompanied by symptoms including proptosis, elevated IOP, decreased visual acuity, an afferent pupillary defect (Marcus-Gunn pupil), or restricted extraocular movements. Due to the risk of rapidly progressive and irreversible vision loss, OCS is a clinical diagnosis, and treatment should not be delayed by imaging or other diagnostics (7). When IOP measurement is available, a value of 40 mm Hg is typically considered the threshold above which emergent intervention is indicated (18). In patients with periorbital injury who are unconscious or unable to participate with physical examination, an IOP > 40 mm Hg is sufficient indication to perform LCC (19). Globe rupture (suggested by enophthalmos rather than proptosis) is a contraindication to bedside decompression.

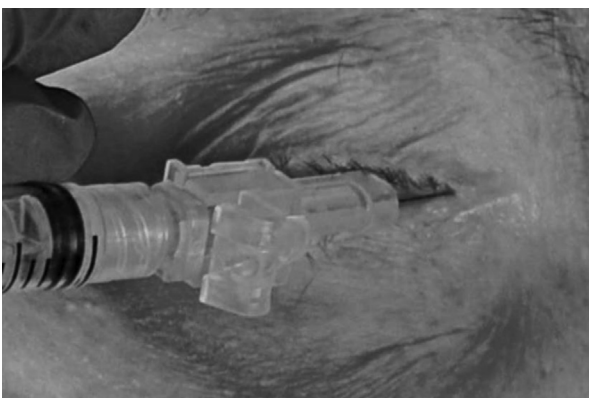


Figure 4. Injection of local anesthetic into the skin of the lateral canthus. Note the orientation of the needle away from the globe. Less than 1 cc of anesthetic is necessary, as the anatomic structures are small and potentially distorted by excessive fluid infiltration.

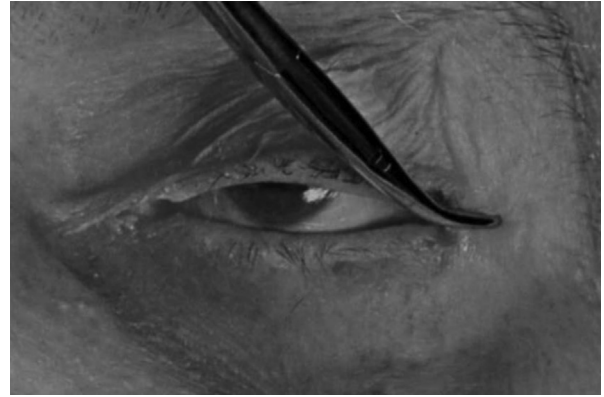


Figure 5. Application of a hemostat to the skin of the lateral canthus. This isolates and crushes the skin, resulting in a relative devascularization of the area to be incised. This step is more important in cases where greater swelling and tissue distortion is present due to the inciting injury.

Technique

Because of its superficial location and the relative distance of its inferior crus from other anatomic structures (such as the lacrimal apparatus), the lateral canthal tendon is the preferred anatomic target for emergent bedside orbital decompression. Division of the inferior crus of the lateral canthal tendon separates the inferior tarsal plate from the lateral bony orbit. The lower lid becomes lax and allows anterior-inferior displacement of the globe from its normal position, thereby increasing the volume of the orbit and relieving the pressure therein.

The area around the lateral canthus is cleaned using irrigation with normal saline and draped (20). True sterile prep is often impractical due to time pressure and the dirty nature of most wounds, but the skin may be cleaned with chlorhexidine or a similar solution while avoiding chemical injury to the globe. The initial landmarks are carefully identified (Figure 3).

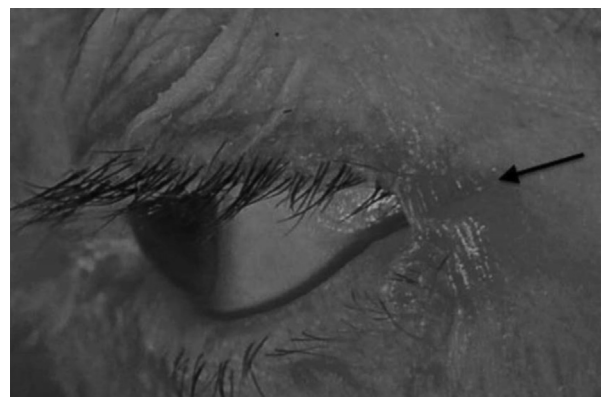


Figure 6. After application of the hemostat, the canthal skin is crushed and the landmark for canthotomy is highlighted (arrow).



Figure 7. Scissors are inserted carefully along the internal aspect of the lateral canthus, with the points being directed away from the globe. In this position, the skin and conjunctiva of the lateral canthus can be divided while minimizing the risk of iatrogenic globe injury. The incision should extend to the rim of the bony orbit.

The skin of the lateral canthus is infiltrated with a small amount (1–2 mL) of 1% lidocaine with 1:100,000 epinephrine (Figure 4).

Next, a hemostat is applied to the canthus for 30 to 60 s to crush and devascularize the skin (Figures 5 and 6).

Sterile scissors are used to incise the canthus (canthotomy). The incision is approximately 1 cm long and is directed toward the lateral bony orbital rim (Figure 7). This will divide the skin, fascial septum, orbicularis oculi muscle, and conjunctiva (Figure 8). Care is taken to direct the instrument laterally and superficially to avoid iatrogenic globe injury. Swelling may be extreme, and undue haste can compound the patient's injuries.

The canthotomy itself is not therapeutic; it only serves to expose the canthal tendon, which must be divided to release the retrobulbar pressure. When the canthotomy exposes the orbital rim, palpation identifies the lateral




Figure 8. After lateral canthotomy, the skin and conjunctiva are divided, revealing orbital fat (arrowhead). At this stage, no significant increase in the laxity of the eyelid will be achieved, but the canthal tendon can be identified (arrow).

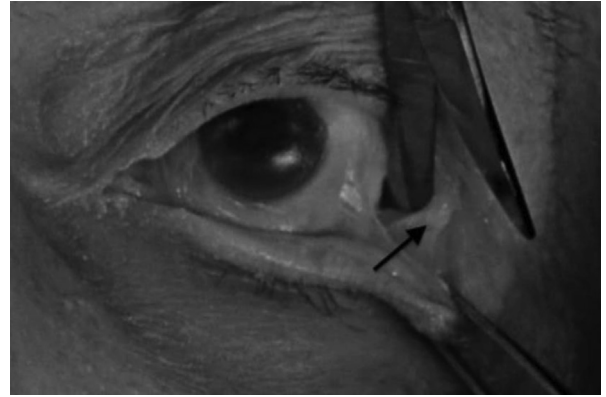


Figure 9. With distraction of the lower lid, the inferior crus of the canthal tendon is isolated (arrow). Again, great care is taken to direct the point of the scissors away from the globe.

canthal tendon near its insertion. A metal instrument may aid in identification of the superior crus and inferior crus, especially if visual landmarks are distorted. Inferior retraction of the lower lid by an assistant can facilitate the procedure.

The second step uses sharp scissors to divide the inferior crus of the lateral canthal tendon. The instrument is directed inferiorly and laterally, away from the globe. This incision is approximately 1 cm long, toward the inferolateral orbital rim (Figure 9). Upon division of the tendon, the globe and lower lid will displace anteriorly and inferiorly (Figure 10).

Invoking the mnemonic “one is the number” may be helpful when performing this uncommon but important procedure: use about 1 cc of 1% lidocaine with epinephrine to infiltrate; use the hemostats for about 1 min to devitalize the skin at the lateral canthus before making a 1-cm incision (the lateral canthotomy) to expose the one structure you want to incise *first*, again with a 1-cm

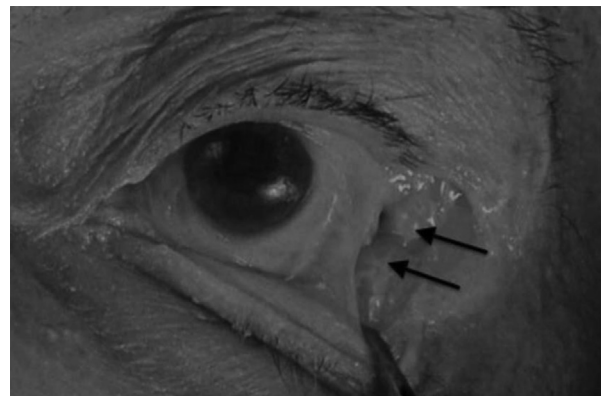


Figure 10. After cantholysis. Now the lateral attachment of the lower eyelid is divided (arrows, cut edges). The fibrous tarsal plate within the eyelid, which forms the anterior border of the orbit, can be mobilized. This is the step that increases the volume of the orbit and thereby decreases its pressure.

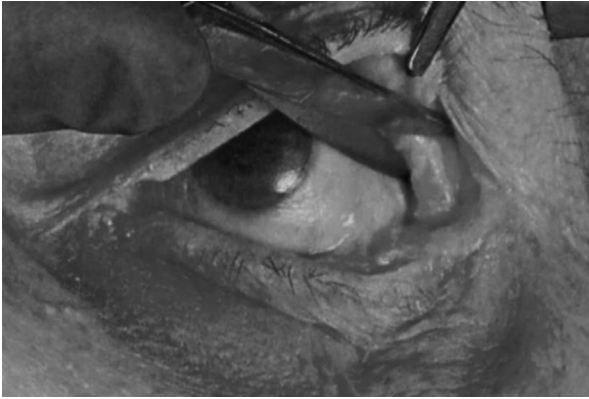


Figure 11. If further intervention is required, the superior crus of the canthal tendon may be isolated and divided in the same manner as the inferior crus.

incision: the inferior crus of the lateral canthal tendon (the inferior cantholysis).

At this point, the operator should reassess the patient. Rapid improvement in symptoms should occur, and IOP should decrease as well. The goals of the procedure are a return of visual acuity and an IOP < 40 mm Hg. Physical findings such as proptosis and extraocular motions will be less reliable after a successful LCC. The afferent pupillary defect, however, should resolve as circulation returns to the optic nerve and retina.

If release of the retrobulbar pressure is deemed incomplete, whether by lack of symptom improvement or by elevated repeat IOP measurement, the operator should confirm the adequacy of the superficial dissection and inferior cantholysis. The inferior crus may again be approached. Or, if complete inferior cantholysis is assured, division of the superior crus of the lateral canthal tendon should proceed.

When dividing the superior crus, the instrument is directed superiorly and laterally, again away from the globe and toward the bony orbital rim (Figure 11).

Successful division of the superior crus should allow laxity of both eyelids and even greater mobility of the globe (Figure 12). Extra care should be taken when dividing the superior crus, as it lies in close proximity to the lacrimal gland.

Pitfalls and Complications

The most common pitfalls for inexperienced operators are failure to fully expose the canthal tendon and failure to fully divide it. As long as the instruments are directed toward the orbital rim, tangential to the globe surface, accidental injury to extraocular muscles or other major structures is unlikely. Incomplete canthal release, however, serves no therapeutic purpose.

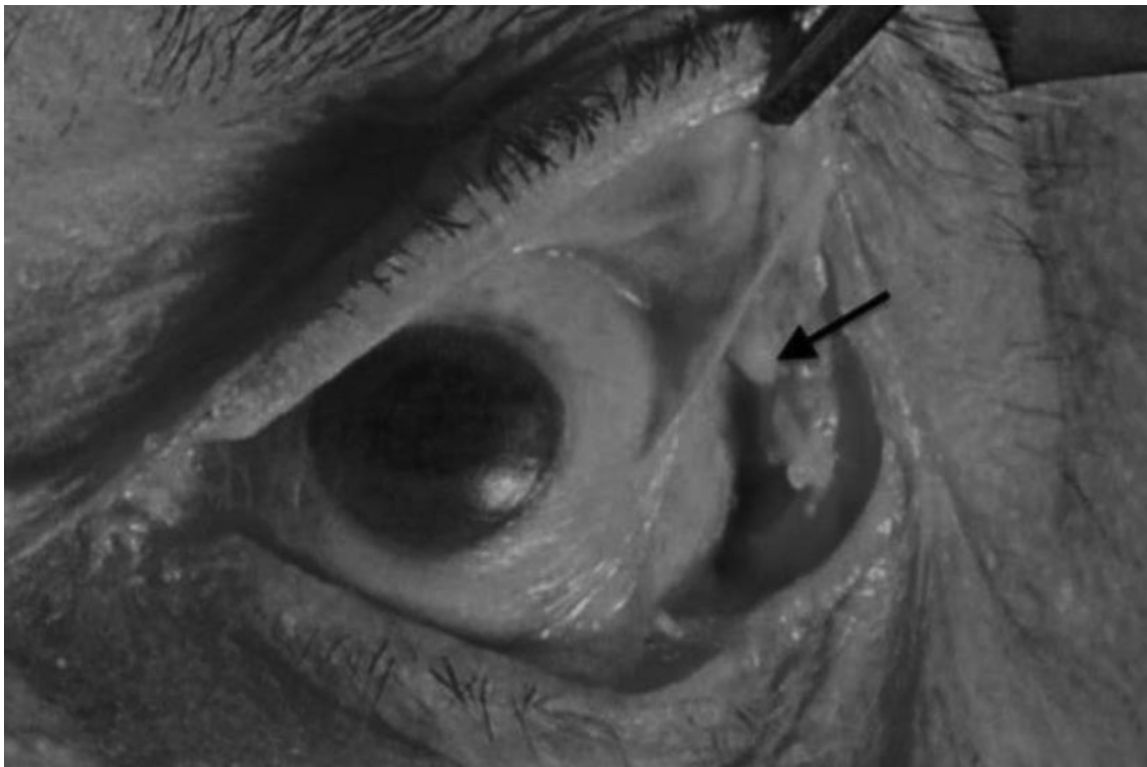


Figure 12. After canthotomy, inferior cantholysis, and superior cantholysis (arrow, cut edge of superior crus). Both eyelids are disconnected from their lateral attachments to the bony orbit, and the maximum decompression of the orbit is achieved.

The principal anticipated immediate complication of emergent canthotomy and cantholysis is iatrogenic globe injury. Since portions of the procedure are performed blindly, care must be taken to direct all instruments laterally, toward the orbital edge.

Delayed complications, such as infection, functional impairment, and cosmetic deformity, are all effectively managed after the acute sight-threatening emergency has been resolved. Spontaneous healing is the norm, and delayed surgical repair of the canthotomy is not indicated or performed. Emergent ophthalmologic consultation should occur, even if the procedure is performed by the emergency physician. There exists an inherent trade-off between the risks and benefits of any emergent procedure; in this case, prevention of irreversible visual loss is considered to take priority over the potential complications of LCC.

CONCLUSION

Retrolbulbar hemorrhage can cause orbital compartment syndrome, a time-sensitive and sight-threatening emergency. Orbital decompression via lateral canthotomy and cantholysis is the treatment of choice and can be readily performed at the bedside by the emergency physician, without specialized equipment.

Acknowledgments—For assistance with photography, we thank Dr. Brett A Oxberry and Victor Thompson, Department of Anatomy and Cell Biology, Temple University School of Medicine.

REFERENCES

- Bord SP, Linden J. Trauma to the globe and orbit. *Emerg Med Clin North Am* 2008;26:97–123. vi–vii.
- McInnis G, Howes D. Lateral canthotomy and cantholysis: a simple, vision-saving procedure. *CJEM* 2002;4:49–52.
- Vassallo S, Hartstein M, Howard D, Stetz J. Traumatic retrobulbar hemorrhage: emergent decompression by lateral canthotomy and cantholysis. *J Emerg Med* 2002;22:251–6.
- Ballard SR, Enzenauer RW, O'Donnell T, Fleming JC, Risk G, Waite AN. Emergency lateral canthotomy and cantholysis: a simple procedure to preserve vision from sight threatening orbital hemorrhage. *J Spec Oper Med* 2009;9:26–32.
- Katz B, Herschler J, Brick D. Orbital haemorrhage and prolonged blindness: a treatable posterior optic neuropathy. *Br J Ophthalmol* 1983;67:549–53.
- Whitnall SE. On a tubercle on the malar bone, and on the lateral attachments of the tarsal plates. *J Anat Physiol* 1911;45:426–32.
- Lima V, Burt B, Leibovitch I, Prabhakaran V, Goldberg RA, Selva D. Orbital compartment syndrome: the ophthalmic surgical emergency. *Surv Ophthalmol* 2009;54:441–9.
- Gioia V, Linberg J, McCormick S. The anatomy of the lateral canthal tendon. *Arch Ophthalmol* 1987;105:529–32.
- Kiel J. The ocular circulation. San Rafael, CA: University of Texas Health Science Center at San Antonio, Morgan & Claypool Life Sciences; 2010.
- Kratky V, Hurwitz JJ, Avram DR. Orbital compartment syndrome. Direct measurement of orbital tissue pressure: 1. Technique. *Can J Ophthalmol* 1990;25:293–7.
- Riemann CD, Foster JA, Kosmorsky GS. Direct orbital manometry in patients with thyroid-associated orbitopathy. *Ophthalmology* 1999;106:1296–302.
- Gerstenblith A, Rabinowitz M. *Wills eye manual: office and emergency room diagnosis and treatment of eye disease*. 6th edn. Philadelphia: Lippincott Williams & Wilkins; 2012.
- Hayreh SS, Kolder WE, Weingeist TA. Central retinal artery occlusion and retinal tolerance time. *Ophthalmology* 1980;87:75–8.
- Ashton H. The effect of increased tissue pressure on blood flow. *Clin Orthop Relat Res* 1975;113:15–26.
- Matsen FA 3rd. Compartmental syndrome: a unified concept. *Clin Orthop Relat Res* 1975;8–14.
- Akar Y, Apaydin KC, Ozel A. Acute orbital effects of retrobulbar injection on optic nerve head topography. *Br J Ophthalmol* 2004; 88:1573–6.
- Prodhan P, Noviski NN, Butler WE, Eskandar E, Ellen Grant P, Whalen MJ. Orbital compartment syndrome mimicking cerebral herniation in a 12-yr-old boy with severe traumatic asphyxia. *Pediatr Crit Care Med* 2003;4:367–9.
- Samples JR, Hedges JR. Ophthalmologic procedures. In: Roberts JR, Hedges JR, eds. *Clinical procedures in emergency medicine*. 3rd edn. Philadelphia: W.B. Saunders Co; 1998:1089–119.
- Lubeck D. Penetrating ocular injuries. *Emerg Med Clin North Am* 1988;6:127–46.
- Albert D, Jakobiec F. *Principles and practice of ophthalmology*. Portland, OR: WB Saunders Company; 2000.