

UCLA

Proceedings of UCLA Health

Title

Tracheal Tumors: An Uncommon Cause for the Common Symptom of Cough

Permalink

<https://escholarship.org/uc/item/0z6272hp>

Journal

Proceedings of UCLA Health, 21(1)

Author

Wong, Brian K.

Publication Date

2017-11-07

CLINICAL VIGNETTE

Tracheal Tumors: An Uncommon Cause for the Common Symptom of Cough

Brian K. Wong, M.D.

Case

The patient is a 47-year-old school nurse referred for persistent cough. She developed initial symptoms of low-grade fever, sputum production, and persistent cough approximately 3 months prior to evaluation. Initial therapy prescribed at an urgent care clinic consisted of antibiotics, albuterol inhaler, and prednisone 20 mg daily for 5 days. Her symptoms improved with resolution of sputum production and cough but returned a few days after completion of therapy. An additional course of antibiotics and higher dose prednisone regimen was initiated, which improved but did not eliminate her cough. The patient is a lifelong nonsmoker and takes no prescription medications. She denied recent travel but was born and raised in the Phoenix, Arizona area.

Physical examination was notable for only mild prolongation of expiratory phase on lung auscultation. There was no stridor discerned. Cardiac examination was unremarkable. Spirometry was normal. Flow volume loop revealed no evidence of fixed airway obstruction.

Chest radiograph taken at urgent care was normal. Non-contrast CT scan of the chest taken on initial consultation revealed several small 2 mm micro nodules. There was one calcified micro nodule compatible with granuloma. At the level of the carina and posterior wall of the trachea was a 0.6x0.5x0.9 cm polypoid appearing lesion. No adenopathy was visualized. Laboratory evaluation including CBC and metabolic panels were normal. MTB Quantiferon assay and coccidioidomycosis antibody serology were both negative. PET imaging showed no evidence of hypermetabolic activity.

Diagnostic bronchoscopy was performed, which revealed an ulcerated polypoid lesion at the level of the orifice of the left mainstem bronchus (Figure 1). Biopsy showed benign respiratory mucosa with focal ulceration and granulation tissue with reactive atypia. There was no evidence of malignancy.

The patient was referred to interventional pulmonology and underwent successful multimodality tumor excision with electrocautery, contact cryotherapy, and argon plasma coagulation. Pathology revealed inflammatory myofibroblast tumor. The patient is currently awaiting definitive treatment recommendations.

Discussion

Primary neoplasm involving the trachea is very rare with a reported annual incidence of 0.1 per 100,000 with tracheal cancers representing less than 0.05 percent of all malignant tumors of the lung.¹ The most common cancer was squamous cell in up to two thirds of the cases, followed by adenoid cystic carcinomas with less than ten percent.² Inflammatory myofibroblast tumors are very rare in adults, although they represent one of the most common lung tumors in the pediatric population with a frequency of 0.04%-0.07%.³ Tracheal involvement is extremely rare. One study reviewed 90 uncommon tracheal tumors retrospectively over 44 years and reported one case.⁴

Clinical presentation with primary tumors of the trachea are usually of insidious onset and usually do not occur until the lesion is at least 50% of the lumen diameter.⁵ In a series of 329 patients, dyspnea was the most prevalent symptom (71%), with cough (40%), hemoptysis (34%), and asthma (19%) seen less frequently.⁶ Similar symptoms can be found in more common diagnosis such as asthma, which can cause a delay in diagnosis up to 2.5 months in one study, with employment of multiple inhaled bronchodilators and oral corticosteroids.⁶

Plain chest radiographs are almost always normal, often causing a delay in diagnosis.⁶ Chest CT with multiplanar reconstruction is the best method of imaging tracheal lesions and is usually obtained most often in patients not responding to bronchodilators or who present with hemoptysis.⁷ Positron emission tomography PET/CT, which is useful for staging lung cancer has very limited data for primary tracheal tumors.⁷ Flow volume loops can demonstrate flattening of either the inspiratory or expiratory loop, indicative of extrathoracic, or intrathoracic airway obstruction. This is relatively insensitive as lesions must reduce the tracheal area by 80 percent before abnormalities can be detected.⁸

Bronchoscopy is the diagnostic procedure of choice as it may provide tissue specimens for diagnosis, as well as providing precise assessment of the airway. Due to the possibility of significant airway compromise, it should be performed under carefully controlled circumstances with consultations with anesthesia and interventional pulmonology.⁹

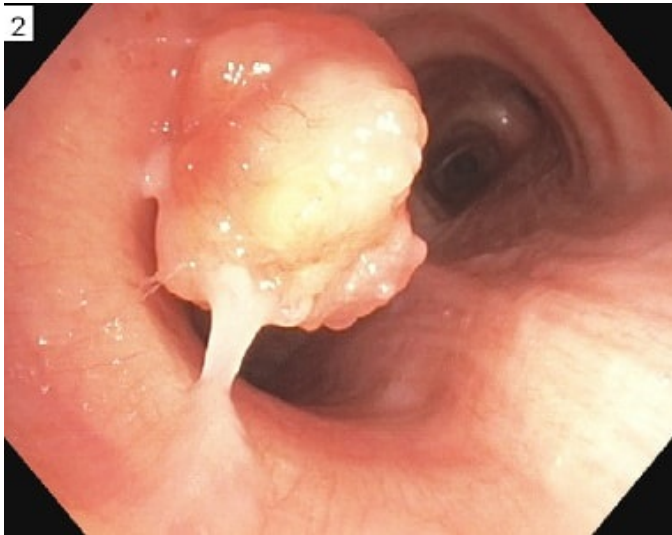
Surgical resection when feasible remains the treatment of choice to prevent recurrence as well as local or distant

metastasis. Studies suggest 50-75 percent of patients with tracheal tumors are potentially resectable.¹⁰ Radiation therapy and chemotherapy can be given after surgery. In our case of inflammatory myofibroblastic tumor, immunohistochemistry staining was positive for anaplastic lymphoma kinase (ALK). A new potential therapy uses a competitive inhibitor of ALK and crizotinib and may be useful in nonresectable cases.¹¹

In summary, primary tracheal tumors, although uncommon, must be considered in the patient with common symptoms of dyspnea, cough, and wheezing that do not respond to standard therapeutic intervention.

Figures and Images

Figure 1. Diagnostic bronchoscopy was performed, which revealed an ulcerated polypoid lesion at the level of the orifice of the left mainstem bronchus



REFERENCES

1. **Urdaneta AI, Yu JB, Wilson LD.** Population based cancer registry analysis of primary tracheal carcinoma. *Am J Clin Oncol.* 2011 Feb;34(1):32-7. doi: 10.1097/COC.0b013e3181cae8ab. PubMed PMID: 20087156.
2. **Grillo HC, Mathisen DJ.** Primary tracheal tumors: treatment and results. *Ann Thorac Surg.* 1990 Jan;49(1):69-77. PubMed PMID: 2153371.
3. **Özgül MA, Toru Ü, Acat M, Özgül G, Çetinkaya E, Dinçer HE, Omaygenç DÖ, Ürer HN.** A rare tumor of trachea: Inflammatory myofibroblastic tumor diagnosis and endoscopic treatment. *Respir Med Case Rep.* 2014 Nov 5;13:57-60. doi:10.1016/j.rmcr.2014.10.001. eCollection 2014. PubMed PMID: 26029563; PubMed Central PMCID: PMC4246357.
4. **Gaissert HA, Grillo HC, Shadmehr MB, Wright CD, Gokhale M, Wain JC, Mathisen DJ.** Uncommon primary tracheal tumors. *Ann Thorac Surg.* 2006 Jul;82(1):268-72; discussion 272-3. PubMed PMID: 16798228.
5. **Brand-Saberi BE, Schäfer T.** Trachea: anatomy and physiology. *Thorac Surg Clin.* 2014 Feb;24(1):1-5. doi: 10.1016/j.thorsurg.2013.09.004. Epub 2013 Nov 9. Review. PubMed PMID: 24295654.
6. **Bhattacharyya N.** Contemporary staging and prognosis for primary tracheal malignancies: a population-based analysis. *Otolaryngol Head Neck Surg.* 2004 Nov;131(5):639-42. PubMed PMID: 15523440.
7. **Park CM, Goo JM, Lee HJ, Kim MA, Lee CH, Kang MJ.** Tumors in the tracheobronchial tree: CT and FDG PET features. *Radiographics.* 2009 Jan-Feb;29(1):55-71. doi: 10.1148/rg.291085126. PubMed PMID: 19168836.
8. **Miller RD, Hyatt RE.** Obstructing lesions of the larynx and trachea: clinical and physiologic characteristics. *Mayo Clin Proc.* 1969 Mar;44(3):145-61. PubMed PMID: 5776050.
9. **Ding YF, Chen L, Huang HD, Dong YC, Yao XP, Huang Y, Wang Q, Zhang W, Li Q, Bai C.** [Clinical analysis of therapeutic bronchoscopy for tracheal neoplasm]. *Zhonghua Jie He He Hu Xi Za Zhi.* 2017 Jun 12;40(6):435-439. doi: 10.3760/cma.j.issn.1001-0939.2017.06.008. Chinese. PubMed PMID: 28592026.
10. **Honings J, Gaissert HA, Verhagen AF, van Dijck JA, van der Heijden HF, van Die L, Bussink J, Kaanders JH, Marres HA.** Undertreatment of tracheal carcinoma: multidisciplinary audit of epidemiologic data. *Ann Surg Oncol.* 2009 Feb;16(2):246-53. doi: 10.1245/s10434-008-0241-3. Epub 2008 Nov 27. PubMed PMID: 19037701.
11. **Butrynski JE, D'Adamo DR, Hornick JL, Dal Cin P, Antonescu CR, Jhanwar SC, Ladanyi M, Capelletti M, Rodig SJ, Ramaiya N, Kwak EL, Clark JW, Wilner KD, Christensen JG, Jänne PA, Maki RG, Demetri GD, Shapiro GI.** Crizotinib in ALK-rearranged inflammatory myofibroblastic tumor. *N Engl J Med.* 2010 Oct 28;363(18):1727-33. doi: 10.1056/NEJMoa1007056. PubMed PMID: 20979472; PubMed Central PMCID: PMC3014292.

Submitted November 7, 2017