

UC Davis

Dermatology Online Journal

Title

An unusual presentation of seborrheic keratoses in a man with hereditary hemochromatosis

Permalink

<https://escholarship.org/uc/item/0xn124r8>

Journal

Dermatology Online Journal, 23(4)

Authors

Loh, Tiffany Y
Cohen, Philip R

Publication Date

2017

DOI

10.5070/D3234034630

Copyright Information

Copyright 2017 by the author(s). This work is made available under the terms of a Creative Commons Attribution-NonCommercial-NoDerivatives License, available at <https://creativecommons.org/licenses/by-nc-nd/4.0/>

Peer reviewed

An unusual presentation of seborrheic keratoses in a man with hereditary hemochromatosis

Tiffany Y Loh¹ BS, Philip R Cohen² MD

Affiliations: ¹School of Medicine, University of California San Diego, La Jolla, California, ²Department of Dermatology, University of California San Diego, La Jolla, California

Corresponding Author: Tiffany Y Loh, BS, 7608-53 Palmilla Drive, San Diego, CA 92122, Email: tiffany.yv.loh@gmail.com

Abstract

Hereditary hemochromatosis is an autosomal recessive disorder that disturbs iron metabolism and results in iron deposition throughout the body. Iron accumulation in various organs may cause a wide range of systemic symptoms and cutaneous manifestations of the disease are particularly striking. Classically, hereditary hemochromatosis has been termed “bronze diabetes.” Although diffuse hyperpigmentation is a well-described feature of this disease, other cutaneous symptoms may also occur, and a variety of anomalies may be observed. We present a case of long-standing hereditary hemochromatosis associated with hypopigmented plaques, which were found to be seborrheic keratoses on histologic examination. The cutaneous findings in hereditary hemochromatosis are summarized and an unusual case of seborrheic keratosis manifesting as hypopigmented plaques in a man with hereditary hemochromatosis is described. PubMed was used to search the following terms: hemochromatosis, hereditary, hyperpigmentation, hypopigmentation, keratosis, melanin, seborrheic, siderosis. Despite the generalized hyperpigmentation that is usually observed in hereditary hemochromatosis, seborrheic keratosis may present rarely as hypopigmented lesions in individuals affected by this disease. Therefore, seborrheic keratoses should be considered in the differential diagnosis in hemochromatosis patients who present with uncharacteristic pigmentation changes.

Keywords: hemochromatosis, hereditary, hyperpigmentation, hypopigmentation, keratosis, melanin, seborrheic, siderosis

Introduction

Hereditary hemochromatosis is an autosomal recessive disease that interferes with iron storage in the body [1]. Most cases are caused by mutations in the gene for human hemochromatosis protein (HFE), which is responsible for regulating circulating iron levels; disruption of this process results in excessive iron deposition in various organs and tissues [1-3]. Clinically, a wide variety of systemic effects may be observed. The classic triad of symptoms often described in hemochromatosis consists of cirrhosis, diabetes mellitus, and skin hyperpigmentation [4, 5]. The cutaneous features of this disease are striking and there may be extensive variation among affected individuals. We present an unusual case in which a patient developed multiple hypopigmented plaques in the setting of diffuse hyperpigmentation from hereditary hemochromatosis.

Case Synopsis

The patient was a 61-year-old man with hereditary hemochromatosis that was diagnosed 20 years earlier. The patient noticed the white lesions on his back and was concerned since they had not been previously present. As an avid swimmer who swam outside daily, he was concerned about skin cancer. On physical examination, he was found to have several flesh-colored to hypopigmented plaques on his back during routine skin examination. The patient had diffuse hyperpigmentation of the face, upper

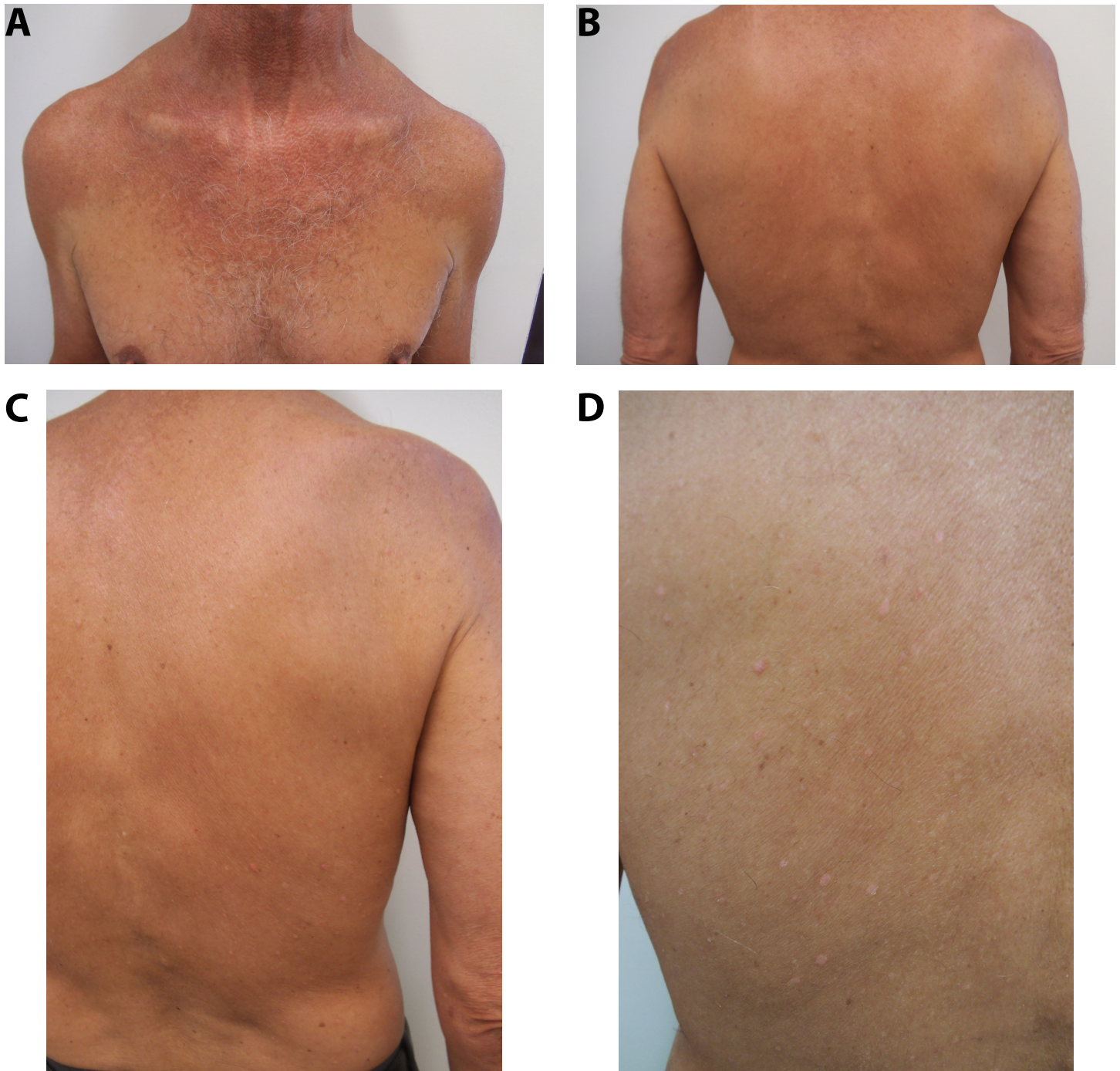


Figure 1. Hereditary hemochromatosis in a 61-year-old man manifesting as diffuse hyperpigmentation of the upper chest, upper back, proximal arms, and legs from the mid-thigh to ankle bilaterally (A, B, and C). Several flesh-colored to hypopigmented papules are also present on the back (B, C, and D).

chest and back, proximal arms, and legs from the mid-thigh to ankle bilaterally (**Figure 1**).

The hypopigmented plaques on his back were located within the area of hyperpigmentation and the patient endorsed having them for many years (**Figure 1**). He denied pruritus, bleeding, or any other associated symptoms. Biopsy samples were obtained from areas of the skin showing hyperpigmentation

(**Figure 2**), uninvolved (normal appearing) skin (**Figure 3**), and the white plaques on the back (**Figure 4**). The hyperpigmented skin shows increased melanin in the basal layer of the epidermis; a Perl's iron stain was negative for hemosiderin (**Figure 2**). In contrast, the non-pigmented normal-appearing skin shows benign-appearing epidermis and dermis, with a normal amount of pigmentation (**Figure 3**).

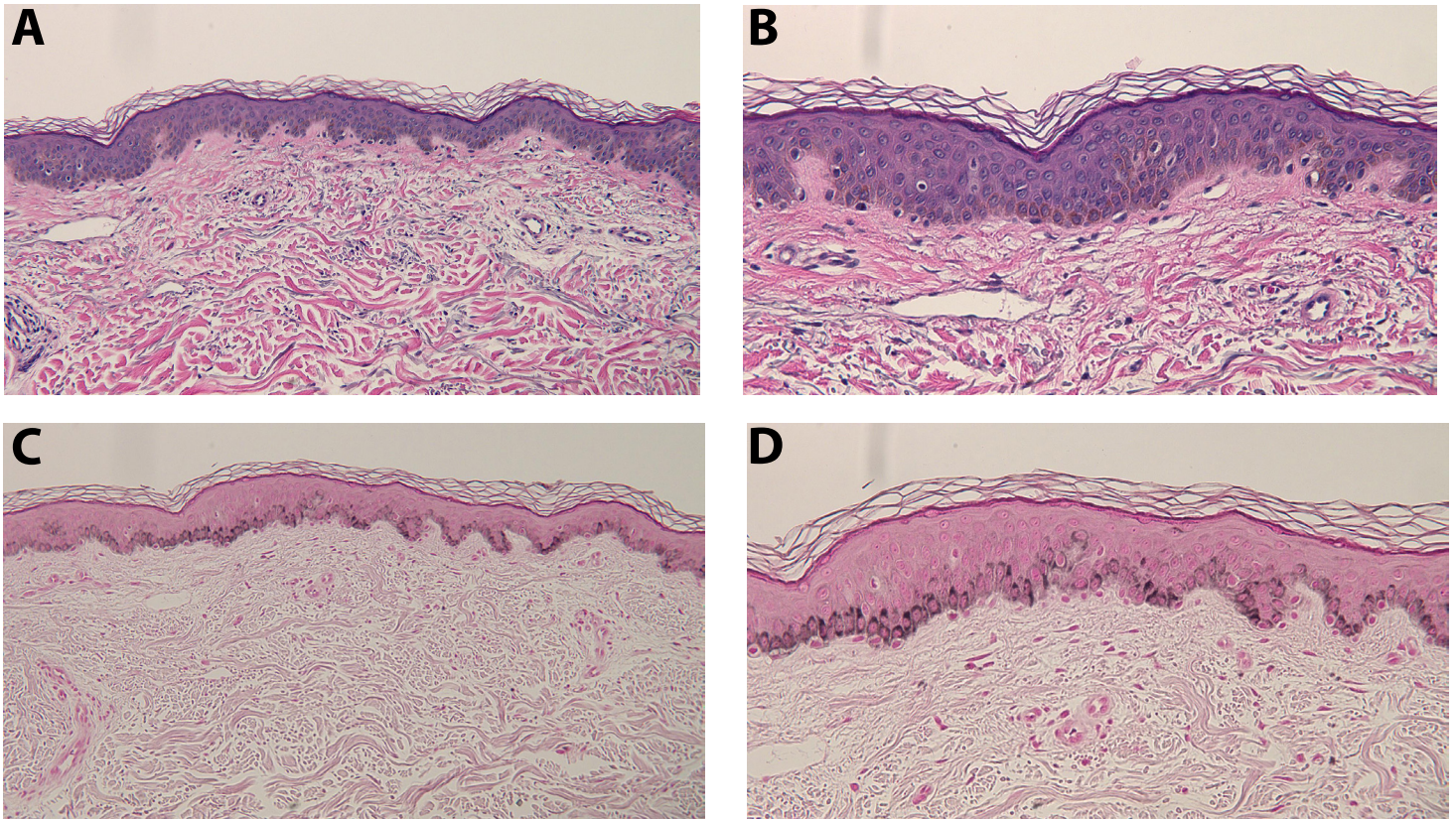


Figure 2. The patient's left anterior deltoid area, which shows hyperpigmentation, was biopsied. Hyperpigmentation of the basilar layer seen on hematoxylin and eosin stained sections (A and B). The Fontana Masson stain (C and D) highlights the increased melanin in the basal layer of the epidermis (H&E: A, 4x; B, 10x; Fontana Masson: C, 4x; D, 10x).

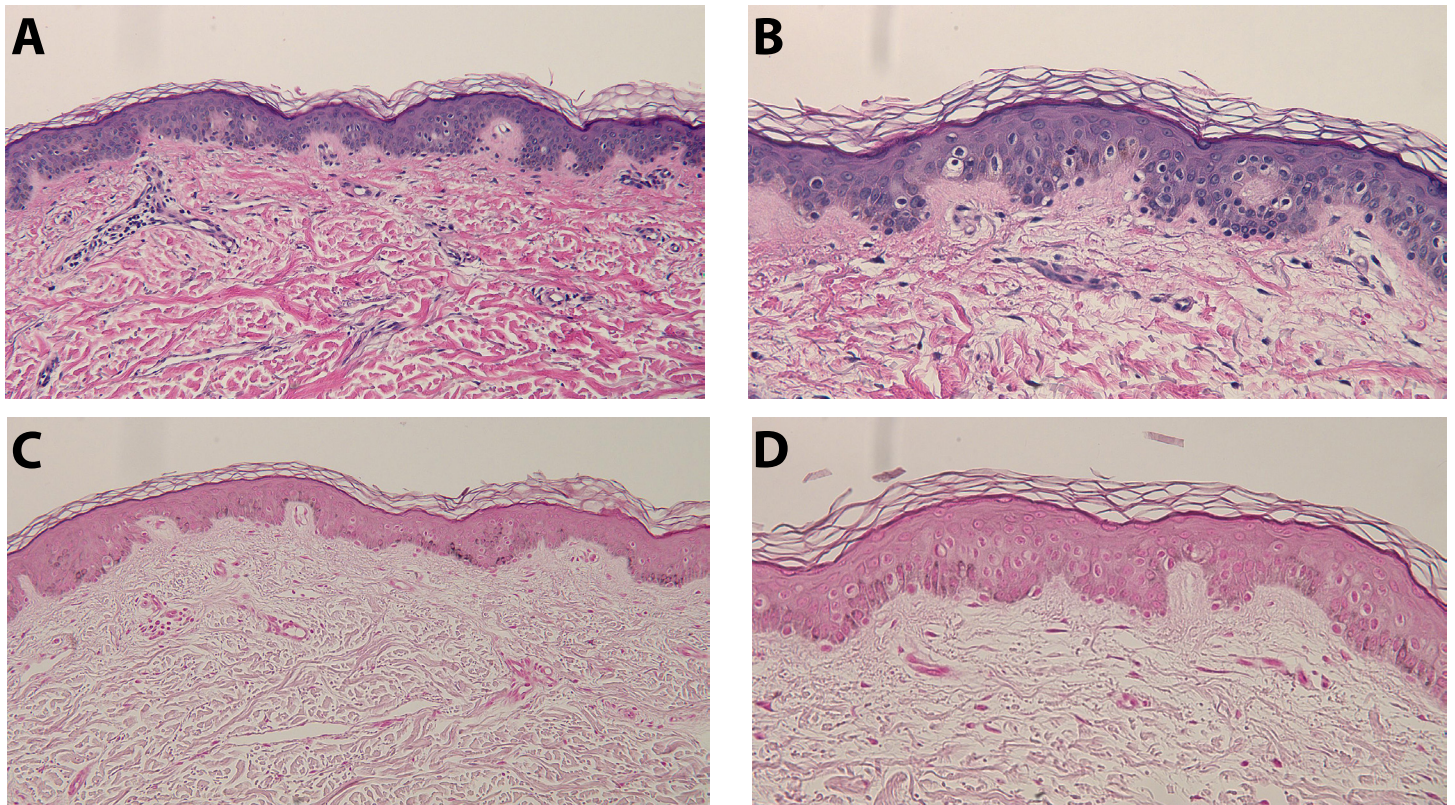


Figure 3. The patient's left posterior deltoid area, clinically normal-appearing non-pigmented skin, was also biopsied. Tissue samples stained with hematoxylin and eosin showed benign-appearing epidermis and dermis (A and B). The Fontana Masson stain shows a normal amount of pigmentation (C and D) epidermis (H&E: A, 4x; B, 10x; Fontana Masson: C, 4x; D, 10x).

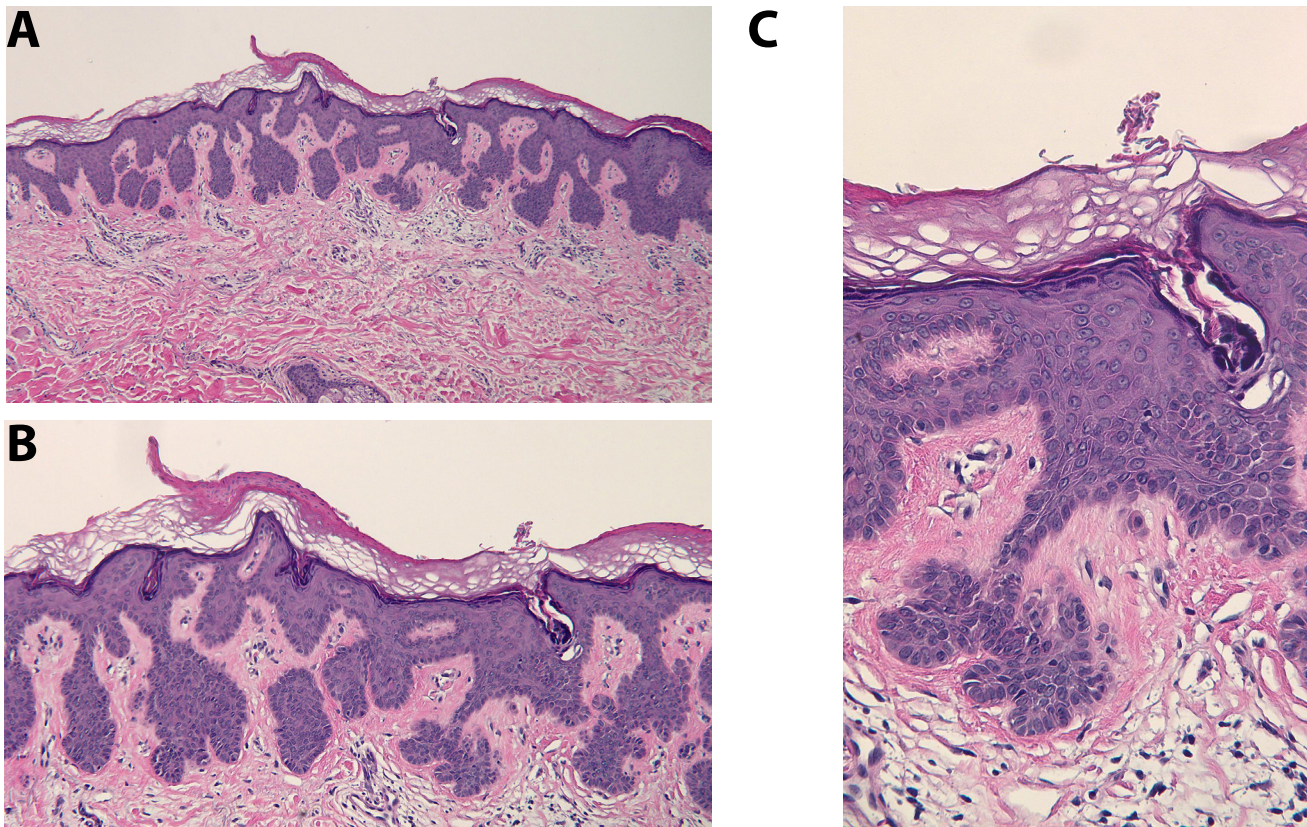


Figure 4. Microscopic examination of the patient's hypopigmented plaques on his back showed an epithelial lesion. There is orthokeratosis with focal parakeratosis. The epidermis is acanthotic with elongation of the rete ridges and invagination of overlying keratin into the epithelium, consistent with early pseudocyst formation (A-C). These findings establish a diagnosis of seborrheic keratosis (H&E: A, 4x; B, 20x; C, 40x).

Histologic examination of the white plaques showed focal parakeratosis overlying a hyperplastic epidermis. The rete ridges are elongated and the overlying keratin invaginates into the epithelium (**Figure 4**). These findings established the diagnosis of a seborrheic keratosis.

Case Discussion

Hereditary hemochromatosis, in most patients, is inherited in an autosomal recessive manner and associated with a homozygous C282Y mutation in the HFE gene [1]. Transferrins are proteins that bind free iron in the bloodstream. Normally, HFE helps to facilitate cellular uptake of transferrin-bound iron [1, 6]. In hereditary hemochromatosis, defects in this process leads to increased transferrin saturation, which is exacerbated by inappropriately high levels of iron transport from intestinal cells to the bloodstream [7].

Diffuse hyperpigmentation is a clinical feature of hereditary hemochromatosis. It may involve

both cutaneous and mucosal surfaces [8, 9]. Skin coloration may range from a metallic grey to brown color. Although it often presents as a generalized dermatosis, sun-exposed areas are often prominently involved [9, 10].

Two mechanisms have been described to account for the abnormal pigmentation observed in hereditary hemochromatosis. First, hemosiderosis, or excess iron deposition, occurs in the dermis, as well as other organs throughout the body [5]. Second, increased melanogenesis appears to occur in the epidermis of individuals affected with hereditary hemochromatosis, which contributes to the observed pigmentation changes [5].

A study of 100 patients with hereditary hemochromatosis found that the degree of melanin or iron pigmentation did not appear to be related to the clinically observed color of the skin [9]. Several other cutaneous changes, in addition to diffuse hyperpigmentation, may be observed in hereditary

hemochromatosis [9, 11], (**Table 1**).

Among these, hair loss, ichthyosis-like changes, nail changes (koilonychia), and skin atrophy appear to be the most common.

Siderosis may be found in the eccrine sweat glands of hyperpigmented or normal-appearing skin in some of the untreated patients with hemochromatosis [9]. Thus, iron deposition in the eccrine glands may be a specific sign of hemochromatosis that may be used as an adjunct in diagnosis [9]. Additional pathologic changes in the hyperpigmented skin, similar to our patient, include hyperpigmentation of the basal layer and melanophages in the upper dermis.

Seborrheic keratoses are benign tumors that occur more commonly with age [12]. They are thought to occur as a result of clonal proliferation of epidermal keratinocytes that have been mutated [13]. Although seborrheic keratoses may have varied pigmentation, they usually present as brownish plaques on sun-exposed areas of the body [14]. Treatment options include observation, cryotherapy, shave excision, or excision [14].

Sometimes, the new onset of multiple seborrheic keratoses may be concerning for occult malignancy, termed the Leser Trelat sign [15]. However, there have been reports of this phenomenon occurring in individuals without any internal malignancy, and our patient was not found to have any occult malignancies either [15, 16].

Depigmentation [areola (6 patients), scars (2 patients), exposed body areas (1 patient), and external genitalia (1 patient)] was observed in 10% (10/100) of individuals with hemochromatosis in a study conducted by Chevrant-Breton et al. [9]. Our patient's seborrheic keratosis presented as hypopigmented plaques within areas of confluent hyperpigmentation on his back. The occurrence of these hypopigmented lesions in the setting of diffuse hyperpigmentation from hemochromatosis appears paradoxical.

This case highlights the clinical importance of being aware of various possible presentations of seborrheic keratoses. The occurrence of seborrheic keratoses in patients with hereditary hemochromatosis has rarely

been reported and clinicians need to be aware of the atypical presentation of white hypopigmented lesions on a background of cutaneous hyperpigmentation associated with hereditary hemochromatosis.

Conclusion

Hereditary hemochromatosis is a disease that may affect various body systems and present with a wide range of clinical findings. Cutaneous manifestations of this disease are especially notable and specific patterns of iron deposition – particularly in eccrine sweat glands – observed under histologic examination may aid in the diagnosis. Although diffuse hyperpigmentation is the most commonly described cutaneous manifestation of hereditary hemochromatosis, other dermatologic findings – such as hair loss, koilonychia, and skin atrophy – may also occur. In addition, less frequently, discrete hypopigmentation has also been observed in individuals with hemochromatosis, including our patient. The presentation of seborrheic keratosis as hypopigmented plaques in this disease is uncommon. However, this benign diagnosis should be considered when an individual affected with hereditary hemochromatosis presents with acquired hypopigmented lesions.

References

1. Pietrangelo A. Hereditary hemochromatosis – a new look at an old disease. *N Engl J Med* 2004;350:2383-2397. [PMID: 15175440]
2. Santos PC, Krieger JE, Pereira AC. Molecular diagnostic and pathogenesis of hereditary hemochromatosis. *Int J Mol Sci* 2012;13:1497-1511. [PMID: 22408404]
3. Limdi JK, Crampton JR. Hereditary haemochromatosis. *QJM* 2004;97:315-324. [PMID: 15152104]
4. Zoller H, Henninger B. Pathogenesis, diagnosis and treatment of hemochromatosis. *Dig Dis* 2016;34:364-373. [PMID: 27170390]
5. Fistarol SK, Itin PH. Disorders of pigmentation. *J Dtsch Dermatol Ges* 2010;8:187-201. [PMID: 19788584]
6. Pietrangelo A. Iron and the liver. *Liver Int* 2016;Suppl 1:116-123. [PMID: 26725908]
7. Salgia RJ, Brown K. Diagnosis and management of hereditary hemochromatosis. *Clin Liver Dis* 2015;19:187-198. [PMID: 25454304]
8. O'Neil J, Powell L. Clinical aspects of hemochromatosis. *Semin Liver Dis* 2005;25:381-391. [PMID: 16315132]
9. Chevrant-Breton J, Simon M, Bourel M, Ferrand B. Cutaneous manifestations of idiopathic hemochromatosis. Study of 100 cases. *Arch Dermatol* 1977 113:161-165. [PMID: 836692]
10. Chacon AH, Morrison B, Hu S. Acquired hemochromatosis with pronounced pigment deposition of the upper eyelids. *Clin Aesthet Dermatol* 2013;6:44-46. [PMID: 24155994]
11. Köstler E, Porst H, Wollina U. Cutaneous manifestations of metabolic disease: uncommon presentations. *Clin Dermatol* 2005;45:457-464. [PMID: 16179179]
12. Roh NK, Hahn HJ, Lee YW, Choe YB, Ahn KF. Clinical and

- histopathological investigation of seborrheic keratosis. *Ann Dermatol* 2016;28:152-158. [PMID: 27081260]
13. Nakamura H, Hirota S, Adachi S, Ozaki K, Asada H, Kitamura Y. Clonal nature of seborrheic keratosis demonstrated by using the polymorphism of the human androgen receptor locus as a marker. *J Invest Dermatol* 2011;116:506-510. [PMID: 11286615]
 14. Jackson JM, Alexis A, Berman B, Berson DS, Taylor S, Weiss JS. Current understanding of seborrheic keratosis: prevalence, etiology, clinical presentation, and management. *J Drugs Dermatol* 2015;14:1119-1125. [PMID: 26461823]
 15. Safa G, Darrieux L. Leser-Trélat sign without internal malignancy. *Case Rep Oncol* 2011;4:175-177. [PMID: 21526136]
 16. Turan E, Yesilova Y, Yurt N, Koçarslan S. Leser-Trélat sign: does it really exist? *Acta Dermatovenerol Croat* 2013;21:123-127. [PMID: 14001422]