

## **UC San Diego**

### **UC San Diego Previously Published Works**

**Title**

An Index for Quantitative Assessment of Lip Augmentation

**Permalink**

<https://escholarship.org/uc/item/0wg59136>

**Author**

Lemperle, Gottfried

**Publication Date**

2015-04-05

Peer reviewed

# An Index for Quantitative Assessment of Lip Augmentation

Gottfried Lemperle, MD, PhD; Russell Anderson, MS, MBA; and Terry R. Knapp, MD

Aesthetic Surgery Journal  
30(3) 301–310  
© 2010 The American Society for  
Aesthetic Plastic Surgery, Inc.  
Reprints and permission:  
[http://www.sagepub.com/  
journalsPermissions.nav](http://www.sagepub.com/journalsPermissions.nav)  
DOI: 10.1177/1090820X10374095  
[www.aestheticsurgeryjournal.com](http://www.aestheticsurgeryjournal.com)



## Abstract

**Background:** Lip dimensions and their relation to the whole face have been discussed mainly in the dental literature. There have been few attempts to scientifically measure the degree of lip augmentation, regardless of method.

**Objectives:** The authors describe a Lip Index that will allow reliable, quantitative analysis of the human lip complex, which is necessary to assess the efficacy and duration of attempts at lip augmentation.

**Methods:** The authors developed a Lip Index as the basis for objective measurements of the effect and duration of lip augmentation with dermal fillers. Measurements may be taken directly from the patient, from standardized photos, or from the computer screen. Using a metric ruler, the height of the vermilion in the middle of the Cupid's bow is first measured (in mm) on the frontal view. The point of maximum protrusion of the vermilion is then measured (in mm) on a standardized side view perpendicular to a vertical line connecting the base of the columella to the fold demarcating lower lip and chin. Vermilion height multiplied by horizontal protrusion directly correlates with the central volume of the lips, upper and lower.

**Results:** The easily applied ruler provided consistent measures before and after the injection of dermal fillers or soft implants. Adding upper and lower lip indices resulted in the Overall Lip Index for each patient, which was found to be approximately 50 in average females of Caucasian descent, about 100 in females of Asian descent, and nearly 200 in females of African descent.

**Conclusions:** The Lip Index allows for the practical evaluation of the clinical effects and duration of dermal filler injectables or implants. Quantitative assessments of results over time are easy to calculate, without the need for complex measurements or sophisticated analyses.

## Keywords:

Lip Index, lip augmentation, lip dimensions, lip protrusion, dermal fillers

EDITOR'S NOTE: In this article, the author discusses off-label applications of injectable products to augment the aging lip. Please see this month's Editorial for additional notes on the considerations inherent in off-label treatment.

It is common knowledge that the aesthetic desires of our patients vary with emerging fashion trends and differ among cultures. Over the past five decades, fuller lips have been considered a desirable trait. Many younger patients are presenting for lip augmentation to achieve the sought-after look commonly seen in movie stars and fashion magazines.<sup>1</sup> Based on a study published in 2004, it was found that models, in general, appear to have fuller lips than nonmodels.<sup>2</sup> Of note, lip augmentation and/or radial wrinkle mitigation is predominantly a correction sought by women. Clearly, there is a predominance of radial wrinkle manifestation in women, most likely attributable to the lack of large hair follicles and adnexal glands in the skin complex.<sup>3</sup> In men, the presence of moustache hair tends to stabilize the skin/subcutaneous fat complex, probably mitigating the tendency to form radial wrinkles.

In 2007, Beer<sup>4</sup> described three categories of patients who seek lip improvement: those with pleasing lip shape who want more fullness, those with genetically thin lips and/or poor definition of the vermilion border, and those with atrophic lips and poor definition of the vermilion border due to advancing age. Aging creates a predictable, often undesirable, spectrum of change in the lips. Much as with the rest of the face, the upper lip undergoes fat tissue atrophy<sup>5</sup> and lengthens vertically, at the expense of a thinner and decreasingly visible vermilion. This increased laxity does not necessarily result in a decrease in volume of the whole lip.<sup>6,7</sup> Other common changes in the aging

Dr. Lemperle is Voluntary Clinical Professor in the Division of Plastic Surgery at the University of California, San Diego. Mr. Anderson is a consultant of Lithera, Inc. in San Diego, California. Dr. Knapp is a plastic surgeon in private practice in Niwot, Colorado.

## Corresponding Author:

Gottfried Lemperle, MD, PhD, 302 Prospect Street, La Jolla, CA 92037, USA.

E-mail: [glemperle@aol.com](mailto:glemperle@aol.com)

upper lip include a flattening of the philtrum, widening of the cupid's bow, and loss of the natural "pout" of the vermilion. Orbicularis muscle activity and thinning of the tissues result in the occurrence of radial lip lines, with unsightly "wicking" of lipstick into the furrows as they cross the white line. All of these factors drive patients to seek lip augmentation. Often, when a patient presents for treatment, the upper lip dominates the discourse, but the lower lip may require treatment as well. With age, the lower lip may develop ptosis, with a resulting unattractive lower dental show.

The objective of lip augmentation is a natural three-dimensional (3-D) enhancement of lip volume with well-defined vermilion border. The goal for the upper lip is a change in form that harmonizes with the patient's unique features while avoiding overcorrection. The goal for the lower lip is to add bulk, greater prominence, and projection of the vermilion—all in proportion with the upper lip.

Lip dimensions and their relation to the whole face have been discussed mainly in the dental literature.<sup>8</sup> There have been few attempts to scientifically measure the degree of lip augmentation, regardless of method. Some have attempted to quantify changes in lip volume with magnetic resonance imaging (MRI)<sup>9,10</sup> and computerized 3-D stereophotogrammetry.<sup>11,12</sup> However, these sophisticated, complex, and expensive methods are not practical as an office assessment or as part of clinical routine.

Carruthers et al<sup>13</sup> described a five-point photometric rating scale (Lip Fullness Grading Scale [LFS]) from a series of morphed and unretouched lip photos. As with many analog rating scales,<sup>14</sup> accurate reproduction and consistency are difficult to achieve because the "rating" depends on the subjective judgment of the observer. Clearly, a reproducible means of injectable delivery and an objective method for measuring results over time are both necessary. To that end, we describe the development of an objective Lip Index (LI) for quantifying the results of lip augmentation procedures. We designed our LI based on the protrusion and height (in mm) of the upper and lower vermilion in two standardized photos of 40 patients. With this index, when lips thin out during aging and/or when they are augmented, lip protrusion and height can be measured on comparable photos months or years later, and the effect of enhancement or aging can be documented accurately.

## METHODS

Photographs were taken of each patient from a standardized frontal and a 90-degree side view with a camera setup offering chin support and a fixed distance, in front of a light background. The lips were 1 to 2 mm loosely open, to show the incisors (Figure 1A and 1B). The size of the photo correlated with the clinical size of the lips. (For comparison, the width of the lips can be measured from the right to the left commissure and compared with the width on the photo.)

Measurements were taken directly from each patient, from standardized photos, or from the computer screen.

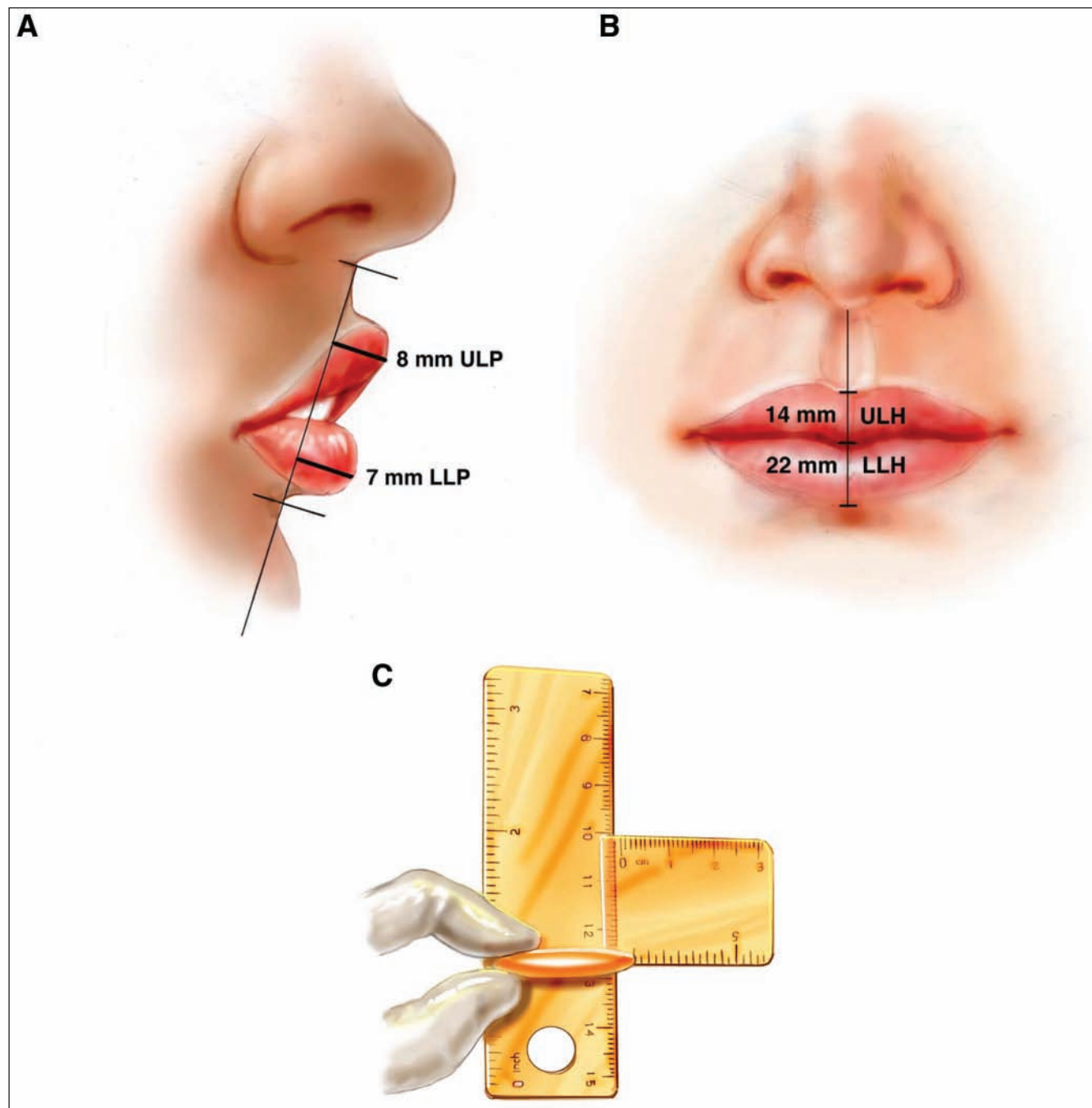
We designed a convenient device for measuring the lips, consisting of two small rulers glued together perpendicularly, at a 90-degree angle (Figure 1C). With this metric ruler, the height of the vermilion (upper lip height [ULH] and lower lip height [LLH]) was first measured (in mm) in the middle of the cupid's bow on the frontal view. The point of maximum protrusion of the vermilion was then measured (upper lip protrusion [ULP] and lower lip protrusion [LLP]) in mm on a standardized side view, perpendicular from a vertical line connecting the base of the columella (columella-lip junction) to the fold demarcating lower lip and chin. ULH multiplied by horizontal ULP directly correlated with the central volume in mm<sup>2</sup> of the middle 1-mm slice. This number was the patient's own Upper Lip Index (ULI) and Lower Lip Index (LLI) in mm<sup>2</sup>, respectively. The formulas (ULH × ULP = ULI and LLH × LLP = LLI) became the baseline for comparative purposes following augmentation. Adding the ULI and LLI resulted in the Overall Lip Index (ULI + LLI = OLI in mm<sup>2</sup>). The examination of 40 lips in our patient files indicated roughly an OLI of about 50 to 100 in average females of Caucasian descent, about 100 to 200 in females of Asian descent, and 200 to 300 in females of African descent. The greater the OLI, the fuller the lips.

The fullness measurement of lips appears to have no mathematical relationship to surrounding features such as nose, chin, or cheeks,<sup>13,15</sup> although fullness does appear to correspond to racial origins. For these reasons, it probably means little to calculate mean volumes and standard deviations in attempts to define ideal lip physiognomy. Relative to LI calculation, every patient is best treated as a singularity, comparing the LI only to that patient's variation over time.

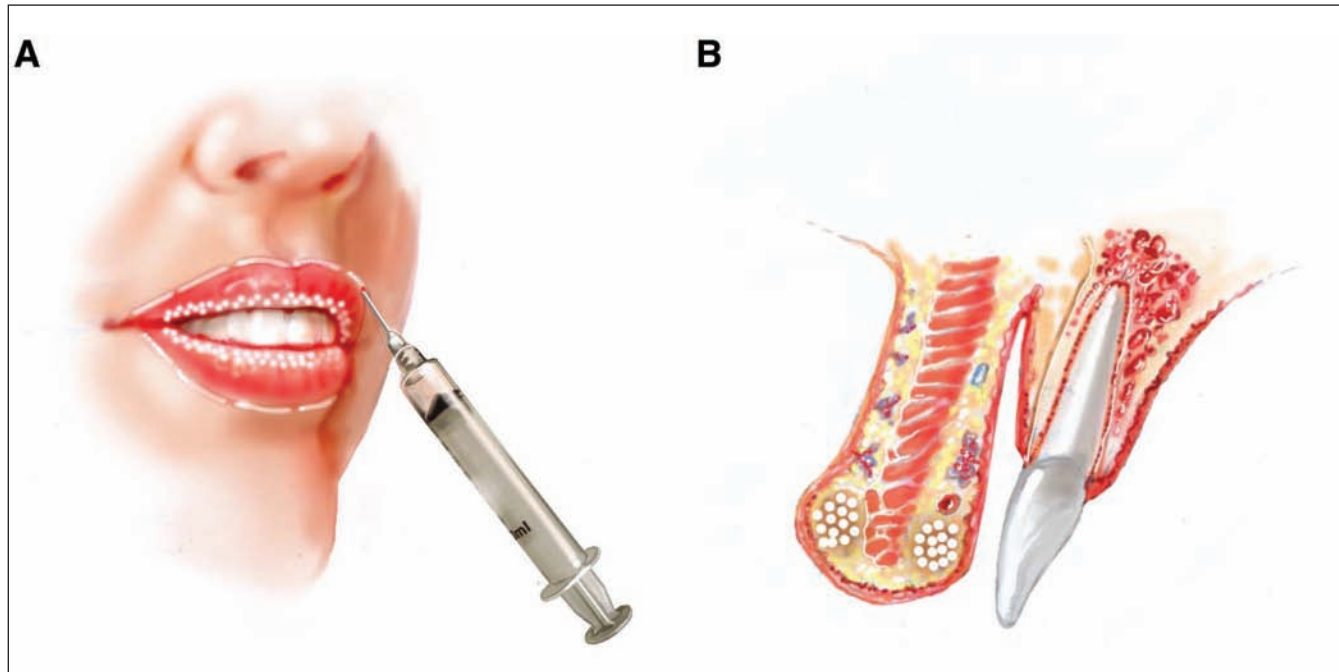
## Injection Technique

The goal of lip filling may be more than to simply augment. Lip recontouring is undertaken to improve shape and bring upper and lower lips into better proportion with one another. The ideal proportion is the ratio of 1:1.6 between upper and lower lip<sup>2</sup> (Figure 2A). There are three small tubercles on the upper lip and two on the lower lip,<sup>2,16</sup> which give the shape of the lips its individuality and should therefore be preserved during augmentation.

Collagen, hyaluronic acid (HA) products, and liquid silicone (LIS) have all been injected intramuscularly in lips.<sup>1,4</sup> However, all such intramuscular injections are prone to dislocation by constant muscle movement and therefore may cause lumping.<sup>5,17,18</sup> Experience dictates that all particle-based injectables such as ArteFill (Sunova Medical, Inc., San Diego, California), Radiesse (Bioform Medical, Inc., San Mateo, California), and Sculptra (Sanofi-Aventis, Bridgewater, New Jersey)—none of which are approved by the Food and Drug Administration (FDA) for lip treatment—should strictly be administered either along the vermilion borders and/or submucosally along the dry-wet border, avoiding intramuscular placement (Figure 2B).



**Figure 1.** (A) An aesthetically pleasing lip, with a rare midline notch and an upper lip height (ULH) of 10 mm. In this case, the ULH could also be measured laterally from the midline (17 mm). The lower lip height (LLH) is 22 mm. (B) A line is drawn from the columella-lip junction to the horizontal chin fold, and the maximal protrusion of the lips is measured perpendicular to this line (ULH = 8 mm, LLH = 7 mm). (C) To recreate the authors' measuring device, a short mm measure should be cut from the end of a simple metric ruler and then attached to the other piece in a perpendicular fashion. The horizontal part of the ruler measures the protrusion of the lips from an imaginary line between the base of the nose and the horizontal chin fold (either directly on the patient or on the computer screen). The ratio should be 1:1.



**Figure 2.** (A) Placing one strand of a filler into the white roll enhances the pouting effect. In lip augmentation, the submucosal “serial puncture technique” along the dry-wet border is the treatment of choice for the prevention of lumps. (B) Filler should never be injected into the muscle, but rather into the natural pockets beneath the white roll above and beneath the “red line” in the back of the lip.

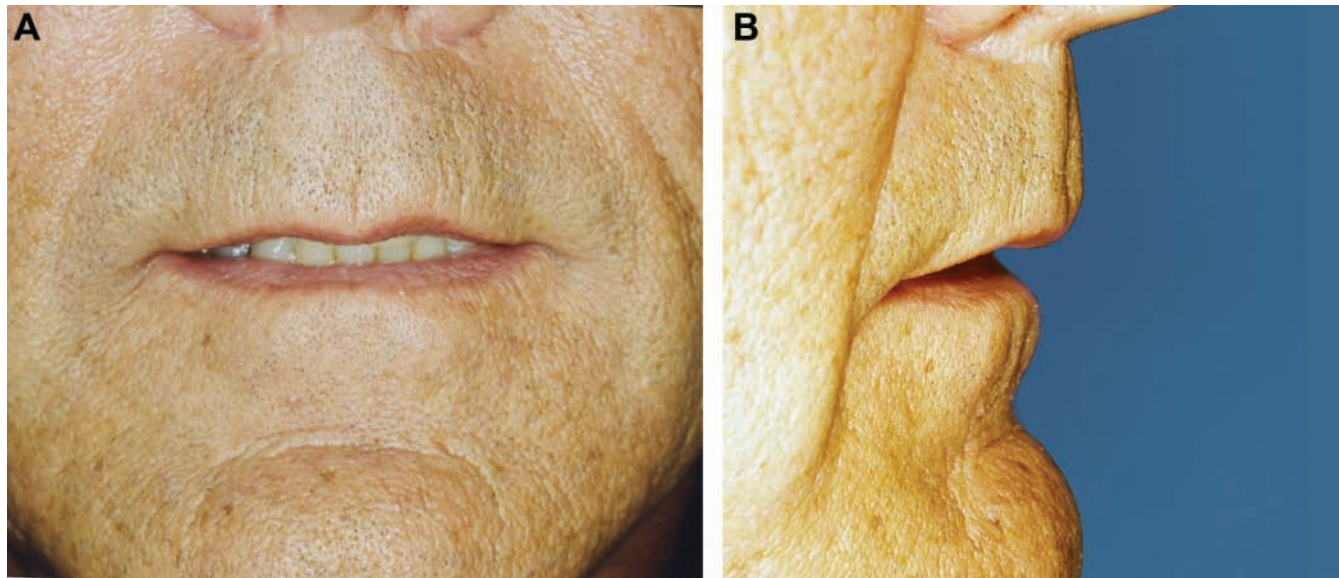
We have found that the ideal needle size is 30-gauge and its length is one-half inch. This small needle also works with higher viscosity injectables like the three mentioned earlier. The smaller the needle diameter, the smaller the initial volume injected. However, the smaller the needle, the longer the postshot oozing from the needle tip. To minimize this oozing during the microdroplet injection technique, we recommend a short 26-gauge needle for the inner submucosal injection of high-viscous products. The upper and lower lips are best anesthetized by lidocaine injections into the labiogingival fold<sup>19</sup> that numb the lips within two minutes.

Beneath the vermilion border appears a natural, loose interstitial plane between the skin of the white roll and the underlying orbicularis oris muscle. This plane is easily located and may be augmented with the filler (Figure 2B). One may readily direct the needle into the correct plane at an angle from lateral to medial or vice versa (Figure 2A). While injecting, it is often useful to hold the white roll between two fingers in order to prevent filler dislocation. Usually, filler can be implanted in half of the lip in a single penetration by withdrawing the needle from the white roll while injecting under pressure. A volume of 0.4 to 0.8 mL should be sufficient for each lip. Larger volumes may result in overdistention and pain. If large corrections are indicated, it is better to augment the lips in stages. If the injectable is well tolerated and the lips are soft after three months, more injectate can be introduced in the same tissue plane. To increase fullness and protrusion (“pouting”)

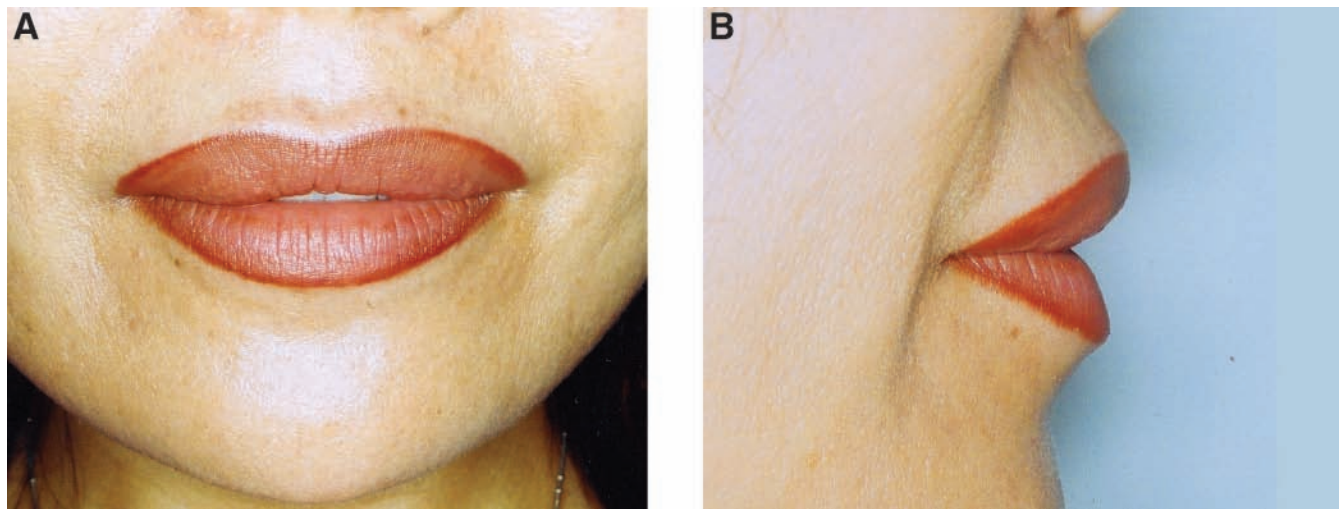of the lip, a second volume can be applied horizontally along the dry-wet border (red line) of the inner vermilion. In this location in the lip, the serial puncture technique must be used exclusively to prevent clumping of the filler during early lip movement.

As noted previously, particulate materials such as ArteFill, Radiesse, and Sculptra have no FDA approval for lip augmentation because of the history and potential danger of resulting lumps. These materials should *never* be implanted into the orbicularis oris muscle because this may cause dislocation of the injectate and nodule formation. The patient must be aware that longer-lasting fillers implanted submucosally can nearly always be felt with the tongue or the teeth and may appear white in color when the lip is stretched. Sensitivity to strong touch and firm kissing may last up to one year, but usually resolves spontaneously.

A flattened philtrum may be raised effectively with two vertical injections of filler along the philtral ridges, starting from below (ie, from the two peaks or tubercles of the Cupid’s bow within the white roll,<sup>2,16</sup> extending vertically to just below the nasal sill). Occasionally, fluid injectables may migrate into the surrounding tissue during the injection. Immediate correction is possible by molding the implant between two fingers into the philtrum ridge or the white roll. The proper injection technique entails linear threading<sup>19</sup> of the injectable along the desired path. The serial puncture technique should be studiously avoided in the visible part of the lip.



**Figure 3.** (A) A 58-year-old man with thin lips. The patient has an upper lip height (ULH) of 2 mm and a lower lip height (LLH) of 4 mm. (B) In the profile view, the very thin upper lip has a ULP of 4 mm and the lower lip an LLP of 1 mm. Per the calculations described in the text, both lips have an Overall Lip Index of  $8 + 4 = 12 \text{ mm}^2$ .

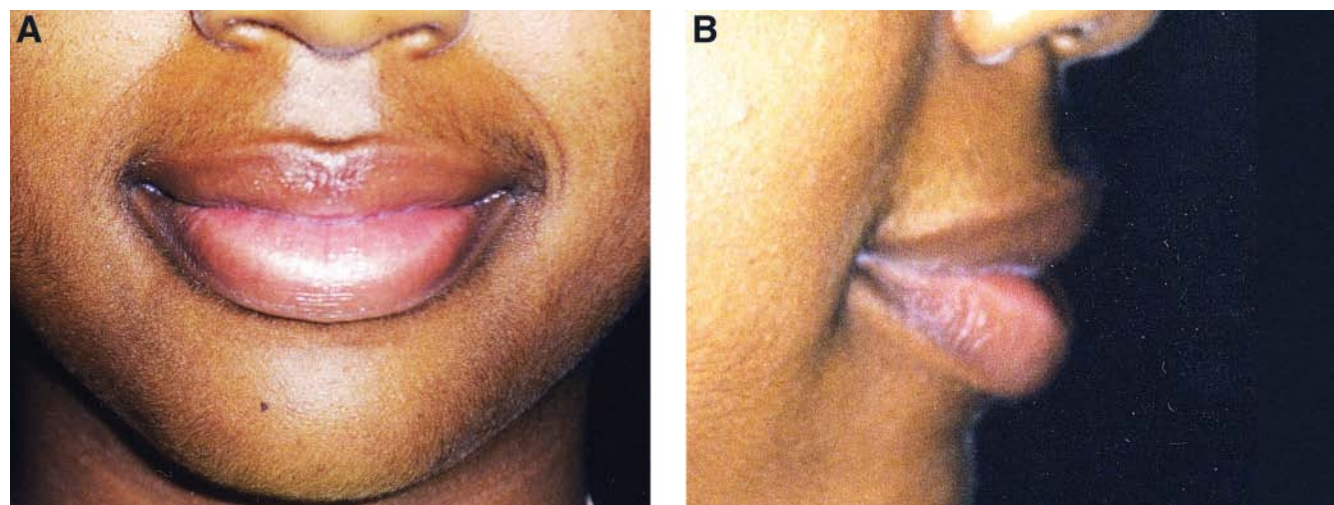


**Figure 4.** (A) A 53-year-old Asian patient with an upper lip height (ULH) of 7 mm and a lower lip height (LLH) of 13 mm. (B) In the profile, the upper lip protrusion (ULP) is 7 mm and the lower lip protrusion (LLP) is 6 mm, which gives this patient an Overall Lip Index of  $127 \text{ mm}^2$ .

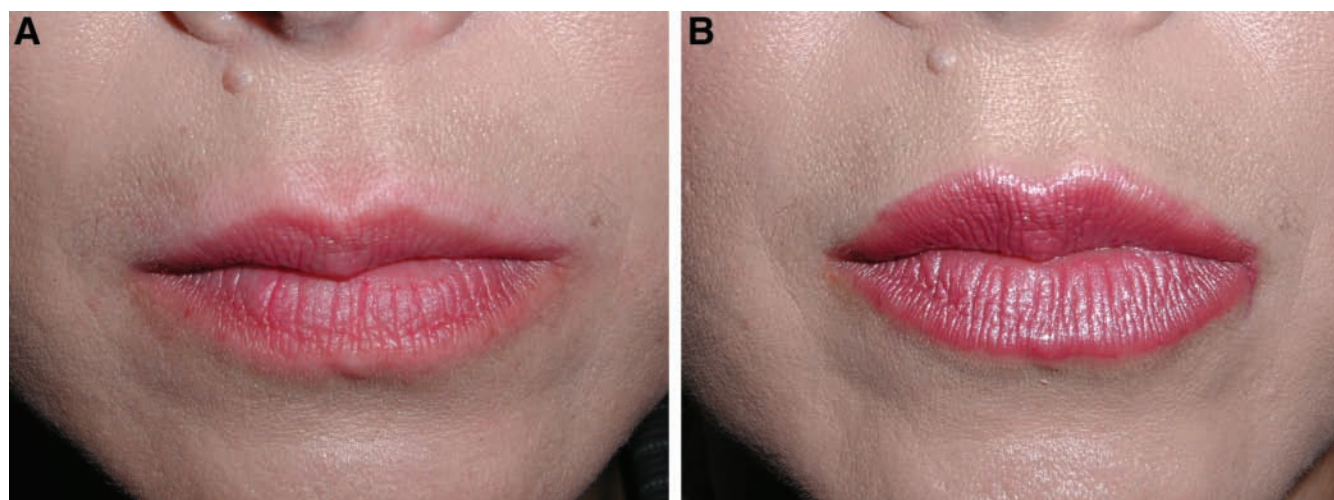
When the upper lip is long and dental show is less-than-desirable as a result (as with the patient in Figure 6), injection of filler material should be avoided. Doing so may further lengthen the lip and hide the front teeth on smiling. In these patients, a surgical lip lift (subnasal bull-horn excision) may be preferable.

The primary complication with injectables in the lips, observed to varying degrees with all fillers, has been the formation of nodules<sup>17,18,20</sup> and granulomas.<sup>15,21-25</sup> The absence of strictly-reproducible injection techniques and

the variability among patients certainly adds to the uncertainty and lack of consistency in results. Irregularities usually reflect lack of technical skill and experience of the injector, whereas lumpiness most often is due to the constant movement of the orbicularis oris muscle, which compresses each strand of any injectable into a lump during uncontrolled pouting. Fluid fillers such as collagen, silicone, and HA may dissipate within or outside the muscle when injected intramuscularly. Permanent and semi-permanent fillers such as ArteFill, Radiesse, or Sculptra



**Figure 5.** (A) A 24-year-old woman of African descent with an upper lip height (ULH) of 14 mm and a lower lip height (LLH) of 19 mm. (B) In the profile, the upper lip protrusion (ULP) is 10 mm and the lower lip protrusion (LLP) is 12 mm, which gives her an Overall Lip Index of  $14 \times 10 + 19 \times 12 = 368 \text{ mm}^2$ .



**Figure 6.** (A) A 26-year-old woman with an upper lip height (ULH) of 9 mm and a lower lip height (LLH) of 12 mm. (B) Two months posttreatment of the upper lip, the ULH increased to 11 mm and the LLH remained at 12 mm. This patient's Overall Lip Index of  $45 + 60 = 105$  increased after treatment to  $66 + 60 = 126 \text{ mm}^2$ .

will remain where injected due to their higher viscosity. For this reason, we strongly advocate avoiding the orbicularis muscle during injection, instead delivering the product in the subcutaneous or submucosal fat.

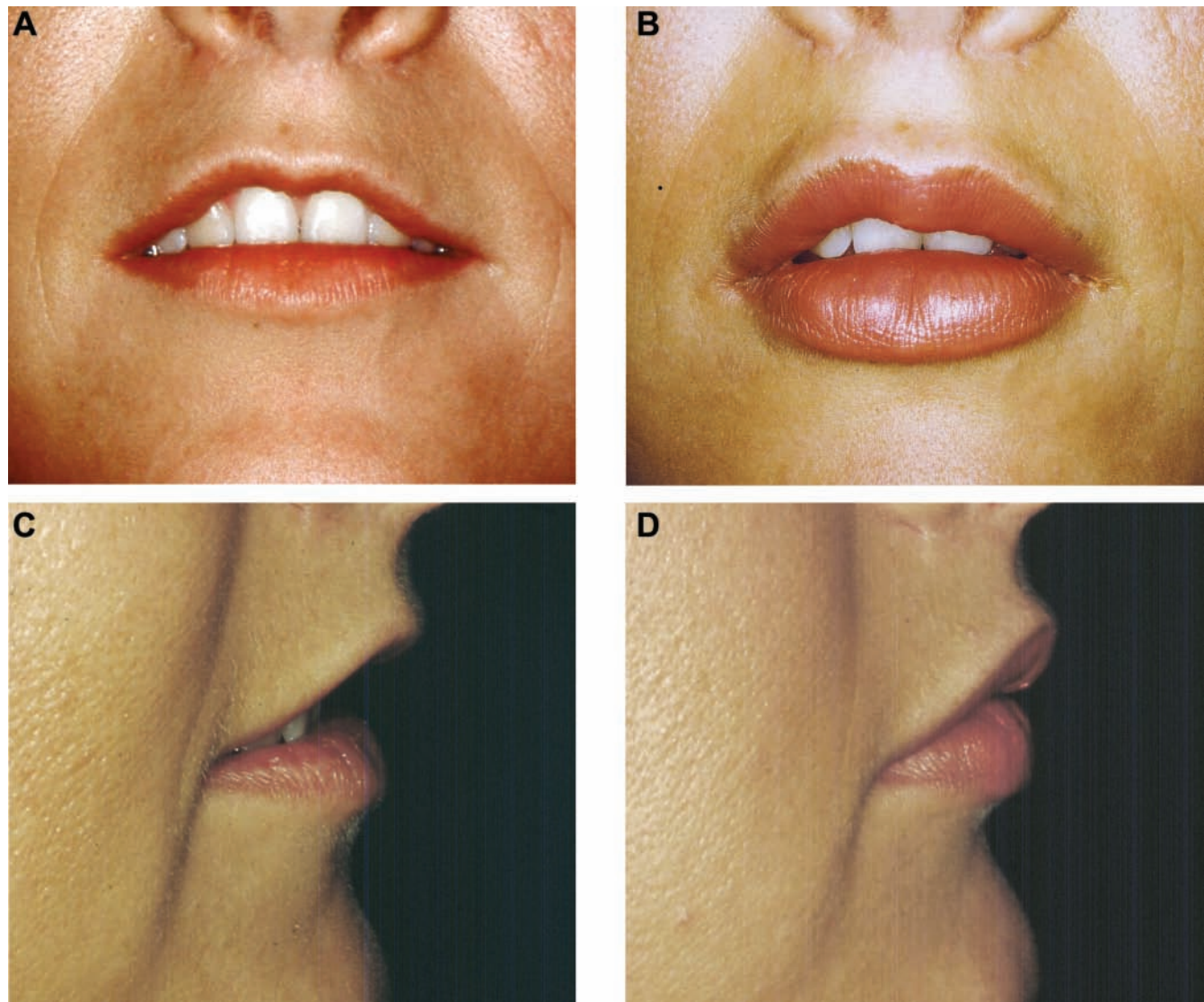
## RESULTS

Figures 3 to 7 illustrate the ease and reliability of measurements and results with our OLI calculations. Of course, unilateral vermilion components can be measured as well in patients with asymmetries and unilateral cleft lips<sup>26,27</sup>

(Figure 8). Edematous or lumpy lips caused by filler granulomas or other etiologies can be measured over time, and the effectiveness of corrective treatment can thereby be documented.

## DISCUSSION

There appears to be an ever-expanding list of commercial products that have potential for lip augmentation. In Europe, we estimate that there are more than 50 dermal fillers on the market. There are also a number of autologous materials



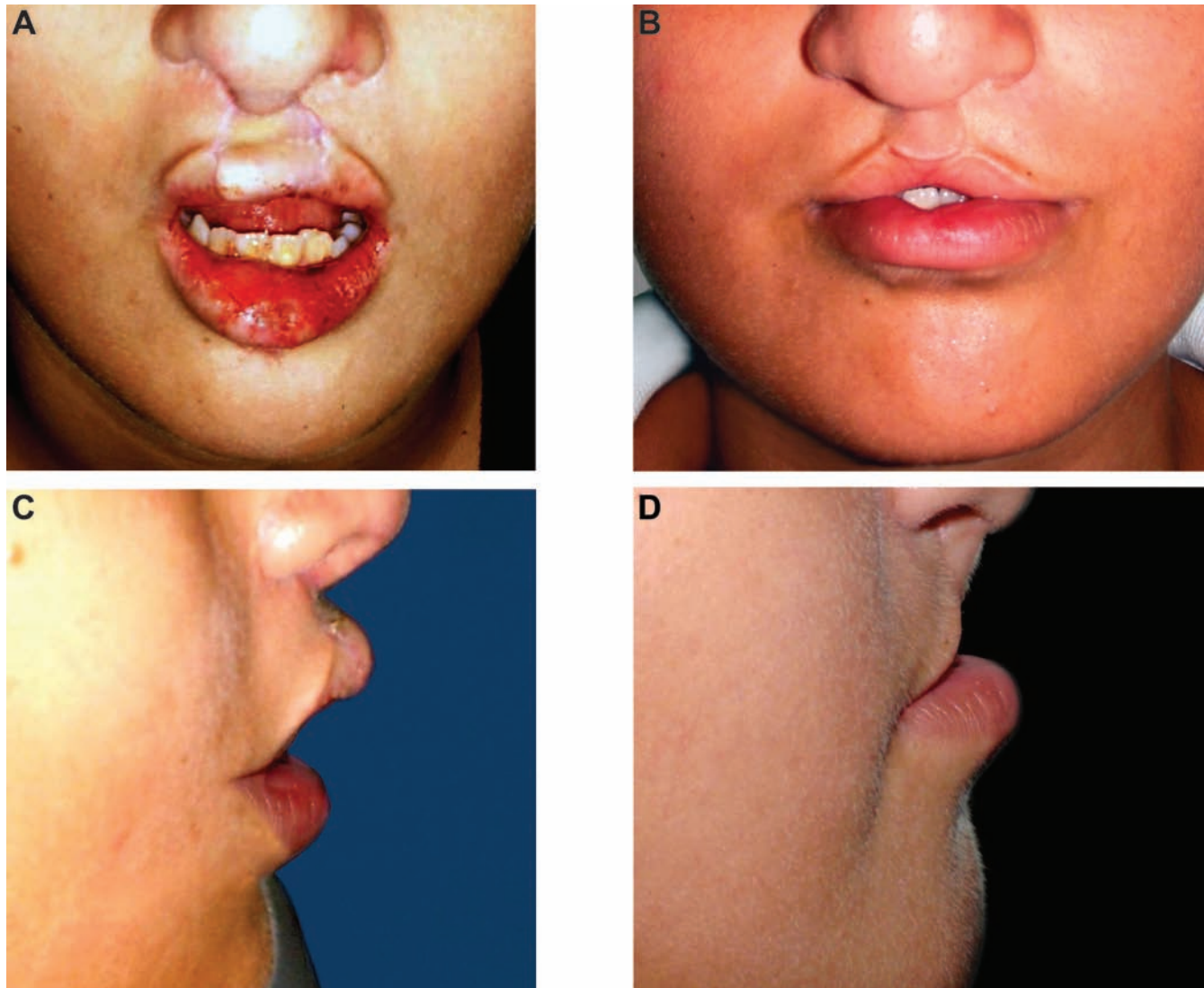
**Figure 7.** (A, C) A 29-year-old patient with a thin upper lip and no change after lip lift (bullhorn excision): upper lip height (ULH) = 3 mm, lower lip height (LLH) = 11 mm; upper lip protrusion (ULP) = 3 mm, lower lip protrusion (LLP) = 3 mm. (B, D) One year after augmentation with Artecoll (and before correction of the asymmetry): ULH = 8 mm, LLH = 18 mm; ULP = 6 mm, LLP = 5 mm. The Upper Lip Index increased from 9 to 48 mm, and the Lower Lip Index from 33 to 90 mm, so the Overall Lip Index went from 41 to 138 mm<sup>2</sup>.

(such as fat, fascia, and tendon) that may be employed to augment the lips. Despite the plethora of modalities, there are very few published sources of technical information or guidelines to assist the practitioner with the correct technique for lip enhancement.

The most common approach to lip augmentation is the use of commercially available dermal fillers.<sup>9</sup> There is a broad range of expected outcomes with injectables, depending on the skills of the injector, the anatomy of the patient, and the intrinsic properties of the product. Resurfacing techniques for lip skin are also available, including dermabrasion, laser, or chemical peels, thereby adding to the nearly infinite number of permutations that may be employed for lip rejuvenation.<sup>4</sup>

In the decades immediately prior to this century, lip augmentation options were limited mainly to silicone injections or implants,<sup>7,28</sup> bovine collagen injections,<sup>21</sup> and a few surgical procedures. Several new injectable dermal fillers have become available over the past decade. These include extracellular connective tissue components such as HA<sup>22,26</sup> and porcine collagen (Evolence; not available in the United States).<sup>20,29-31</sup> Injectable products that offer more long-term, durable results are also evolving and becoming available on the market. These injectables derive their longevity from microspheres of polylactic acid,<sup>23</sup> calcium phosphate,<sup>17,24</sup> and polymethylmethacrylate.<sup>19</sup> Although lip augmentation may not be





**Figure 8.** (A, C) A 13-year-old male with an operated double cleft lip. His upper lip height (ULH) was 7 mm and lower lip height (LLH) was 14 mm; upper lip protrusion (ULP) =  $-3$  mm, lower lip protrusion (LLP) = 8 mm. (B, D) Immediately after separation of the Abbe flap, ULH was 12 mm and LLH was 13 mm (swollen). ULP = 12 mm (swollen), LLP = 8 mm. The Upper Lip Index increased from  $-21$  to 144, and the Lower Lip Index decreased from 112 to 104 (swollen) due to the volume loss after removal of the Abbe flap.

an indication under approved labeling (and is not recommended by any manufacturer), a body of clinical data is slowly evolving for this application.

In addition to injectables, solid, soft alloplastic implants from expanded PTFE (Advanta Facial Implant; Atrium Medical Corporation, Hudson, New Hampshire),<sup>11,32-34</sup> silicone (PermaLip; SurgiSil, LLP, Plano, Texas), and saline-filled ePTFE-silicone shells (FulFil and VeraFil; Evera Medical, Foster City, California)<sup>35</sup> have been described as bulking agents and implants for lip augmentation. Finally, autogenous grafts of fat,<sup>27,36-38</sup> temporal fascia, and palmaris longus tendon<sup>39,40</sup> have been used in attempts at permanent lip augmentation. The autogenous tissue

approach so far has been largely anecdotal and difficult to reproduce with consistency.<sup>27,36-38</sup>

Regardless of the augmentation material chosen, over time, our LI enables a practitioner to follow the results of lip augmentation and accurately assess the longevity and efficacy of various augmentation techniques, without having to resort to complex and difficult mathematical formulas. For example, it is easy to ascertain a baseline Caucasian OLI of 30 mm<sup>2</sup>, observe an enhancement effect with treatment that may cause the OLI to increase to 100 mm<sup>2</sup>, and then follow it over time to judge when additional correction may be warranted.

## CONCLUSIONS

To assess lip volume and follow it over time in individual patients, the authors designed a simple, straightforward measurement method, referred to as the Overall Lip Index (OLI). The OLI allows for the practical evaluation of the clinical effects and duration of dermal filler injectables or implants after lip enhancement. Quantitative assessments of results over time are easy to calculate, without the need for complex measurements or sophisticated analyses.

## Disclosures

Gottfried Lemperle and Russell Anderson are former employees of Artes Medical, Inc., San Diego, the manufacturer of ArteFill. That company is no longer in business. At present, none of the authors has a financial interest in the products described herein.

## Funding

The authors received no financial support for the research and/or authorship of this article.

## REFERENCES

- Segall L, Ellis DA. Therapeutic options for lip augmentation. *Facial Plast Surg Clin North Am* 2007;15:485-490.
- Bisson M, Grobbelaar A. The esthetic properties of lips: a comparison of models and nonmodels. *Angle Orthod* 2004;74:162-166.
- Paes EC, Teepen HJLM, Koop WA, Kon M. Perioral wrinkles: histologic differences between men and women. *Aesthetic Surg J* 2009;29:467-472.
- Beer KR. Rejuvenation of the lip with injectables. *Skin Ther Lett* 2007;12:5-7.
- Rohrich RJ, Pessa JE. The anatomy and clinical implications of perioral submuscular fat. *Plast Reconstr Surg* 2009;124:266-271.
- Iblher N, Klopper J, Penna V, Bartholomae JP, Stark GB. Changes in the aging upper lip: a photomorphometric and MRI-based study (on a quest to find the right rejuvenation approach). *J Plast Reconstr Aesthetic Surg* 2008;61:1170-1176.
- Penna V, Stark GB, Eisenhardt SU, Bannasch H, Iblher N. The aging lip: a comparative histological analysis of age-related changes in the upper lip complex. *Plast Reconstr Surg* 2009;124:624-628.
- Ferrario VF, Sforza C, Serrao G. A three-dimensional quantitative analysis of lips in normal young adults. *Cleft Palate-Craniofacial J* 2000;37:48-54.
- Sarnoff DS, Saini R, Gotkin RH. Comparison of filling agents for lip augmentation. *Aesthetic Surg J* 2008;28:556-563.
- Stauber I, Vairaktaris E, Holst A, et al. Three-dimensional analysis of facial symmetry in cleft lip and palate patients using optical surface data. *J Orofac Orthop* 2008;69:268-282.
- Ali MJ, Ende K, Maas CS. Perioral rejuvenation and lip augmentation. *Facial Plast Surg Clin North Am* 2007;15:491-500.
- Sawyer AR, See M, Nduka C. 3D stereophotogrammetry quantitative lip analysis. *J Aesthetic Plast Surg* 2009;33:497-504.
- Carruthers A, Carruthers J, Hardas B, et al. A validated lip fullness grading scale. *Dermatol Surg* 2008;34(suppl 2):S161-S166.
- Lemperle G, Holmes RH, Cohen SR, Lemperle SM. A classification of facial wrinkles. *Plast Reconstr Surg* 2001;108:1735-1750.
- Jham BC, Nikitakis NG, Scheper MA, Papadimitriou JC, Levy BA, Rivera H. Granulomatous foreign-body reaction involving oral and perioral tissues after injection of bio-materials: a series of 7 cases and review of the literature. *J Oral Maxillofac Surg* 2009;67:280-285.
- Jacono AA. A new classification of lip zones to customize injectable lip augmentation. *Arch Facial Plast Surg* 2008;10:25-29.
- Beer KR. Radiesse nodule of the lips from a distant injection site: report of a case and consideration of etiology and management. *J Drugs Dermatol* 2007;A6:846-847.
- Lemperle G, Rullan PP, Gauthier-Hazan N. Avoiding and treating dermal filler complications. *Plast Reconstr Surg* 2006;118(suppl 3):92S-107S.
- Lemperle G, Sadick NS, Knapp TR, Lemperle SM. Arte-Fill® permanent injectable for soft tissue augmentation: Part 2. Indications and applications. *Aesthetic Plast Surg* 2010;34:273-286.
- Braun M, Braun S. Nodule formation following lip augmentation using porcine collagen-derived filler. *J Drugs Dermatol* 2008;7:579-581.
- Fulton JE Jr, Porumb S, Caruso JC, Shitabata PK. Lip augmentation with liquid silicone. *Dermatol Surg* 2005;31:1577-1585.
- Edwards PC, Fantasia JE, Iovino R. Foreign body reaction to hyaluronic acid (Restylane): an adverse outcome of lip augmentation. *J Oral Maxillofac Surg* 2006;64:1296-1299.
- Dionyssopoulos A, Nikolis A, Patsatsi A, Sotiriadis D. Granulomas of the lips: a rare complication after injection of polylactic acid for aesthetic augmentation. *J Plast Reconstr Aesthetic Surg* 2007;60:1079-1080.
- Sankar V, McGuff HS. Foreign body reaction to calcium hydroxylapatite after lip augmentation. *J Am Dent Assoc* 2007;138:1093-1096.
- Lemperle G, Gauthier-Hazan N, Wolters M, Eisemann-Klein M, Zimmermann U, Duffy DM. Foreign body granulomas after all injectable dermal fillers: Part 1. Possible causes. *Plast Reconstr Surg* 2009;123:1842-1863.
- Schweiger ES, Riddle CC, Tonkovic-Capin V, Aires DJ. Successful treatment with injected hyaluronic acid in a patient with lip asymmetry after surgical correction of cleft lip. *Dermatol Surg* 2008;34:717-719.
- Duskova M, Kristen M. Augmentation by autologous adipose tissue in cleft lip and nose: final esthetic touches in clefts: Part 1. *J Craniofac Surg* 2004;15:478-481.
- Barnett JG, Barnett CR. Silicone augmentation of the lip. *Facial Plast Surg Clin North Am* 2007;15:501-512.
- Landau M. Lip augmentation and rejuvenation using a novel, porcine collagen-derived filler. *J Drugs Dermatol* 2008;7:236-240.

30. De Boule K, Swinberghe S, Engman M, Shoshani D. Lip augmentation and contour correction with a ribose cross-linked collagen dermal filler. *J Drugs Dermatol* 2009;8(suppl 3):1-8.
31. Seymour PE, Leventhal DD, Pribitkin EA. Lip augmentation with porcine small intestinal submucosa. *Arch Facial Plast Surg* 2008;10:30-33.
32. Niamtu J III. Advanta ePTFE facial implant in cosmetic facial surgery. *J Oral Surg* 2006;64:543-549.
33. Clymer MA. Evolution in techniques: lip augmentation. *Facial Plast Surg* 2007;23:21-26.
34. Redbord KP, Hanke CW. Expanded polytetrafluoroethylene implants for soft tissue augmentation: 5-year follow-up and literature review. *Dermatol Surg* 2008;34:735-743.
35. Niamtu J III. Experience and evaluation of a new saline-filled implant for cosmetic lip augmentation. *Am J Cosmet Surg* 2007;24:183-192.
36. Erguen SS, Cek DI, Baloglu H, Alguen Z, Onay H. Why is lip augmentation with autologous fat injection less effective in the vermilion border? *Aesthetic Plast Surg* 2001;25:350-352.
37. Lemperle G. What happens to free fat grafts after 20 years in patients who gain weight? *Plast Reconstr Surg* 2005;116:2035-2036.
38. Kaufman MR, Miller TA, Huang C, et al. Autologous fat transfer for facial recontouring: is there science behind the art? *Plast Reconstr Surg* 2007;119:2287-2296.
39. Trussler AP, Kawamoto HK, Wasson KL, et al. Upper lip augmentation: palmaris longus tendon as an autologous filler. *Plast Reconstr Surg* 2008;121:1024-1032.
40. Malaviya GN. Upper lip augmentation: palmaris longus as an autologous filler. *Plast Reconstr Surg* 2009;123:427-428.