

UCLA

UCLA Previously Published Works

Title

Disguised as Ovarian Tumor: A Rare Case of Uterine Abscess Due to Hypervirulent *Klebsiella pneumoniae* Infection.

Permalink

<https://escholarship.org/uc/item/0w87m16f>

Journal

Open forum infectious diseases, 9(7)

ISSN

2328-8957

Authors

Kamau, Edwin
Ranson, Elizabeth L
Zakhour, Mae
[et al.](#)

Publication Date

2022-07-01

DOI

10.1093/ofid/ofac321

Copyright Information

This work is made available under the terms of a Creative Commons Attribution-NonCommercial-NoDerivatives License, available at <https://creativecommons.org/licenses/by-nc-nd/4.0/>

Peer reviewed

Disguised as Ovarian Tumor: A Rare Case of Uterine Abscess Due to Hypervirulent *Klebsiella pneumoniae* Infection

Edwin Kamau,^{1,6} Elizabeth L. Ranson,² Mae Zakhour,³ Mark S. Mayo,² Ashlyn N. Sakona,² Paul R. Allyn III,² and Shangxin Yang^{1,6}

¹Department of Pathology and Laboratory Medicine, UCLA David Geffen School of Medicine, Los Angeles, California, USA, ²Division of Infectious Diseases, UCLA David Geffen School of Medicine, Los Angeles, California, USA, and ³Obstetrics and Gynecology, Gynecologic Oncology, UCLA David Geffen School of Medicine, Los Angeles, California, USA

Hypervirulent *Klebsiella pneumoniae* (hvKp) causes invasive infections in the community setting. We report a rare case of uterine abscess due to hvKp, which appeared as a large-sized ovarian tumor-like pelvic mass. A timely laboratory warning of possible hvKp prompted correct diagnosis and helped guide perioperative decision making, contributing to successful treatment.

Keywords. hvKp; hypervirulent *Klebsiella pneumoniae*; ovarian tumor; pelvic mass; uterine abscess.

Hypervirulent *Klebsiella pneumoniae* (hvKp) is a pathotype of *K pneumoniae* (Kp) that is more virulent than classic *K pneumoniae* (cKp) [1]. Hypervirulent Kp was first described in Asia where it is now endemic, and it has now spread globally and caused diverse and distinct clinical syndromes not commonly caused by cKp [1–5]. This infection is mostly acquired in the community by otherwise healthy individuals, with particular susceptibility in those with diabetes [1–4]. The classic presentation is hepatic abscess, which in a subset of patients can metastasize to other sites [1, 3]. As a primary or metastatic infection, hvKp can also cause nonhepatic abscesses, endophthalmitis, bacteremia, and soft tissue and bone infections, among other infectious sequelae [1, 3, 4]. Less commonly, hvKp may infect abdominal and pelvic organs including the prostate, kidneys, and spleen [3].

The prognosis for hvKp infection is poor with significant morbidity and mortality [1, 3]. Although hvKp is generally susceptible to most antimicrobial drugs, multidrug-resistant hvKp strains have emerged, significantly increasing the risk for mortality [3]. Management of hvKp infections requires adequate source control and potentially longer treatment depending on site and extent of infection [1, 3, 4]. In this study, we present the first reported case of a uterine abscess due to hvKp in a

woman with diabetes who presented with a large pelvic mass initially suspected to be tumor. A timely laboratory warning of possible hvKp prompted correct diagnosis that, coupled with a lack of malignant findings, helped guide perioperative decision making to preserve her normal-appearing right ovary and led to successful treatment and good outcome.

METHODS

Drug minimal inhibitory concentrations were determined by broth microdilution following CLSI guidelines per UCLA's established protocol for Gram-negative panel. Hypermucoviscosity phenotypic characteristics were determined by the string test [5]. Whole-genome sequencing (WGS) was performed on the hvKp isolates using MiSeq (Illumina, San Diego, CA) with the 2 × 250 base pair protocol, and the sequence files were submitted to the National Center for Biotechnology Sequence Read Archive (<https://www.ncbi.nlm.nih.gov/sra>) under BioProject accession number PRJNA729785. The sequences were analyzed using the CLC Genomics Workbench (QIAGEN, <https://www.qiagen.com>) and Geneious Prime (Biomatters, Auckland, New Zealand). The in silico detection of the K capsular serotype determined by the WZI gene cluster in the chromosome, the multilocus sequence types, and virulence factors was performed using BIGSdb (<http://bigsdb.pasteur.fr/klebsiella>). ResFinder was used to identify antimicrobial resistance genes, CSI Phylogeny was used to identify single-nucleotide polymorphisms, and PlasmidFinder was used to identify plasmid replicons (Center for Genomic Epidemiology, <http://www.genomicepidemiology.org/>).

Patient Consent Statement

This study has been exempted from institutional review board review by the UCLA Office of Human Research Protection Program. We obtained written consent from the patient.

Received 04 March 2022; editorial decision 21 June 2022; accepted 28 June 2022; published online 30 June 2022

Correspondence: Shangxin Yang, PhD, D(ABMM), UCLA Clinical Microbiology Laboratory, 11633 San Vicente Blvd., Los Angeles, CA 90049 (shangxinyang@mednet.ucla.edu).

Open Forum Infectious Diseases®

© The Author(s) 2022. Published by Oxford University Press on behalf of Infectious Diseases Society of America. This is an Open Access article distributed under the terms of the Creative Commons Attribution-NonCommercial-NoDerivs licence (<https://creativecommons.org/licenses/by-nc-nd/4.0/>), which permits non-commercial reproduction and distribution of the work, in any medium, provided the original work is not altered or transformed in any way, and that the work is properly cited. For commercial re-use, please contact journals.permissions@oup.com

<https://doi.org/10.1093/ofid/ofac321>

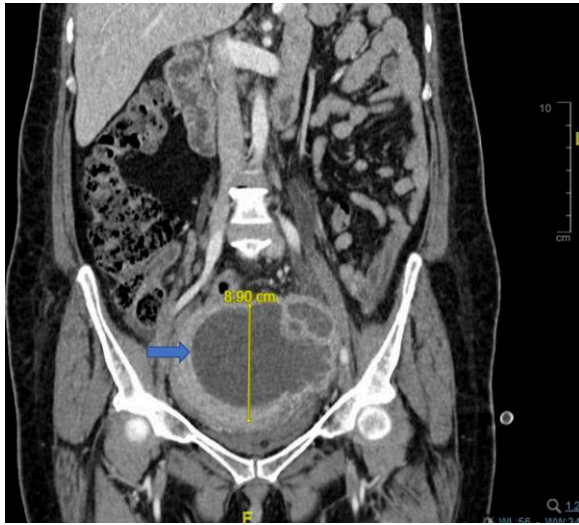


Figure 1. Computed tomography of the abdomen and pelvis with contrast showing multiseptated, predominantly cystic pelvic mass measuring up to 12.2 in its greatest dimension.

RESULTS

A 52-year-old woman from Mexico with a history of poorly controlled type 2 diabetes mellitus ([DM] hemoglobin A1c 12.3%) and hypertension presented to our emergency department (ED) with urinary retention and worsening pelvic pain in the setting of a pelvic mass concerning for ovarian malignancy. She did not report that a pelvic exam had been previously performed. Starting 4 months before her presentation to our institution, she presented several times to an outside facility with reports of pelvic pain and green vaginal discharge. Over the course of 3 months she was treated for 5 infections: her urine grew *Escherichia coli* treated with 10 days of cephalexin, then 2 weeks later grew Kp treated with 10 days of ciprofloxacin, then 6 weeks later again grew *E coli* treated with 14 days of cephalexin. Two weeks later she presented to an ED with severe left lower quadrant pain and was given vancomycin and piperacillin-tazobactam due to concern on imaging for tubo-ovarian abscess, but it was believed to be more consistent with a pelvic tumor. She was discharged with 2 weeks of metronidazole and doxycycline and referral to gynecologic oncology. Two weeks after this presentation, she again presented to their facility and was treated for a urinary tract infection (UTI) due to Kp with 10 days of cephalexin. Over the ensuing 3 weeks she developed worsening pelvic pain, requiring opiates, as well as difficulty urinating that ultimately progressed to complete retention, which prompted her to present to our hospital.

In the ED, she was initially afebrile, but she became febrile (101.3°F) a few hours later and was hypertensive. Admission laboratory results were notable for elevated white blood cells ($13.23 \times 10^3/\mu\text{L}$) and platelets ($607 \times 10^3/\mu\text{L}$), normocytic

anemia (hemoglobin 9.4 g/dL), hyperglycemia (glucose 437 mg/dL), and an elevated alkaline phosphatase (332 U/L). A Foley catheter was placed with drainage of 600 cc urine. Urine cultures were not sent before the initiation of antibiotics. Computed tomography showed a multiseptated 12.2-cm pelvic mass, but it was unclear whether it was uterine or adnexal (Figure 1), and it was favored to represent a left ovarian neoplasm. It also demonstrated left greater than right hydroureteronephrosis secondary to extrinsic compression from the pelvic mass. The hepatobiliary tree was unremarkable other than mild biliary dilation, consistent with her post-cholecystectomy state. She had no visual symptoms or meningismus. A transthoracic echocardiogram showed no valvular vegetations. Cefoxitin and doxycycline were started for possible pelvic infection. A pelvic exam was performed, which revealed copious yellow vaginal discharge, a normal appearing cervix, and a large immobile pelvic mass filling the posterior cul-de-sac of the pelvis, easily palpable on rectovaginal examination. A biopsy was not performed due to concern for spreading malignant cells through the peritoneal cavity. On hospital day 2, admission blood cultures grew Kp, and antibiotics were switched to ceftriaxone. On hospital day 7, she underwent exploratory laparotomy, modified radical hysterectomy with left salpingo-oophorectomy, right salpingectomy, extensive lysis of adhesions, and bilateral ureterolysis. At the time of surgery, there were dense adhesions and extensive fibrosis involving the uterine fundus, left adnexa, and left pelvic sidewall. The uterus contained a fluctuant mass that was embedded in the myometrium, with extension to the left uterine serosa. Upon gentle manipulation of the left adnexa to dissect it off the uterus, a cavity into the uterus was entered and 500 cc of purulent fluid was drained from the cavity within the myometrium. Pathological examination showed findings consistent with abscess involving the serosal surface and myometrium of the uterus without evidence of malignancy, as well as acute and chronic salpingitis. The confirmation of nonmalignancy on intraoperative frozen section examination, coupled with the microbiology laboratory finding of possible hvKp, guided the perioperative decision to only remove the left ovary, which showed extensive tissue abnormality due to chronic inflammatory process, and preserve the normal-appearing right ovary. Ceftriaxone was continued until hospital day 10 and she was discharged on day 14 with ciprofloxacin and metronidazole for 4 weeks from the date of surgery with full recovery.

Although with known limitations, clinical suspicion coupled with positive string test of Kp isolate has been used to establish putative hvKp infection [1, 5]. In our patient, Kp isolates from both blood and uterine abscess were hypermucoid with positive string test and were susceptible to all drugs tested (data not shown). The bacterium was closely related to a reference hvKp strain NTUH-K2044 (GenBank accession AP006725),

with high whole-genome coverage (99.2%) and pairwise identity ([PI] 98.6%). The genotype of the isolate was determined to be serotype K1, sequence type 23 (K1-ST23). In the chromosome, several hypervirulent genes and genomic islands were identified including K1 capsular gene cluster and siderophores enterobactin and yersiniabactin on an ICEKp10 mobile genetic element (Supplementary Figure 1). The hvKp isolates were also found to possess a plasmid (pVir-UCLA834) that is also highly similar to the NTUH-K2044 reference plasmid: pK2044 (GenBank accession number AP006726) with coverage of 100% and PI of 98.4% (Supplementary Figure 2). The pVir-UCLA834 plasmid carried the hvKp virulence genes including *iuc* (aerobactin), *iro* (salmochelin), *peg-344*, *rmpA*, and *rmpA2*. These data confirm the isolates as hvKp.

DISCUSSION

Although classically presenting as liver abscess with metastatic involvement [1, 3], hvKp can also cause primary extrahepatic disease with or without focal site of infection [6, 7]. In this study, we report the first case of hvKp extrahepatic invasive syndrome with the uterus as the focal, primary site of infection causing secondary bacteremia with imaging initially suggestive of malignancy. The patient endured progressively worsening pain for several months, and recurrent UTIs were unresolved with antibiotic treatment alone. At our hospital, the laboratory team recognized the presence of possible hvKp in blood cultures based on positive string test, then they notified the Infectious Disease team. Based on this information, suspicion was raised for primary abscess before surgery, which was confirmed intraoperatively.

Studies have suggested hvKp infection is preceded by gastrointestinal colonization and carriage in healthy individuals [1, 8], but it is not clear what triggers colonization to become an infection [3]. Uterine and other pelvic abscesses typically form as a sequela of pelvic inflammatory disease and can manifest with a pelvic mass, fever, lower abdominal-pelvic pain, and/or vaginal discharge [9]. It is notable that our patient did have thrombocytosis and anemia, which were consistent with chronic inflammation. Pelvic abscesses are typically caused by pathogens from ascending vaginal flora, or rarely from hematogenous spread [9]. In our patient, it is plausible that hvKp ascended from gastrointestinal colonization through the vaginal canal, eventually developing a uterine abscess, which led to the lower abdominal-pelvic pain, vaginal discharge, and bacteremia.

The string test has been used to identify hvKp but with known limitations: not all hvKp strains are hypermucoviscous, whereas some non-hvKp strains can be string test positive [5, 10]. More recently, molecular methods including polymerase chain reaction and WGS have been used to characterize

hvKp strains [10]. The best-characterized virulence genes conferring hypervirulent phenotype include *iuc* (a siderophore aerobactin), *iro* (a siderophore salmochelin), *peg-344* (a metabolic transporter of unknown function), and *rmpA* (a regulator involved in increased capsule production) [1]. These genes are mostly found in large plasmids or genetic islands in the chromosome. In a murine sepsis model, hvKp strains have been shown to be much more lethal than cKp strains, with a 50% lethal dose of $<10^3$ colony-forming units (CFUs) compared with $>10^6$ (CFU) for nonvirulent strains [11]. All of the hvKp virulence factors contribute significantly to the lethality of this strain and are associated with a hazard ratio of >25 for severe illness or death [10]. Sequence data confirmed the isolate from our study was K1-ST23, one of the most prevalent hvKp strains, and carried 1 large plasmid with all the virulence factors described above.

Early studies had suggested that Asians, Pacific Islanders, and Hispanics might be at increased risk for hvKp compared with other ethnicities or races [1, 3]. However, numerous studies do not support this observation. The first report of hvKp infection causing liver abscess with metastatic involvement (endophthalmitis and meningitis) in the United States was in a Black man from Little Rock, Arkansas who had DM [12]. Since then, a few dozen cases have been reported in the United States [7, 13, 14], including a recent (2015–2018) surveillance study in a New York City hospital that reported 462 invasive Kp infection cases, 17 (3.7%) of which were with a hypervirulent strain [14]. Of these, 9 (53%) were in Hispanic patients, and only 2 (14%) were in Asians, and the others were White (5) or Black (1). Similar to other studies, 6 (35%) of these patients had DM, and 8 (47%) had hypertension, with 4 (24%) having both [14]. Ethnicity or race should not be the only important risk factor used in raising clinical suspicion and the diagnosis of hvKp infection.

CONCLUSIONS

In conclusion, our case highlights the clinical challenges of diagnosing and treating hvKp infection in nonendemic settings. Now that it is evident that hvKp has spread globally, epidemiological and surveillance studies will become increasingly important to inform specific countries, regions, and hospitals about the prevalence of hvKp in their patient populations. Most importantly, laboratorians and clinicians in nonendemic settings must become increasingly aware and recognize hvKp infections to ensure prompt diagnosis and proper treatment. In settings where hvKp molecular testing is not readily available, a Kp infection should prompt concern for presence of abscess with appropriate workup, particularly in community-dwelling, diabetic patients. Our case also highlights the importance of a multidisciplinary effort for the effective diagnosis and management of hvKp infections and the

value of timely laboratory reporting of suspected hvKp presenting with hypermucoid phenotype.

Supplementary Data

Supplementary materials are available at *Open Forum Infectious Diseases* online. Consisting of data provided by the authors to benefit the reader, the posted materials are not copyedited and are the sole responsibility of the authors, so questions or comments should be addressed to the corresponding author.

Acknowledgments

We thank the UCLA Clinical Microbiology Laboratory for their technical support.

Potential conflict of interest. All authors: No reported conflicts.

All authors have submitted the ICMJE Form for Disclosure of Potential Conflicts of Interest.

References

1. Russo TA, Marr CM. Hypervirulent *Klebsiella pneumoniae*. *Clin Microbiol Rev* **2019**; 32:e00001-19. doi: 10.1128/CMR.00001-19.
2. Liu YC, Cheng DL, Lin CL. *Klebsiella pneumoniae* liver abscess associated with septic endophthalmitis. *Arch Intern Med* **1986**; 146:1913-6. doi:10.1001/archinte.1986.00360220057011
3. Choby JE, Howard-Anderson J, Weiss DS. Hypervirulent *Klebsiella pneumoniae* —clinical and molecular perspectives. *J Intern Med* **2020**; 287:283-300. doi: 10.1111/joim.13007.
4. Fang CT, Lai SY, Yi WC, Hsueh PR, Liu KL, Chang SC. *Klebsiella pneumoniae* genotype K1: an emerging pathogen that causes septic ocular or central nervous system complications from pyogenic liver abscess. *Clin Infect Dis* **2007**; 45: 284-93. doi: 10.1086/519262.
5. Fang CT, Chuang YP, Shun CT, Chang SC, Wang JT. A novel virulence gene in *Klebsiella pneumoniae* strains causing primary liver abscess and septic metastatic complications. *J Exp Med* **2004**; 199:697-705. doi: 10.1084/jem.20030857.
6. Ku Y-H, Chuang Y-C, Yu W-L. Clinical spectrum and molecular characteristics of *Klebsiella pneumoniae* causing community-acquired extrahepatic abscess. *J Microbiol Immunol Infect* **2008**; 41:311-7.
7. Prokesch BC, TeKippe M, Kim J, Raj P, TeKippe EM, Greenberg DE. Primary osteomyelitis caused by hypervirulent *Klebsiella pneumoniae*. *Lancet Infect Dis* **2016**; 16:e190-5. doi:10.1016/S1473-3099(16)30021-4
8. Fung CP, Lin YT, Lin JC, et al. *Klebsiella pneumoniae* in gastrointestinal tract and pyogenic liver abscess. *Emerg Infect Dis* **2012**; 18:1322-5. doi: 10.3201/eid1808.111053.
9. Inal ZO, Inal HA, Gorkem U. Experience of tubo-ovarian abscess: a retrospective clinical analysis of 318 patients in a single tertiary center in middle Turkey. *Surg Infect (Larchmt)* **2018**; 19:54-60. doi: 10.1089/sur.2017.215.
10. Russo TA, Olson R, Fang CT, et al. Identification of biomarkers for differentiation of hypervirulent *Klebsiella pneumoniae* from classical *K. pneumoniae*. *J Clin Microbiol* **2018**; 56:e00776-18. doi: 10.1128/JCM.00776-18.
11. Nassif X, Sansonetti PJ. Correlation of the virulence of *Klebsiella pneumoniae* K1 and K2 with the presence of a plasmid encoding aerobactin. *Infect Immun* **1986**; 54:603-8. doi: 10.1128/iai.54.3.603-608.1986.
12. Saccette M. *Klebsiella pneumoniae* liver abscess, endophthalmitis, and meningitis in a man with newly recognized diabetes mellitus. *Clin Infect Dis* **1999**; 29: 1570-1. doi: 10.1086/313539.
13. McCabe R, Lambert L, Frazee B. Invasive *Klebsiella pneumoniae* infections, California, USA. *Emerg Infect Dis* **2010**; 16:1490-1. doi: 10.3201/eid1609.100386.
14. Parrott AM, Shi J, Aaron J, Green DA, Whittier S, Wu F. Detection of multiple hypervirulent *Klebsiella pneumoniae* strains in a New York City hospital through screening of virulence genes. *Clin Microbiol Infect* **2021**; 27:583-9. doi: 10.1016/j.cmi.2020.05.012.