

# UC San Diego

## UC San Diego Previously Published Works

### Title

Alternating wide complex tachycardia after surgical aortic valve replacement

### Permalink

<https://escholarship.org/uc/item/0tr2c7qd>

### Journal

Indian Pacing and Electrophysiology Journal, 21(3)

### ISSN

2590-1753

### Authors

Darden, Douglas  
Eskander, Michael  
Feld, Gregory K

### Publication Date

2021-05-01

### DOI

10.1016/j.ipej.2021.02.001

Peer reviewed



Contents lists available at ScienceDirect

# Indian Pacing and Electrophysiology Journal

journal homepage: [www.elsevier.com/locate/IPEJ](http://www.elsevier.com/locate/IPEJ)

## Alternating wide complex tachycardia after surgical aortic valve replacement

Douglas Darden<sup>a, \*</sup>, Michael Eskander<sup>a</sup>, Gregory K. Feld<sup>a</sup><sup>a</sup> Division of Cardiology, Department of Medicine, Cardiovascular Institute, University of California San Diego, United States

### ARTICLE INFO

#### Article history:

Received 23 November 2020

Received in revised form

17 January 2021

Accepted 1 February 2021

Available online 6 February 2021

#### Keywords:

Ventricular tachycardia

Bundle branch reentry

Aortic valve replacement

### ABSTRACT

A 51-year-old male developed recurrent episodes of palpitations and pre-syncope after surgical aortic valve replacement. Electrocardiograms after surgery revealed a wide complex tachycardia with alternating left bundle branch and right bundle branch block morphologies. An electrophysiology study (EPS) demonstrated typical bundle branch reentry ventricular tachycardia (BBRVT) treated successfully with right bundle ablation. We demonstrate the key diagnostic features of BBRVT on EPS, describe the circuit of BBRVT with explanation of the HV pseudointerval, and highlight the association of BBRVT and valve replacement.

Copyright © 2021, Indian Heart Rhythm Society. Production and hosting by Elsevier B.V. This is an open access article under the CC BY-NC-ND license (<http://creativecommons.org/licenses/by-nc-nd/4.0/>).

### 1. Case

A 51-year-old male presented to the emergency department with persistent palpitations and pre-syncope. The patient had a history of hypertension and bicuspid aortic stenosis with an ascending aortic aneurysm and had undergone mechanical aortic valve replacement and graft replacement one month before presentation. Prior to surgery, an echocardiogram was notable for severe aortic stenosis with preserved left ventricular ejection fraction (LVEF) and a coronary angiogram revealed no significant coronary artery disease. On arrival, his blood pressure was 100/65 mmHg and heart rate 198 beats per min. A 12-lead ECG showed a monomorphic wide complex tachycardia (WCT) with right bundle branch block (RBBB) morphology (Fig. 1A). Pre-syncope symptoms persisted with hypotension, and the patient subsequently underwent successful cardioversion with a 200J transthoracic shock. No adenosine, verapamil, or anti-arrhythmic drugs were given prior to cardioversion. An electrocardiogram (ECG) after cardioversion

**Abbreviations:** LVEF, left ventricular ejection fraction; WCT, wide complex tachycardia; RBBB, right bundle branch; ECG, electrocardiogram; LBBB, left bundle branch block; AV, atrioventricular; AVNRT, atrioventricular nodal reentrant tachycardia; JT, junctional tachycardia; EPS, electrophysiology study; HPS, His-Purkinje system; BBRVT, bundle branch reentry ventricular tachycardia.

\* Corresponding author. 9452 Medical Center Dr., La Jolla, CA, 92037, United States.

E-mail address: [djdarden@ucsd.edu](mailto:djdarden@ucsd.edu) (D. Darden).

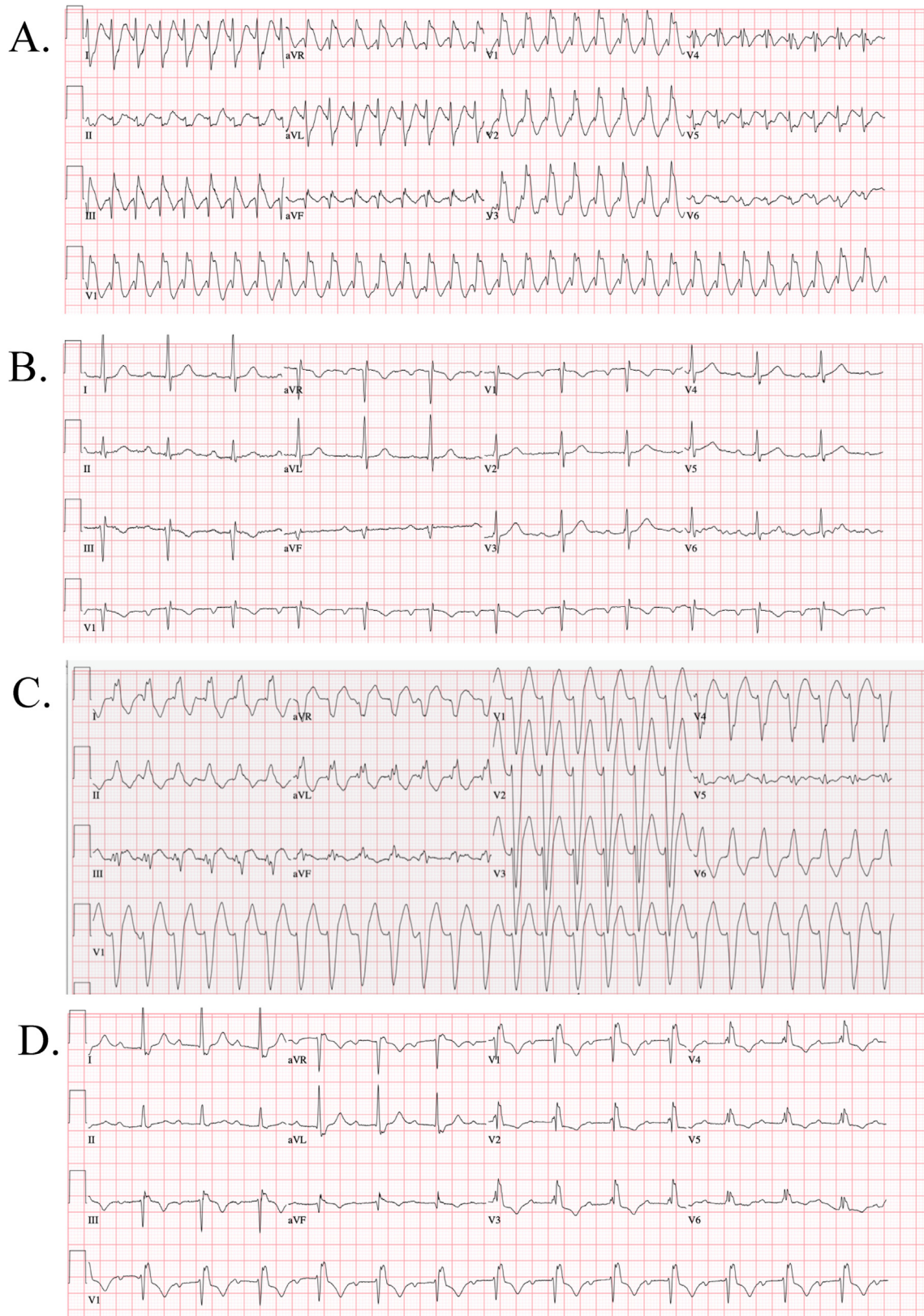
Peer review under responsibility of Indian Heart Rhythm Society.

<https://doi.org/10.1016/j.ipej.2021.02.001>

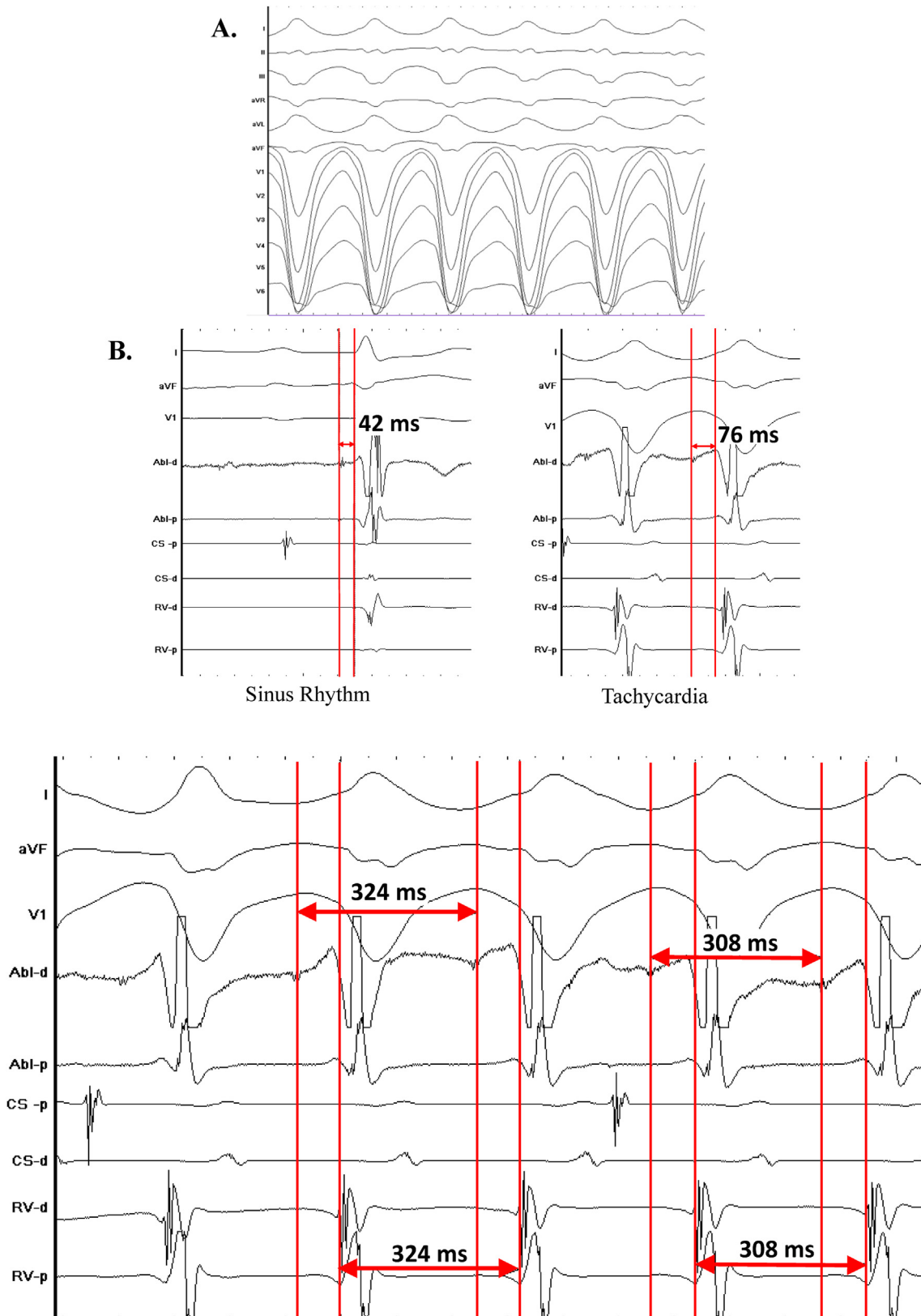
0972-6292/Copyright © 2021, Indian Heart Rhythm Society. Production and hosting by Elsevier B.V. This is an open access article under the CC BY-NC-ND license (<http://creativecommons.org/licenses/by-nc-nd/4.0/>).

showed normal sinus rhythm with prolonged PR interval (246 ms) and incomplete RBBB (Fig. 1B). Echocardiogram demonstrated preserved EF and normally functioning prosthetic aortic valve with mean gradient 8 mmHg. On review of previous ECGs, the PR interval and QRS duration were normal prior to surgery. Immediately after surgery, the ECG showed sinus rhythm with prolonged PR interval and LBBB. On post-operative day two, the patient developed a WCT with LBBB morphology at a rate of 156 bpm that spontaneously terminated after approximately 10 minutes (Fig. 1C). It was presumed to be a supraventricular tachycardia with LBBB aberrancy, for which the patient was started on low-dose beta blocker, although he did not continue it following discharge. On the day of discharge the ECG revealed sinus rhythm, prolonged PR interval, and a similar RBBB pattern as later seen in the presenting WCT (Fig. 1D). What is the mechanism and treatment of this tachycardia?

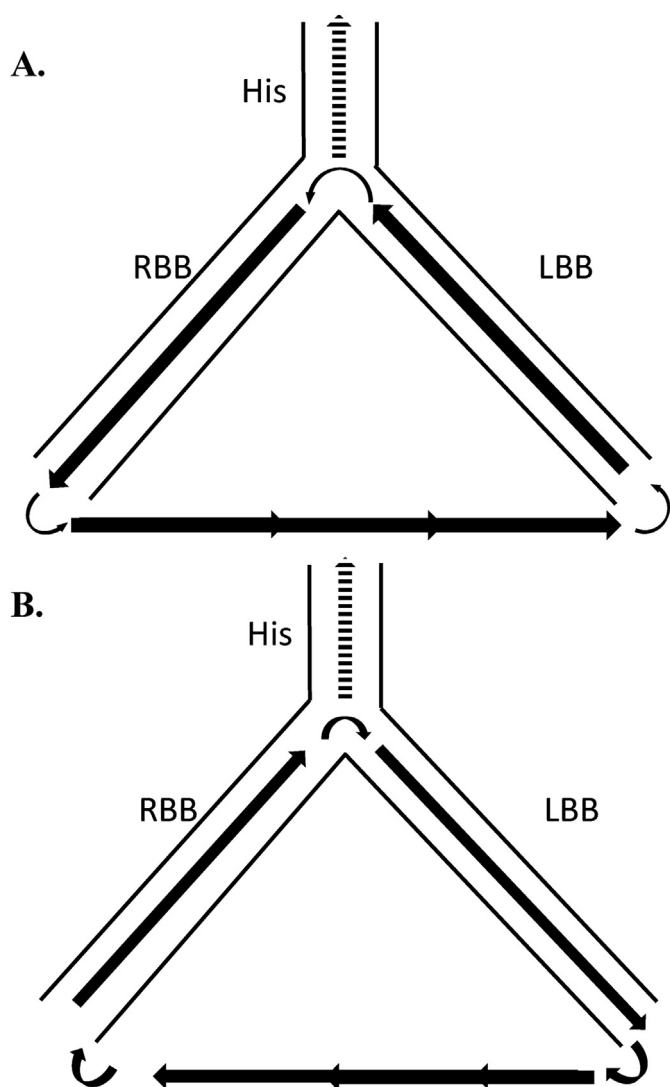
The differential diagnosis for WCT generally includes ventricular tachycardia (VT), supraventricular tachycardia (SVT) with aberrancy or pre-existing bundle branch block, and antidromic atrioventricular reentrant tachycardia (AVRT). On careful inspection of Fig. 1A, AV dissociation is present, most evident in lead II. The presence of atrioventricular (AV) dissociation excludes AVRT, while VT and other types of SVT with aberrancy or pre-existing bundle branch block still remain, such as atrioventricular nodal reentrant tachycardia (AVNRT) or junctional tachycardia (JT). Given the alternating BBB patterns and symptomatic WCT, he was referred for electrophysiology study (EPS) and pacemaker implantation on the day of hospital presentation. No medications were initiated prior to



**Fig. 1.** A. Presenting ECG: WCT with RBBB morphology. B. Post-cardioversion: NSR, prolonged PR interval, and incomplete RBBB. C. Post-SAVR: WCT with LBBB morphology. D. Day of discharge after SAVR: NSR, prolonged PR interval with RBBB morphology.



**Fig. 2.** A. 12-lead ECG of WCT induced during EPS. LBBB-type morphology with negative concordance in the precordial leads and left superior axis. B. Consistent His bundle potential was not obtained. RB potential (as measured on Abl-D) to V interval during sinus rhythm measures 42 ms, while the RB-V is longer during tachycardia (78 ms). C. Changes in the RB-RB interval precedes the changes in the V-V interval.



**Fig. 3.** Schematic representation of BBRVT. **A.)** During LBBB-BBRVT, the impulse is conducted anterogradely through the RBB and retrogradely through the LBB. **B.)** During RBBB-BBRVT, the activation pattern is reversed. Note the His is activated retrogradely and not involved in the BBRVT circuit.

the EPS.

At baseline, the patient was in normal sinus rhythm with evidence of conduction delay in the His-Purkinje system (HPS) with a prolonged HV interval of 70 ms. A consistent right-sided His bundle potential recording could not be obtained. However, a proximal right bundle (RB) potential recording was obtained via a sensor-enabled ablation catheter. Ventricular programmed extra-stimulation repeatedly induced a WCT at a cycle length of 310 ms with a LBBB morphology, left superior axis, and negative concordance in the precordial leads (Fig. 2A). There was clear evidence of AV dissociation during tachycardia with earliest activation at the RV apex, ruling out atrioventricular reentrant tachycardia. The remaining possibilities included ventricular tachycardia and the rare possibilities of JT with retrograde block and aberrancy, AVNRT with upper common pathway block and aberrancy, and antidromic reentrant tachycardia using a nodofascicular or nodoventricular

pathway with retrograde block. Attempts at pacing entrainment from the right ventricular (RV) apex repeatedly terminated the tachycardia, as did His-refractory premature ventricular extra-stimuli, ruling against AVNRT and JT. Furthermore, there was no evidence of dual atrioventricular nodal physiology during atrial pacing. Intravenous adenosine failed to terminate the tachycardia ruling out a nodofascicular or nodoventricular tachycardia. During tachycardia, there was a 1:1 relationship with the RB potential and ventricular electrograms and the RB-V interval was longer compared to sinus rhythm (Fig. 2B). The onset of ventricular depolarization was preceded by the RB potential and changes in the RB-RB interval preceded changes in the V–V interval, indicating that His-Purkinje activation drives the tachycardia (Fig. 2C). The findings were consistent with bundle branch reentrant ventricular tachycardia (BBRVT) with a counterclockwise circuit, the most common form of macro-reentry using the HPS. The ablation catheter was then advanced into the RV, where a RB potential was identified and radiofrequency energy was applied. The incomplete RBBB pattern on ECG at baseline then became a complete RBBB, after which BBRVT was no longer inducible. There was no evidence of AV block after ablation, however given previous evidence of alternating bundle branch block, the patient received a dual-chamber pacemaker. At six-month follow-up our patient had no recurrence of VT on routine pacemaker interrogation.

## 2. Discussion

BBRVT is an uncommon, potentially life-threatening form of macro-reentrant VT, incorporating both bundle branches and the intervening septal ventricular myocardium into a macro-reentry circuit. Patients typically present with heart rates above 200 bpm, and with pre-syncope, syncope or sudden death, particularly in those with underlying structural heart disease. BBRVT is seen in patients with HPS dysfunction, such as those with dilated cardiomyopathy, myotonic dystrophy, or valvular heart disease following transcatheter or surgical aortic valve replacement (SAVR) [1,2]. BBRVT typically occurs within a month after SAVR and most have preserved LVEF. It is thought that valve implantation causes conduction disturbances (i.e. slow conduction) within the HPS facilitating reentry due to its close proximity to the valvular annulus.

BBRVT may be misdiagnosed as SVT with aberrancy given typical left or right bundle branch block morphology. The patient had clinical presentations of both typical (counterclockwise, LBBB pattern) and suspected atypical (clockwise, RBBB pattern) BBRVT. LBBB pattern is most commonly seen in BBRVT, as the activation wave front propagates anterogradely down the RBB, followed by transeptal myocardial conduction, retrograde conduction using the LBB, and finally reentering the conduction system at the LB and RB Purkinje fiber-myocardial junction located infra-Hisian (Fig. 3A). Since the RB refractory period is usually longer than that of the LB, RV extrastimulus pacing can lead to retrograde conduction delay and block in the RBB, followed by impulse propagation retrogradely up the LBB. The atypical form of BBRVT presents with a RBBB pattern when the activation pattern is reversed, as suspected to have occurred in the presenting arrhythmia (Fig. 3B). RBBB-BBRVT can be induced through LV pacing or incremental atrial pacing, although atrial PES pacing did not induce tachycardia in the present case [3]. Of note, atypical BBRVT was not induced on EPS, thus concomitant interfascicular reentrant VT was not completely ruled out. Interfascicular VT can be distinguished from BBRVT usually with a shorter HV interval during VT compared to sinus rhythm and by demonstrating that the RB is not part of the circuit. Several

reports have demonstrated inducibility of interfascicular VT immediately after RBB ablation [4,5]. However, RBBB-WCT was not induced before or after ablation in the present case. Therefore, further ablation of the anterior or posterior fascicle was not performed.

It is important to note that the His bundle is not part of the BBRVT circuit. The HV interval during BBRVT represents the retrograde conduction time to the His bundle via the turnaround site at the proximal bundle branches plus the antegrade conduction time back to the turnaround site and then to the ventricular exit site, and thus represents a pseudo-interval. Hence, the relationship between the HV interval in sinus rhythm and tachycardia is unreliable, as it may be longer in tachycardia or sinus rhythm in some cases. On the other hand, the RB-V interval has been shown to consistently prolong during tachycardia, perhaps contributing to the maintenance of BBRVT [6].

The key diagnostic features of BBRVT include: 1) QRS morphology exhibiting typical BBB pattern similar to sinus rhythm with AV dissociation; 2) LB-HB-RB activation sequence in typical BBRVT or RB-HB-LB in atypical BBRVT; 3) variations in the H–H, RB–RB, or LB–LB interval precedes changes in the V–V interval; and 4) non-inducible tachycardia after RBB ablation. Entrainment from the RV apex is another diagnostic pacing maneuver in BBRVT with LBBB pattern that proves useful when a stable His cannot be recorded. A post-pacing interval minus tachycardia cycle length (PPI-TCL) < 30 ms suggests BBBRT and excludes AVNRT and JT [7]. Radiofrequency ablation of the RB is considered first-line therapy with high long-term success rates [8].

The present case describes a rare case of BBRVT with both typical and atypical forms suspected to have observed clinically with curative ablation of the right bundle branch following SAVR in a patient with preserved ejection fraction.

#### Funding

None.

#### Declaration of competing interest

Dr. Darden and Dr. Eskander have no disclosures to report. Dr. Feld is Director of the Cardiac Electrophysiology Fellowship Training Program, which receives fellowship stipend support from Medtronic, Abbott, Boston Scientific, Biosense Webster, and Biotronik.

#### References

- [1] Caceres J, Jazayeri M, McKinnie J, Avitall B, Denker ST, Tchou P, Akhtar M. Sustained bundle branch reentry as a mechanism of clinical tachycardia. *Circulation* 1989;79:256–70.
- [2] Narasimhan C, Jazayeri MR, Sra J, Dhala A, Deshpande S, Biehl M, Akhtar M, Blanck Z. Ventricular tachycardia in valvular heart disease: facilitation of sustained bundle-branch reentry by valve surgery. *Circulation* 1997;96:4307–13.
- [3] Mizusawa Y, Sakurada H, Nishizaki M, Ueda-Tatsumoto A, Fukamizu S, Hiraoka M. Characteristics of bundle branch reentrant ventricular tachycardia with a right bundle branch block configuration: feasibility of atrial pacing. *Europace* 2009;11:1208–13.
- [4] Blanck Z, Sra J, Akhtar M. Incessant interfascicular reentrant ventricular tachycardia as a result of catheter ablation of the right bundle branch: case report and review of the literature. *J Cardiovasc Electrophysiol* 2009;20:1279–83.
- [5] Berger RD, Orias D, Kasper EK, Calkins H. Catheter ablation of coexistent bundle branch and interfascicular reentrant ventricular tachycardias. *J Cardiovasc Electrophysiol* 1996;7:341–7.
- [6] Chen H, Shi L, Yang B, Ju W, Zhang F, Yang G, Gu K, Li M, Cao K, Ouyang F, Chen M. Electrophysiological characteristics of bundle branch reentry ventricular tachycardia in patients without structural heart disease. *Circ Arrhythm Electrophysiol* 2018;11:e006049.
- [7] Merino JL, Peinado R, Fernandez-Lozano I, Lopez-Gil M, Arribas F, Ramirez LJ, Echeverria IJ, Sobrino JA. Bundle-branch reentry and the postpacing interval after entrainment by right ventricular apex stimulation: a new approach to elucidate the mechanism of wide-QRS-complex tachycardia with atrioventricular dissociation. *Circulation* 2001;103:1102–8.
- [8] Pathak RK, Fahed J, Santangeli P, Hyman MC, Liang JJ, Kubala M, Hayashi T, Muser D, Pathak M, Kochar A, Castro SA, Garcia FC, Frankel DS, Supple GE, Schaller RD, Lin D, Riley MP, Deo R, Epstein AE, Zado ES, Dixit S, Callans DJ, Marchlinski FE. Long-term outcome of catheter ablation for treatment of bundle branch Re-entrant tachycardia. *JACC Clin Electrophysiol* 2018;4:331–8.