

UC Irvine

UC Irvine Previously Published Works

Title

Female phenotype associated with XY karyotype: report of a case with gonadal dysgenesis.

Permalink

<https://escholarship.org/uc/item/0sf5741m>

Journal

South African Medical Journal, 43(46)

ISSN

2078-5135

Authors

Smith, M
Pepler, WJ

Publication Date

1969-11-15

Copyright Information

This work is made available under the terms of a Creative Commons Attribution License, available at <https://creativecommons.org/licenses/by/4.0/>

Peer reviewed

FEMALE PHENOTYPE ASSOCIATED WITH XY KARYOTYPE: REPORT OF A CASE WITH GONADAL DYSGENESIS*

MOYRA SMITH, M.B., CH.B., M.SC. AND W. J. PEPLER, M.D., D.SC., Pretoria

The 3 conditions that should be considered in the differential diagnosis of individuals of predominantly female phenotype who prove to be chromatin negative and to have an XY karyotype are male pseudohermaphroditism, testicular feminization and gonadal dysgenesis. The clinical findings in the patient reported here suggested the diagnosis of gonadal dysgenesis and this diagnosis was subsequently confirmed by gonadal histology.

CASE REPORT

The patient, who had been reared as a female, presented at the age of 25 years with primary amenorrhoea. On physical examination she was found to be of short stature (4 ft 11 in.). There was no breast development and no axillary or pubic hair was present. The vagina was small and ended in a hypoplastic cervix. The uterus was not palpable.

Buccal smears were taken from the patient but no typical Barr body was found in 100 cells examined. Subsequently 20 cells derived from peripheral blood cultures were examined and found to have an XY karyotype.

At laparotomy the uterus was found to be very small but symmetrical, the fallopian tubes were extremely thin, and in the normal position of the ovaries gonadal streaks were present. Biopsy specimens were taken from each of the streaks for histological examination and culture. Ten cells derived from the cultures of each of the specimens were examined and found to have a 46 XY karyotype (Fig. 1).

Sections of the specimen from the left gonad taken at various levels revealed vascular connective tissue and occasional islets of hilar cells, but no ovarian stroma or follicles were observed.

Sections of the right gonad showed a thin layer of ovarian stroma (Fig. 2), rete ovarii and groups of hilar cells (Fig. 3) but no germ cell elements.

DISCUSSION

Although the external genitalia in patients with male pseudohermaphroditism may, on superficial examination, present a complete female appearance as a result of the prominent skinfolds resembling labia majora, Overzier¹ considered that careful inspection will disclose the intersexual condition. A phallus usually replaces the clitoris and a prepuce partially covers the glans. The urethral and vaginal openings may be separate or common. The genital duct differentiation may be male or female. The testes are usually intra-abdominal, although seldom in the position of normal ovaries. Histology of the testes shows good development of Leydig cells and other medullary components.²

The incomplete masculinization of the external genitalia and internal sex ducts in this condition cannot be explained by the morphologic structure of the testes. Wilkins² con-

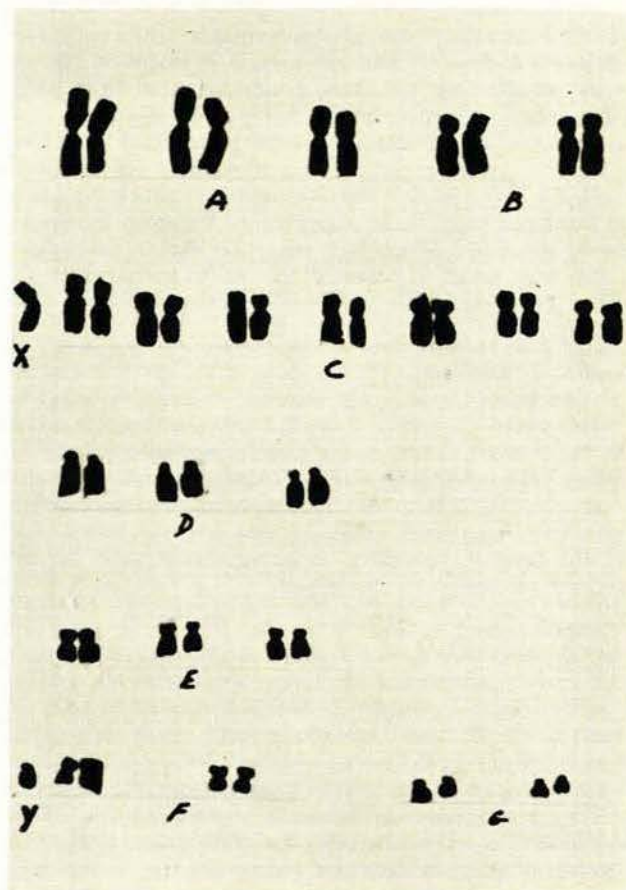


Fig. 1. Karyotype of cell derived from biopsy specimen of right gonad.

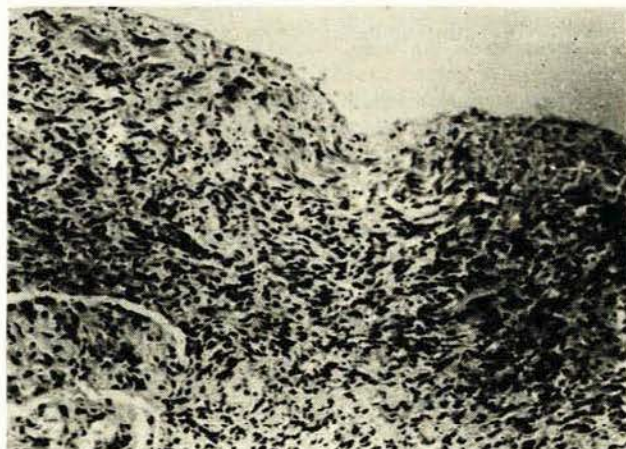


Fig. 2. Superficial part of right gonad showing ovarian stroma (H & E \times 250).

*Date received: 13 March 1969.

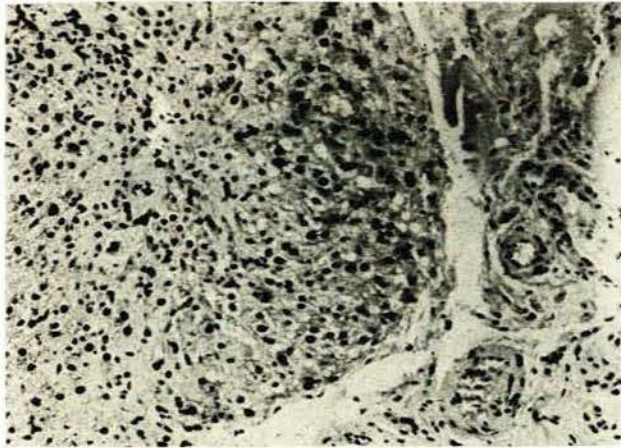


Fig. 3. Nodule of hilar cells in same gonad (H & E \times 250).

considers the condition to be functional disturbance of the foetal testes, with inadequate formation of male organizing substances.

Overzier¹ considers the condition of testicular feminization to constitute a separate entity distinct from other forms of male pseudohermaphroditism. Hauser² has defined testicular feminization as 'a form of intersex characterized by female breasts, completely female external genitalia but without a uterus and with male gonadal and chromosomal sex'.

Testicular feminization is usually diagnosed after puberty when a female of average or tall stature presents with primary amenorrhoea and sometimes hypertrophic breast development. Notable clinical features are the blind ending of the vagina and scantiness of vulval hair.^{3,4} Inguinal herniae containing testes may occur.

Histological examination of the gonads in testicular feminization shows narrow seminiferous tubules frequently without a lumen. Usually only occasional Sertoli cells are seen and spermatogonia seldom occur, although the presence of sperm has been reported by a few authors.⁵ Leydig cells are usually well developed.

The basic defect in this condition is currently thought to be a target-organ unresponsiveness to circulating androgens.⁶

Hauser² has defined gonadal dysgenesis as 'a condition that is characterized by the absence of germ cells and the development of female external and internal genital organs (tubes, uterus and vagina). The gonads are usually represented by remnants of tissue, e.g. ovarian stroma, rete structures and hilus cells that do not contain any germ cells. The internal genital organs are usually very hypoplastic and the external genitalia infantile.' Gonadal dysgenesis is classically seen in association with sex chromosomal anomalies where it is usually accompanied by somatic abnormalities which may include short stature, webbed neck, shield chest, cubitus valgus, congenital lymphoedema of the feet, cutaneous naevi and congenital cardiac anomalies.⁷ A number of structural abnormalities of the X chromosome have been found in association with gonadal dysgenesis and variable occurrence of Turner stigmata.⁷ Such abnormalities include iso-chromosomes of the long or short arm of the X chromosome, deleted X

chromosome and ring X chromosome. Loss of the short arm of the X chromosome appears to be the important factor in the aetiology of Turner stigmata.⁷

So-called pure gonadal dysgenesis occurs in patients with apparently normal or XY chromosomes. The abnormal sex differentiation in these patients coincides with the castration experiments of Jost⁸ and is therefore considered to indicate primary failure of the foetal gonad.⁹ Jost demonstrated that castration of male rabbit foetuses before the stage of differentiation of the genital tract led to development of a female genital tract. He therefore concluded that a normal functioning testis was necessary for the development and differentiation of the mesonephric duct (Wolffian duct), repression of development of the para-mesonephric duct (Mullerian duct) and male differentiation of the urogenital sinus and external genitalia.

The precise aetiology of failure of the foetal gonad is essentially unknown at present. The primordial germ cells have, however, been shown to be of prime importance in the development of the gonad. Experimental work in mice has shown that if germ cells are destroyed before or during their migration from the yolk-sac to the gonadal ridges, the result is atrophic gonads not unlike the streak gonads of gonadal dysgenesis.¹⁰ In their work, Hemsworth and Jackson¹⁰ used bisulphan to destroy germ cells. Ferguson-Smith⁷ suggested that sex chromosomal abnormalities, e.g. sex chromomonosomy, the XXY condition, may lead to germ-cell destruction. Pure gonadal dysgenesis is encountered in the presence of apparently normal sex chromosomes, however, and one must therefore conclude that there are other influences beside karyotype which may lead to germ-cell destruction. One may reasonably suppose that the primordial germ cells which are required to migrate from the yolk-sac along the wall of the gut and thence to the gonadal ridges of the medial aspect of the mesonephros would be more sensitive to external noxious influence than most embryonic cells. This would possibly explain the occurrence of pure gonadal dysgenesis and its direct consequences, in individuals in whom no other phenotypic abnormalities can be demonstrated.

SUMMARY

A patient who presented with primary amenorrhoea had infantile external genitalia and there was lack of breast development. The karyotype in blood cultures and in cultures of material obtained from gonadal biopsy was 46 XY. Histological studies of gonadal biopsies revealed gonadal dysgenesis. The diagnoses which must be considered in individuals where a female phenotype is associated with a male karyotype include male pseudohermaphroditism, testicular feminization and gonadal dysgenesis. These 3 conditions are discussed in terms of clinical findings, gonadal histology and aetiology.

REFERENCES

- Overzier, C., ed. (1963): *Intersexuality*, p. 235. London: Academic Press.
- Wilkins, L. (1960): *Pediatrics*, **26**, 846.
- Hauser, G. A. in Overzier, C., ed. (1963): *Intersexuality*, p. 255. London: Academic Press.
- Dewhurst, C. J. (1967): *J. Obstet. Gynaec. Brit. Cwlth.*, **74**, 353.
- Selle, W. A. (1965): *Testicular Feminization*, p. 71. Springfield, Ill.: Charles C. Thomas.
- Hauser, G. A. in Overzier, C., ed. (1963): *Op. cit.*³ p. 298.
- Ferguson-Smith, M. A. (1965): *J. Med. Genet.*, **2**, 142.
- Jost, A. in Jones, H. and Scott, W. W., eds. (1958): *Hermaphroditism, Genital Anomalies and Related Disorders*, p. 15. Baltimore: Williams & Wilkins.
- Ferguson-Smith, M. A. in Hubble, D., ed. (1969): *Paediatric Endocrinology*, chapt. 7. Oxford: Blackwell Scientific Publications (in press).
- Hemsworth, B. N. and Jackson, H. (1963): *J. Reprod. Fertil.*, **5**, 187.