

# UC San Diego

## UC San Diego Previously Published Works

### Title

MR imaging of overuse injuries in the skeletally immature gymnast: spectrum of soft-tissue and osseous lesions in the hand and wrist

### Permalink

<https://escholarship.org/uc/item/0r95k3dh>

### Journal

Pediatric Radiology, 39(12)

### ISSN

1432-1998

### Authors

Dwek, Jerry R.  
Cardoso, Fabiano  
Chung, Christine B.

### Publication Date

2009-12-01

### DOI

10.1007/s00247-009-1428-x

Peer reviewed

# MR imaging of overuse injuries in the skeletally immature gymnast: spectrum of soft-tissue and osseous lesions in the hand and wrist

Jerry R. Dwek · Fabiano Cardoso · Christine B. Chung

Received: 12 August 2009 / Revised: 18 September 2009 / Accepted: 24 September 2009 / Published online: 22 October 2009  
© The Author(s) 2009. This article is published with open access at Springerlink.com

## Abstract

**Background** In the pediatric gymnast, stress-related physal injuries have been well described with characteristic imaging findings. However, a spectrum of overuse injuries, some rarely reported in the literature, can be encountered in the gymnast's hand and wrist.

**Objective** To demonstrate the MR appearance of a spectrum of overuse injuries in the skeletally immature wrist and hand of pediatric gymnasts.

**Materials and methods** A total of 125 MR exams of the hand and wrist in skeletally immature children were performed at our institution during a 2-year period. Clinical histories were reviewed for gymnastics participation. MR studies of that subpopulation were reviewed and abnormalities tabulated.

**Results** Of the MR studies reviewed, ten gymnasts were identified, all girls age 12–16 years (mean age 14.2 years) who presented with wrist or hand pain. Three of these children had bilateral MR exams. Abnormalities included chronic physal injuries in three children. Two girls exhibited focal lunate osteochondral defects. Triangular fibrocartilage tears were present in three girls, one of whom had a scapholunate ligament tear. Two girls manifested metacarpal head flattening and necrosis.

**Conclusion** A variety of soft-tissue and osseous lesions can be encountered in the skeletally immature gymnast.

Familiarity with these stress-related injuries is important for accurate diagnosis.

**Keywords** Gymnastics · MRI · Overuse · Children

## Introduction

Gymnastics has become a common and popular sport in the world today. In addition to those who partake in this sport for recreational purposes, there is a subpopulation of high-performance child athletes that strive for the ultimate goal of being an Olympian. During practice, skills or routines are learned and then repeated over and over in search of perfection. Many of these skills place extraordinary stress on the growing ends of the radius and ulna but also on the carpal bones and the bones of the hand and the many ligaments that stabilize these structures. At our institution we have encountered a variety of stress-related injuries in the skeletally immature gymnast, some of which have not been previously described in this patient population. The goal of this study was to document and review stress-related injuries sustained by young gymnasts in the wrist and hand.

## Material and methods

We retrospectively reviewed the reports and histories of all wrist and hand MRIs at our institution for the 2-year period from March 2006 to February 2008. The total number of exams reviewed was 125. From that group, all exams in which the history given by the referring physician or by the patient included gymnastics were retrieved into the study group.

---

J. R. Dwek (✉)  
Rady Children's Hospital and Health Center,  
Department of Radiology,  
3020 Children's Way,  
San Diego, CA 92123, USA  
e-mail: jdwek@yahoo.com

F. Cardoso · C. B. Chung  
Department of Radiology, University of California at San Diego,  
San Diego, CA, USA

All MR imaging was performed on a GE (General Electric Healthcare, Milwaukee, WI, USA) 1.5-T HDx platform. Children were placed prone with arm extended, and pronated (palm down) in the “superman” position.

Standard wrist MR imaging included coronal T1 (TR 300–330 msec, TE 13–17 msec), T2 fat-saturated (TR 2,850–3,300 msec, TE 60 msec), GRE (TE 15 msec TR 360–400 msec flip angle 15°), sagittal T1 and T2 fat-saturated, and axial T1 and T2 fat-saturated sequences. The slice thickness in all exams and sequences was 3 mm. When intravenous gadolinium (Magnevist Bayer Healthcare Pharmaceuticals, Wayne, NJ, USA) was administered imaging included post-contrast axial, sagittal and coronal T1 fat-saturated (TE 14–16 msec TR 400–530 msec) sequences.

MR arthrography was preceded by an injection of dilute gadopentate dimeglumine (Magnevist) (1 mm/L concentration) contrast agent via a dorsal approach into the radiocarpal joint under fluoroscopy. The clinical indication for MR arthrography was wrist pain with suspicion of ligamentous injury.

MR arthrographic sequences included coronal T1 (TE 13–17 msec, TR 300–330 msec), T1 fat-saturated (TE 14–16 msec TR 400–530 msec), and T2 fat-saturated (TE 60 msec, TR 2,850–3,300 msec), sagittal T1 and T2 fat-saturated and axial T1, T1 fat-saturated and T2 fat-saturated sequences as well as a 3-D SPGR fat-saturated cartilage sequence (TR 20–21, TE 3–4.4 flip angle 35–45). Again the slice thickness was 3 mm in all sequences.

MR imaging in the hand included both T1 (TR 300–330 msec, TE 13–17 msec) and T2 fat-saturated (TR 2,850–3,300 msec, TE 60 msec) sequences in all three planes. Slice thickness was again 3 mm throughout. If IV gadolinium contrast agent was given, post-contrast T1 fat-saturated (TE 14–16 msec TR 400–530 msec) imaging was performed in all three planes. Intravenous gadolinium contrast agent was administered in cases of osseous abnormality to help assess for osteonecrosis.

The images were reviewed by two attending musculoskeletal radiologists (JRD and CBC), each with more than 9 years of experience, for the presence of osseous, ligamentous and cartilaginous injuries. The physes of the distal ulna and radius were assessed for bony bridges as well as for foci of abnormal extension of physeal cartilage into the metaphyses. Agreement was by consensus. Other imaging was also reviewed if available. The ulnar variance of each individual was measured by one of the authors (JRD) using the average of three measurements from the conventional radiograph with the use of electronic calipers available on our PACS workstation (Amicas, Cambridge, MA, USA). The method used was that described by Hafner et al. [1] for skeletally immature individuals using method “A,”

which is the more accurate method for comparative analysis. Ulnar variance according to this method is determined by measuring the distance from the most proximal point of the ulnar metaphysis to the most proximal point of the radial metaphysis. In the individual whose growth plates were fused, the method used was that described by Gelberman et al. [2, 3]. In this method, ulnar variance is determined by measuring the distance between a line drawn from the ulnar side of the distal articular surface of the distal radius and a line drawn along the carpal surface of the distal ulna. In either case, ulnar positivity is present when the ulnar articular surface is lying distal to the line marking the measured point of the distal radius. Ulnar negativity is the converse. The measurement is given as a positive number for ulnar-positive variance and negative numbers for ulnar-negative variance. The general demographics of sex and age were also recorded. Surgical records and clinical history were reviewed when available.

At our institution, radiology retrospective reviews are deemed exempt from institutional review board approval.

## Results

A total of ten children were retrieved from the retrospective review. Three had bilateral examinations, resulting in the review of 13 MR imaging studies. All were girls age 12–16 years (mean age 14.2 years) at presentation. The lone 16-year-old girl also had an exam on the contralateral wrist at 18 years old (Table 1).

Of the ten girls, 8/10 had MR exams of the wrist and 2/10 had MR exams of the hand. One girl who had an MR imaging study of the hand also had a CT examination using a 64-slice MDCT (GE LightSpeed VCT, Waukesha, WI, USA). All patients had conventional radiographs. Of the eight children with wrist exams, three had bilateral MR exams and four had MR arthrograms.

Intravenous gadolinium contrast agent (Magnevist) was also administered to one patient with otherwise standard wrist imaging, and in that case the patient had MR exams done bilaterally 2 years apart both with IV contrast administration.

MR imaging of the hand was performed in two girls. Gadolinium contrast agent was given intravenously in one child.

### Physeal injuries

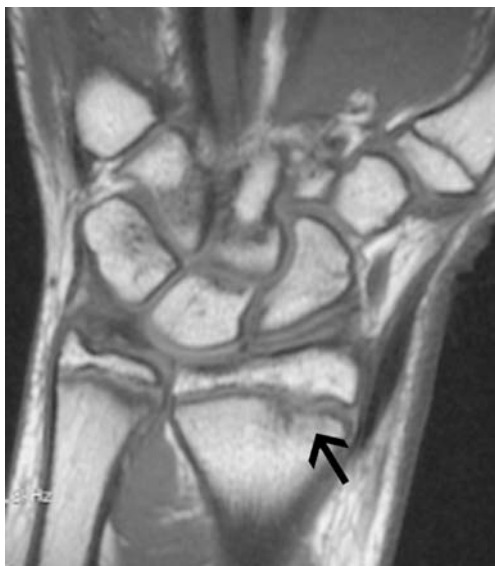Three girls exhibited abnormally high T2 signal intensity with widening of the distal radial physis. There were no bridges. The appearance was typical of what has been termed gymnast wrist, with fraying, widening and irregularity of the physis (Fig. 1) [4].

**Table 1** Review of records of ten children

| Pt. | Gender | Age    | Examination                          | Variance          | Findings  |
|-----|--------|--------|--------------------------------------|-------------------|---|
| 1   | F      | 12     | Standard MR wrist                    | -1                | Chronic physeal injury  |
| 2   | F      | 13     | MR arthrogram bilateral              | RT=0<br>LT=0      | RT=central communicating TFCC tear stripped UCL, scapholunate ligament tear<br>LT=central communicating TFCC tear |
| 3   | F      | 13     | Standard MR wrist bilateral          | RT=-0.5<br>LT=2.8 | RT, LT=Chronic physeal injury   |
| 4   | F      | 13     | Standard MR wrist                    | -0.5              | Chronic physeal injury  |
| 5   | F      | 14     | Standard MR, CT hand                 | -1.1              | 4th metacarpal head necrosis  |
| 6   | F      | 14     | MR arthrogram                        | 0                 | Focal lunate chondromalacia   |
| 7   | F      | 14     | Standard MR hand                     | -2                | 2-5 metacarpal head necrosis  |
| 8   | F      | 14     | MR arthrogram                        | 1                 | Central communicating TFCC tear, stripped UCL   |
| 9   | F      | 15     | MR arthrogram                        | 1.5               | Central communicating TFCC tear   |
| 10  | F      | 16, 18 | MR wrist with IV contrast, bilateral | RT=1<br>LT=1.2    | RT, LT=Focal lunate necrosis  |

### Ligamentous injuries

Three girls had TFCC tears, one of whom had TFCC tears bilaterally. All were the central communicating type. Additional findings included stripping of the ulnar collateral ligament from its distal ulnar insertion in two patients. One patient also had a scapholunate ligament tear, with contrast agent passing through the scapholunate joint from the radiocarpal to the midcarpal compartment (Fig. 2).



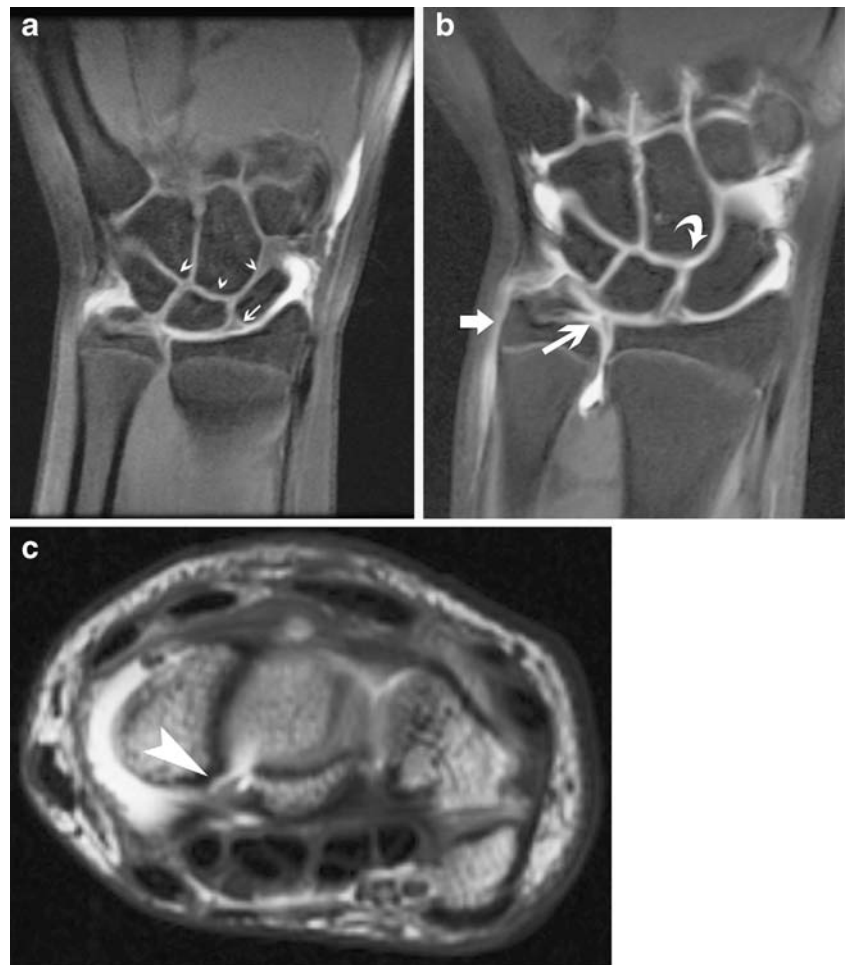
**Fig. 1** Coronal T1-W MRI of patient 1, a 12-year-old girl with chronic physeal injury. The distal radial physis is wide and irregular. Note low-signal intrusions into metaphysis typical of focal failure of ossification of physeal cartilage (arrow)

### Osseous injuries

Two girls showed an ovoid area of low T1 signal that was mildly hyperintense on T1 in the lunate at the scapholunate articulation. In both girls the scapholunate ligament was intact. In one girl the lunate abnormality was present toward the dorsal half of the bone. This lesion measured 6×3 mm and 3 mm in depth. In the other case, the abnormality was at the central portion and measured 5×3 mm and 3.5 mm in depth. This second girl was surgically explored. The focal area of abnormality in the lunate was described as filled with soft white material. The overlying articular cartilage had a reticulated appearance. The scapholunate ligament was described as intact but abnormal. Significantly, there was no abnormal motion at the scapholunate joint, with passive ranging of the carpus. Histological analysis showed a fibrocartilaginous matrix most consistent with chondromalacia. There were no necrotic elements to indicate Keinbock disease. This girl was initially examined at 16 years old on her right wrist, and she returned 2 years later at 18 years old with an identical injury to the left wrist and identical MR appearance (Fig. 3).

Two children had abnormalities involving the metacarpal heads. In one child flattening of metacarpals two through five was noted, with irregularity of the articular surface. In one child flattening and focal defects of the articular surface of the fourth metacarpal were noted without involvement of the other metacarpals. In both children, bright T2 signal was noted at the articular surface in a subchondral location with clear flattening of the articular surface, and irregularity with focal defects of the articular surface was seen (Fig. 4). The child with changes limited to the fourth metacarpal head also had an MDCT exam, which portrayed the

**Fig. 2** Ligamentous injury.  
**a** Normal triangular appearance of the scapholunate ligament (*arrow*) in a 14-year-old girl. Note that no bright gadolinium contrast is present in the midcarpal row (*arrowheads*).  
**b** Coronal T1-W MRI of a 13-year-old girl (patient 2). A central communicating tear of the TFCC is shown (*long arrow*) with contrast agent extending into the distal radioulnar joint. Contrast agent also extends proximally along the medial aspect of the ulna along the stripped UCL (*short arrow*). Note focus of contrast agent in the midcarpal row (*curved arrow*) passing through a tear of the scapholunate ligament that lacks its normal triangular configuration.  
**c** Axial T1-W fat-saturated MRI of the same patient. A tear of the volar portion of the scapholunate ligament is shown (*arrow*)



articular findings particularly well. The findings were typical of aseptic necrosis of the metacarpal head or Dieterich disease.

Measurements of ulnar variance showed a mean ulnar-negative variance measuring  $-0.18$  mm (SD 1.28 mm, RANGE  $-2.0$  mm to 2.8 mm, CI  $= -0.78$ ). This includes both wrists of the slightly older individual who returned to our institution at 18 years of age after first presenting at 16 years old. The normative value taken from Hafner et al. [1] in this age group is  $-2.2$  to  $-2.3$  mm so that ulnar variance was significantly more positive ( $P=0.05$ ) than that of the general population. Although the sample size was small, the ulnar variance was either neutral or positive in those patients 14 years or older and always positive in those 15 years or older.

**Discussion**

Since high-profile athletes such as Nadia Comaneci and Olga Korbut showcased the sport of gymnastics on the worldwide stage, it has been growing in popularity. It is a

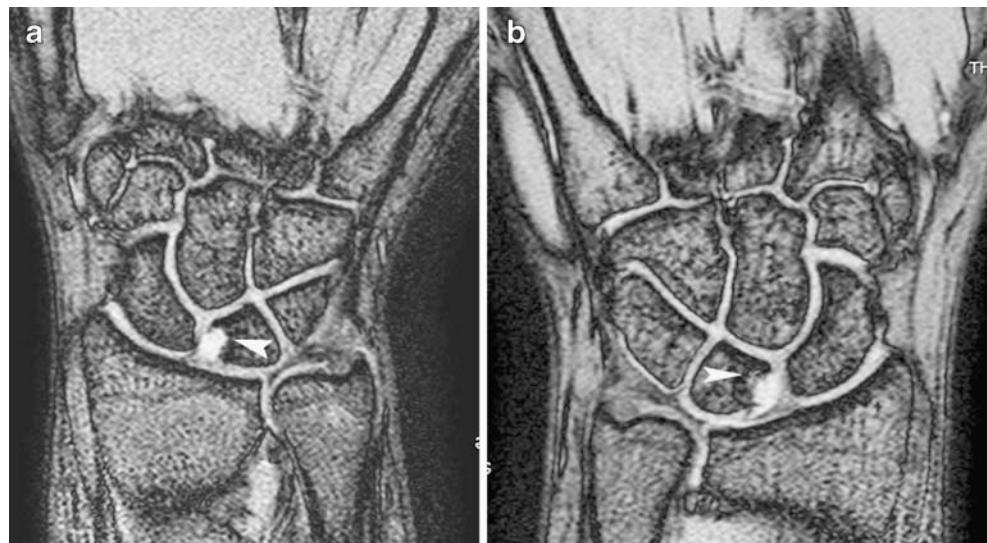
sport that requires many long hours of practice and repetition. A moment's consideration is sufficient to understand the enormous biomechanical stresses placed on the skeleton by this sport. The human body was not engineered to tumble end over end in a stunning combination of laybacks, twists and somersaults. Inevitably, injuries occur, usually but not solely as a result of chronic repetitive micro- or macrotrauma [5, 6].

Chronic growth plate injuries in gymnasts have been described fairly extensively [4, 7–10]. Plain film findings include irregular widening of the physes as well as irregularity and thickening of the zone of provisional calcification. On MR imaging, there is edema on the metaphyseal and epiphyseal sides of the physis. Foci of cartilaginous ingrowth resulting from failure of ossification of physeal cartilage into the metaphyses attest to metaphyseal injury while bony bridging results from epiphyseal trauma [11, 12].

Gymnasts are known to have ulnar-positive variance, which almost certainly results from chronic injury to the growing distal radial physis [13–16]. Although the distal ulnar physis is sometimes abnormal, in general, the



**Fig. 3** Patient 10. **a** Right wrist coronal GRE MRI of a 16-year-old girl. Focal bright signal in the lunate is consistent with an osteochondral defect proved by biopsy. **b** Same girl at age 18. Left wrist coronal GRE MRI. Focal bright signal in the lunate is identical to abnormality in right wrist

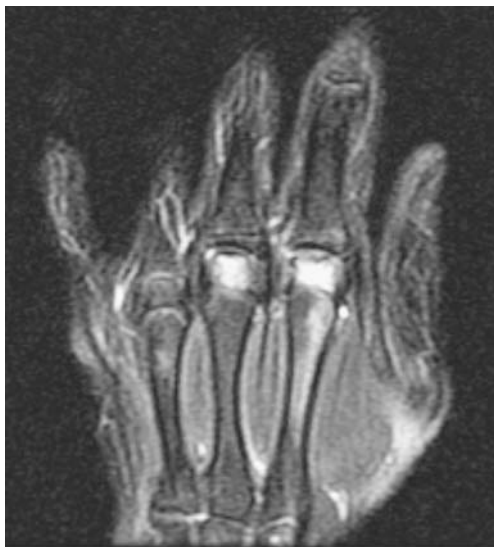

majority of stress changes and growth abnormalities are seen at the radius. Several theories have been advanced to explain this predilection. Although the actual cause might be multifactorial, the relative maturity of the radial physis and ulnar physis could be one contributor. When compared with the standards of the Gruelich and Pyle method of bone age measurement, the ulnar physis appears to lose its growth potential earlier than the distal radial physis. This has been in part confirmed by Ogden et al. [17], who found that in 2 out of 3 pathologic specimens the distal ulnar physis fused and lost its growth potential prior to the distal radius in children 13–14 years of age. Another important factor is the significantly greater cross-sectional area of the

distal radial physis as compared to that of the distal ulna. In the neutral position with neutral ulnar variance, 80% of an axial load is exerted by the radius and 20% by the ulna [18], such that far greater forces are exerted on the distal radial physis than on the distal ulnar physis. Ulnar negativity causes the load borne by the distal radius to rise to 96% [19]. Children normally tend to be ulnar-negative, which increases drastically the load on the distal radius. Furthermore, forearm supination causes a relative negative ulnar variance while ulnar positivity occurs during pronation [20]. Some exercises might be primarily performed with supination rather than pronation but no detailed biomechanical studies have been performed. The gymnastic predilection for ulnar-positive variance was reflected in our study, where the mean variance was only 0.18-mm negative. In contrast, most children 12–16 years of age have negative ulnar variance measuring  $-2.2$  to  $-2.3$  mm [1].

TFCC injuries are well described in gymnasts. Traumatic TFCC injuries are more common in those individuals who are ulnar-positive and indeed two of our three patients with TFCC injuries were ulnar-positive and the third was ulnar-neutral. Because many gymnasts become ulnar-positive from chronic injury to the distal radial physis, the two injuries might be related.

Focal chondral injury to the lunate with a similar appearance to that of our two cases has been described by Earp et al. [21] in association with a scapholunate ligament tear. In our one surgically explored case the scapholunate ligament was abnormal but intact and no abnormal motion was demonstrated at the joint. Because the articular cartilage over the area had a reticulated appearance and the ligament was described as abnormal, it is likely that this represents an osteochondral injury in association with a scapholunate ligament injury. Our second case of focal



**Fig. 4** Coronal T2-W MRI of a 14-year-old girl (patient 7). Flattening and bright signal of the second through fourth metacarpal heads consistent with osteonecrosis

lunate chondromalacia had an identical appearance, with an intact scapholunate ligament by MR arthrographic imaging. However, this does not rule out a healed scapholunate ligament injury and resultant osteochondral injury. Neither case had the typical appearance of Kienbock disease, which usually involves the entire lunate. Histological analysis of the one surgically proven case showed no necrotic elements consistent with Kienbock disease. In addition, Kienbock disease is more commonly associated with ulnar minus variance. One of our two patients with lunate changes was ulnar-neutral and the second was ulnar-positive. It is unclear whether this injury is related to ulnar-positive variance, because of the small sample size.

There were two children who had injuries to their metacarpal heads. This has not been described previously. During the gymnastic exercise the metacarpophalangeal joints are under great tension both in flexion and extension. Dieterich in 1932 described aseptic necrosis of the metacarpal head [22]. It can be idiopathic but has also been associated with trauma [23], systemic lupus erythematosus and steroid use [24]. Most commonly the third metacarpal head is involved. Wright et al. [25] have described the vascular anatomy and supply of the metacarpal heads. In 35% of people the vascular supply of the metacarpal heads depends on numerous small pericapsular arterioles. In the few cases of metacarpal head necrosis described in the literature, compression and low or absent flow possibly by a joint effusion have been postulated as possible causes but it would seem to be a tenuous association when considering the relative rarity of metacarpal head necrosis and the commonality of solely pericapsular vascular supply as is present in 35% of people. In neither case did we observe abnormality of the stabilizing structures of the metacarpophalangeal joints including the fibrous joint capsule, collateral ligaments and overlying tendons. Although a discrete fracture line was not observed, an insufficiency fracture and subsequent osteonecrosis with flattening of the articular surface is a strong possibility.

It is tempting to consider the entire spectrum of the injuries we have described as a chronic impaction type of injury that is manifesting at various levels in the carpus and the hand, depending on the age of the patients and the type of exercise performed, affecting the kinetic chain of the hand and wrist at various locations. Only physeal injuries manifested in the younger children, whereas the injury pattern shifted to osseous and ligamentous abnormalities in the older individuals. To some extent this is to be expected. The physis is most vulnerable to injury during pubertal growth when the growth rate is maximal. Later, when growth plate closure is imminent the physis is stronger as it narrows and small bony bridges occur prior to complete fusion. Instead of the injuries manifesting at the growth plate level, the area of failure shifts to the ligamentous tissue of the carpus, especially but not limited to the TFCC.

It is unclear why some children injured their TFCC while others injured their lunates and still others their metacarpal heads. The issue is complex and might be related to the different routines being performed by the different children and the specific osseous anatomy in each of the children and individual technique-related biomechanics. It is important to note that these injuries and specifically those in the metacarpal heads and in the lunate have not been previously described in gymnasts. A different emphasis or even method of training might affect the specific pattern of injuries produced. The radiologist must remain aware that sports injuries are dynamic, with multiple contributing factors including structural composition, technique-related biomechanics, and repetition, among other things.

Our study is limited by its retrospective nature and limited selection criteria. Only those individuals who gave a history of gymnastics or whose physicians gave such a history were included. There are likely to be other patients with a history of significant gymnastic exercise whose histories were incomplete.

In addition, certain conditions, especially chronic growth plate injuries, might be underrepresented. This diagnosis is usually evident by conventional radiography, and MR imaging is reserved for those with atypical or more severe pain.

## Conclusion

We have presented a set of injuries in gymnasts that span the gamut from growth plate injuries in the youngest children to articular injuries at various levels in individuals who, while still skeletally immature, have little growth potential remaining at the carpal level. Both the referring physician and the radiologist need to be aware of the range of injuries that can occur in the young gymnast. The term “gymnast wrist,” usually associated with chronic physeal trauma, should probably be enlarged to include nonphyseal osseous, ligamentous and osteochondral injuries.

**Open Access** This article is distributed under the terms of the Creative Commons Attribution Noncommercial License which permits any noncommercial use, distribution, and reproduction in any medium, provided the original author(s) and source are credited.

## References

1. Hafner R, Poznanski AK, Donovan JM (1989) Ulnar variance in children—standard measurements for evaluation of ulnar shortening in juvenile rheumatoid arthritis, hereditary multiple exostosis and other bone or joint disorders in childhood. *Skeletal Radiol* 18:513–516

2. Thienpont E, Mulier T, Rega F et al (2004) Radiographic analysis of anatomical risk factors for Kienbock's disease. *Acta Orthop Belg* 70:406–409
3. Gelberman RH, Salamon PB, Jurist JM et al (1975) Ulnar variance in Kienbock's disease. *J Bone Joint Surg Am* 57:674–676
4. Liebling MS, Berdon WE, Ruzal-Shapiro C et al (1995) Gymnast's wrist (pseudorickets growth plate abnormality) in adolescent athletes: findings on plain films and MR imaging. *AJR* 164:157–159
5. Gabel GT (1998) Gymnastic wrist injuries. *Clin Sports Med* 17:611–621
6. Webb BG, Rettig LA (2008) Gymnastic wrist injuries. *Curr Sports Med Rep* 7:289–295
7. Caine D, Roy S, Singer KM et al (1992) Stress changes of the distal radial growth plate. A radiographic survey and review of the literature. *Am J Sports Med* 20:290–298
8. De Smet L, Claessens A, Fabry G (1993) Gymnast wrist. *Acta Orthop Belg* 59:377–380
9. Ruggles DL, Peterson HA, Scott SG (1991) Radial growth plate injury in a female gymnast. *Med Sci Sports Exerc* 23:393–396
10. Shih C, Chang CY, Penn IW et al (1995) Chronically stressed wrists in adolescent gymnasts: MR imaging appearance. *Radiology* 195:855–859
11. Ecklund K, Jaramillo D (2002) Patterns of premature physeal arrest: MR imaging of 111 children. *AJR* 178:967–972
12. Jaramillo D, Laor T, Zaleske DJ (1993) Indirect trauma to the growth plate: results of MR imaging after epiphyseal and metaphyseal injury in rabbits. *Radiology* 187:171–178
13. Chang CY, Shih C, Penn IW et al (1995) Wrist injuries in adolescent gymnasts of a Chinese opera school: radiographic survey. *Radiology* 195:861–864
14. De Smet L, Claessens A, Lefevre J et al (1994) Gymnast wrist: an epidemiologic survey of ulnar variance and stress changes of the radial physis in elite female gymnasts. *Am J Sports Med* 22:846–850
15. DiFiori JP, Puffer JC, Mandelbaum BR et al (1997) Distal radial growth plate injury and positive ulnar variance in nonelite gymnasts. *Am J Sports Med* 25:763–768
16. Mandelbaum BR, Bartolozzi AR, Davis CA et al (1989) Wrist pain syndrome in the gymnast. Pathogenetic, diagnostic, and therapeutic considerations. *Am J Sports Med* 17:305–317
17. Ogden JA, Beall JK, Conlogue GJ et al (1981) Radiology of postnatal skeletal development. IV. Distal radius and ulna. *Skeletal Radiol* 6:255–266
18. af Ekenstam FW, Palmer AK, Glisson RR (1984) The load on the radius and ulna in different positions of the wrist and forearm. A cadaver study. *Acta Orthop Scand* 55:363–365
19. Palmer AK, Werner FW (1984) Biomechanics of the distal radioulnar joint. *Clin Orthop Relat Res* 187:26–35
20. Palmer AK, Glisson RR, Werner FW (1982) Ulnar variance determination. *J Hand Surg [Am]* 7:376–379
21. Earp BE, Waters PM, Wyzykowski RJ (2006) Arthroscopic treatment of partial scapholunate ligament tears in children with chronic wrist pain. *J Bone Joint Surg Am* 88:2448–2455
22. Bjorkman A, Jorgsholm P, Burtscher IM (2005) Osteonecrosis of the metacarpal head in a patient with a prothrombin 20210A gene mutation. *Scand J Plast Reconstr Surg Hand Surg* 39:379–381
23. McElfresh EC, Dobyns JH (1983) Intra-articular metacarpal head fractures. *J Hand Surg Am* 8:383–393
24. Weissman BN, Rappoport AS, Sosman JL et al (1978) Radiographic findings in the hands in patients with systemic lupus erythematosus. *Radiology* 126:313–317
25. Wright TC, Dell PC (1991) Avascular necrosis and vascular anatomy of the metacarpals. *J Hand Surg [Am]* 16:540–544