

UCLA

Proceedings of UCLA Health

Title

Bullous Pemphigoid Mimicking Epidermolysis Bullosa Acquisita

Permalink

<https://escholarship.org/uc/item/0qw358jd>

Journal

Proceedings of UCLA Health, 24(1)

Author

Gill, Liza

Publication Date

2020-04-03

CLINICAL VIGNETTE

Bullous Pemphigoid Mimicking Epidermolysis Bullosa Acquisita

Liza Gill, MD

Case

A 74-year-old female presented with a 2.5-year history of pruritus and blister formation on the trunk and extremities. Previous biopsies performed at an outside facility showed findings consistent with bullous drug eruption and immunobullous disorders. Direct immunofluorescence (DIF) was negative. Prior treatments included a 1-month prednisone taper, clobetasol cream, oral antihistamines, and permethrin cream. She reported improvement only with prednisone.

On the chest, upper and central lower back, and anterior lower legs, there were several pink, smooth to slightly scaly scars with many densely concentrated milia. A rare vesicle was noted on the right upper back and a flaccid bulla on the right medial breast. There were no oral or ocular vesicles, erosions or ulcers.

Biopsy of the right upper back showed a sub-epidermal vesicle with no inflammatory cells present within the blister cavity (Figure 1). Festooning of the dermal papillae and fibrin deposition in the floor of the blister cavity were noted. A diagnosis of epidermolysis bullosa acquisita was favored but differential diagnosis included pauci-inflammatory bullous pemphigoid.

CBC, CMP and G6PD level were within normal limits. DIF of perilesional right upper back skin showed linear deposits of IgG and C3 at the basement membrane zone (Figures 2A and 2B). Indirect immunofluorescence of the patient's serum showed autoantibodies against the epidermal side of the basement membrane zone at a titer of 1:20 using specific antihuman IgG conjugate and NaCl split skin as the substrate (Figures 3A and 3B). ELISA Studies were negative for BP180 (level: 4.6 units) and positive for BP230 (level: 77.5 units). These findings, in combination with the histopathology, confirmed the diagnosis of bullous pemphigoid.

The patient was started on dapsons 50 mg daily and increased to dapsons 100 mg daily after 1 week. She was improved with no new blistering at her 1-month follow up visit. The plan is to continue dapsons 100 mg daily.

Discussion

Bullous pemphigoid (BP) is the most common autoimmune sub-epidermal blistering disease. It is a chronic disease with risk factors including old age, neurologic diseases (dementia, Parkinson's disease, cerebrovascular disease), and certain

medications (loop diuretics, spironolactone, neuroleptics). BP is most commonly associated with autoantibodies directed against BP antigen 180 and BP antigen 230, components of hemidesmosomes that promote dermal-epidermal adhesion. Diagnosis is made by direct and indirect immunofluorescence microscopy as well as anti-BP180/BP230 ELISAs.¹

The classic features of BP include intense pruritus and tense blister formation on the trunk and extremities. Milia and scarring seem to be uncommon in patients with BP and are classically associated with epidermolysis bullosa acquisita (EBA), an antibody-mediated bullous disease characterized by skin fragility, scarring, and formation of milia. Prost *et al.* reported that milia were present in 9 of 17 patients with mucous membrane pemphigoid or EBA, but were absent in all 14 patients with BP.²

In contrast, few cases of BP with milium formation during recovery have been reported. Recently, Uchida *et al.* reported a BP case with numerous milia during recovery. The patient had IgG autoantibodies to the recombinant protein of the NC16a domain of BP180 and the soluble 120-kDa ectodomain of BP180. In addition, there was weak IgA reactivity with the BP180-NC16a recombinant protein.³ Tsuruta *et al.* reported a BP case with numerous milia who only had IgG autoantibodies to the BP180-NC16a recombinant protein.⁴ Through immunoblotting analyses of 30 patients with BP, Venning *et al.* reported that there is likely no correlation between the BP antigens detected in immunoblots (BP180 vs. BP230 vs. neither) and the clinical presentation of milia.⁵ Banfield *et al.* noted milium formation in 23 of 74 BP patients and found that HLA DQ6 positive patients had a significant predisposition to milium formation.⁶ These reports suggest that although it is more commonly seen in patients with EBA, milium formation may occasionally occur in patients with BP. Milium formation may be associated with an immunological predisposition (HLA DQ6).

In summary, clinical features of BP are polymorphic. Although it is more classically associated with EBA, milium formation can rarely be seen in patients with BP. Immunopathologic studies are necessary to definitively diagnose bullous diseases.

Figures

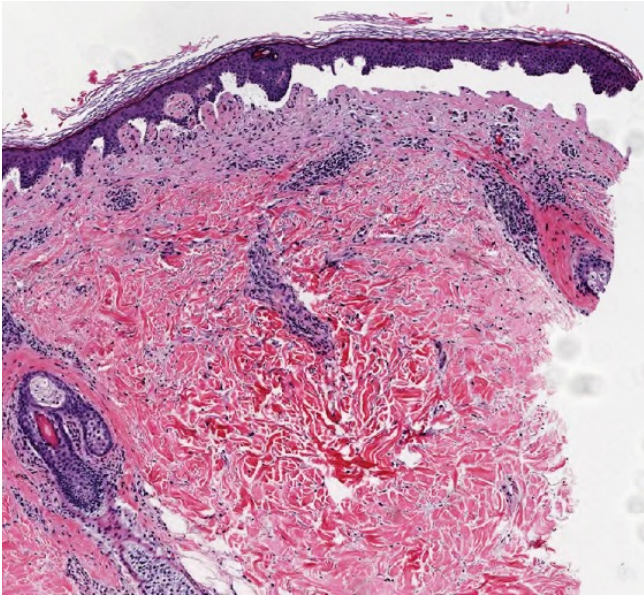


Figure 1.

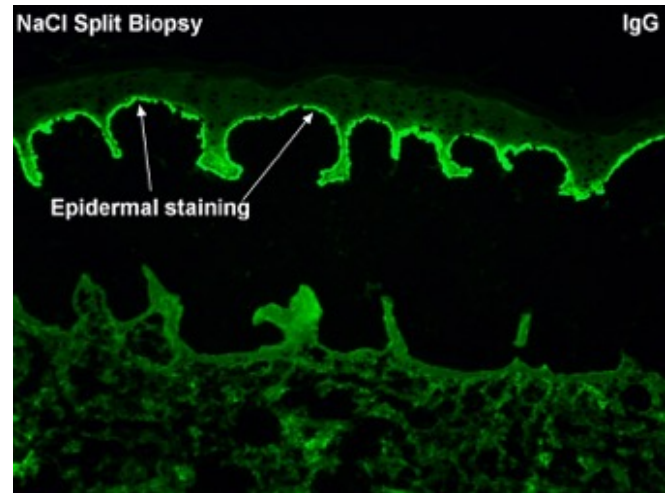


Figure 3A.

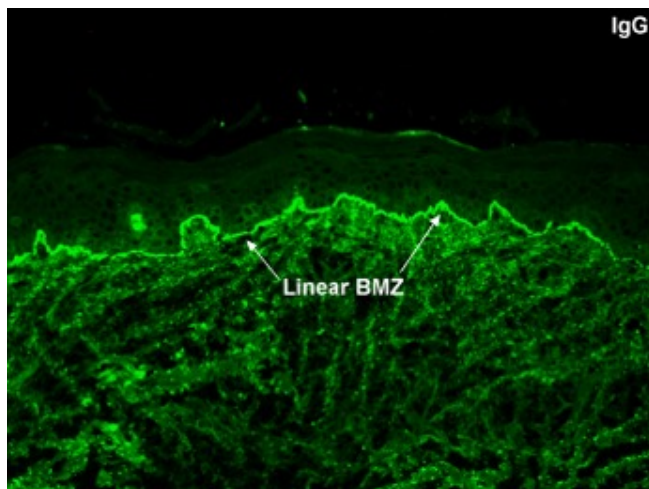


Figure 2A.

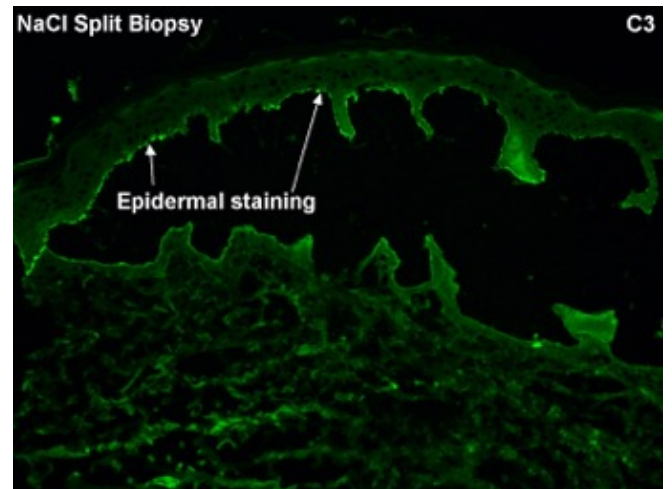


Figure 3B.

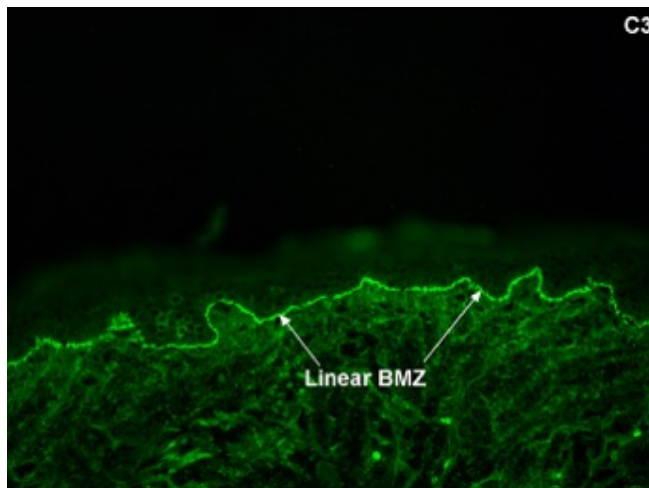


Figure 2B.

REFERENCES

1. **Bernard P, Antonicelli F.** Bullous Pemphigoid: A Review of its Diagnosis, Associations and Treatment. *Am J Clin Dermatol.* 2017 Aug;18(4):513-528. doi: 10.1007/s40257-017-0264-2. Review. PubMed PMID: 28247089.
2. **Prost C, Labeille B, Chaussade V, Guillaume JC, Martin N, Dubertret L.** Immunoelectron microscopy in subepidermal autoimmune bullous diseases: a prospective study of IgG and C3 bound in vivo in 32 patients. *J Invest Dermatol.* 1987 Dec;89(6):567-73. PubMed PMID: 3316411.
3. **Uchida S, Oiso N, Koga H, Ishii N, Okahashi K, Matsuda H, Hashimoto T, Kawada A.** Refractory bullous pemphigoid leaving numerous milia during recovery. *J Dermatol.* 2014 Nov;41(11):1003-5. doi: 10.1111/1346-8138.12650. PubMed PMID: 25346302.
4. **Tsuruta D, Brzezinski P, Koga H, Ohata C, Furumura M, Hashimoto T.** Bullous pemphigoid with prominent

milium formation. *Acta Dermatovenerol Croat.* 2013;21(1):35-8. PubMed PMID: 23683484.

5. **Venning VA, Whitehead PH, Leigh IM, Allen J, Wojnarowska F.** The clinical expression of bullous pemphigoid is not determined by the specificity of the target antigen. *Br J Dermatol.* 1991 Dec;125(6):561-5. PubMed PMID: 1760360.
6. **Banfield CC, Wojnarowska F, Allen J, George S, Venning VA, Welsh KI.** The association of HLA-DQ7 with bullous pemphigoid is restricted to men. *Br J Dermatol.* 1998 Jun;138(6):1085-90. PubMed PMID: 9747382.