

# UC San Diego

## UC San Diego Previously Published Works

### Title

Ultrasound-Guided Lateral Femoral Cutaneous Nerve Cryoneurolysis for Analgesia in Patients With Burns.

### Permalink

<https://escholarship.org/uc/item/0q5957ws>

### Journal

Journal of Burn Care & Research, 41(1)

### ISSN

1559-047X

### Authors

Finneran, John J  
Swisher, Matthew W  
Gabriel, Rodney A  
et al.

### Publication Date

2020-01-30

### DOI

10.1093/jbcr/irz192

Peer reviewed

# Ultrasound-Guided Lateral Femoral Cutaneous Nerve Cryoneurolysis for Analgesia in Patients With Burns

John J. Finneran IV, MD,<sup>\*,\*</sup> Matthew W. Swisher, MD, MS,<sup>\*</sup> Rodney A. Gabriel, MD, MAS,<sup>\*</sup> Alfredo Fiallo, MD,<sup>\*</sup> Jeffrey R. Hamilton, MD,<sup>\*</sup> Jeanne G. Lee, MD,<sup>†</sup> and Brian M. Ilfeld, MD, MS<sup>\*</sup>

Autologous skin grafting from the thigh is frequently required for treatment of burns and is associated with intense pain at the donor site. Local anesthetic-based (LA) nerve blocks of the lateral femoral cutaneous nerve (LFCN) have been demonstrated to provide analgesia when the graft is taken from the lateral thigh. However, the duration of these single injection blocks has been reported to average only 9 hours, whereas the pain from the procedure lasts days or weeks. Continuous LA nerve blocks can also be used to provide analgesia during serial debridement of burns, although this requires placement of a perineural catheter which may increase infection risk in a population with an increased susceptibility to infection. Cryoneurolysis of the LFCN can potentially provide analgesia of the lateral thigh for skin graft harvesting or serial burn debridement that lasts far longer than conventional LA nerve blocks. Here, we present a series of three patients who received a combination of a LA nerve block and cryoneurolysis nerve block of the LFCN for analgesia of the lateral thigh. Two of these patients had the blocks placed before harvesting a split thickness skin graft. The third received the blocks for outpatient wound care of a burn to the lateral thigh. In all cases, the resulting analgesia lasted more than 1 week. A single cryoneurolysis block of the LFCN successfully provided extended duration analgesia of the lateral thigh for autologous skin graft donor site or wound care of a burn in three patients.

Pain management in burn patients is often required for both the site of the burn as well as donor sites for autologous split thickness skin grafting (STSG). In many patients, the pain from the graft donor site exceeds that of the burn, requires a significant amount of opioid analgesics, and, because the lower extremity is usually the site for harvesting, often inhibits the patient's ability to perform physical therapy.<sup>1</sup>

The lateral femoral cutaneous nerve (LFCN) provides cutaneous sensation to the lateral aspect of the thigh and can be visualized with ultrasound in the intermuscular space between the tensor fascia latae and sartorius muscles.<sup>2</sup> With no motor component, the LFCN is an optimal target for regional anesthesia of the lateral thigh, and local anesthetic-based (LA) nerve blocks of the LFCN have been demonstrated to provide excellent anesthesia of the lateral thigh for harvesting autologous skin grafts.<sup>1,3</sup> Unfortunately, the average duration of

LFCN block performed with bupivacaine is usually less than 12 hours,<sup>1</sup> whereas the duration of the pain associated with skin graft harvesting or debridement may be days or weeks.

Ultrasound-guided percutaneous cryoneurolysis is a U.S. Federal Drug Administration-cleared technique that offers the potential for a prolonged sensory block, lasting weeks to months. This technique, which uses freezing temperatures ( $-70^{\circ}\text{C}$ ) to reversibly ablate nerves, has been used by anesthesiologists to successfully treat both acute and chronic pain.<sup>4-7</sup> Given the duration of the induced block, the analgesia provided may be better matched to the expected duration of pain associated with STSG and burn care.

## CASE REPORT

### Description of Technique

Patients were positioned supine with standard American Society of Anesthesiologists monitors applied. The LFCN was identified in short-axis by ultrasound using a 13- to 6-MHz linear ultrasound transducer (HFL38, SonoSite, Bothell, WA) in the intermuscular space between the sartorius and tensor fasciae latae muscles (Figure 1).<sup>2</sup> To maximize block distribution, the nerve was traced cephalad as far as it could be easily visualized. Before block needle insertion, the block site was prepared with chlorhexidine gluconate and the skin was anesthetized with 1% lidocaine.

Using an in-plane, ultrasound-guided technique, a 22-Gauge (G) B-bevel needle was advanced adjacent to the LFCN (Figure 2). Bupivacaine 0.5% (10 ml) was injected to circumferentially cover the nerve. Approximately 20 minutes following the LA block, loss of temperature discrimination

<sup>\*</sup>Department of Anesthesiology and <sup>†</sup>Department of Surgery, University of California, San Diego

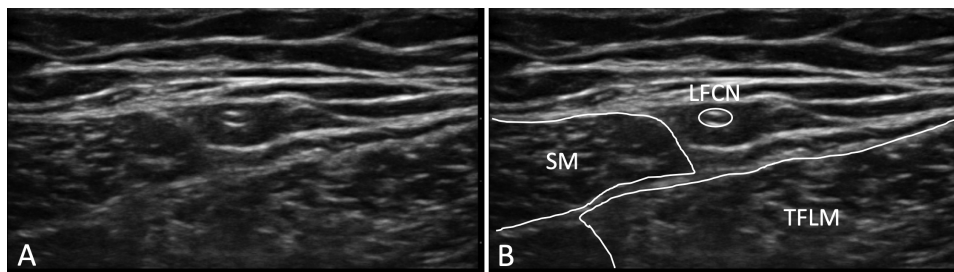
Funding: Epimed International (Farmers Branch, TX) provided the cryoneurolysis devices and probes used for these cases.

Conflict of interest statement. J.J.F., M.W.S., R.A.G., and B.M.I.: The University of California has received funding and product for other research projects from Myoscience and Epimed; infusion pump manufacturer Infutronics; perineural catheter manufacturer Ferrosan Medical; and a manufacturer of a peripheral nerve stimulation device, SPR Therapeutics. B.M.I.: In addition to the above, Dr. Ilfeld's institution has received funding for another research project from a manufacturer of a long-acting bupivacaine formulation, Heron Pharmaceuticals. A.F., J.R.H., and J.G.L.: No additional conflicts.

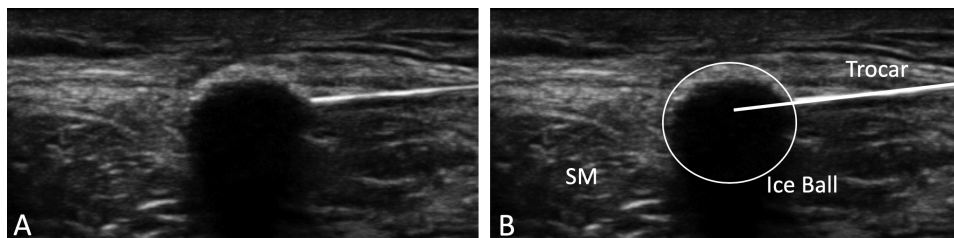
Address correspondence to John J. Finneran IV, MD, 200 West Arbor Drive MC 8770, San Diego, CA 92103. Email: [jfinneran@ucsd.edu](mailto:jfinneran@ucsd.edu)

© American Burn Association 2019. All rights reserved. For permissions, please e-mail: [journals.permissions@oup.com](mailto:journals.permissions@oup.com).

doi:10.1093/jbcr/irz192



**Figure 1.** (A) The LFCN is identified in the intermuscular plane between the sartorius muscle and the tensor fascia latae muscle. (B) The lateral femoral cutaneous nerve (LFCN), sartorius (SM), and tensor fasciae latae muscles (TFLM) are labeled.



**Figure 2.** (A) An ice ball is seen forming in tissue at the tip of the cryoneurolysis trocar. (B) Sartorius muscle (SM), cryoneurolysis trocar, and ice ball are labeled. Not pictured is the LFCN, which is encompassed within the ice ball.

to ice was used to map the block distribution (Figure 3). Following this, cryoneurolysis was performed with a console-based cryoneurolysis machine (PainBlocker, Epimed International, Farmers Branch, TX). A 14G trocar was inserted through a 14G intravenous catheter positioned at the same cephalad-caudad level approximately 0.25 cm deep to the LFCN and three 2-minute cryoablation cycles separated by 1-minute thaw periods were applied to the nerve.

### Case 1

A 42-year-old man with a history of homelessness, substance abuse, and recurrent skin abscesses presented with painful ulceration of the lower leg (4% body surface area, Baux score = 46). The patient was scheduled for autologous STSG from the lateral thigh to cover the ulcerated area. Preoperative nerve block of the LFCN with LA and cryoneurolysis was performed for the donor site. On the first postoperative day, the patient reported minimal pain at the donor site with the exception of a small area on the anterior aspect, likely representing a watershed area with the femoral nerve. This pain was easily controlled with multimodal oral analgesic regimen consisting of gabapentin 300 mg every 8 hours, acetaminophen 650 mg every 6 hours, and oxycodone available as needed in 5 to 10 mg doses (10–30 mg used daily). On the seventh postoperative day, the patient began to notice a return of sensation to his lateral thigh; however, his pain remained controllable with this oral analgesic regimen.

### Case 2

A 59-year-old man with a history of type-II diabetes mellitus and significant peripheral neuropathy presented with fourth-degree burns (2% body surface area, Baux score = 61) to the lower leg and foot after resting his leg on a space heater. The patient was taken to the operating room for skin grafting from the

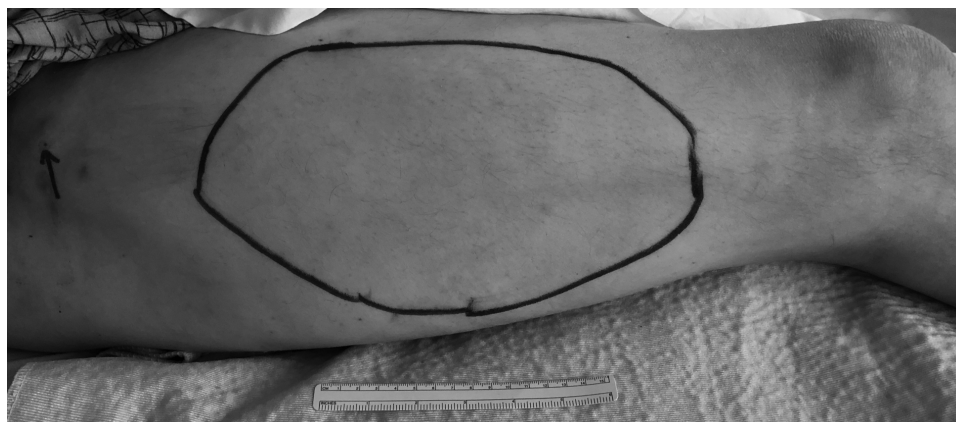
lateral thigh to the burned area of the leg. Preoperative LFCN LA and cryoneurolysis blocks were performed as the primary anesthetic for the surgical procedure. In this patient, the LFCN was less than 1 cm deep to the skin. To prevent the ice ball created by the cryoneurolysis probe from contacting the skin, a tumescent local anesthetic technique was used, infiltrating local anesthetic between the nerve and the subcutaneous tissue to increase the distance between the two (Figure 4). On the first postoperative day, the patient denied pain at his donor site and reported mild pain that was controllable with oral analgesics, acetaminophen 650 mg every 6 hours and oxycodone available as needed (0–10 mg per day), at the burn site. He began reporting increased pain in the lateral thigh on the ninth postoperative day, which was manageable with slightly increased consumption of oxycodone (10–15 mg per day).

### Case 3

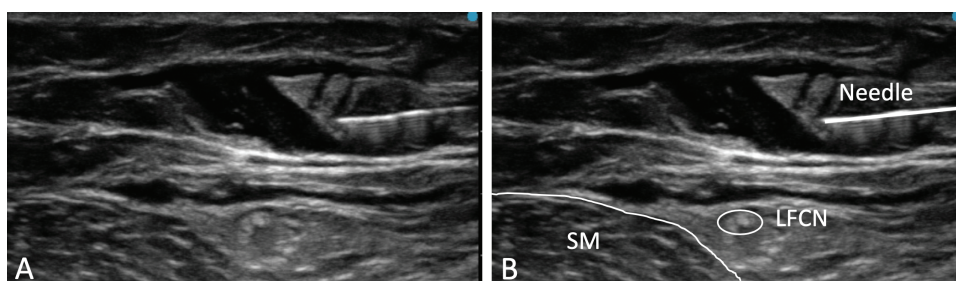
An 83-year-old woman presented with third-degree scald burns (3% body surface area, Baux score = 86) from hot coffee spilled onto the outer aspect of her thigh. The patient had difficulty tolerating dressing changes to the burn site, reporting 10/10 pain with dressing changes after premedication with 15-mg oxycodone. Additionally, the patient was extremely sedated after the dressing changes with this analgesic regimen. LFCN blocks with LA and cryoneurolysis were performed to assist with dressing changes. The patient reported 0/10 pain during the subsequent dressing change approximately 36 hours after the procedure and required no opioid analgesics. She was subsequently discharged home with family and continued to tolerate the dressing changes well over the subsequent 10 days.

### Follow-up

All patients had follow-up by telephone at 3 months after the cryoneurolysis procedure to assess for procedure-related



**Figure 3.** Block distribution of the LFCN is marked by testing temperature discrimination to ice. The injection site is labeled with an arrow. A ruler is included for scale.



**Figure 4.** (A) Local anesthetic is infiltrated in a tumescent technique to increase the vertical distance between the LFCN and the skin. (B) The lateral femoral cutaneous nerve (LFCN), sartorius muscle (SM), and needle are labeled.

complications. No complications were identified and sensation in the lateral thigh had returned to normal in all three patients.

*Consent for Publication.* The University of California San Diego Institutional Review Board (San Diego, CA) waives review requirements for case reports and short case series. Written informed consent for the LFCN cryoneurolysis procedure as well as publication of relevant, nonidentifiable medical history, sonographic imaging, and photographs in the form of a case report was obtained from all patients.

## DISCUSSION

Pain in the lateral thigh associated with autologous skin graft harvesting and dressing changes for patients with burns is amenable to treatment with regional anesthesia.<sup>1,3</sup> However, LA blocks of the LFCN have a duration measured in hours,<sup>1</sup> whereas the pain these patients experience is measured in days or weeks. Percutaneous peripheral nerve cryoneurolysis, as an alternative or supplement to LA blocks, offers the potential to induce a block lasting days to weeks. When exposed to extreme cold ( $-70^{\circ}\text{C}$ ), axonal injury causes Wallerian degeneration distal to the ablation site. Since the endoneurium, perineurium, and epineurium remain intact, the axons regenerate at a rate of approximately 1 mm per day.<sup>8</sup> The duration of the induced block therefore depends on the distance between the ablation site and the location

of the painful stimulus. In this series, there was greater than 5-cm distance between the cryoneurolysis site and the STSG donor site.

As a nerve with no motor component, the LFCN makes a particularly appealing target for cryoneurolysis compared to other nerves innervating the thigh (i.e., femoral or sciatic), which, when blocked with local anesthetic, increase risk of falls.<sup>9-12</sup> The prolonged block produced by cryoneurolysis would potentially interfere with ambulation and physical therapy for more than a week if applied to these nerves. However, care should be taken when performing cryoneurolysis of the LFCN to ensure no involvement of the skin with the visualized ice ball to prevent skin hyperpigmentation or hypopigmentation. When the nerve is immediately deep to the skin, separating the two by infiltrating local anesthetic between the nerve and the skin may protect the skin from cold-induced discoloration. Other risks of cryoneurolysis include thermal injury to the skin, which may be decreased by inserting the probe through an intravenous catheter as an introducer, and discomfort associated with the numbness, which some patients find distressing. For this reason, it is preferable to perform a LA block before cryoneurolysis, so the patient can “preview” the effect.<sup>6</sup> These additional risks should be discussed with the patient along with the associated benefits of improved analgesia and decreased opioid consumption when compared with conventional therapy of LA for nerve blocks or surgical site infiltration.

The additional cost of cryoneurolysis compared with conventional LA nerve blocks and opioid analgesics must be considered when weighing the choice of postoperative analgesia strategy. Cryoneurolysis is associated with a large initial investment in the form of the console unit and probes; however, the operating costs are limited to nitrous oxide, sterilization of the trays, and time. The technique described in this series can be estimated to add 10 minutes of patient care time (3 cycles x 2-min freezing and 1-min thawing with 1 min for probe placement by an experienced regional anesthesiologist). It should be noted that the cryoneurolysis procedure can be done postoperatively to save time preoperatively. Patient populations most likely to benefit from cryoneurolysis include those who are intolerant of opioid analgesics, those with a history of opioid abuse or dependence, and chronic pain patients. However, all patients would likely benefit from the opioid sparing effects of prolonged sensory blockade. Additionally, if cryoneurolysis can be used to facilitate home wound debridement that otherwise would require hospital admission, this must be considered in the cost analysis.

In this series, three patients had extended duration (greater than 1 wk) analgesia in the lateral thigh after a single application of cryoneurolysis to the LFCN. Additionally, we describe a novel technique of using tumescent local anesthetic to increase the distance between the skin and the target nerve and thereby decrease the risk of cold-induced skin injury. As with any newly described technique, randomized, controlled trials are required to document and quantify the risks and benefits of ultrasound-guided percutaneous cryoneurolysis of the LFCN in burn patients.

## REFERENCES

1. Shteynberg A, Riina LH, Glickman LT, Meringolo JN, Simpson RL. Ultrasound guided lateral femoral cutaneous nerve (LFCN) block: safe and simple anesthesia for harvesting skin grafts. *Burns* 2013;39:146–9.
2. Zhu J, Zhao Y, Liu F, Huang Y, Shao J, Hu B. Ultrasound of the lateral femoral cutaneous nerve in asymptomatic adults. *BMC Musculoskelet Disord* 2012;13:227.
3. Wardrop PJ, Nishikawa H. Lateral cutaneous nerve of the thigh blockade as primary anaesthesia for harvesting skin grafts. *Br J Plast Surg* 1995;48:597–600.
4. Gabriel RA, Finneran JJ, Asokan D, Trescot AM, Sandhu NS, Ilfeld BM. Ultrasound-Guided percutaneous cryoneurolysis for acute pain management: a case report. *A A Case Rep* 2017;9:129–32.
5. Gabriel RA, Finneran JJ 4<sup>th</sup>, Trescot AM, Ilfeld BM. Ultrasound-Guided percutaneous cryoneurolysis for postoperative analgesia after limb amputation: a case series. *A A Pract* 2019;12:231–4.
6. Trescot AM. Cryoanalgesia in interventional pain management. *Pain Physician* 2003;6:345–60.
7. Ilfeld BM, Gabriel RA, Trescot AM. Ultrasound-guided percutaneous cryoneurolysis providing postoperative analgesia lasting many weeks following a single administration: a replacement for continuous peripheral nerve blocks?: a case report. *Korean J Anesthesiol* 2017;70:567–70.
8. Trojaborg J. Rate of recovery in motor and sensory fibres of the radial nerve: clinical and electrophysiological aspects. *Neurol Neurosurg Psychiatr* 1970;33:625–38.
9. Kwofie MK, Shastri UD, Gadsden JC, et al. The effects of ultrasound-guided adductor canal block versus femoral nerve block on quadriceps strength and fall risk: a blinded, randomized trial of volunteers. *Reg Anesth Pain Med* 2013;38:321–5.
10. Finn DM, Agarwal RR, Ilfeld BM, et al. Fall risk associated with continuous peripheral nerve blocks following knee and hip arthroplasty. *Medsurg Nurs* 2016;25:25–30, 49.
11. Wegener JT, van Ooij B, van Dijk CN, Hollmann MW, Preckel B, Stevens MF. Value of single-injection or continuous sciatic nerve block in addition to a continuous femoral nerve block in patients undergoing total knee arthroplasty: a prospective, randomized, controlled trial. *Reg Anesth Pain Med* 2011;36:481–8.
12. Ilfeld BM, Duke KB, Donohue MC. The association between lower extremity continuous peripheral nerve blocks and patient falls after knee and hip arthroplasty. *Anesth Analg* 2010;111:1552–4.