

UC Berkeley

UC Berkeley Previously Published Works

Title

Amyloid in dementia associated with familial FTLD: not an innocent bystander

Permalink

<https://escholarship.org/uc/item/0q4217rf>

Journal

Neurocase, 22(1)

ISSN

1355-4794

Authors

Naasan, Georges

Rabinovici, Gil D

Ghosh, Pia

et al.


Publication Date

2016-01-02

DOI

10.1080/13554794.2015.1046458

Peer reviewed



Amyloid in dementia associated with familial FTLN: not an innocent bystander

Georges Naasan, Gil D. Rabinovici, Pia Ghosh, Jonathan D. Eloffson, Bruce L. Miller, Giovanni Coppola, Anna Karydas, Jamie Fong, David Perry, Suzee E. Lee, Jennifer S. Yokoyama, William W. Seeley, Joel H. Kramer, Michael W. Weiner, Norbert Schuff, William J. Jagust, Lea T. Grinberg, Mochtar Pribadi, Zhongan Yang, Renee Sears, Eric Klein, Kevin Wojta & Howard J. Rosen

To cite this article: Georges Naasan, Gil D. Rabinovici, Pia Ghosh, Jonathan D. Eloffson, Bruce L. Miller, Giovanni Coppola, Anna Karydas, Jamie Fong, David Perry, Suzee E. Lee, Jennifer S. Yokoyama, William W. Seeley, Joel H. Kramer, Michael W. Weiner, Norbert Schuff, William J. Jagust, Lea T. Grinberg, Mochtar Pribadi, Zhongan Yang, Renee Sears, Eric Klein, Kevin Wojta & Howard J. Rosen (2016) Amyloid in dementia associated with familial FTLN: not an innocent bystander, *Neurocase*, 22:1, 76-83, DOI: [10.1080/13554794.2015.1046458](https://doi.org/10.1080/13554794.2015.1046458)

To link to this article: <https://doi.org/10.1080/13554794.2015.1046458>

View supplementary material

Published online: 04 Jun 2015.

Submit your article to this journal

Article views: 127

View Crossmark data

Citing articles: 3 View citing articles

Amyloid in dementia associated with familial FTLN: not an innocent bystander

Georges Naasan^{a*}, Gil D. Rabinovici^a, Pia Ghosh^a, Jonathan D. Eloffson^a, Bruce L. Miller^a, Giovanni Coppola^d, Anna Karydas^a, Jamie Fong^a, David Perry^a, Suzee E. Lee^a, Jennifer S. Yokoyama^a, William W. Seeley^a, Joel H. Kramer^a, Michael W. Weiner^b, Norbert Schuff^b, William J. Jagust^c, Lea T. Grinberg^a, Mochtar Pribadi^d, Zhongan Yang^d, Renee Sears^d, Eric Klein^d, Kevin Wojta^d and Howard J. Rosen^a

^aMemory and Aging Center, Department of Neurology, University of California, San Francisco, CA, USA; ^bDepartment of Radiology, University of California, San Francisco, CA, USA; ^cSchool of Public Health, University of California Berkeley and Lawrence Berkeley National Laboratory, Berkeley, CA, USA; ^dDepartment of Psychiatry, Semel Institute for Neuroscience and Human Behavior, David Geffen School of Medicine, University of California, Los Angeles, CA, USA

(Received 19 November 2014; accepted 18 April 2015)

Patients with frontotemporal lobar degeneration (FTLD) can show superimposed amyloid pathology, though the impact of amyloid on the clinical presentation of FTLD is not well characterized. This cross-sectional case–control study compared clinical features, fluorodeoxyglucose-positron emission tomography metabolism and gray matter volume loss in 30 patients with familial FTLD in whom amyloid status was confirmed with autopsy or Pittsburgh compound B-PET. Compared to the amyloid-negative patients, the amyloid-positive patients performed significantly worse on several cognitive tests and showed hypometabolism and volume loss in more temporoparietal regions. Our results suggest that in FTLD amyloid positivity is associated with a more Alzheimer’s disease-like pattern of neurodegeneration.

Keywords: frontotemporal dementia; Alzheimer’s disease; amyloid; MRI; FDG-PET

Traditional models of neurodegenerative disease propose that an abnormality in a specific protein catalyzes a cascade of changes, leading ultimately to neurodegeneration (Jack et al., 2010). Although alternative models are receiving more attention (Jack & Holtzman, 2013), this idea still guides current diagnostic approaches, as well as clinical trials, which have thus far focused on treating single, specific proteins. Yet, in many patients, brain autopsy shows a mixture of abnormalities involving several putatively disease-specific proteins (Echavarrri, Caballero, Aramendia, Garcia-Bragado, & Tunon, 2011). Mixed pathology can be interpreted in at least two ways: (1) a primary protein caused most of the patient’s symptoms and the other proteinopathy is a secondary phenomenon, or (2) both pathologies contributed to neurodegeneration and accounted for the clinical features in that patient. If the primary/secondary model applies, treatment for the primary protein may be adequate, whereas the combined-effects model suggests that treatments for both proteins should be considered.

Frontotemporal lobar degeneration (FTLD) is a leading cause of dementia (Brunnstrom, Gustafson, Passant, & Englund, 2009) most commonly associated with one of two protein abnormalities: tau or TDP-43 (Mackenzie & Rademakers, 2007). Around 20–50% of FTLD patients have a strong family history, with about 10% of FTLD showing an autosomal-dominant pattern of inheritance

(familial, or f-FTLD). Many of these cases are caused by mutations that confer very high risk for FTLD (Rohrer, & Warren, 2011). Several authors have reported that the clinical and imaging features in patients with f-FTLD can mimic Alzheimer’s disease (AD) (Kelley et al., 2009; Le Ber et al., 2008; Rademakers et al., 2007). In some of these cases, dual pathology with FTLD and beta-amyloid in f-FTLD has been confirmed (Josephs et al., 2007; Perry et al., 2013). The influence of this dual pathology on clinical and imaging features has not been systematically examined.

Materials and methods

Study population

Patients were included from ongoing projects whose goal was to improve diagnosis of FTLD. Assessments included neurological history and examination, neuropsychological testing, informant interview and genetic testing, and postmortem examination as described previously (Coppola et al., 2012; Coppola et al., 2008; Fogel et al., 2012; Grinberg et al., 2013; Kramer et al., 2003; Rosen et al., 2002) (see Supplemental data for details on genetic and autopsy methods). Brain imaging included MRI, fluorodeoxyglucose-positron emission tomography (FDG-PET) and amyloid-PET (see below). Diagnosis is determined prior to review of imaging during a

*Corresponding author. Email: gnaasan@memory.ucsf.edu

multidisciplinary conference where the team is blind to the genetic status of the patient. Patients were included in this study based on the following criteria: (1) symptomatic from f-FTLD as defined by a dementia or motor neuron syndrome in the presence of an established mutation or rare genetic variation in a gene associated with FTLN, and (2) confirmed presence or absence of beta-amyloid pathology either from autopsy or PET scanning. We limited our analysis to f-FTLD in order to identify patients with strong evidence of dual FTLN/beta-amyloid pathology. f-FTLD patients with evidence of amyloid are highly likely to have dual pathology including FTLN. In addition, the presence of a mutation strongly favors FTLN as the “primary” pathology, so that AD pathology is likely to be secondary. Analyzing the effects of amyloid in this setting provides the strongest evidence about the influence of amyloid on the evolution of an FTLN neurodegenerative process.

Cognitively normal comparison subjects (CN), who were recruited from the community via advertisements and community events, had a similar assessment and were required to be functioning independently and to be performing within normal limits on neuropsychological testing (Kramer et al., 2007; Mormino et al., 2009).

Participants or their surrogates provided written consent of participation in the study. The study was approved by the University of California in San Francisco (UCSF), UC Berkeley and Lawrence Berkeley National Laboratory (LBNL) institutional review boards for human research.

Image acquisition and processing

PET and MRI preprocessing and analysis were conducted using SPM8 (<http://www.fil.ion.ucl.ac.uk/spm>). Subjects underwent FDG-PET and amyloid PET using Pittsburgh compound B (PiB) on a Siemens ECAT EXACT HR scanner at LBNL (Lehmann et al., 2013). FDG frames for each subject were summed and normalized to mean activity in the pons. For PiB, voxelwise distribution volume ratios were calculated using Logan graphical analysis (Rabinovici et al., 2007). PiB scans were interpreted by a visual rater as “positive” or “negative” as previously described (Rabinovici et al., 2011). FDG-PET standardized uptake volume ratios were spatially normalized to Montreal Neurological Institute space using the subject’s structural MRI and smoothed by 12 mm.

T1-weighted magnetization-prepared rapid gradient-echo images were acquired on one of three scanners: a 1.5-T Siemens Magnetom VISION system (Rosen et al., 2002), a Siemens 3-T TIMM Trio Scanner (Bettcher et al., 2012), or (in the case of one patient) a Bruker MedSpec 4-T system controlled by a Siemens TrioTM console (Mueller et al., 2009). The patient scanned at 4 T was included in the clinical description and FDG-PET analysis but not the MRI group analysis. Gray matter content was

analyzed using voxel-based morphometry, as previously described (Rosen et al., 2010). Modulated gray matter images were smoothed with a 12 mm Gaussian kernel.

Statistical analysis

Patients were categorized as amyloid positive (A+) based on either the PiB-PET or the presence of at least a consortium to establish a registry for Alzheimer’s disease (CERAD) moderate level of amyloid plaques at autopsy because PiB positivity is associated with this level of plaque (Clark et al., 2011). Voxelwise comparisons were performed separately for FDG-PET and MRI using analysis of covariance models that included diagnosis (CN, A+, A-) as the condition, and age and sex as covariates. For MRI, total intracranial volume and scanner field strength (1.5 T versus 3 T) were also included. Contrasts were performed as follows: A+ < CN, A- < CN, A+ > A-, and A- > A+. T-maps were displayed on a canonical brain at a threshold of $p < .001$ uncorrected for multiple comparisons. The threshold for statistical significance was $p < .05$ after family-wise error correction for multiple comparisons.

Demographics and neuropsychological data for the two groups were analyzed using Stata/IC 11.0 for Windows. Continuous variables were analyzed using *t*-tests, and categorical variables were analyzed using χ^2 tests.

Results

Clinical features in A+ versus A- cases

Thirty patients meeting the criteria for the study were identified including 19 with *C9ORF72* expansions, 6 with *GRN* mutations, 1 with a *MAPT* mutation, 2 with a rare variation of unknown significance in the *TARDBP* gene, and 2 with the rare p.A152T variation in the *MAPT* gene (see eTable 1 in the Supplemental data for more details). In total, 15 of these cases had PiB-PET and 17 had autopsies (two had both). Six patients were categorized as A+; three with PET only, two with autopsy only, and one with PET and autopsy (Figure 1). Three of the A+ cases have been described previously (Lee et al., 2013; Perry et al., 2013).

Autopsies in three of six A+ cases confirmed dual FTLN/AD pathology (two are shown in Figure 2). In case 1 with the *TARDBP* variant, the diagnosis was FTLN with unclassifiable FTLN-TDP-43, featuring frequent crescent-shaped, round, skein-like, and granular TDP-43 neuronal inclusions, scattered intranuclear neuronal inclusions in several cortical and subcortical areas, along with abundant β -amyloid neuritic plaques. Lack of tau neuronal inclusions or tau positivity in dystrophic neurites precluded the pathological diagnosis of AD. An autopsy performed on the brother of case 1, who carried

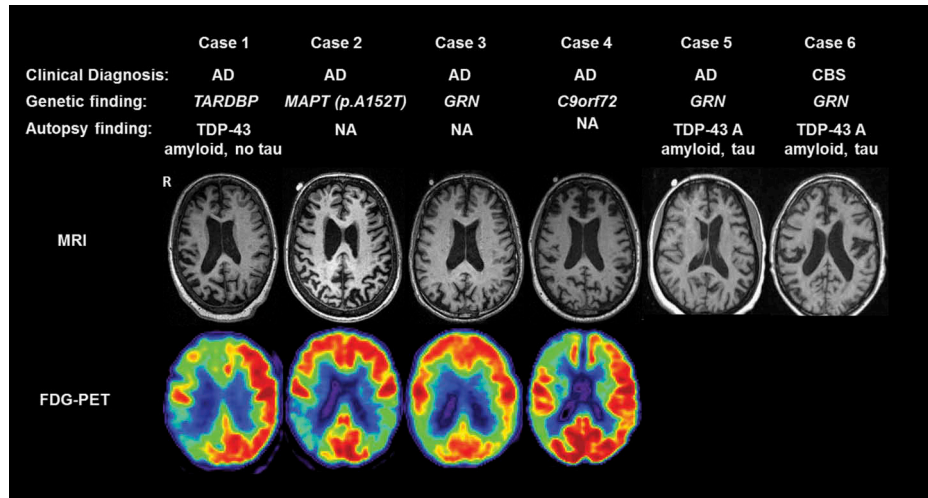


Figure 1. Overview of six A+ f-FTLD cases. Diagnosis, genetic findings, autopsy diagnoses and representative imaging in the six cases identified as A+. [To view this figure in color, please see the online version of this Journal.]

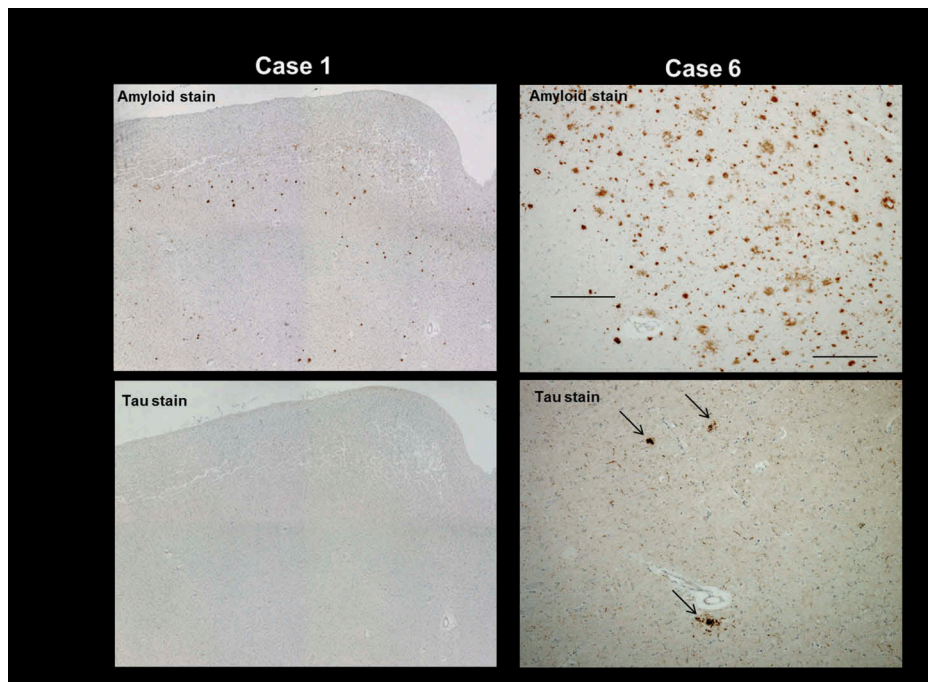


Figure 2. Pathological findings in two A+ f-FTLD cases. Representative pathological findings from the angular gyrus in two of the A+ cases shown in Figure 1: case 1 (top and bottom left) and case 6 (top and bottom right). Top rows show amyloid plaques using 4G8 antibody. Bottom rows show tau staining using CP-13 antibody, with arrows pointing to tau components of plaques in case 6 (bottom right). Tau-positive threads can also be seen throughout the section. In case 1, tau staining is negative (bottom left). [To view this figure in color, please see the online version of this Journal.]

the same *TARDBP* variation but was not clinically evaluated at UCSF, showed very similar pathology. Case 5 had TDP-43 type A inclusions (Mackenzie et al., 2010) along with AD pathology including CERAD frequent plaques and Braak Stage V neurofibrillary tangles (high-likelihood AD; Hyman & Trojanowski, 1997). Case 6 had

FTLD-TDP-43 type A pathology and AD-related neuropathological changes including CERAD moderate plaques and Braak IV–V neurofibrillary tangles (intermediate likelihood AD; Hyman & Trojanowski, 1997).

All of the A+ cases carried the apolipoprotein E (APOE) ϵ_4 allele compared with 8 of the 22 A– cases in whom APOE

Table 1. Demographics and clinical characteristics of A+ and A- groups.

Test (maximal score)	Without amyloid (n = 24)	With amyloid (n = 6)	p-Value
Age at MRI	58.7	65.7	.02
Percent female	21	50	
Education (years)	14.6	16	.3
Age at disease onset (range)	52.5 (42–67)	59.8 (56–69)	.02
Duration between onset and MRI (range)	6.2 (0–16)	5.6 (2–14)	.9
MMSE (30)	25	17.3	.003
Memory			
9-item CVLT delayed recall (9)	4.0	1.66	.08
Benson figure delayed recall (17)	7.4	4.7	.2
Language			
15-item Boston Naming Test (15)	11.9	7.3	.004
Syntax comprehension (5)	4.2	2.7	.004
Repetition (5)	3.6	1.7	.004
Visuospatial			
Benson figure copy (17)	14.5	11.6	.08
VOSP number location (10)	8.5	7.6	.6
Arithmetic problem solving (5)	3.6	3.4	.7
Executive functions			
Modified trails: correct within 120" (14)	12.1	10.0	.5
Category fluency (animals)	10.8	6.5	.05
Letter fluency (D words)	7.6	7.2	.8
Stroop interference: correct in 60"	30.1	9.3	.04
Digits backward (max span)	3.8	2.3	.04
Behavior			
Geriatric depression scale – self-report (30)	7.7	5.0	.3
NPI severity score	9.7	10.3	.9

Note: MMSE, mini-mental status examination; CVLT, California verbal learning task; VOSP, visual object and space perception battery; NPI, neuropsychiatric inventory.

status was available ($\chi^2 7.63, p < .01$). In five of the six A+ cases, the initial clinical diagnosis was AD, whereas this was the initial diagnosis in three of the amyloid-negative cases ($\chi^2 12.32, p < .001$). Diagnoses in the A- cases included behavioral variant frontotemporal dementia (bvFTD), non-fluent variant of primary progressive aphasia, progressive supranuclear palsy, and amyotrophic lateral sclerosis. Although all the A+ cases were recognized as atypical (see Supplemental data), the features leading to AD diagnoses included early problems with memory (cases 1 and 3), visuospatial functions (case 2), calculations (case 4), and logopenic type aphasia (case 5). Case 6 was diagnosed with corticobasal syndrome. The A+ group was older at symptom onset and time of scanning, but the duration between onset and time of scan was the same as that in A- (Table 1). The A+ also had lower scores on the MMSE, several language tasks, and some frontal/executive function measures. Verbal memory and visuospatial scores were also lower in the A+ group, although the difference did not reach statistical significance.

Imaging

MRI

MRIs suitable for group analysis were available for 4 A+ (mean age 59.8) and 24 A- patients (mean age 58.7).

Case 2's MRI done at 4 T was analyzed separately and case 5's MRI was excluded due to motion artifact. For comparison, a group of 30 MRIs from CNs was assembled (mean age 60.1), including 11 scanned at 1.5 T and 19 at 3 T. Compared with CN, the A- group showed extensive frontal and anterior temporal volume loss involving the ventral, dorsal, lateral, and medial frontal regions, as well as the striatum and thalamus (Figure 3). In the A+ group, volume loss involved the lateral parietal and temporal regions, and the hippocampus. When the A+ group was compared directly with the A- group, A+ showed decreased volume in the medial and lateral parietal regions and hippocampus, including a subset of voxels in the right parietal regions that survived the multiple comparisons threshold (no regions were significant in the A+ < A- contrast). To examine whether the amyloid effect might overlap with the effect of APOE e4, we compared the 8 A- APOE e4 carriers to the 16 A- non-APOE e4 carriers, and found no significant differences (data not shown).

Case 2 was compared to a group of 10 CN individuals who were all aged 68 and who were scanned at 4 T. Similar to the rest of the A+ group, she showed a posterior pattern of atrophy (eFigure 1 in the Supplemental data).

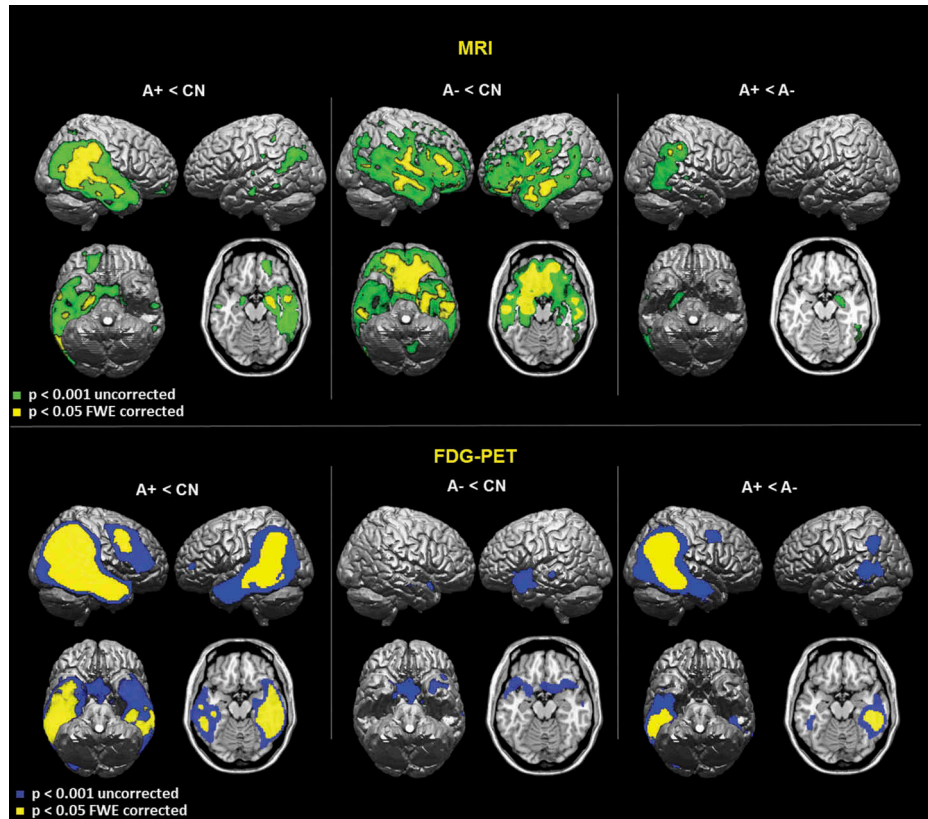


Figure 3. Voxelwise analysis of MRI and PET imaging. Statistical maps for comparisons of gray matter volumes (top) and FDG metabolism (bottom) in A+ and A− groups compared with CN and each other, displayed on a canonical brain in MNI space. [To view this figure in color, please see the online version of this Journal.]

FDG-PET

FDG-PET was available for 4 A+ (mean age 67) and 11 A− patients (mean age 59). Their images were compared with those from 25 CNs (mean age of 66). The A− group showed hypometabolism in the anterior temporal and medial and orbital frontal regions (Figure 3), while the A+ group showed hypometabolism in the right temporo-parietal region and the right middle frontal gyrus. When directly compared with the A− group, the A+ group showed a metabolic deficit in the right temporoparietal region.

Discussion

The goal of this study was to characterize the impact of amyloid pathology on the pattern of neurodegeneration and clinical presentation in FTL D. We identified six cases with significant amyloid pathology in a group of 30 patients with f-FTLD. Clinically, all but one of the A+ patients had features that led to a diagnosis of AD, and the A+ group showed parietal/posterior temporal atrophy and hypometabolism in a pattern typical for AD. These data provide strong evidence that amyloid, when

present, exerts a significant influence on the pattern of neurodegeneration and clinical presentation in f-FTLD. The findings have implications for the diagnosis, treatment, and biology of neurodegenerative disease.

Clinicians should be aware that the clinical presentation and distribution of anatomical and metabolic abnormalities in FTL D can be modified by amyloid co-pathology, with increased involvement of posterior structures. Several studies have identified patients diagnosed clinically with FTL D who were found to have amyloid by imaging or autopsy (Davies et al., 2005; Josephs, Tsuboi, Cookson, Watt, & Dickson, 2004; Perry et al., 2013; Rabinovici et al., 2011). These cases have usually been interpreted as misdiagnoses, yet most of the imaging studies did not include autopsies, and many of the autopsy studies did not directly address the issue of dual pathology or were done before TDP-43 was identified as a protein relevant to FTL D.

Our finding of several A+ cases in a group of patients with FTL D pathology indicates that, in unusual cases where FTL D is a consideration and clinical and/or biomarker evidence of amyloid pathology is found, that co-occurring FTL D and amyloid should be considered. Furthermore, the specific choice of biomarker may affect

this issue. We classified patients as A+ based on amyloid PET, which becomes abnormal with a moderate level of plaque pathology. cerebrospinal fluid (CSF) A β ₄₂ levels may be more sensitive to the presence of plaques than amyloid imaging (Fagan et al., 2006), increasing the risk that clinicians would erroneously attribute symptoms to “pure” AD in cases of AD/FTLD co-pathology when using CSF biomarkers. These issues can only be addressed with studies that combine CSF, amyloid imaging, autopsy, and other biomarkers of FTLN pathology as they become available.

Regarding treatment, clinical trials aimed at modifying the course of neurodegenerative disease have usually focused on a single protein, most commonly amyloid (Doody et al., 2014; Salloway et al., 2014). The failure of these studies has caused some to consider that concurrent treatment for multiple protein abnormalities may be necessary in AD, where the importance of both amyloid and tau are well established (Bloom, 2014). The current findings extend this logic to FTLN and suggest that treatment for both amyloid and whatever FTLN protein is involved in each patient may be necessary to treat all factors leading to neurodegeneration.

From a biological perspective, the findings raise questions about the factors influencing the accumulation of amyloid in FTLN and the mechanisms through which amyloid mediates its effect in the brain. In a previous report, we suggested that *GRN* mutations may increase risk for AD and accelerate AD pathology (Perry et al., 2013). In the current study, amyloid was also observed with *C9ORF72* and *TARDBP* mutations, indicating that the phenomenon is not limited to *GRN*. Furthermore, all patients with amyloid were APOE e4 carriers, suggesting that AD risk factors are more likely to be driving the accumulation of amyloid than were the FTLN mutations. This is consistent with previous studies linking APOE e4 to AD co-pathology in autopsy samples (Josephs et al., 2004). It is notable, however, that not all subjects with APOE e4 had amyloid, indicating that additional factors must play a role. Prior studies of the effect of APOE e4 in *GRN* carriers have come to varied conclusions, with some showing modified clinical features with APOE e4 (Rademakers et al., 2007) and others showing no effect (Bruni et al., 2007). The fact that we saw no effect of APOE e4 in patients who did not have amyloid suggests that APOE e4 may only have a meaningful impact in FTLN if it results in amyloid accumulation. Even if FTLN genes are not independent risk factors for AD, they may still interact with AD risk factors to accelerate AD-related neurodegeneration (Perry et al., 2013). Another issue raised by these findings is whether the effect of amyloid in the brain is always mediated through tau. The fact that case 1 showed no tau at autopsy but still showed AD-like clinical and imaging features indicates that this may be possible.

A potential limitation to our study is the larger representation of C9 carriers in the control group. Although this may potentially change the structural anatomy of the control group, we would expect it to do so in favor of more posterior involvement (Sha et al., 2012) and therefore dilute any potential difference between the A+ and A– groups in posterior brain structures. Since the anatomical changes involving the parietal lobes in the A+ group were still observed despite the large representation of C9 carriers in the A– control group, we are confident that this represents a true difference between the two groups.

The p.A152T variant of the *MAPT* gene, which was present in one A+ case who was diagnosed with corticobasal syndrome due to AD, merits special consideration. The role of this variant in neurodegenerative disease is still being characterized. A recent genetic analysis in over 15,000 cases indicated that this rare variant can be present in cognitively healthy individuals and confers an intermediate risk of neurodegenerative disease (including FTD and AD) rather than functioning as a dominant mutation (Coppola et al., 2012). p.A152T has been associated with increased formation of tau oligomers and inefficient microtubule assembly (Coppola et al., 2012), and with fragmentation and hyperphosphorylation of tau and neurodegeneration in induced pluripotent stem cells (Fong et al., 2013). Most p.A152T cases with autopsy have had tauopathies with low levels of amyloid (Kara et al., 2012; Kovacs et al., 2011). A simple interpretation of these findings would be to conclude that our A+ with this variant simply has AD; however, considering this case in light of the others in our analysis requires a more complex interpretation. Our results suggest that AD risk factors can interact with genetic risk factors for FTLN, resulting in amyloid pathology being superimposed on FTLN. In the same way, p.A152T may primarily be a risk factor for tauopathy and present with an FTLN-like clinical picture in the absence of additional AD risk factors, but with clinical and pathological features of AD when such risk factors are present. No studies have examined potential interactions between p.A152T and AD risk factors, likely because of small numbers, but such studies would be informative in clinical cohorts and in preclinical models.

Although the number of A+ cases in this group was relatively small, the clinical and imaging data provide a clear picture of the effect of amyloid. Our analysis only included f-FTLN cases because even living f-FTLN patients who are amyloid positive can be reasonably assumed to have dual FTLN/amyloid pathology. These findings, however, have potential implications for sporadic FTLN (Padovani et al., 2013) – an issue that can be addressed in pathologically confirmed groups. Our findings highlight the danger of making conclusions about the pathological underpinnings of a patient’s symptoms based on only a single biomarker. They stress the continuing

importance of thorough clinical assessment, which remains an extremely sensitive tool for detecting the effects of specific proteins on neurological functioning. Future clinical and preclinical studies should pay more attention to mixed pathology if we are to fully understand the process by which protein abnormalities lead to neurodegeneration.

Acknowledgments

We would like to thank all research participants without which this study would not be possible. We also thank the contributors who collected samples used in this study, as well as patients and their families, whose help and participation made this work possible.

Disclosure statement

No potential conflict of interest was reported by the authors.

Funding

Samples from the National Cell Repository for Alzheimer's Disease (NCRAD), which receives government support under a cooperative agreement grant [U24 AG21886] awarded by the National Institute on Aging (NIA), were used in this study. Additional support for this study was provided by NIH grants [RC1 AG035610] and [R01 AG26938]. Dr. Rosen is funded by NIH grants [R01 AG032306], [K24 AG045333], [P50 AG02350], [P01 AG019724-09], State of CA DHS: 09-11410 and the John Douglas French Alzheimer's Foundation. Dr. Howard Rosen and Dr. Georges Naasan had full access to all of the data in the study and take responsibility for the integrity of the data and the accuracy of the data analysis. All authors contributed to study conception and design, data acquisition, analysis and interpretation; drafting and critically revising article; approving the final version to be published.

Supplemental data and research data

Supplemental data for this article can be accessed at <http://dx.doi.org/10.1080/13554794.2015.1046458>.

References

- Bettcher, B. M., Wilhelm, R., Rigby, T., Green, R., Miller, J. W., Racine, C. A., ... Kramer, J. H. (2012). C-reactive protein is related to memory and medial temporal brain volume in older adults. *Brain, Behavior, and Immunity*, *26*, 103–108. doi:10.1016/j.bbi.2011.07.240
- Bloom, G. S. (2014). Amyloid-beta and tau: The trigger and bullet in alzheimer disease pathogenesis. *JAMA Neurology*. doi:10.1001/jamaneurol.2013.5847
- Bruni, A. C., Momeni, P., Bernardi, L., Tomaino, C., Frangipane, F., Elder, J., ... Rogaevea, E. (2007). Heterogeneity within a large kindred with frontotemporal dementia: A novel progranulin mutation. *Neurology*, *69*, 140–147. doi:10.1212/01.wnl.0000265220.64396.b4
- Brunnström, H., Gustafson, L., Passant, U., & Englund, E. (2009). Prevalence of dementia subtypes: A 30-year retrospective survey of neuropathological reports. *Archives of Gerontology and Geriatrics*, *49*, 146–149. doi:10.1016/j.archger.2008.06.005
- Clark, C. M., Schneider, J. A., Bedell, B. J., Beach, T. G., Bilker, W. B., Mintun, M. A., ... Skovronsky, D. M. (2011). Use of florbetapir-PET for imaging beta-amyloid pathology. *JAMA: The Journal of the American Medical Association*, *305*, 275–283. doi:10.1001/jama.2010.2008
- Coppola, G., Chinnathambi, S., Lee, J. J., Dombroski, B. A., Baker, M. C., Soto-Ortolaza, A. I., ... Geschwind, D. H. (2012). Evidence for a role of the rare p.A152T variant in MAPT in increasing the risk for FTD-spectrum and Alzheimer's diseases. *Human Molecular Genetics*, *21*, 3500–3512. doi:10.1093/hmg/ddsl61
- Coppola, G., Karydas, A., Rademakers, R., Wang, Q., Baker, M., Hutton, M., ... Geschwind, D. H. (2008). Gene expression study on peripheral blood identifies progranulin mutations. *Annals of Neurology*, *64*, 92–96. doi:10.1002/ana.21397
- Davies, R. R., Hodges, J. R., Kril, J. J., Patterson, K., Halliday, G. M., & Xuereb, J. H. (2005). The pathological basis of semantic dementia. *Brain: A Journal of Neurology*, *128*, 1984–1995. doi:10.1093/brain/awh582
- Doody, R. S., Thomas, R. G., Farlow, M., Iwatsubo, T., Vellas, B., Joffe, S., ... Mohs, R. (2014). Phase 3 trials of solanezumab for mild-to-moderate Alzheimer's disease. *The New England Journal of Medicine*, *370*, 311–321. doi:10.1056/NEJMoa1312889
- Echavari, C., Caballero, M. C., Aramendia, A., Garcia-Bragado, F., & Tunon, T. (2011). Multiprotein deposits in neurodegenerative disorders: Our experience in the tissue brain bank of Navarra. *The Anatomical Record: Advances in Integrative Anatomy and Evolutionary Biology*, *294*, 1191–1197. doi:10.1002/ar.21413
- Fagan, A. M., Mintun, M. A., Mach, R. H., Lee, S. Y., Dence, C. S., Shah, A. R., ... Holtzman, D. M. (2006). Inverse relation between in vivo amyloid imaging load and cerebrospinal fluid Aβ42 in humans. *Annals of Neurology*, *59*, 512–519. doi:10.1002/ana.v59.3
- Fogel, B. L., Pribadi, M., Pi, S., Perlman, S. L., Geschwind, D. H., & Coppola, G. (2012). C9ORF72 expansion is not a significant cause of sporadic spinocerebellar ataxia. *Movement Disorders: Official Journal of the Movement Disorder Society*, *27*, 1835–1836. doi:10.1002/mds.25245
- Fong, H., Wang, C., Knoferle, J., Walker, D., Balestra, M. E., Tong, L. M., ... Huang, Y. (2013). Genetic correction of tauopathy phenotypes in neurons derived from human induced pluripotent stem cells. *Stem Cell Reports*, *1*, 226–234. doi:10.1016/j.stemcr.2013.08.001
- Grinberg, L. T., Wang, X., Wang, C., Sohn, P. D., Theofilas, P., Sidhu, M., ... Seeley, W. W. (2013). Argyrophilic grain disease differs from other tauopathies by lacking tau acetylation. *Acta Neuropathologica*, *125*, 581–593. doi:10.1007/s00401-013-1080-2
- Hyman, B. T., & Trojanowski, J. Q. (1997). Editorial on consensus recommendations for the postmortem diagnosis of Alzheimer disease from the National Institute on Aging and the Reagan Institute Working Group on diagnostic criteria for the neuropathological assessment of Alzheimer disease. *Journal of Neuropathology and Experimental Neurology*, *56*, 1095–1097. doi:10.1097/00005072-199710000-00002
- Jack Jr., C. R., & Holtzman, D. M. (2013). Biomarker modeling of Alzheimer's disease. *Neuron*, *80*, 1347–1358. doi:10.1016/j.neuron.2013.12.003
- Jack Jr., C. R., Knopman, D. S., Jagust, W. J., Shaw, L. M., Aisen, P. S., Weiner, M. W., ... Trojanowski, J. Q. (2010).

- Hypothetical model of dynamic biomarkers of the Alzheimer's pathologic cascade. *The Lancet Neurology*, 9, 119–128. doi:10.1016/S1474-4422(09)70299-6
- Josephs, K. A., Ahmed, Z., Katsuse, O., Parisi, J. F., Boeve, B. F., Knopman, D. S., ... Dickson, D. W. (2007). Neuropathologic features of frontotemporal lobar degeneration with ubiquitin-positive inclusions with progranulin gene (PGRN) mutations. *Journal of Neuropathology and Experimental Neurology*, 66, 142–151. doi:10.1097/nen.0b013e31803020cf
- Josephs, K. A., Tsuboi, Y., Cookson, N., Watt, H., & Dickson, D. W. (2004). Apolipoprotein E {varepsilon}4 is a determinant for Alzheimer-type pathologic features in tauopathies, synucleinopathies, and frontotemporal degeneration. *Archives of Neurology*, 61, 1579–1584.
- Kara, E., Ling, H., Pittman, A. M., Shaw, K., De Silva, R., Simone, R., ... Revesz, T. (2012). The MAPT p.A152T variant is a risk factor associated with tauopathies with atypical clinical and neuropathological features. *Neurobiology of Aging*, 33, 2231.e7–2231.e14. doi:10.1016/j.neurobiolaging.2012.04.006
- Kelley, B. J., Haidar, W., Boeve, B. F., Baker, M., Graff-Radford, N. R., Krefft, T., ... Petersen, R. C. (2009). Prominent phenotypic variability associated with mutations in progranulin. *Neurobiology of Aging*, 30, 739–751. doi:10.1016/j.neurobiolaging.2007.08.022
- Kovacs, G. G., Wöhler, A., Ströbel, T., Botond, G., Attems, J., & Budka, H. (2011). Unclassifiable tauopathy associated with an A152T variation in MAPT exon 7. *Clinical Neuropathology*, 30, 3–10. doi:10.5414/NPP30003
- Kramer, J. H., Jurik, J., Sha, S. J., Rankin, K. P., Rosen, H. J., Johnson, J. K., & Miller, B. L. (2003). Distinctive neuropsychological patterns in frontotemporal dementia, semantic dementia, and Alzheimer disease. *Cognitive and Behavioral Neurology*, 16, 211–218. doi:10.1097/00146965-200312000-00002
- Kramer, J. H., Mungas, D., Reed, B. R., Wetzel, M. E., Burnett, M. M., Miller, B. L., ... Chui, H. C. (2007). Longitudinal MRI and cognitive change in healthy elderly. *Neuropsychology*, 21, 412–418. doi:10.1037/0894-4105.21.4.412
- Le Ber, I., Camuzat, A., Hannequin, D., Pasquier, F., Guedj, E., Rovelet-Lecrux, A., ... Brice, A. (2008). Phenotype variability in progranulin mutation carriers: A clinical, neuropsychological, imaging and genetic study. *Brain: A Journal of Neurology*, 131, 732–746. doi:10.1093/brain/awn012
- Lee, S. E., Tartaglia, M. C., Yener, G., Genc, S., Seeley, W. W., Sanchez-Juan, P., ... Miller, B. L. (2013). Neurodegenerative disease phenotypes in carriers of MAPT p.A152T, a risk factor for frontotemporal dementia spectrum disorders and Alzheimer disease. *Alzheimer Disease & Associated Disorders*, 27, 302–309. doi:10.1097/WAD.0b013e31828cc357
- Lehmann, M., Ghosh, P. M., Madison, C., Laforce Jr., R., Corbetta-Rastelli, C., Weiner, M. W., ... Rabinovici, G. D. (2013). Diverging patterns of amyloid deposition and hypometabolism in clinical variants of probable Alzheimer's disease. *Brain: A Journal of Neurology*, 136, 844–858. doi:10.1093/brain/aws327
- Mackenzie, I. R. A., & Rademakers, R. (2007). The molecular genetics and neuropathology of frontotemporal lobar degeneration: Recent developments. *Neurogenetics*, 8, 237–248. doi:10.1007/s10048-007-0102-4
- Mackenzie, I. R., Neumann, M., Bigio, E. H., Cairns, N. J., Alafuzoff, I., Kril, J., ... Mann, D. M. (2010). Nomenclature and nosology for neuropathologic subtypes of frontotemporal lobar degeneration: An update. *Acta Neuropathologica*, 119, 1–4. doi:10.1007/s00401-009-0612-2
- Mormino, E. C., Kluth, J. T., Madison, C. M., Rabinovici, G. D., Baker, S. L., Miller, B. L., ... Jagust, W. J. (2009). Episodic memory loss is related to hippocampal-mediated amyloid deposition in elderly subjects. *Brain: A Journal of Neurology*, 132, 1310–1323. doi:10.1093/brain/awn320
- Mueller, S. G., Laxer, K. D., Barakos, J., Cheong, I., Garcia, P., & Weiner, M. W. (2009). Subfield atrophy pattern in temporal lobe epilepsy with and without mesial sclerosis detected by high-resolution MRI at 4 Tesla: Preliminary results. *Epilepsia*, 50, 1474–1483. doi:10.1111/j.1528-1167.2009.02010.x
- Padovani, A., Premi, E., Pilotto, A., Gazzina, S., Cosseddu, M., Archetti, S., ... Borroni, B. (2013). Overlap between frontotemporal dementia and Alzheimer's disease: Cerebrospinal fluid pattern and neuroimaging study. *Journal of Alzheimer's Disease: JAD*, 36, 49–55. doi:10.3233/JAD-121969
- Perry, D. C., Lehmann, M., Yokoyama, J. S., Karydas, A., Lee, J. J., Coppola, G., ... Rabinovici, G. (2013). Progranulin mutations as risk factors for Alzheimer disease. *JAMA Neurology* (1–5). doi:10.1001/2013.jamaneurol.393
- Rabinovici, G. D., Furst, A. J., O'Neil, J. P., Racine, C. A., Mormino, E. C., Baker, S. L., ... Jagust, W. J. (2007). 11C-PIB PET imaging in Alzheimer disease and frontotemporal lobar degeneration. *Neurology*, 68, 1205–1212. doi:10.1212/01.wnl.0000259035.98480.ed
- Rabinovici, G. D., Rosen, H. J., Alkalay, A., Kornak, J., Furst, A. J., Agarwal, N., ... Jagust, W. J. (2011). Amyloid vs FDG-PET in the differential diagnosis of AD and FTL. *Neurology*, 77, 2034–2042. doi:10.1212/WNL.0b013e31823b9c5e
- Rademakers, R., Baker, M., Gass, J., Adamson, J., Huey, E. D., Momeni, P., ... Hutton, M. (2007). Phenotypic variability associated with progranulin haploinsufficiency in patients with the common 1477C->T (Arg493X) mutation: An international initiative. *Lancet Neurology*, 6, 857–868. doi:10.1016/S1474-4422(07)70221-1
- Rohrer, J. D., & Warren, J. D. (2011). Phenotypic signatures of genetic frontotemporal dementia. *Current Opinion in Neurology*, 24, 542–549. doi:10.1097/WCO.0b013e318234cd442
- Rosen, H. J., Alcantar, O., Rothlind, J., Sturm, V., Kramer, J. H., Weiner, M., & Miller, B. L. (2010). Neuroanatomical correlates of cognitive self-appraisal in neurodegenerative disease. *Neuroimage*, 49, 3358–3364. doi:10.1016/j.neuroimage.2009.11.041
- Rosen, H. J., Gorno-Tempini, M. L., Goldman, W. P., Perry, R. J., Schuff, N., Weiner, M., ... Miller, B. L. (2002). Patterns of brain atrophy in frontotemporal dementia and semantic dementia. *Neurology*, 58, 198–208. doi:10.1212/WNL.58.2.198
- Salloway, S., Sperling, R., Fox, N. C., Blennow, K., Klunk, W., Raskind, M., ... Brashear, H. R. (2014). Two phase 3 trials of bapineuzumab in mild-to-moderate Alzheimer's disease. *The New England Journal of Medicine*, 370, 322–333. doi:10.1056/NEJMoa1304839
- Sha, S. J., Takada, L. T., Rankin, K. P., Yokoyama, J. S., Rutherford, N. J., Fong, J. C., ... Boxer, A. L. (2012). Frontotemporal dementia due to C9ORF72 mutations: Clinical and imaging features. *Neurology*, 79, 1002–1011. doi:10.1212/WNL.0b013e318268452e