

## **UC Davis**

### **UC Davis Previously Published Works**

#### **Title**

Functional Adrenal Collision Tumor in a Patient with Cushing's Syndrome.

#### **Permalink**

<https://escholarship.org/uc/item/0ns0087d>

#### **Authors**

Zhou, Cathy  
Fananapazir, Ghaneh  
Campbell, Michael J

#### **Publication Date**

2020

#### **DOI**

10.1155/2020/7415762

Peer reviewed

## Case Report

# Functional Adrenal Collision Tumor in a Patient with Cushing's Syndrome

Cathy Zhou <sup>1</sup>, Ghaneh Fananapazir <sup>1</sup> and Michael J. Campbell <sup>2</sup>

<sup>1</sup>Department of Radiology, University of California, Davis Medical Center, Sacramento, CA, USA

<sup>2</sup>Department of Surgery, University of California, Davis Medical Center, Sacramento, CA, USA

Correspondence should be addressed to Michael J. Campbell; [mjcampb@ucdavis.edu](mailto:mjcampb@ucdavis.edu)

Received 5 February 2020; Revised 2 November 2020; Accepted 16 November 2020; Published 14 December 2020

Academic Editor: J. Paul Frindik

Copyright © 2020 Cathy Zhou et al. This is an open access article distributed under the Creative Commons Attribution License, which permits unrestricted use, distribution, and reproduction in any medium, provided the original work is properly cited.

Adrenal collision tumors are rare and produce unique diagnostic challenges for clinicians. We report the case of a 45-year-old woman with obesity and diabetes mellitus and an incidentally-discovered adrenal mass containing macroscopic fat, thought to be a myelolipoma. A functional workup confirmed adrenocorticotrophic hormone- (ACTH-) independent Cushing's syndrome. The patient underwent a successful laparoscopic adrenalectomy with pathology showing an adrenal collision tumor consisting of an adrenocortical adenoma and a myelolipoma. Postoperatively, the clinical symptoms, body mass index, and hemoglobin A1C all improved. Clinicians should consider a functional workup in patients with radiographically diagnosed myelolipomas as some may prove to be hormonally active collision tumors.

## 1. Introduction

“Adrenal collision tumor” is the radiographic term used to describe the appearance of a single radiographic mass consisting of two histologically distinct adrenal neoplasms. Adrenal collision tumors involving a myelolipoma are particularly challenging because radiologists are trained to label adrenal lesions with any amount of macroscopic fat as myelolipomas [1]. Clinicians are trained that radiographically diagnosed myelolipomas do not need further imaging or a biochemical evaluation for autonomous hormone production like other adrenal tumors. We report a case of a 45-year-old woman with Cushing's syndrome secondary to an adrenal tumor diagnosed as a myelolipoma on abdominal imaging. Ultimately, the patient was found to have an adrenal collision tumor composed of a functioning adrenocortical adenoma and a myelolipoma. Only five similar cases have been previously described and are reviewed in this report [2–6].

*1.1. Case Presentation.* In November 2012, a 45-year-old Caucasian woman presented to her primary care physician with lower abdominal pain. At the time of presentation, her

medical history was notable for obesity (weight = 183.2 kg and body mass index (BMI) 61.6 mg/m<sup>2</sup>), type 2 diabetes mellitus (hemoglobin A1C (HbA1C) = 7.5%), hypertension, and recurrent episodes of cellulitis. A contrast-enhanced CT scan of the abdomen and pelvis in the portal venous phase was obtained that showed no source for her abdominal pain but did note an incidental 5.5 × 4.0 cm left adrenal tumor containing macroscopic fat and reported as a myelolipoma (Figure 1(a)). This tumor had grown from a CT scan in April 2007, where it measured 4.4 × 3.3 cm (Figure 1(b)). The right adrenal appeared normal on both scans.

In September 2014, the patient was referred to an endocrinologist for worsening diabetes mellitus. At this visit, her weight was 184.7 kg with a BMI of 61.9 mg/m<sup>2</sup> and HbA1C of 9.2%. Because of clinical concern for hypercortisolism, a functional workup was initiated. A 1 mg dexamethasone suppression test revealed a postsuppression cortisol of 9.3 μg/d (reference range <1.8 μg/dL). Serum aldosterone was 4.7 ng/dL with a renin activity of 0.3 ng/ml/hr. Plasma free metanephrines were less than the upper limit of normal, and a morning adrenocorticotrophic hormone (ACTH) was 16 ng/L (reference range 6–50 ng/L). The patient was lost to follow-up before completing further testing.

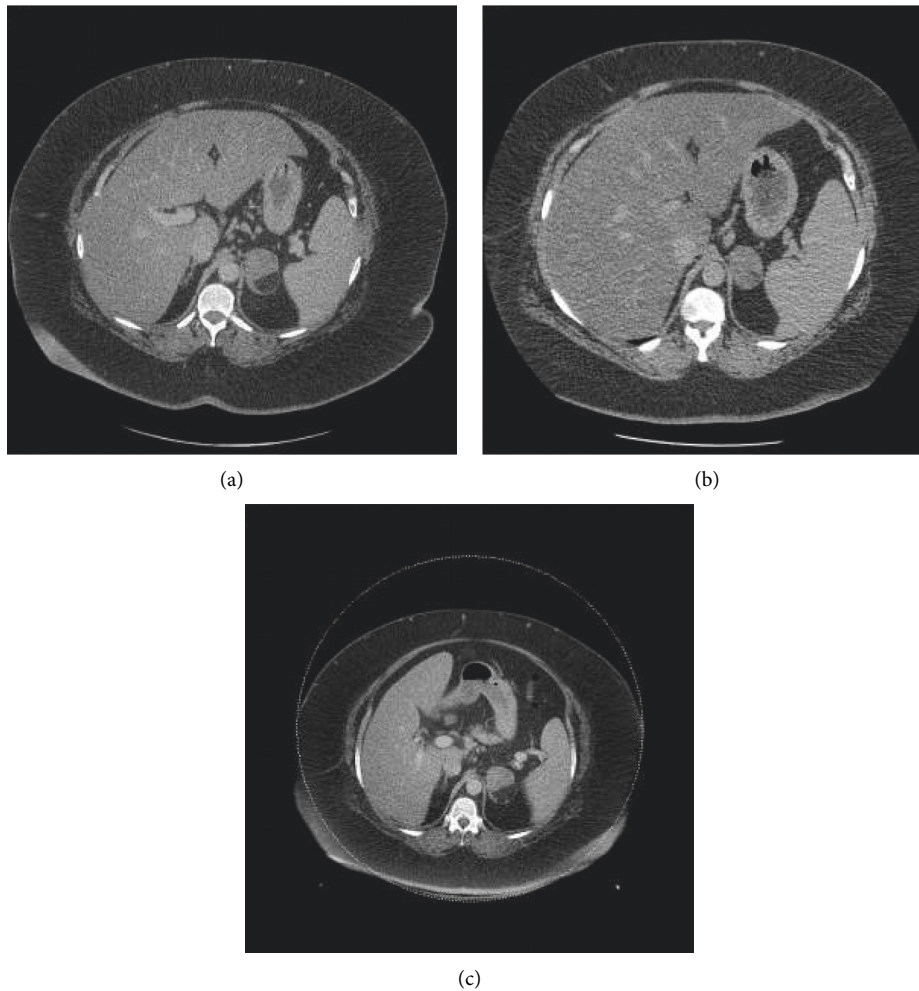


FIGURE 1: A CT for abdominal pain in November 2012 revealed a presumed adrenal myelolipoma with a focus of macroscopic fat (a). In comparing to a prior exam from April 2007 (b), this mass had grown in size, and subsequent imaging from April 2016 (c) continued to demonstrate growth.

In June 2015, she reestablished care with her endocrinologist. Physical exam was notable for obesity, but without other clinical signs of Cushing's syndrome, including moon facies, buffalo hump, or striae. A dual-energy X-ray absorptiometry (DEXA) scan showed normal bone health. The 24-hour urine cortisol level was  $54.1 \mu\text{g}/\text{day}$  (reference range  $<45 \mu\text{g}/\text{day}$ ). Repeat 24-hour urine cortisol was again elevated at  $47.5 \mu\text{g}/\text{day}$ . ACTH was  $8 \text{ ng}/\text{L}$  (reference range  $6\text{--}50 \text{ ng}/\text{L}$ ) and dehydroepiandrosterone sulfate (DHEAS) was suppressed at  $<15 \mu\text{g}/\text{dL}$  (reference range  $32\text{--}240 \mu\text{g}/\text{dL}$ ). Repeat 1-mg dexamethasone suppression test was elevated at  $13.5 \mu\text{g}/\text{dL}$  (reference range  $<1.8 \mu\text{g}/\text{dL}$ ). BMI was  $62.4 \text{ kg}/\text{m}^2$  (weight  $186.1 \text{ kg}$ ), and HgA1C was  $9.0\%$ . Given continued symptomatology and positive lab values, the patient was then referred to endocrine surgery with suspicion for Cushing's syndrome from her left adrenal myelolipoma but failed to make her appointments.

In March 2016, the patient was seen by endocrine surgery for consideration of a laparoscopic left adrenalectomy for Cushing's syndrome. A repeat CT showed the

tumor had increased in size to  $5.8 \text{ cm}$  and was still partially composed of macroscopic fat and consistent with a myelolipoma (Figure 1). BMI was  $65.1 \text{ kg}/\text{m}^2$  (weight =  $188.7 \text{ kg}$ ) and HbA1C was  $10.0\%$ . She underwent an uncomplicated laparoscopic adrenalectomy in October 2017. The case was performed via a standard transabdominal approach. The patient had a generous amount of intraabdominal fat which was mobilized with the colon and spleen from the left adrenal gland. She required an increased pneumoperitoneum pressure to facilitate exposure ( $17 \text{ cm}$  of water). The remainder of her case and postoperative course were unremarkable. On surgical pathology, she was noted to have a  $6.7 \text{ cm}$  adrenal collision tumor comprised of a  $4 \text{ cm}$  adrenocortical adenoma and a  $2.7 \text{ cm}$  myelolipoma (Figure 2). Postoperatively, the patient was placed on corticosteroid replacement, which was tapered over the course of a year and a half without significant symptoms of adrenal insufficiency. 24 hour urine cortisol following discontinuation of steroids normalized to  $7.6 \mu\text{g}/24 \text{ hours}$ . Her weight decreased to  $149.4 \text{ kg}$  with a BMI of  $51.6$  and HbA1c of  $7.3\%$  (Figure 3).

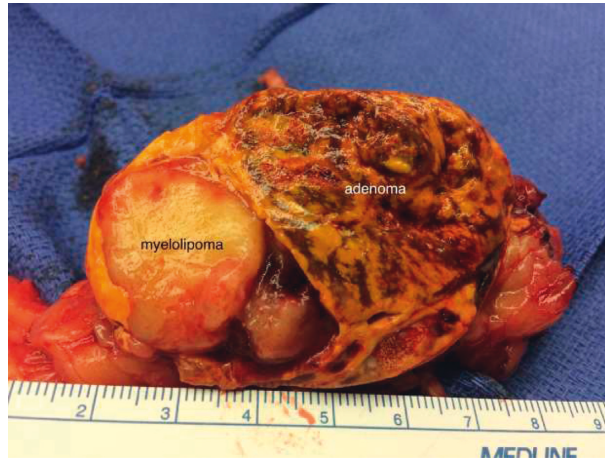

FIGURE 2: The surgical specimen demonstrates the characteristic macroscopic fat component of the myelolipoma with an adjacent well-circumscribed solid golden yellow adenoma.

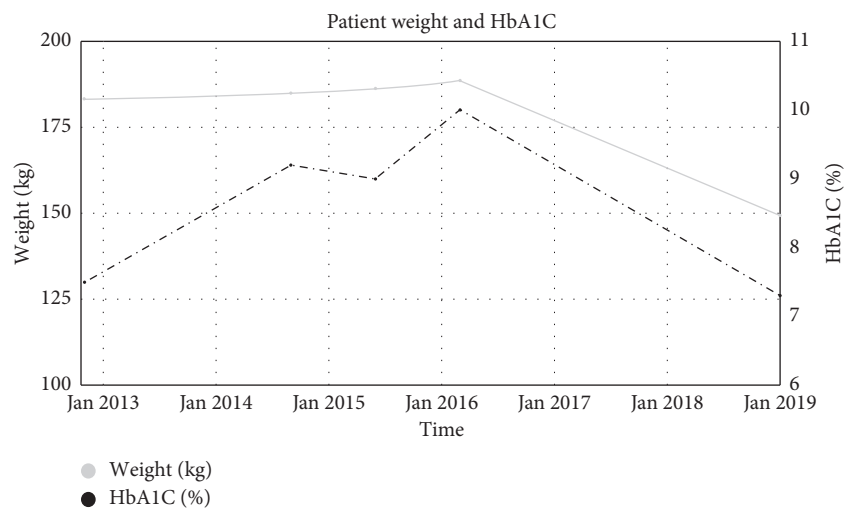


FIGURE 3: Patient weight and hemoglobin A1C graphed over time.

## 2. Discussion

We present the case of a 45-year-old woman with a radiographically diagnosed myelolipoma and ACTH independent Cushing's syndrome that underwent laparoscopic left adrenalectomy with surgical pathology showing a collision tumor with a 4 cm adrenocortical adenoma and 2.7 cm myelolipoma. Following surgery, her weight and diabetes improved and 24 hour urine cortisol normalized.

Incidentally discovered adrenal tumors, adrenal incidentalomas (AIs), are common, occurring in 3–7% of abdominal imaging performed for other reasons [1]. The majority of AIs are benign adrenocortical adenomas [7]. It is generally accepted that most AIs should undergo evaluation for the autonomous secretion of cortisol, catecholamines, and aldosterone (in hypertensive or hypokalemic patients) [1]. About 10–12% of AIs are cortisol secreting [7].

The presence of macroscopic fat on CT in an AI is considered virtually diagnostic of myelolipoma [8]. Adrenal myelolipomas are uncommon tumors that are composed of

mature adipose and myeloid tissue and thought to be benign tumors which are not capable of autonomous hormone production [9]. It is generally accepted that myelolipomas do not warrant an evaluation for autonomous hormone production. The diagnosis of myelolipoma is made radiographically by the presence of an adrenal tumor containing macroscopic fat [10], but our group has previously reported that the accuracy of this diagnosis may depend on the amount of macroscopic fat seen in the tumor [11]. While adrenal myelolipomas are hormonally inactive, there is an increased association of myelolipomas and multiple endocrine disorders, including Cushing's syndrome. Although the exact etiology is unknown, one theory suggests a hormonally induced transformation of adrenal tissue into myeloid and lipomatous cells [12, 13].

Alternatively, others have suggested adrenal tissue necrosis may lead to myelolipomatous change [9, 10]. Both theories may account for the incidence of myelolipomas coupled with adrenal hyperplasia and Cushing's syndrome, as it has been reported [12, 14, 15].

TABLE 1: Case reports of adrenal myelolipoma and functioning adrenal adenoma.

Case authors	Age	Gender	ACTH	Cortisol	Side	Tumor size (cm)	Symptoms
Vyberg et al. [16]	31	F	↓	↑	L	2.5	Weight gain, hair loss, ecchymoses
Selye et al. [13]	58	F	↓	↑	R	7×4×4	Diabetes mellitus
Jenkins et al. [15]	67	F	↓	↑	L	3.5×3×2	Diabetes mellitus
Su et al. [9]	29	F	↓	—	R	3.3×2.2×1.7	Transient hypertension
Guresci et al. [14]	1.5	F	—	↑	L	7×6×4.5	Hypertension, weight gain, excessive body hair growth

Long-term hypercortisolism is associated with diabetes mellitus, hypertension, hyperlipidemia, and osteoporosis. Laparoscopic adrenalectomy has been shown to improve outcomes over nonsurgical therapy [16] and is the recommended treatment for patients with unilateral cortisol-secreting adrenal tumors [17]. Long-term autonomous secretion of cortisol from an adrenal tumor leads to suppression of the contralateral adrenal gland. Therefore, patients undergoing adrenalectomy for unilateral hypercortisolism require postoperative glucocorticoid replacement until the recovery of their remaining adrenal gland. There can be a delayed recovery taking up to 24 months [18].

Only five other case reports have chronicled a combination of an adrenal myelolipoma and functioning adrenal adenoma in a patient with Cushing's syndrome [2–6] (Table 1). An additional case of an adrenal myelolipoma and a functioning adrenal adenoma in a patient with Conn's syndrome have also been described [17]. As with our patient, Lu et al. previously reported that the majority of myelolipoma-adrenocortical adenoma collision tumors were found in female patients, involved the left adrenal gland, and if functional, demonstrated hormonal profiles compatible with Cushing's syndrome [17].

### 3. Conclusion

Adrenal lesions with macroscopic fat on imaging are typically labelled as myelolipomas and may not undergo a functional evaluation. This case report demonstrates that clinicians should consider a functional evaluation of select patients with radiographically diagnosed myelolipomas as they may prove to be functional collision tumors.

### Data Availability

No data were used to support this study.

### Conflicts of Interest

The authors declare no conflicts of interest regarding the publication of this paper.

### References

- [1] W. W. Mayo-Smith, J. H. Song, G. L. Boland et al., "Management of incidental adrenal masses: a white paper of the american incidental findings committee," *Journal of the American College of Radiology*, vol. 14, no. 8, pp. 1038–1044, 2017.
- [2] T. Matsuda, H. Abe, M. Takase et al., "Case of combined adrenal cortical adenoma and myelolipoma," *Pathology International*, vol. 54, no. 9, pp. 725–729, 2004.
- [3] R. Armand, A. R. Cappola, R. B. Horenstein, C. B. Drachenberg, H. Sasano, and J. C. Papadimitriou, "Adrenal cortical adenoma with excess black pigment deposition, combined with myelolipoma and clinical Cushing's syndrome," *International Journal of Surgical Pathology*, vol. 12, no. 1, pp. 57–61, 2004.
- [4] I. A. Cardinalli, A. G. de Oliveira-Filho, M. J. Mastellaro, R. C. Ribeiro, and S. S. Aguiar, "A unique case of synchronous functional adrenocortical adenoma and myelolipoma within the ectopic adrenal cortex in a child with Beckwith-Wiedemann syndrome," *Pathology-Research and Practice*, vol. 208, no. 3, pp. 189–194, 2012.
- [5] H. Hisamatsu, H. Sakai, S. Tsuda, K. Shigematsu, and H. Kanetake, "Combined adrenal adenoma and myelolipoma in a patient with Cushing's syndrome: case report and review of the literature," *International Journal of Urology*, vol. 11, no. 6, pp. 416–418, 2004.
- [6] M. Vyberg and L. Sestoft, "Combined adrenal myelolipoma and adenoma associated with Cushing's syndrome," *American Journal of Clinical Pathology*, vol. 86, no. 4, pp. 541–545, 1986.
- [7] M. Fassnacht, W. Arlt, I. Bancos et al., "Management of adrenal incidentalomas: European society of endocrinology clinical practice guideline in collaboration with the European network for the study of adrenal tumors," *European Journal of Endocrinology*, vol. 175, no. 2, pp. G1–G34, 2016.
- [8] N. Khater and R. Khauli, "Myelolipomas and other fatty tumours of the adrenals," *Arab Journal of Urology*, vol. 9, no. 4, pp. 259–265, 2011.
- [9] H. C. Su, X. Huang, W. L. Zhou et al., "Pathologic analysis, diagnosis and treatment of adrenal myelolipoma," *Canadian Urological Association Journal*, vol. 8, no. 9–10, pp. E637–E640, 2014.
- [10] E. M. Schaeffer and L. R. Kavoussi, "Adrenal myelolipoma," *Journal of Urology*, vol. 173, no. 5, p. 1760, 2005.
- [11] M. J. Campbell, M. Obasi, B. Wu, M. T. Corwin, and G. Fananapazir, "The radiographically diagnosed adrenal myelolipoma: what do we really know?" *Endocrine*, vol. 58, no. 2, pp. 289–294, 2017.
- [12] A. Ishay, A. Ishay, M. Dharan, M. Dharan, R. Luboshitzky, and R. Luboshitzky, "Combined adrenal myelolipoma and medullary hyperplasia," *Hormone Research*, vol. 62, no. 1, pp. 23–26, 2004.
- [13] H. Selye and H. Stone, "Hormonally induced transformation of adrenal into myeloid tissue," *The American Journal of Pathology*, vol. 26, no. 2, pp. 211–233, 1950.
- [14] S. Guresci, C. Kara, D. T. Ertugrul, and A. Unsal, "Combined adrenal medullary hyperplasia and myelolipoma: a mimicker of pheochromocytoma," *Turkish Journal of Endocrinology and Metabolism*, vol. 13, pp. 84–86, 2009.
- [15] P. J. Jenkins, S. L. Chew, D. G. Lowe, R. H. Reznick, and J. A. H. Wass, "Adrenocorticotrophin-independent unilateral

- macronodular adrenal hyperplasia occurring with myelolipoma: an unusual cause of Cushing's syndrome," *Clinical Endocrinology*, vol. 41, no. 6, pp. 827–830, 1994.
- [16] A. Toniato, I. Merante-Boschin, G. Opocher, M. R. Pelizzo, F. Schiavi, and E. Ballotta, "Surgical versus conservative management for subclinical cushing syndrome in adrenal incidentalomas: a prospective randomized study," *Annals of Surgery*, vol. 249, no. 3, pp. 388–391, 2009.
- [17] H. S. Lu, M. F. Gan, H. S. Chen, and S. Q. Huang, "Adrenal myelolipoma within myxoid cortical adenoma associated with Conn's syndrome," *Journal of Zhejiang University Science B*, vol. 9, no. 6, pp. 500–505, 2008.
- [18] M. Välimäki, R. Pelkonen, L. Porkka, A. Sivula, and A. Kahri, "Long-term results of adrenal surgery in patients with Cushing's syndrome due to adrenocortical adenoma," *Clinical Endocrinology*, vol. 20, no. 2, pp. 229–236, 1984.