

# UCLA

## UCLA Previously Published Works

### Title

Preliminary Experience with Intravascular Ultrasound Guided Palmaz-Schatz Coronary Stenting: The Acute and Short-Term Results on a Consecutive Series of Patients

### Permalink

<https://escholarship.org/uc/item/0nk8p498>

### Journal

Journal of Interventional Cardiology, 7(2)

### ISSN

0896-4327

### Authors

HALL, PATRICK  
COLOMBO, ANTONIO  
ALMAGOR, YARON  
[et al.](#)

### Publication Date

1994-04-01

### DOI

10.1111/j.1540-8183.1994.tb00897.x

### Copyright Information

This work is made available under the terms of a Creative Commons Attribution License, available at <https://creativecommons.org/licenses/by/4.0/>

Peer reviewed

---

## Preliminary Experience with Intravascular Ultrasound Guided Palmaz-Schatz Coronary Stenting: The Acute and Short-Term Results on a Consecutive Series of Patients

PATRICK HALL, M.D., ANTONIO COLOMBO, M.D., YARON ALMAGOR, M.D.,  
LUIGI MAIELLO, M.D., SHIGERU NAKAMURA, M.D., GIOVANNI MARTINI, C.C.P.,  
and JONATHAN M. TOBIS, M.D.\*

From the Centro Cuore Columbus, Milan, Italy; and the \*University of California, Irvine, Division of Cardiology, Orange, California

---

*The purpose of this study was to prospectively test the hypothesis that systemic anticoagulation is not needed following coronary stenting when adequate stent expansion is achieved and documented and other flow limitations eliminated. Intravascular ultrasound (IVUS) was used to confirm adequate stent expansion, which was defined as good plaque compression together with the achievement of an in-trastent lumen cross-sectional area (CSA) that was > 40% of the average reference vessel CSA. In this prospective study, Palmaz-Schatz coronary stenting was performed on 343 lesions in 263 consecutive patients. Primary stenting was successful in 254 patients (96.6%) and 332 lesions (96.8%). All patients with successful primary stenting underwent IVUS imaging except nine patients (13 lesions) that did not have an IVUS evaluation for technical reasons and three patients (4 lesions) in which IVUS was unsuccessful. The initial IVUS performed after achieving an acceptable angiographic result revealed inadequate stent expansion in 191 patients (79%) and 244 lesions (77%). After further dilatation, final adequate stent expansion was accomplished in 230 patients and 301 lesions. These patients were treated with Ticlopidine 250 mg twice per day for 2 months and did not receive postprocedure anticoagulation. There was one acute stent thrombosis (0.3%) that occurred in a lesion with slow flow and an inadequately expanded stent. There was no subacute stent thrombosis and no bleeding or vascular complications. We conclude that when adequate stent expansion is achieved and confirmed and other flow limiting lesions eliminated, that systemic anticoagulation after the stent procedure is not necessary. (J Intervent Cardiol 1994; 7:141-159)*

---

### Introduction

Intracoronary stents have been extensively investigated, and are currently being utilized for the treatment of coronary artery disease. In comparison to historical control groups, the Gianturco-Roubin stent (Cook, Inc., Bloomington, IN, USA) reduces the incidence of myocardial infarction

and need for emergency coronary bypass in patients that have complications of acute vessel closure following coronary angioplasty.<sup>1-4</sup> Using similar historical angioplasty comparisons,<sup>5-9</sup> the potential benefit of stents in reducing restenosis rates, particularly in de novo lesions<sup>10-12</sup> and in vein grafts<sup>10-12</sup> has also been reported. More recently, results of the Benestent randomized trial comparing stents and angioplasty in treating de novo native coronary artery lesions has also demonstrated a significant reduction in the restenosis rates in the stent treatment group.<sup>13</sup>

Despite these encouraging results, subacute

---

Address for reprints: Antonio Colombo, M.D., Centro Cuore Columbus, Via M. Buonarroti 48, 20145 Milan, Italy. Fax: 392-481-93433.

stent thrombosis remains a conspicuous complication following intracoronary stenting.<sup>1,12-28</sup> Subacute stent thrombosis was first identified as a problem following coronary stenting in the early experience with the self expanding Medinvent stent (Lausanne, Switzerland)<sup>14,15</sup> and the nonarticulated Palmaz stent (Johnson & Johnson, Interventional Systems, Warren, NJ, USA).<sup>16</sup> Subsequent to this early experience, a rigorous antiplatelet and anticoagulant regimen to include aspirin, persantine, dextran, heparin, and warfarin has had an impact on reducing stent thrombosis although it remains a significant problem with incidences ranging from 0.6%–23%.<sup>11-28</sup> The anticoagulant regimen has also created a category of anticoagulant related bleeding and vascular complications.<sup>1,11,12,16,20,25-28</sup> Major bleeding events that require transfusions or vascular complications that necessitate surgical repair occur in 8.4%–16% of patients that undergo coronary stent implantation.<sup>1,11,16,20,25-28</sup> Even in the absence of significant complication or morbidity, the anticoagulant regimen necessitates prolonged bedrest, lengthy hospitalization, requires frequent laboratory evaluations, contributes to the overall expense of the procedure and is, in general, a source of tremendous anxiety to the patient and physician alike. The conflicting dilemmas of stent thrombosis and anticoagulation associated bleeding complications threaten to limit the appropriate or potential application of the intracoronary stent.

The inherent thrombogenicity of the stainless steel stent has been implicated as a major factor in subacute stent thrombosis.<sup>29-34</sup> Other clinical, anatomical, and procedural factors have also been associated with a higher incidence of stent thrombosis.<sup>16,20,25,27,28,35,36</sup> Stenting patients with unstable angina<sup>27</sup> or in the early postmyocardial infarct period,<sup>35</sup> stenting smaller vessels,<sup>25,36</sup> stenting for the indication of acute vessel closure,<sup>20,32</sup> and residual distal dissection<sup>25</sup> have all been implicated with higher stent closure rates. Stents that are coated with heparin, hirudin, or other antiplatelet agents have been proposed and are being evaluated as a solution for combating stent thrombosis while reducing the need for systemic anticoagulation and, concomitantly, the associated bleeding and vascular complications.<sup>12,37-39</sup>

Early experience with intravascular ultrasound (IVUS) evaluation after achieving an acceptable angiographic result revealed that over 80% of stents were insufficiently dilated.<sup>40,41</sup> These observations pointed to a primary cause of stent thrombosis being incomplete stent dilatation rather than the inherent thrombogenicity of the metallic stent. In the light of this new information, one reasonable, albeit provocative, interpretation of the body of literature on intracoronary stents is that anticoagulation has not provided absolute protection against stent thrombosis when administered in the setting of an underexpanded stent.

The working hypothesis for this study is that when adequate stent placement and expansion is achieved and documented and other flow limiting lesions eliminated, that systemic anticoagulation following the stenting procedure is not necessary. This hypothesis was prospectively evaluated on 263 consecutive patients undergoing Palmaz-Schatz intracoronary stenting of 343 lesions. Intravascular ultrasound was used to document adequate stent expansion. All patients that met quantitative and qualitative IVUS criteria for adequate stent expansion did not receive prolonged anticoagulant therapy after the stent procedure. The focus of this report is to describe the technique, procedural, angiographic and IVUS results, and the short-term clinical outcome of patients undergoing IVUS guided stenting without subsequent anticoagulation.

## Methods

**Patient Population.** This ongoing prospective investigation was initiated on March 30, 1993 and includes the 263 consecutive patients (343 lesions) enrolled through October 6, 1993. Two centers have participated in the protocol: Centro Cuore Columbus in Milan and Villa Bianca in Bari, Italy. All procedures were performed by experienced operators (AC, YA, LM, and AG). The 263 procedures represented 52% of the 510 interventional procedures performed during the study period. Clinical entry criteria included: (1) coronary artery disease manifested by clinical symptoms or objective evidence of myocardial is-

## CORONARY STENTING WITHOUT ANTICOAGULATION

chemia either on exercise test or by nuclear scintigraphy; and (2) angiographic evidence of single or multiple vessel coronary disease with target lesion stenosis  $> 70\%$  by visual estimates. There were no specific age or ejection fraction limitations for study entry. The exclusion criteria included: (1) small vessels  $< 2.25$  mm; and (2) diffuse distal disease that might compromise outflow from the target stented lesion.

**Stent Type.** Five different types of Johnson & Johnson tubular slotted stents were utilized during the course of this study. The decision on which stent to use was based, primarily, on anatomical variables: the vessel size, the extent of proximal tortuosity, the site of the lesion, and lesion length. The stents that were most commonly used were the standard Palmaz-Schatz stent and the short stent composed of one 7-mm tubular slotted segment. The use of the short stent has been previously well-described.<sup>42</sup> For large proximal native coronary or bypass graft conduits a 10-mm long biliary stent, 20-mm renal stent composed of two 10-mm segments with a central articulation, or a disarticulated 10-mm long renal stent were often used. A delivery system with premounted standard coronary stent was used sparingly during the study.

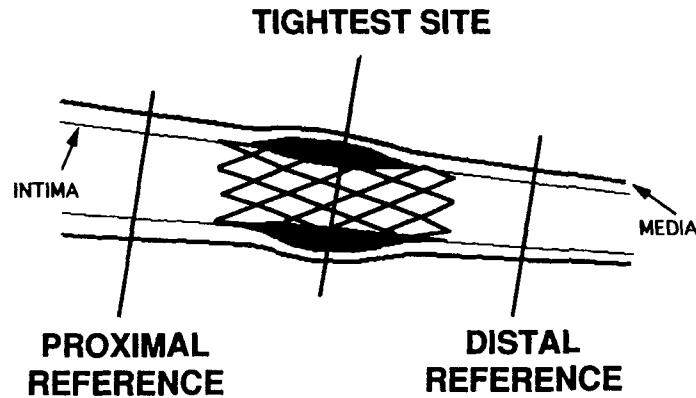
**Stent Procedure.** Patients were brought to the catheterization laboratory in a fasting state. After appropriate sedation was achieved, the procedure was performed by femoral approach. Following initial angiograms, a guidewire was positioned distal to the target lesion. Routine dilation or predilation was performed prior to stenting. *Predilation was performed with an undersized balloon catheter.* Stents were mounted on 2.5- or 3.0-mm balloon catheters and hand crimped tightly on the balloon using previously described techniques.<sup>42</sup> The stents were delivered to and centered over the target lesion then deployed with rapid balloon inflation to 10 atm. Dilation with larger balloon catheters was performed to achieve an optimal angiographic result. Following an assessment of a good angiographic result, IVUS was performed. All subsequent treatment decisions were based on the ultrasound results in conjunction with angiographic assessment.

**Intravascular Ultrasound Equipment.** The majority of coronary arteries were imaged using a 3.9Fr monorail system with a 25-mHz transducer

tipped catheter (Interpret Catheter, Intertherapy/CVIS, Sunnyvale, CA, USA). A Cardiovascular Imaging System (CVIS) with a 2.9Fr catheter was used in 5% of the procedures. Imaging system mechanics and catheter dynamics for these systems have been previously well-described.<sup>43-46</sup> All images were obtained using a manual pullback system. Positioning correlations were made as necessary with fluoroscopic updates. Data was stored on 0.5-inch high resolution videotape. Quantitative analysis was performed either on-line or off-line. Validation of the computerized lumen and vessel measurements have been previously reported.<sup>44-46</sup>

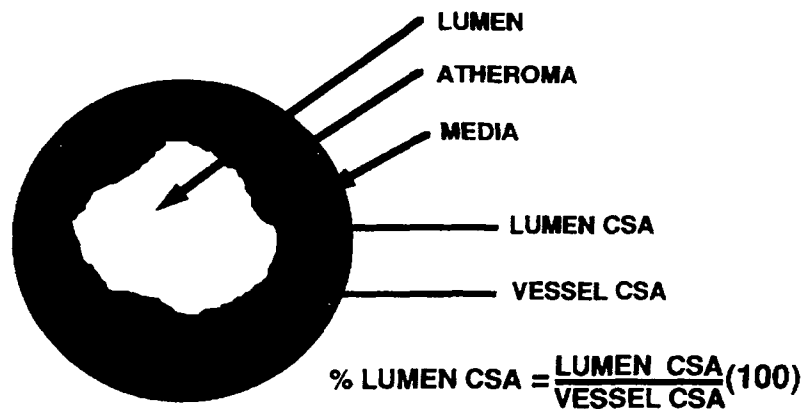
**Qualitative and Quantitative Ultrasound Evaluation.** After an optimal angiographic result was obtained, an ultrasound imaging catheter was advanced over the guidewire until it was positioned distal to the stented segment. While recording, the imaging catheter was pulled back slowly through the stented segment and subsequently into the guiding catheter. Subsequent imaging was performed if necessary. Using computer planimetry, measurements were performed of the distal and proximal reference segments and the stented site (Fig. 1). In the reference segments, vessel cross-sectional area (CSA), minimal and maximal vessel diameters were obtained. The vessel measurements were made at the inner boundary of the echolucent media. Proximal and distal reference lumen CSA, and minimal and maximal diameters were also measured. Lumen measurements were made at the inner border of the echodense plaque. Position for measurements at the reference sites are graphically displayed in Figure 2. The reference artery measurements were made 2-3 mm on either side of the stented segment to minimize the effect of balloon stretch. Intrastent lumen CSA, minimal diameter, and maximal diameter measurements were made at the tightest position within the stent. Vessel measurements of the stented site were not performed because intense echo reflections from the metallic struts frequently prevented adequate visualization of the plaque media border. Additionally, the plaque media border was obscured when there was adequate plaque compression by the stent. For these reasons the average of the proximal and distal vessel diameters and CSA was

## IVUS MEASUREMENT SITES



**Figure 1.** Intravascular Ultrasound Measurement Sites: This diagram is a schematic representation of the length of an artery and shows the positions at which measurements are taken: The proximal and distal reference sites and the tightest point within the stented segment. Reference vessel measurements were performed at the inner border of the media and the atheroma and averaged to obtain the average reference vessel CSA. The intrastent lumen CSA (at the tightest point) was divided by the average reference vessel CSA then multiplied by 100 to calculate the percent stent lumen expansion.

## IVUS MEASUREMENTS



**Figure 2.** Intravascular Ultrasound Measurements: The vessel CSA and diameters are obtained at the inner border of the media. The lumen CSA and diameter measurements were obtained at the border of the atherosclerotic plaque. The percent lumen CSA was defined as the lumen CSA divided by the vessel CSA times 100. The percent lumen CSA was calculated at the proximal and distal reference vessel sites. The stented segment percent lumen CSA was calculated using the average of the proximal and distal reference vessel CSA.

used to reflect the vessel dimensions within the stented segment.

**Intravascular Ultrasound Criteria for Optimal Stent Expansion.** With each imaging run, attention was directed to a qualitative and quantitative assessment of the stented segment and to the regions just distal and proximal to the stented segment. Significant luminal encroachment in the adjacent nonstented segments, whether from residual lesion or dissection, was treated with angioplasty or further stenting at the discretion of the operator. The intrastent dilation was considered satisfactory based on two criteria. First, there had to be adequate plaque compression. While this is an inherently qualitative evaluation, it was felt to be achieved when the media border in the stented segment could not be identified. Second, a stent lumen CSA that was 40% of the average of the measured proximal and distal vessel CSA was considered adequate stent expansion (Fig. 2). A target stent lumen CSA of 60% of the average vessel CSA was used in the early experience before subsequent modification. If either of the first or second criteria were not met, then further balloon dilation was performed. When further dilations were necessary, the initial IVUS imaging run provided information on the reference vessel and lumen diameter, which was helpful in choosing balloons for subsequent dilations that were within an acceptable safety margin. As experience with this technique of IVUS guided stenting was obtained, we generally opted for high pressure inflations with balloons that were undersized by ultrasound measurements. The final balloon dilations were most commonly performed with minimally compliant short (9 mm long) or ultrashort (4 mm long) balloons (Short Speedy, Schneider, Zurich, Switzerland) or standard length (20 mm) noncompliant balloons (NC Shadow, SCIMED Life Systems, Maple Grove, MN, USA). Intravascular ultrasound was performed after each additional balloon inflation to document whether the criteria for stent expansion was achieved.

**Definitions.** In this report, the following definitions are used. Primary stenting success was achieved when there was successful stent deployment and dilation with achievement of an acceptable angiographic result. Primary stent failure occurred when there was failure to deliver the stent

to the appropriate site. In this group there was no acute angiographic, procedural, or major clinical complications with the patients undergoing subsequent elective bypass surgery. Primary stent complications were considered those complications of stent deployment or initial stent dilations that resulted in major clinical complications. These complications occurred prior to the IVUS evaluation. Intravascular ultrasound complications were complications that occurred during or following the initial ultrasound evaluation. Intravascular ultrasound success was achieved when there was adequate plaque compression within the stented segment and the stented segment was expanded to at least 40% of the average of the proximal and distal reference vessel CSA. The initial IVUS evaluation (after achieving an acceptable angiographic result) was defined as the FIRST STEP. The final IVUS evaluation when the criteria for stent expansion was achieved was defined as the FINAL STEP. Acute stent thrombosis was defined as stent thrombosis that occurred within 24 hours of the stent procedure. Thrombosis that occurred beyond 24 hours, but within 3 weeks of the stenting process was labeled subacute stent thrombosis.

**Angiographic Analysis.** Coronary angiograms were analyzed by an experienced angiographer not involved in the study procedure. The stented lesions were measured from an optically magnified image in a single, matched "worst" view using digital calipers (Brown and Sharp, North Kingstown, RI, USA). Prior studies have demonstrated that digital caliper measurements are highly reproducible and correlate well with digital image analysis.<sup>47,48</sup> The guiding catheter was used as the reference object. The diameter of the proximal and distal reference segments was averaged to give a mean reference diameter. Mean angiographic reference vessel measurements were used so as to achieve a relative correlation with the IVUS average reference vessel measurements. Minimal lumen diameter, lesion length, and percent diameter stenosis were obtained before the intervention and at the final step. Although angiograms were performed at the first step, the angiographic measurements were not consistently performed because previous experience with the technique of IVUS guided stenting has already showed a significant improvement in

the angiographic and ultrasound dimensions between the first step and final step.<sup>40,41</sup> Lesion length was measured as the distance between the proximal and distal shoulder of the lesion in the view that best elongated the stenosis. The lesion shoulder was considered the point where the lumen becomes compromised by 50%. Each stenotic segment was evaluated for the presence or absence of calcium and thrombosis. Coronary lesions were characterized according to the modified American College of Cardiology/American Heart Association criteria.<sup>49</sup>

**Medications, Postprocedure Protocol, and Short-Term Follow-Up.** Prior to the stenting procedure, all patients were premedicated with aspirin 325 mg and calcium channel blockers. During the stenting procedure, patients received a bolus of 10,000 units of heparin with repeat bolus's of 5,000 units given as needed to maintain procedural activated clotting time (ACT) > 300. If the patient satisfied all the IVUS criteria for optimal stent expansion and the final angiogram also demonstrated a good result, no further heparin was administered and sheaths were removed in 4–6 hours when the ACT normalized. When procedures were performed, late heparin was infused overnight and the sheaths removed the following morning. Patients were fully ambulatory within 12–24 hours. In the first 2 months of this protocol, patients were observed in the hospital for 1 week. Subsequent to this period patients were discharged from the hospital within 2–3 days as is typical following routine coronary angioplasty. Following the procedure, patients received Ticlopidine 250 mg po bid for 2 months. Patients that had not received Ticlopidine prior to the stent procedure also received aspirin 325 mg/day for 3 days.

Creatine kinase with isoenzymes were obtained every 8 hours for the first 24 hours following the procedure. Electrocardiograms were obtained prior to the procedure immediately following the procedure, the day after the procedure, and as indicated for symptoms. While hospitalized, the patients were monitored. Angiograms were performed in all patients with chest pain, even if the chest pain was atypical. Phone contact was made 1 week following discharge from the hospital and 1 month after the stent procedure.

**Statistics.** Normally distributed data are expressed as mean  $\pm$  1 standard deviation (SD). Comparisons between groups were analyzed by paired Student's *t*-test. Differences were considered to be statistically significant at  $P < 0.05$ .

## Results

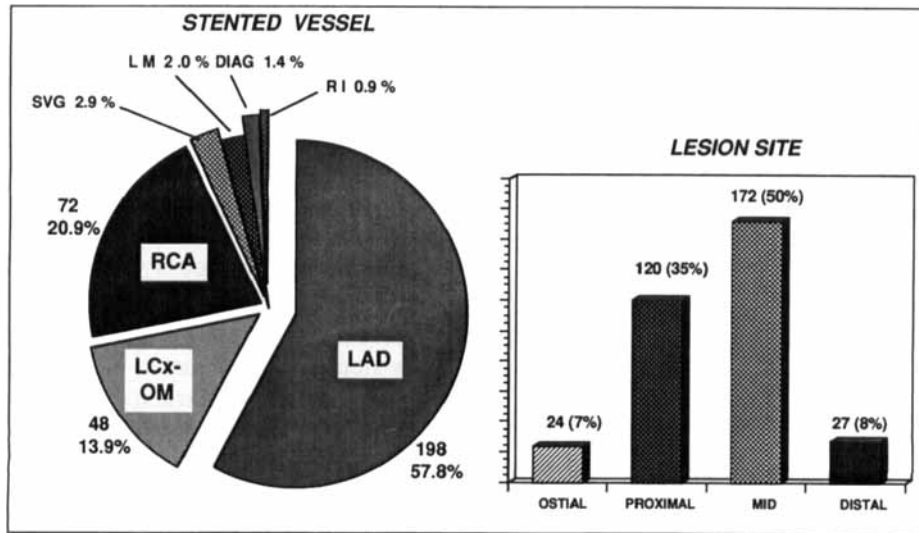
**Clinical, Angiographic, and Procedural Characteristics.** The clinical characteristics of the 263 patients in this study are represented in Table 1. Mean age was  $58.5 \pm 0.5$ . Diabetes was present in 14% of patients with 4.9% of patients having insulin dependent diabetes. Unstable angina, defined as either accelerating angina or rest angina, was present in 40% of the patients. Vessel distribution and lesion sites in the 343 lesions are presented in Figure 3. The vessel distribution was: left anterior descending artery in 198 (57.8%), right coronary artery in 72 (20.9%), circumflex or obtuse marginal in 48 (13.9%), saphenous vein

Table 1. Baseline Clinical Characteristics

	Patients	Percent
Study population	263	
Mean age		$58.5 \pm 9.4$
Gender: male	226	86.0
female	37	14.0
Diabetes	37	14.0
Insulin dependent	13	4.9
Hypertension	77	29.2
Hypercholesterolemia	131	49.6
Smoking: active	107	40.9
former	39	14.8
Family history	101	38.6
Previous MI	141	53.6
Previous bypass	28	10.6
Previous angioplasty	59	22.3
Mean ejection fraction		$56 \pm 10.7$
Unstable angina	105	40.2
CCS angina class		
class I	50	18.9
class II	78	29.5
class III	69	26.5
class IV	66	25.0
Number of diseased vessels		
1 vessel	132	50.0
2 vessels	86	33.0
3 vessels	45	17.0

MI = myocardial infarction; CCS = Canadian Cardiovascular Society.

## CORONARY STENTING WITHOUT ANTICOAGULATION



**Figure 3.** Vessel and lesion site distribution of 343 lesions. LAD = left anterior descending; LCx = left circumflex; RCA = right coronary artery; SVG = saphenous vein graft; LM = left main; DIAG = diagonal; RI = ramus intermedia.

graphs in 10 (2.9%), unprotected left main in 7 (2.0%), diagonal in 5 (1.4%), and ramus intermediate in 3 (0.9%) lesions. Lesion sites were ostial in 24 (7.0%), proximal in 120 (35.2%), mid in 172 (50.0%), and distal in 27 (7.8%). Indications for stenting are presented in Table 2. Stenting was performed electively in 227 patients (66%), for restenosis in 46 patients (13.4%), for suboptimal angioplasty result in 38 patients (11.3%), for dissection with acute or threatened closure in 14 patients (4.1%), and following opening a chronic total occlusion in 18 patients (5.2%). The number and type of stents are presented in Table 3. A total of 695 stents were deployed in this study population and included 333 standard stents, 347

short stents, 12 biliary stents, 2 short renal stents, and 1 renal stent.

Customizing or tailoring the stenting process to the individual patient was an important part of the overall stenting strategy in this study. This involved the use of short stents and multiple stents (Table 4 and Fig. 4). Short stents were uti-

**Table 2.** Indications for Stenting

Indications	Percent	# Lesions
Elective	66.0	227
Restenosis	13.4	46
Suboptimal results	11.3	38
Dissection with acute or threatened closure	4.1	14
Post opening chronic total occlusion	5.2	18
<b>Total</b>		<b>343</b>

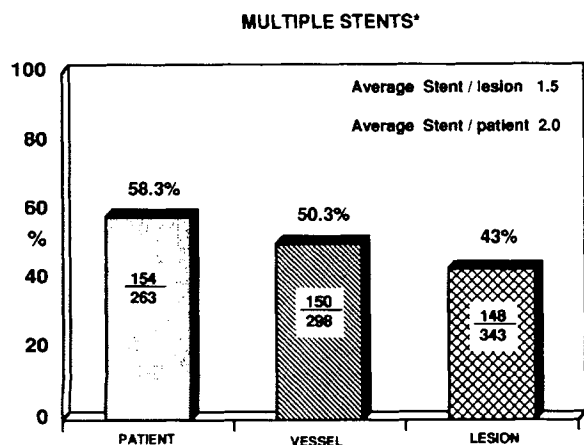
**Table 3.** Number and Type of Stent

Standard stent	333
Short stent	347
Biliary stent	12
Short renal	2
Renal stent	1
<b>Stent total</b>	<b>695</b>

**Table 4.** Indications and Use of Short Stent

Indication	Lesions	# Stents
Focal lesions	26	26
Overlapping short stents to avoid stent articulation site at critical lesion	91	224
Stenting residual lesion or dissection at stent site	48	97
<b>Total</b>	<b>165</b>	<b>347</b>





\* Multiple stents defined as deployment of greater than a 15 mm stent.  
 Figure 4. Bar graph depicting deployment of multiple stents. Multiple stents defined as deployment of greater than a 15 mm stent.

lized in 165 lesions (48.1%). Indications for the short stent were for focal lesions in 26 patients (26 stents), for definitive stenting of lesions with 2 or 3 overlapping stents to avoid placement of the stent articulation site at the tightest point of a lesion (91 lesions, 224 stents), and to treat residual disease following initial stent deployment in 48 lesions (97 short stents). Multiple stent use was defined as the use of stent length > 15 mm (or the length of a standard Palmaz-Schatz stent). Using this definition, one short stent would be

the equivalent of a half stent and two short stents would be the equivalent of one stent. Multiple stents were utilized in 43% (148 of 343) of lesions, 50.3% (150 of 298) of vessels, and in 58.6% (154 of 263) of patients. The average number of stents placed per lesion is 1.5 with the average stents deployed per patient being 2.0.

**Procedural Success.** In this study population, primary stenting success was achieved in 254 of 263 patients (96.6%) and 332 of 343 lesions (96.8%) as graphically depicted in Figure 5. Primary stent failure occurred in two patients (0.8%) with both of these patients undergoing delayed and elective coronary bypass without major clinical complication. Complications during primary stenting occurred in seven patients (2.7%). Stenting was unsuccessful in 11 of the 343 lesions (3.2%).

Following successful primary stenting there were nine patients (3.5%) and 13 lesions (3.9%) that did not have IVUS performed for technical reasons: the ultrasound machine was not operational (three patients), no imaging catheters were available (two patients), or the IVUS unit was being used in another room for a prolonged period of time (four patients). An IVUS evaluation was unsuccessful in three patients (1.2%) and four lesions (1.2%). There were six patients (2.3%) with seven lesions (2.1%) that had an IVUS evaluation performed and were felt to have a suboptimal result. Five of the patients (five lesions) underwent

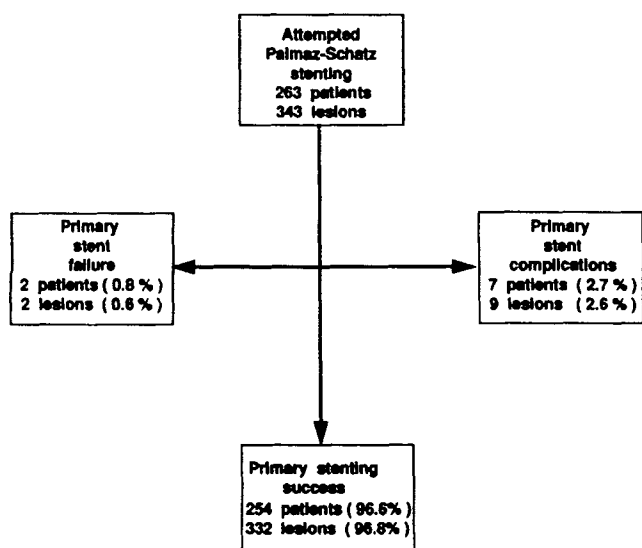
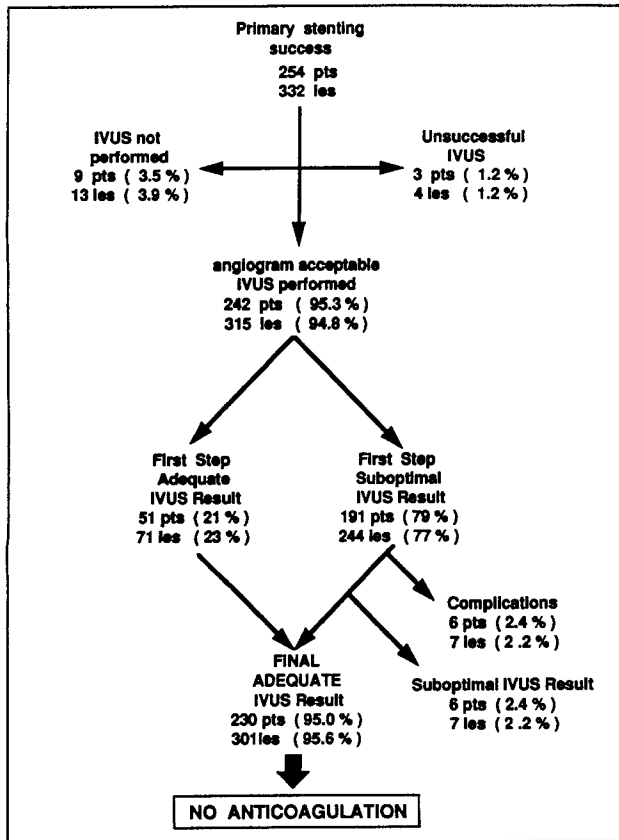


Figure 5. Flow diagram of patient and lesion primary success, primary stent failure, and primary stent complications.

## CORONARY STENTING WITHOUT ANTICOAGULATION



**Figure 6.** Flow diagram of patients following successful primary stenting and of patients and lesions with IVUS guided stenting. pts = patients; les = lesions.

stent procedures in the early phase of the study and had ultrasound results that would have been sufficient to be declared a success later in the study. Together, this heterogeneous group of 18 patients were treated with standard anticoagulation therapy. They did not have any procedural or postprocedural complications and will not be discussed any further in this report.

Intravascular ultrasound was successfully performed in 315 of 332 lesions (94.8%) and 242 of 254 patients (95.3%) with successful primary stenting (Fig. 6). Adequate stent expansion was achieved at the first step in 51 of 242 patients (21%) and in 71 of 315 lesions (23%). The first step (initial) IVUS evaluation was suboptimal in 191 of 242 patients (79%) and in 244 of 315 lesions (77%) with these patients requiring further stent dilation. Final adequate stent expansion was achieved in 230 of the 242 patients (95.0%) and 301 of the 315 lesions (95.6%) in which an IVUS evaluation was performed. The 12 patients that did not have a successful IVUS result included

the six patients (seven lesions) that had a suboptimal result as noted above and six patients (seven lesions) with complications following IVUS. The patients with complications will be described in detail in the subsequent complication section. In addition to adequate stent expansion, the achievement of a final adequate IVUS result also required that there be no significant lesions in the unstented segments immediately adjacent to the stent site. For practical purposes, the adjacent unstented segments were considered a part of the stent site. A significant lesion was defined by IVUS criteria as a lesion that had > 60% CSA stenosis. As shown on Figure 7, IVUS imaging performed at the first step or intermediate steps identified 57 (18%) significant and potentially flow limiting lesions: 45 stenosis (79%) thought to represent residual plaque and 12 dissections (21%).

The 230 patients that had adequate stent expansion by IVUS criteria did not receive prolonged anticoagulation following the stenting procedure.

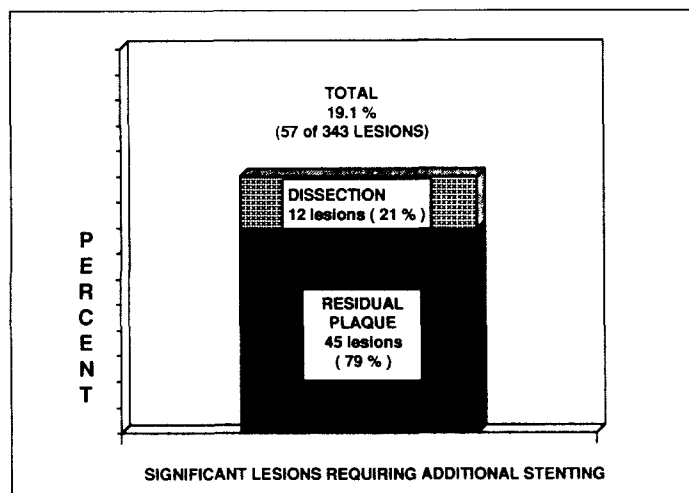


Figure 7. Bar graph depicting the number and type of significant lesions that required additional stenting based on IVUS information. As noted 57 lesions required additional stenting: 45 lesions with significant residual plaque (79%) and 12 lesions for dissection (21%).

The majority of these patients (90%) had no further heparin after leaving the catheterization laboratory while a smaller percentage of patients (10%) received anticoagulation overnight when the procedure was performed late or because a second vessel was to be stented as the final part of a staged procedure the following day. These patients were treated with Ticlopidine for 2 months. None of the patients with successful IVUS guided stent expansion received warfarin following the stent procedure.

**Complications.** The primary stenting complications, the complications that occurred following the initial IVUS evaluation, and the total complications are presented in Table 5. The complications were separated because the later group of patients were felt to have successfully dilated stents by angiographic criteria with complications

arising during the final IVUS guided stent dilation. Primary stent complications occurred in seven patients (2.7%) and included one vessel rupture in 343 lesions (0.3%), non-Q wave myocardial infarction in two patients (0.8%), Q wave myocardial infarction in three patients (1.1%), emergency coronary bypass in six patients (2.2%), and death in one patient (0.4%). Complications that occurred in the process of IVUS guided stent dilation occurred in six patients. One of the complications occurred during the IVUS evaluation and five occurred following the initial IVUS evaluation. These complications included three vessel ruptures in 315 lesions (1.0%), non-Q wave myocardial infarction in three patients (1.2%), Q wave myocardial infarction in one patient (0.4%), emergency coronary bypass in four patients (1.7%), and death in two patients (0.8%).

Table 5. Procedural Complications

	Primary Stent Complications	Post IVUS Stent Complications	Total Complications
Total patient cohort	263	242*	263
Coronary rupture	0.3% (1/343 les)	1.0% (3/312 les)	1.2% (4/343 les)
Myocardial infarct	1.9% (5)	1.6% (4)	3.4% (9)
Q wave MI	1.1% (3)	0.4% (1)	1.5% (4)
non-Q wave MI	0.8% (2)	1.2% (3)	1.9% (5)
Emergency CABG	2.2% (6)	1.7% (4)	3.8% (10)
Death	0.4% (1)	0.8% (2)	1.1% (3)

MI = myocardial infarction; CABG = coronary artery bypass grafting; les = lesion; ( ) = encloses the number of patients with complications.

\* Percent of complications post IVUS was calculated based on number of patients that had an IVUS evaluation performed.

## CORONARY STENTING WITHOUT ANTICOAGULATION

The total procedural complications included non-Q wave myocardial infarction in five patients (1.9%), Q wave myocardial infarction in four patients (1.5%), emergency coronary bypass in ten patients (3.8%), and death in three patients (1.1%).

Angiographic causes of the 13 major clinical complications included vessel rupture in four lesions (1.2%), distal dissection in three lesions (0.9%), threatened or acute closure of a major nonstented epicardial vessel during stenting of the left coronary artery (circumflex closed while stenting the proximal left anterior descending coronary artery or vice versa) in two patients (0.6%), left main dissection in two patients (0.6%), stenting of a false lumen after opening a chronic total occlusion in one patient (0.3%), and an immediate distal embolization in a saphenous vein graft that did not improve with selective intracoronary thrombolysis in one patient (0.3%). None of these patients had procedural or acute stent thrombosis.

Postprocedural complications are presented in Table 6. One patient had acute stent thrombosis (0.4%) with associated Q wave myocardial infarction. This occurred in a patient that had rotablation performed prior to stenting. At the completion of the stent procedure, there was angiographic slow flow. A review of the procedural

**Table 6.** Post Procedural Complications

<b>Angiographic</b>	
Acute stent thrombosis	0.3% (1/343 lesions)
Acute vessel closure*	0.3% (1/343 lesions)
Subacute stent thrombosis	0%
<b>Clinical</b>	
Myocardial infarction	1.2% (3/263 patients)
Q wave MI	0.4% (1/263 patients)
non-Q wave MI	0.8% (2/263 patients)
Emergency CABG	0.4% (1/263 patients)
Death	0%
Vascular repair	0%
Other vascular complications†	0%
Bleeding complications	0%

MI = myocardial infarction; CABG = coronary artery bypass grafting.

† Acute vessel closure refers to vessel closure distal to a stent site with stent patency maintained.

\* Other vascular complications: Defined as access site bleeding or major hemotoma formation requiring transfusion.

**Table 7.** Angiographic Measurements in Patients with Final IVUS Success

n = 301	Baseline	Final
Mean reference diameter (mm)	3.2 ± 0.6	3.2 ± 0.5
Mean lumen diameter (mm)	0.9 ± 0.5	3.47 ± 0.7
% diameter stenosis (mm)	69 ± 19	-11.5 ± 17

IVUS study revealed that the stent did not meet criteria for adequate stent expansion. This patient underwent stent redilation with high pressure balloon inflations and was subsequently treated with heparin. A second patient had occlusion of the vessel distal to a stent as a result of a distal dissection that occurred during the stenting process. The stent, however, remained patent. The acute vessel occlusion occurred 3 hours following the procedure while the patient was still well anticoagulated from procedural administration of heparin. The ACT at the time of symptomatic occlusion was 280 seconds. After an unsuccessful attempt to deliver a stent to the site of the distal dissection the patient underwent uneventful emergency coronary bypass surgery. There were no episodes of subacute stent thrombosis. A final patient had a non-Q wave myocardial infarction felt related to distal embolization from a pre-stent rotablation procedure. A repeat angiogram and IVUS study on this patient documented wide patency of the vessel and the stented segment. Thus, total postprocedural clinical complications included two non-Q wave myocardial infarctions (0.8%), one Q wave myocardial infarction (0.4%), and one emergency coronary bypass surgery (0.4%). No patients had major groin hematomas or other nonaccess site bleeding complications that required transfusions. No patients required vascular repair for access site complications.

**Angiographic Analysis.** Angiographic data is presented in Table 7. The mean baseline minimum lumen diameter was 0.9 ± 0.6 mm with a baseline percent stenosis of 69.0 ± 19%. Baseline mean reference vessel diameter was 3.2 ± 0.6 mm and following the procedure it was not significantly changed at 3.2 ± 0.5 mm. The mean final stent diameter was 3.47 ± 0.7 mm with a mean final percent stenosis of ± 11.5% ± 17%.

**Intravascular Ultrasound Analysis.** Angiographic lumen diameters are presented with

**Table 8.** Angiographic and Intravascular Ultrasound Diameter Measurements

n = 301	Proximal Reference	Stented Site		Distal Reference
		First Step	Final Step	
Angiographic diameter (mm)	3.3 ± 0.6	—	3.5 ± 0.5	3.0 ± 0.6
Minimum lumen diameter (mm)	3.0 ± 0.6	2.7 ± 0.5	3.1 ± 0.5*	2.8 ± 0.6
Major lumen diameter (mm)	3.4 ± 0.6	3.1 ± 0.5	3.6 ± 0.5*	3.2 ± 0.7
Major vessel diameter (mm)	4.4 ± 0.6	4.2 ± 0.6**	4.2 ± 0.6**	4.0 ± 0.7

\* P < 0.0001 between first step and final step.

\*\* Represents the average of the proximal and distal vessel CSA.

**Table 9.** Intravascular Ultrasound Cross Sectional Area Measurements

n = 301	Proximal Reference	Stented Site		Distal Reference
		First Step	Final Step	
Lumen CSA (mm <sup>2</sup> )	8.6 ± 3.0	7.0 ± 2.3	9.1 ± 2.6**	7.5 ± 3.3
Vessel CSA (mm <sup>2</sup> )	14.6 ± 3.9	13.5 ± 3.8*	13.5 ± 23.8*	12.4 ± 4.5
% Lumen CSA (mm <sup>2</sup> )	58.0 ± 14.0	53.0 ± 15.0	68.0 ± 15.0**	61.0 ± 15.0

\* Represents the average of the proximal and distal vessel CSA.

\*\* P < 0.0001 between first step and final step.

IVUS maximum lumen and maximum vessel diameters in Table 8. There is a significant difference between the IVUS first step stent maximum diameter of 3.1 ± 0.5 mm and the IVUS final step stent maximum lumen diameter of 3.6 ± 0.5 mm (P < 0.0001). This table also reveals that the mean angiographic reference lumen diameters are similar to the IVUS maximum lumen diameters at the proximal and distal reference sites. Proximal angiographic reference lumen was 3.3 ± 0.6 mm compared to similar proximal IVUS maximal lumen diameter of 3.4 ± 0.6 mm. The distal angiographic reference lumen was 3.0 ± 0.6 mm in comparison to a distal IVUS maximum lumen diameter of 3.2 ± 0.7 mm. The mean ultrasound maximum vessel diameter is consistently larger than the angiographic lumen diameter at the proximal reference site (4.4 ± 0.6 mm vs 3.3 ± 0.6 mm), and at the distal reference vessel site (4.0 ± 0.7 mm vs 3.0 ± 0.6 mm).

The IVUS reference segment, first step and final step information CSAs are presented in Table 9. The lumen at the tightest point within the stent significantly increased from a first step value of 7.0 ± 2.2 mm<sup>2</sup> to a final step value of

9.1 ± 2.6 mm<sup>2</sup> (P < 0.0001) with further dilatation. Using the criteria of percent lumen expansion that was utilized in the study to guide optimal stent expansion the stent was significantly expanded from 53 ± 15% at the first step to 68 ± 15% at the final step (P < 0.0001).

Optimal stent expansion on IVUS evaluation was achieved through the use of larger balloons and higher inflation pressures as depicted in Table 10. The ratio of balloon diameter to IVUS measured maximum lumen diameter, the balloon diameter, and the inflation pressures were all sig-

**Table 10.** Balloon to Vessel Ratio, Balloon Diameter and Inflation Pressures at the First Step and Final Step

n = 301	First Step	Final
Ratio $\frac{\text{Balloon}}{\text{max IVUS diameter}^*}$	0.87 ± 0.10	0.94 ± 0.10†
Balloon diameter (mm)	3.6 ± 0.1	3.9 ± 0.2†
Inflation pressure (atm)	13.5 ± 3.0	15.0 ± 3.0†

\* Ratio of the balloon diameter to average maximum vessel diameter by IVUS.

† P < 0.0001.

nificantly increased between the first step and the final step evaluations ( $P < 0.0001$ ).

### Discussion

**Stent Thrombosis.** Despite intensive antiplatelet and anticoagulation medication, there is still a risk of stent thrombosis in 0.6%–3% of elective Palmaz-Schatz stent implantations<sup>11,12,17–19</sup> while the incidence of stent thrombosis in emergency stent insertions ranges from 2%–23%.<sup>18–24</sup> Although experience with stenting and the intensive antiplatelet and anticoagulation regimen following stenting has decreased the overall incidence of stent thrombosis, it would appear that this standard regimen has not been fully prophylactic against thrombotic events.<sup>11,12,17–24</sup> Furthermore, the decrease in stent thrombosis rates seems, at times, to come at the expense of higher anticoagulation related complications.<sup>11</sup>

The causes of thrombosis after implantation of a stainless steel stent have not been fully ascertained. While stainless steel is durable and resists corrosion, the electropositivity of the metal relative to blood gives the stent an element of thrombogenicity.<sup>31,32</sup> Animal investigations have documented that fibrin and thrombin deposition occurs on stents or at the stented site shortly after stent implantation.<sup>29,32–34</sup> A similar orderly process of platelet deposition followed by thrombus formation, fibroblast proliferation, and intimal hyperplasia occurs in response to the intimal or media disruption after angioplasty, but does not produce vessel thrombosis unless there is flow limitation. A study on Indium-111-labeled platelet scans and gross inspection of stent sites in animals showed consistently less thrombus in the stent sites of animals treated with aspirin, dipyridamole, heparin, and dextran compared to control groups or groups treated with various combinations of antiplatelet and anticoagulant agents, but never correlated these findings to the clinical event of stent thrombosis.<sup>32</sup> In much of the early stent investigations in animals, there was a very low incidence of stent thrombosis, perhaps, owing to the relative ease in which stents could be expanded in the normal or relatively undiseased animal vessels.<sup>29,32–34,50–52</sup> Schatz reports that repeated animal investigations showed, consis-

tently, that as long as brisk antegrade flow was maintained a controlled sequence of mild platelet deposition, thrombus formation, fibroblast proliferation, and finally endothelialization occurred.<sup>29,33,50–52</sup> What is not clear from any of the pioneering animal investigations on stents is whether the platelet or thrombus deposition that occurs on the metallic foreign body contributes directly to stent thrombosis in the absence of other hemodynamic or flow limiting variables. It could be argued that the increased incidence of stent thrombosis that was encountered in the human coronary experience was a reflection of the relative increased difficulty in consistently achieving adequate stent expansion in vessels that were sometimes severely diseased, calcified, and fibrotic.

This study demonstrates that short-term anticoagulation can be safely omitted following the stenting procedure when adequate stent expansion is achieved and in flow and out flow hazards eliminated. Prior to the initiation of this study, early investigations with IVUS guided stenting revealed that a high percentage (80%) of patients had underexpanded stents, thereby raising suspicions that stent thrombosis was perhaps more of a procedural phenomena than an inherent problem of stent thrombogenicity.<sup>40,41</sup> The findings in the present study also support this concept. The most frequent site of potential flow limitation in this study was the lesion site within the stented segment as evidenced by the 77% of stents that were not adequately dilated at the time of the initial (first step) IVUS imaging. In contrast, IVUS only identified 57 potentially flow limiting lesions (18%) in adjacent unstented segments. The stent thrombosis rate was low (0.3%) despite the absence of anticoagulation. In the present study, the lone stent thrombosis (0.3%) occurred at a stent site that was suboptimally expanded to 35% of the average vessel CSA. There also was visibly evident slow flow in the stented vessel felt related to a pre-stent coronary rotablation procedure. This case illustrates the hazard of an intrastent narrowing when combined with suboptimal antegrade flow. The second patient with occlusion of the stented vessel distal to the stent was also instructive in many ways. During the stenting procedure, there was an angiographically evident dissection distal to the stent that was

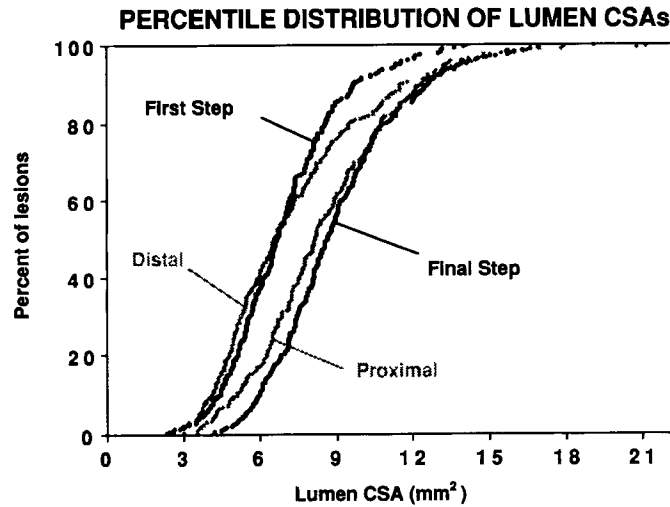
treated with angioplasty. Intravascular ultrasound imaging documented adequate stent expansion and more than 60% lumen CSA narrowing distal to the stent that was not treated any further. Following the stent procedure, the distal vessel occluded while the patient was still fully anticoagulated (ACT of 280). Stent patency was maintained because there was well preserved flow to a diagonal side branch that arose between the stent and the distal occlusion. Both of these complications highlight the hierarchical importance of having good flow over optimal anticoagulation to prevent stent or vessel occlusion. Perhaps, one contribution to the low stent thrombosis rate in this study was the low number of patients stented for acute or threatened closure. In our experience there is no difference in the stent thrombosis rates for the different stenting indications.<sup>22,24,53</sup> Nonetheless, in the 15 patients that were stented for acute or threatened closure, there were no episodes of stent thrombosis despite the absence of poststent anticoagulation treatment.

**Intravascular Ultrasound.** The data illustrates that IVUS is an acceptable instrument to evaluate adequate stent expansion. To maximize the information that could contribute to appropriate and efficient clinical decision making, IVUS imaging was only performed after first obtaining an acceptable angiographic result. The information obtained at the initial IVUS evaluation was used to guide further dilatation if it was necessary. In a previous IVUS guided stenting study at our institution, the mean angiographic percent stenosis was decreased from  $9 \pm 13$  to  $-4 \pm 12$  mm with further IVUS guided balloon dilatations ( $P < 0.0001$ ). This corresponded to a significant increase in the stent lumen from  $49 \pm 10\%$  to  $65 \pm 10\%$  of the average reference vessel on IVUS evaluation.<sup>40</sup> The results of the present study show a similar significant improvement in the stent lumen CSA from  $7.0 \pm 2.3$  mm<sup>2</sup> to  $9.1 \pm 2.6$  mm<sup>2</sup> ( $P < 0.0001$ ). The percent lumen expansion of the stent increased from  $53 \pm 15$  to  $68 \pm 15$  ( $P < 0.0001$ ). Similar highly significant improvements in the stent minimum and maximum diameters were also noted (Table 8).

Analysis of the IVUS data provides other important information in evaluating the overall effect of IVUS guided stent expansion. The IVUS

criteria for adequate stent expansion was to achieve intrastent plaque compression and an intrastent lumen of  $> 40\%$  of the average of the proximal and distal reference vessel. In the early phases of the study, however, the intrastent target area was  $> 60\%$  of the average reference vessel CSA. Using the 40% criteria for successful stent expansion, the percentile graph of the lumen CSAs are shown in Figure 8. This graph demonstrates the relative stenosis that would have been left in the stented segment if no further balloon dilations were performed beyond the first step (when there was an initial acceptable angiographic result). The percentile representation also demonstrates that the final dilations yielded a final intrastent lumen that was, perhaps, larger than was anatomically necessary. In this sense, the curve was shifted far to the left with the net result being that the CSA of the intrastent segment was much larger than either the proximal or the distal lumen. A similar effect can be seen by analysis of the mean lumen CSAs (Table 9). The first step CSA of  $7.0 \pm 2.3$  is less than the distal lumen CSA of  $7.5 \pm 3.3$  reflecting a relative stenosis in the stented segment. After further dilatation, the final step lumen CSA was expanded to a CSA of  $9.1 \pm 2.6$  that was larger than the mean proximal reference lumen of  $8.6 \pm 3.0$ . The percentile distribution graphs of the percent lumen CSAs show the same relative stent underexpansion at the first step and relative overexpansion at the final step (Fig. 9). This overdilation effect is also represented on the angiographic analysis that shows the presence of a negative final lumen stenosis of  $-11 \pm 17\%$ .

From an analysis of the clinical, ultrasound, and angiographic results it appears that the stent expansion that was performed in this study was at the upper limit of the therapeutic range. Part of the reason for this aggressive dilatation strategy was to avoid complications of subacute stent thrombosis in this population of patients that were not receiving anticoagulation therapy following the stent procedure. From reviewing percentile distribution graphs (Figs. 8 and 9), a more appropriate and safer stent dilation strategy might be to expand the stent so that the final lumen in the stented segment is less than or equal to the proximal reference lumen and larger than the distal lumen. This type of strategy would also avoid



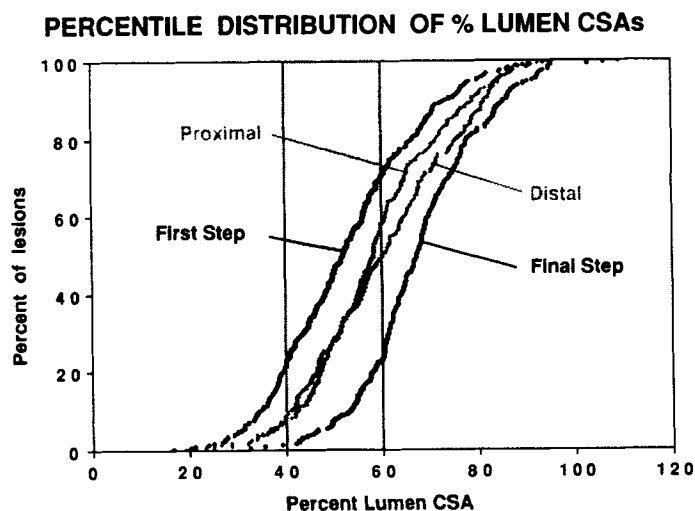
**Figure 8.** Percent distribution of lumen CSAs. The lumen CSA is plotted on the horizontal axis for the proximal and distal reference sites, at the tightest point within the stent after the first step (after the initial adequate angiographic result), and at the final step (after further IVUS guided balloon dilatation). Even though the initial angiographic result was satisfactory, the first step IVUS evaluation shows that the majority of the lesions had a lumen CSA that was less than either the proximal or distal reference lumen CSA. After additional dilatation, the final step was larger than the proximal and the distal reference lumen.

the relative stenosis in the stented segment that could contribute to flow disturbances and stent thrombosis. It is possible that by using a less aggressive method of stent dilation, the minimum safe lower limit of the therapeutic range of IVUS guided stent expansion will be defined. The extreme lower end of the therapeutic spectrum, clinically defined by the point at which stent thrombosis becomes a problem, was not elucidated in the present study and for practical and ethical reasons may never be found. Ultimately, any dilation strategy using ultrasound guidance must take into account the effects it will have on eliminating the risk of procedural complications (i.e., vessel rupture and distal dissection) and stent thrombosis.

**Stent Expansion Strategies.** Dilation strategies are an important part of the process of safely achieving adequate stent dilation. The primary difficulty in achieving adequate stent expansion in all lesions arises from the 20%–30% of lesions that are calcified or fibrotic and resist effective vessel dilation and stent expansion. In the course of this study, a variety of different balloon infla-

tion strategies have been utilized. At present, final stent dilations are performed using an appropriate “angiographically sized” noncompliant balloon inflated to high pressures (standard pressures are over 16 atm). Selecting an appropriate balloon based on angiography provides a safety margin because the true vessel diameter on IVUS is consistently larger than the angiographic lumen size. This can be seen on Table 7, and is consistent with the findings of other investigators.<sup>41,44,54</sup> The use of noncompliant balloon material ensures that the same balloon size and, therefore, the safety margin is maintained even at high pressures up to 20 atm. The balloon length should be the same length as the stent to avoid barotrauma and dissection to unstented segments. The short balloon can also be helpful in applying localized expansile force to a focal resistant intrastent lesion. In using this approach to stent expansion in the last 125 patients, the mean angiographic balloon to vessel ratio has decreased from 1.2 to 0.9 while the average inflation pressures have increased (16.8 atm). This has assured a higher percentage of adequate stent ex-





**Figure 9.** Percent distribution of percent lumen CSAs. The percent expansion of the lumen CSA relative to the vessel CSA is plotted on the horizontal axis. The percent lumen CSA was calculated at proximal and distal reference sites and at the tightest point within the stent. At the stent site the average of the proximal and distal vessel was used as the denominator for this calculation. Despite an initial adequate angiographic result, the first step IVUS reveals that the majority of the stents had a percent lumen CSA that was less than the percent lumen CSA at the proximal or distal reference sites, thus, reflecting a relative stenosis within the stent. After further dilatation, the final percent lumen CSA at the narrowest site within the stent was greater than the proximal or distal reference lumen CSA suggesting that there was an overdilation phenomena.

pansion at the time of the initial ultrasound evaluation, decreased the procedural time, and eliminated complications related to balloon oversizing.

All of the angiographic complications of vessel rupture and two of the three distal dissections that occurred in this study occurred in the early experience and were related to balloon oversizing or balloon rupture at high pressure. This underscores the importance of careful balloon sizing, the value of a noncompliant balloon, and the present need for better noncompliant balloons to safely use high pressure for final stent dilatations. The importance of the combination of all these features to avoid complications cannot be underestimated.

**Angiographic Versus Ultrasound Assessment.** As pointed out by Nakamura et al.,<sup>41</sup> IVUS imaging and angiography provide unique and complementary information in the assessment of an ade-

quate result. Angiography provides a longitudinal assessment of the lumen diameter of a coronary artery. Because of lesion eccentricity and problems of vessel overlap, lesion sites are sometimes not well-appreciated, especially if they are very short. In contrast, IVUS images allows for a magnified and unobstructed circumferential assessment of the CSA that makes it particularly well-suited to evaluate lesion sites or to accurately quantify the extent of stent expansion. Intravascular ultrasound is particularly suited to evaluate focal lesions while angiography is perhaps better suited for detecting dissections.

Well-defined criteria for an angiographic successful stent expansion that would alleviate the risk of stent thrombosis and, thus, the need for anticoagulation have not been developed. There is a limit to visual interpretation of small percent differences on angiogram. It is conceivable that careful on-line quantitative angiographic mea-

## CORONARY STENTING WITHOUT ANTICOAGULATION

surements may better distinguish between small lumen changes and could have a role in determining angiographic success. Careful assessment of the inflated balloon profile and comparing that profile to the final angiographic lumen can provide some clues to whether a stent is adequately expanded. Indentations in the balloon profile or mismatch between the balloon and angiograms most likely reflect a failure in stent expansion rather than recoil and, thus, may point out the need for further balloon dilatations with higher pressures or a larger balloon. Empiric high pressure balloon inflations with an appropriate sized noncompliant balloon will increase the number of patients that will have acceptable stent expansion. In the present study, high pressure balloon inflations up to 16–18 atm have increased the percentage of patients that have adequate stent expansion at the initial IVUS evaluation from <20% to 58%. Thus, at the time of angiographic success there were still 42% of the stents that required additional dilatation with higher pressures, a repeat dilation with slight adjustment in balloon position or, less commonly, a dilatation with a larger balloon. None of these angiographic methods for assessing stent expansion have been prospectively evaluated. Each would have the inherent limitations of an angiographic evaluation: that of a one-dimensional assessment of result. Intravascular ultrasound imaging, thus, remains the only reliable method of definitively confirming adequate stent expansion with a degree of security that allows anticoagulation to be eliminated from the poststent medical regimen.

**The Role of Ticlopidine.** Ticlopidine was used in the present study because it has a proven highly effective antiplatelet activity. Whether this agent played a major or synergistic role in the achievement of the low stent thrombosis in this study will require further evaluation. A similar randomized or observational study with aspirin will help answer the questions of the effect of ticlopidine and also can determine if the results are similar with aspirin.

### Limitations

Using IVUS to assess adequacy of stent expansion increases the length and cost of the procedure.

In the early experience, there were several complications, mainly vessel rupture, that occurred in the process of further stent dilatation. These complications of balloon oversizing were, however, avoided in the last 125 patients. The role of Ticlopidine will require further clarification. To answer this question, a similar study has been initiated in which patients will be treated only with aspirin after successful IVUS guided stenting. Another limitation of this study is the use of digital calipers instead of a quantitative angiographic system of measurements. This effect is minimized in this study as IVUS was the primary mode of assessing the adequacy of the final result and the ultrasound measurements were made using a computerized planimetry system.

### Conclusions and Future Directions

This nonrandomized series of consecutive patients undergoing IVUS guided stenting without subsequent anticoagulation provides a new prospective on the future of intracoronary stenting. On the basis of these observations it is reasonable to conclude that:

- 1) The Palmaz-Schatz stent is not thrombogenic provided antegrade flow is brisk and there are no flow limiting factors present;
- 2) The most frequent cause of potential flow limitation was inadequate stent expansion;
- 3) Anticoagulation therapy can be safely omitted following the stenting procedure when adequate stent expansion is achieved and flow is optimized in adjacent stent segments;
- 4) Intravascular ultrasound is an acceptable method of confirming adequate stent expansion;
- 5) Intravascular ultrasound and angiography provided complementary information that allowed for the poststent anticoagulation regimen to be safely eliminated;
- 6) Adequate stent expansion can be achieved in the majority of patients;
- 7) Adequate stent expansion in human coronaries consistently requires high pressure balloon dilatation.

Questions that remain to be answered after the present study are:

- 1) The therapeutic range of adequate stent expansion;
- 2) The effect that this overall stenting and stent expansion strategy will have on restenosis;
- 3) The role of ticlopidine in the low subacute stent thrombosis rate and the potential safe use of aspirin as the only poststenting antiplatelet agent.

It is hoped that this preliminary work on finding a solution to the conflicting problems of subacute stent thrombosis and anticoagulation related bleeding complications will stimulate further investigation and evaluation to find satisfactory answers to a number of the questions raised. With continued research, improvement, and advances, the appropriate and safe use of intracoronary stents for elective implantation to decrease restenosis and eliminate acute closure may be closer at hand.

### References

1. George BS, Voorhees WD, Roubin GS, et al. Multicenter investigation of coronary stenting to treat acute or threatened closure after percutaneous transluminal coronary angioplasty: Clinical and angiographic outcomes. *J Am Coll Cardiol* 1993;22:135-143.
2. Detre KM, Holmes DR, Holubkov R, et al. Incidence and consequences of periprocedural occlusion: The 1985-1986 National Heart, Lung and Blood Institute percutaneous transluminal coronary angioplasty registry. *Circulation* 1990;82:739-750.
3. Simpfendorfer C, Belardi J, Bellamy G, et al. Frequency management and follow-up of patients with acute occlusion after percutaneous transluminal coronary angioplasty. *Am J Cardiol* 1987;59:267-269.
4. Sinclair IN, Melabe CH, Sipperly ME, et al. Predictors, therapeutic options and long-term outcome of abrupt reclosure. *Am J Cardiol* 1988;61:61G-66G.
5. Popma JJ, Topol EJ. Factors influencing restenosis after coronary angioplasty. *Am J Med* 1990;88:1N-24N.
6. Serruys PW, Luijten HE, Beatt R, et al. Incidence of restenosis after successful coronary angioplasty: A time related phenomenon. A quantitative angiographic study in 342 consecutive patients at 1, 2, 3 and 4 months. *Circulation* 1988;77:361-371.
7. Califf RM, Fortin DF, Frid DJ, et al. Restenosis after coronary angioplasty: An overview. *J Am Coll Cardiol* 1991;17:Suppl. B:2B-13B.
8. Nobuyoshi M, Kimura T, Nosaka H, et al. Restenosis after successful percutaneous transluminal coronary angioplasty: Serial angiographic follow-up of 229 patients. *J Am Coll Cardiol* 1988;12:616-623.
9. Platko WP, Hollman J, Whitlow PL, et al. Percutaneous transluminal angioplasty of saphenous vein graft stenosis: Long term follow up. *J Am Coll Cardiol* 1989;14:1645-1650.
10. Strauss BH, Serruys PW, de Scheerder IK, et al. Relative risk analysis of angiographic predictors of restenosis within the coronary wall stent. *Circulation* 1991;84:1636-1643.
11. Carrozza JP, Kuntz RE, Levine MJ, et al. Angiographic and clinical outcome of intracoronary stenting: Immediate and long-term results from a large single center experience. *J Am Coll Cardiol* 1992;20:328-337.
12. Schatz RA, Goldberg S, Leon M, et al. Clinical experience with the Palmaz-Schatz coronary stent. *J Am Coll Cardiol* 1991;17:155B-159B.
13. Serruys PW, Macaya C, de Jaegere P, et al. Interim analysis of the Benestent Trial (abstract). *Circulation* 1993;88:1-594.
14. Sigwart U, Urban P, Golf S, et al. Emergency stenting for acute occlusion after coronary angioplasty. *Circulation* 1988;78:1121-1127.
15. Serruys PW, Strauss BN, Beatt KJ, et al. Angiographic follow-up after placement of a self-expanding coronary artery stent. *N Engl J Med* 1991;324:13-17.
16. Schatz RA, Baim DS, Ellis SG, et al. Clinical experience with the Palmaz-Schatz coronary stent: Initial results of a multicenter study. *Circulation* 1991;83:148-161.
17. Levine MJ, Leonard BM, Burke JA, et al. Clinical and angiographic results of balloon-expandable intracoronary stent in right coronary artery stenoses. *J Am Coll Cardiol* 1990;16:332-339.
18. Kimura T, Nosaka H, Yokoi H, et al. Serial angiographic follow-up after Palmaz-Schatz stent implantation: Comparison with conventional balloon angioplasty. *J Am Coll Cardiol* 1993;21:1557-1563.
19. Fischman DL, Savage MP, Leon MB, et al. Effect of intracoronary stenting on intimal dissection after balloon angioplasty: Results of quantitative coronary analysis. *J Am Coll Cardiol* 1991;18:1445-1451.
20. Herrman NC, Buchbinder M, Clemen MW, et al. Emergent use of balloon expandable coronary artery stenting for failed percutaneous transluminal coronary angioplasty. *Circulation* 1992;86:812-819.
21. Kastrati A, Schomig A, Dietz R, et al. Time course of restenosis during the first year after emergency coronary stenting. *Circulation* 1993;87:1498-1505.
22. Maiello L, Colombo A, Gianrossi R, et al. Coronary stenting for treatment of acute or threatened closure following dissection after coronary balloon angioplasty. *Am Heart J* 1993;125:1570-1575.
23. Keimeneij F, Laarman GJ, van der Wiekan R. Emergency coronary stenting with the Palmaz-Schatz stent for failed transluminal coronary angioplasty: Results of a learning phase. *Am Heart J* 1993;126:23-31.
24. Colombo A, Goldberg SL, Almagor Y, et al. A novel strategy of stent deployment in the treatment of acute or threatened closure complicating balloon coronary angioplasty. *J Am Coll Cardiol* 1993;22:1887-1891.
25. Roubin GS, Cannen AD, Agrawal SK. Intracoronary stenting for acute or threatened closure complicating percutaneous transluminal coronary angioplasty. *Circulation* 1992;85:916-927.
26. Shatnovich A, Lieberman SM, Mases JW, et al. Clinical and angiographic outcomes of native coronary stenting with a single Palmaz-Schatz™ (PS) stents (abstract). *J Am Coll Cardiol* 1994;21:29A.
27. Nath FC, Muller DWM, Ellis SG, et al. Thrombosis of a flexible coil stent: Frequency predictors and clinical outcome. *J Am Coll Cardiol* 1993;21:622-627.
28. Agrawal SK, Hearn SA, Lin MW, et al. Stent thrombosis and ischemic complications following coronary artery stenting (abstract). *Circulation* 1992;86:1-113.

## CORONARY STENTING WITHOUT ANTICOAGULATION

29. Schatz RA. A view of vascular stents. *Circulation* 1989; 79:445-457.
30. De Palma VA, Baierre RE, Ford JW, et al. Investigation of three surface properties of several metals and their relation to blood compatibility. *J Biomed Mater Res Symp* 1972;3:37.
31. Baier RE, Dutton RC. Initial events in interaction of blood with a foreign surface. *J Biomed Mater Res Symp* 1969;3:191.
32. Palmaz JC, Garcia O, Kopp DT, et al. Balloon expandable intraarterial stents: Effect of anticoagulation on thrombus formation (abstract). *Circulation* 1987; 76(Suppl. IV):IV-45.
33. Schatz RA, Palmaz JC, Tio FO, et al. Balloon expandable intracoronary stents in the adult dog. *Circulation* 1987;76:450-457.
34. Roubin GS, Robinson KA, King SB, et al. Early and late results of intracoronary arterial stenting after coronary angioplasty in dogs. *Circulation* 1987; 76:891-897.
35. Iyer SS, Bilodeau, Cannon AD, et al. Stenting the infarct related artery within 15 days of the acute event: Immediate and long term outcome using the flexible metallic coil stent (abstract). *J Am Coll Cardiol* 1993;21:291A.
36. Doucet S, Fajadet J, Caillard J, et al. Predictors of thrombotic occlusion following coronary Palmaz-Schatz stent implantation (abstract). *Circulation* 1992;86:1-113.
37. Bailey SR, Paige S, Lunn A, et al. Heparin coating of endovascular stents decreases subacute stent thrombosis in a rabbit model (abstract). *Circulation* 1992;86:1-186.
38. van der Giessen WJ, Hardhammar PA, Van Beusekan HMM, et al. Reduction of thrombotic occlusion if heparin coated with non-coated Palmaz-Schatz stents in normal coronary arteries in pigs (abstract). *Eur Heart J* 1993;14:352A.
39. Zider JP, Jackman JD, Gamm RS, et al. Serial assessment of heparin coating on vascular responses to a new tantalum stent (abstract). *Circulation* 1992;86:1-185.
40. Goldberg SL, Colombo A, Nakamura S, et al. The benefit of intracoronary ultrasound in the deployment of Palmaz-Schatz stents. *J Am Coll Cardiol* (In press).
41. Nakamura S, Colombo A, Gaglione S, et al. Intracoronary ultrasound observations during stent implantation. *Circulation* (submitted).
42. Colombo A, Hall P, Thomas J, et al. Initial experience with the disarticulated (one-half) Palmaz-Schatz stent: A technical report. *Cath Cardiovasc Diagn* 1992;25: 304-308.
43. Potkin BN, Bartorelli AL, Gessert JM, et al. Coronary artery imaging with intravascular high frequency ultrasound. *Circulation* 1990;81:1575-1585.
44. Tobis JM, Mallery J, Mahon D, et al. Intravascular ultrasound imaging of human coronary arteries in vivo. Analysis of tissue characterizations with comparison to in vitro histological specimens. *Circulation* 1991;83: 913-926.
45. Honye J, Mahon DJ, Jain A, et al. Morphological effects of coronary balloon angioplasty in vivo assessed by intravascular ultrasound imaging. *Circulation* 1992;85: 1012-1025.
46. Nishimura RA, Edwards WD, Warnes CA, et al. Intravascular ultrasound imaging: In vitro validation and pathologic correlation. *J Am Coll Cardiol* 1990;16: 145-154.
47. Scoblianko DP, Brown G, Mitten S. A new digital electronic caliper for measurement of coronary arterial stenosis: A comparison with visual and computer assisted measurements. *Am J Cardiol* 1984;53:689-693.
48. Theron HT, Lambert CR, Pepine CJ. Video densitometry versus digital calipers for quantitative coronary angiography. *Am J Cardiol* 1990;66:1886-1890.
49. Ryan TJ, Faxon DP, Gunnar RM, et al. A report of the American College of Cardiology/American Heart Association Task Force on assessment of diagnostic and therapeutic cardiovascular procedures. *J Am Coll Cardiol* 1988;12:529-545.
50. Palmaz JC, Windelar SA, Garcia F, et al. Balloon expandable intraluminal grating of atherosclerotic aortas. *Radiology* 1986;147:1251-1256.
51. Palmaz JC, Kopp DJ, Hayashi H, et al. Normal and stenotic renal arteries: Experimental balloon expandable intraluminal stenting. *Radiology* 1987;164:705-710.
52. Mullins CE, O'Laughlin MP, Vick GW, et al. Implantation of balloon expandable intravascular stents by catheterization in pulmonary arteries and systemic veins. *Circulation* 1988;77:188-193.
53. Colombo A, Almagor Y, Maiello L, et al. Coronary stenting: Results with different indications (abstract). *Circulation* 1993;88:1-122.
54. Steil GM, Steil LG, Schofer J, et al. Impact of compensatory enlargement of atherosclerotic coronary arteries on angiographic assessment of coronary disease. *Circulation* 1989;80:1603-1609.