

UC Davis

UC Davis Previously Published Works

Title

A case of retrograde venous air embolism causing cerebral infarction following upper gastrointestinal endoscopy: A novel pathophysiological mechanism

Permalink

<https://escholarship.org/uc/item/0mq6h071>

Journal

Radiology Case Reports, 13(6)

ISSN

1930-0433

Authors

Uldin, Hasaam HU
Shabana, Amr AS
Raslan, Osama OR

Publication Date

2018-12-01

DOI

10.1016/j.radcr.2018.08.002

Peer reviewed

Available online at www.sciencedirect.com

journal homepage: www.elsevier.com/locate/radcr

Case Report

A case of retrograde venous air embolism causing cerebral infarction following upper gastrointestinal endoscopy: A novel pathophysiological mechanism

Hasaam H.U. Uldin, MBChB, BSc^{a,*}, Amr A.S. Shabana, MBBCh, MSc, PhD^b,
Osama O.R. Raslan, MD, MBBCh, MSc^c

^aUniversity Hospitals Birmingham NHS Foundation Trust, Birmingham, UK

^bDepartment of Radiology, Walsall Manor Hospital, Birmingham, UK

^cUniversity of California-Davis, Sacramento, CA, USA

ARTICLE INFO

Article history:

Received 21 May 2018

Revised 28 July 2018

Accepted 3 August 2018

Available online 11 September 2018

Keywords:

Cerebral air embolism

Endoscopic trauma

ABSTRACT

The incidence of cerebral infarction following upper gastrointestinal endoscopic procedures is well described in the existing literature, with most mechanisms involving arterial travel of the embolus. We describe a case of cerebral infarction not explained by previously described mechanisms and detail the proposed occurrence of retrograde venous air embolism causing cerebral infarction following an upper gastrointestinal endoscopic procedure.

© 2018 The Authors. Published by Elsevier Inc. on behalf of University of Washington.

This is an open access article under the CC BY-NC-ND license.

(<http://creativecommons.org/licenses/by-nc-nd/4.0/>)

Introduction

Cerebral infarction following upper gastrointestinal endoscopic procedures has been well documented in the literature, affecting around 0.04% of patients [1]. However, descriptions of cerebral air embolisms following gastrointestinal endoscopy are rare and typically describe arterial embolization. This report suggests a pathophysiological mechanism of cerebral infarction occurring through retrograde venous air embolism in the context of an upper gastrointestinal endoscopic procedure.

Case report

A 72-year-old man presented with a history of dysphagia secondary to eosinophilic esophageal strictures since 2007. The patient has had endoscopies in the past for obtaining biopsy and treating a previous food bolus obstruction. The patient also had undergone multiple stricture dilation procedures, which were unsuccessful in managing his condition. Due to his esophagitis, these procedures had been complicated by the occurrence of mucosal tears even with the use of the smallest viable probe.

Funding: No specific funding was received for this work.

Declaration of Interest: There are no conflicts of interests for any of the authors of this research.

* Corresponding author.

E-mail address: hasaamuldin@gmail.com (H.H.U. Uldin).

<https://doi.org/10.1016/j.radcr.2018.08.002>

1930-0433/© 2018 The Authors. Published by Elsevier Inc. on behalf of University of Washington. This is an open access article under the CC BY-NC-ND license. (<http://creativecommons.org/licenses/by-nc-nd/4.0/>)

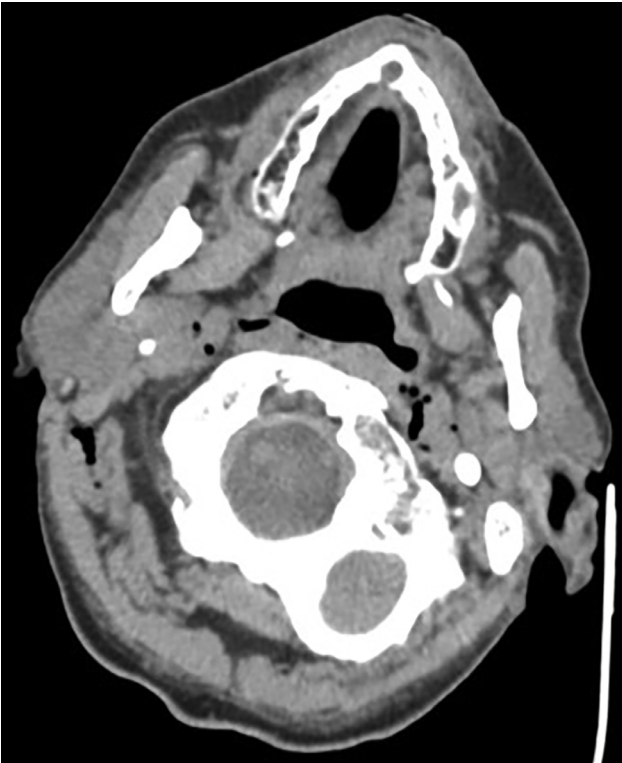


Fig. 1 – CT scan of the neck showing the bilateral presence of air within soft tissues around the carotid sheaths.

Apart from his dysphagia, this patient also suffered with asthma and was an ex-smoker. He was otherwise healthy with a medication list comprising only of oral Lansoprazole and Salbutamol inhalers.

In December 2015, the patient presented with food bolus obstruction. Nasoendoscopic retrieval was successful in pushing the bolus distally, but the procedure was complicated by submucosal perforation of the esophagus. There was no hemorrhage or changes in the patient's anesthetic condition during the procedure. The procedure was done with the patient in the supine position and the patient remained in this position for 2 hours during recovery. Upon mobilizing and becoming upright after this period, the patient developed profound weakness in his right arm (power 1/5).

Imaging using a chest plain film radiograph was unremarkable. An urgent, same day computed tomography (CT) scan of the head showed bilateral subcutaneous emphysema in the upper neck and air was seen around the carotid sheath on both sides (Fig. 1). Intracranial gas was seen around the sella turcica within the cavernous sinus and the pituitary fossa, surrounding the pituitary gland (Fig. 2a and b). Long standing changes in the brain including cortical atrophy and small vessel infarcts in the cortex were also seen. The gas foci disappeared on the follow up CT scan done 5 hours later. A CT neck, thorax, abdomen, and pelvis scan on the same day showed extensive pneumomediastinum and extensive emphysema in the neck.

A magnetic resonance imaging scan of the head was done the following day (Fig. 3). Several acute focal infarcts were

noted bilaterally in the peripheral cortex with the largest in the left precentral gyrus. No other lesions were noted. Doppler ultrasound of the carotid and vertebral arteries performed 6 days later did not show any thrombosis. The patient was discharged 3 days following this and the weakness in the arm had improved with only conservative management (power 3/5).

Discussion

The symptoms of right-sided weakness in the upper limb of the patient were consistent with the largest of the infarcts located in the left-sided precentral gyrus. The literature covers several potential mechanisms for cerebral infarction following an upper gastrointestinal endoscopy. However, this case is substantially different from much of the described literature.

The most well-described mechanism of infarction is that of arterial cerebral air embolism of which there are several possible mechanisms [2–5]. Theoretically, air embolism would require a communication between the lumen of the scoped bowel and the vascular bed in addition to a pressure gradient facilitating the air passage from the former to the latter [6].

In most cases, the proposed pathophysiology is that air insufflates through esophageal veins following compromise of the esophageal wall and vessels. The resulting air embolus travels to the right side of the heart. Here, a right-to-left shunt (most commonly a patent foramen ovale) deposits the embolus into the arterial circulation from where it can cause cerebral infarction. Although insufflation of air into esophageal veins is plausible in our patient, he had been investigated using bubble echocardiography following discharge and this excluded the presence of an intracardiac right-to-left shunt. Theoretically, a paradoxical embolism from veins to arteries in the peripheral or pulmonary circulation is also possible and has been described in the literature but could not be clinically investigated in our case [7]. Furthermore, the presence of air within the venous system of the cranium is not accounted for by a paradoxical embolism hypothesis.

Cardiogenic emboli were also considered as a potential source of arterial embolism. An underlying arrhythmia could have manifested during the gastroscopy and resulted in cardiogenic emboli originating from the left side of the heart depositing in the brain. However, Holter monitoring following discharge excluded any arrhythmias. Additionally, this hypothesis also does not account for the presence of air in the head and neck.

We also considered whether there were any other potential sources that could introduce air into the peripheral circulation, such as cannulas, lines, or wounds. However, these were not present at the times of endoscopy, onset of symptoms, or of CT scanning.

Although, most cases in the literature follow one of these described mechanisms. However, we believe that the findings of bilateral high subcortical infarcts, air within the venous sinuses, and in the absence of right-to-left intracardiac shunt can only be explained satisfactorily by a mechanism involving the presence of an air embolus within the cerebral venous system.

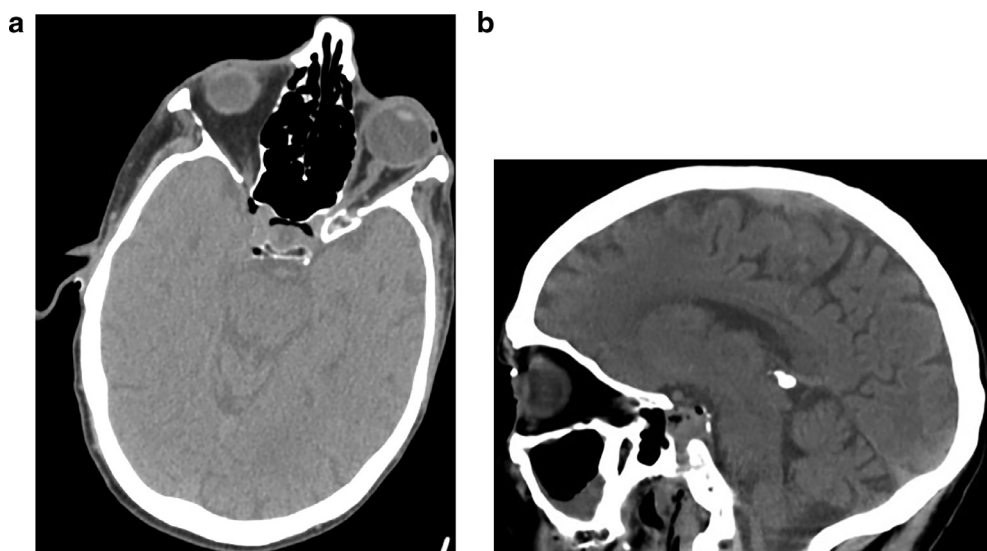


Fig. 2 – (a) CT head scan (transverse plane) showing the presence of gas within the cavernous sinus. (b) CT head scan (sagittal plane) showing the presence of gas within the cavernous sinus.

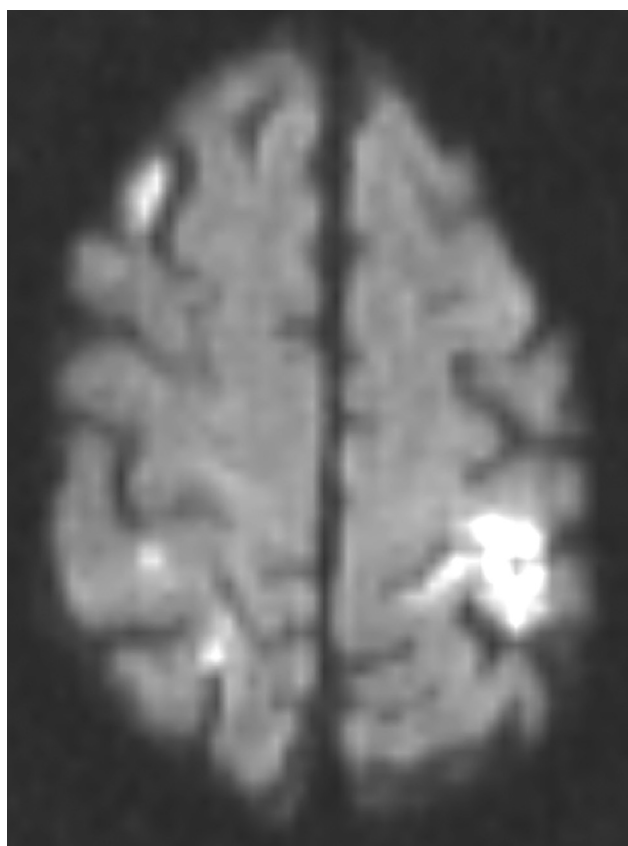


Fig. 3 – MRI scan of the brain showing the presence of bilateral focal infarcts affecting the left precentral gyrus.

This has been shown as being possible in various studies of invasive procedures including upper and lower gastrointestinal endoscopy [6,8–10]. In the context of our case, we believe that the findings of bilateral high subcortical infarcts and air

within the venous sinuses can only be explained satisfactory by a mechanism involving the insufflation of air into the right internal jugular vein. Therefore, we propose that air rather than entering into the arterial circulation entered into the venous circulation.

We suggest that the portal for air entry into the venous system was most likely via the esophageal veins. Considering the underlying eosinophilic esophagitis in our patient as well as the endoscopically noted esophageal tear, it is most likely that endoscopic perforation of the esophageal wall allowed air insufflation into the esophageal veins and soft tissues of the neck. From the esophageal veins, drainage through the azygous venous system would have returned the embolus to the right atrium. We propose that the air embolus then traveled superiorly into the superior vena cava.

From here, the embolus would have ascended retrograde to the venous blood flow to enter into the cerebral sinuses. Retrograde rise of air bubbles against the venous blood flow is a mechanism described previously in literature, commonly following venous vascular intervention and there is speculation that its prevalence is underestimated [9]. It has also been suggested that jugular valve insufficiency can predispose to retrograde embolism in the neck, but this was not demonstrated on ultrasound of the neck in our case [11].

There are 2 main pathways that the air then would have followed in our patient to deposit in 2 main locations. First, our images show air within the cavernous sinus surrounding the pituitary fossa. The air would have arrived here via ascent through the superior and inferior petrosal sinuses from the internal jugular vein.

Second, the presence of focal, bilateral, infarcts on the superior subcortical area of the brain suggests that the air passed through the right sigmoid sinus and transverse sinuses and—under the influence of gravity in the upright cranium—rose into the superior sagittal sinus. From here, the air would have become trapped within the valveless cortical veins on both sides and blocked their drainage. This would have resulted

in the bilateral focal infarcts that were seen. Ultimately, all of the ectopic air would then be reabsorbed into the interstitial space.

Conclusion

We have described a case of venous air embolism resulting in cerebral infarction following perforation of the esophagus during oesophago-gastro-duodenoscopy. We have proposed a potential sequence of events explaining this phenomenon and have presented, why we believe this is the most feasible explanation for the clinical and radiological findings that have been described. However, we recognize that this explanation cannot be definitively proved whilst competing explanations cannot be definitively excluded, thus rendering it only a hypothesis at this stage.

Supplementary materials

Supplementary material associated with this article can be found, in the online version, at doi:[10.1016/j.radcr.2018.08.002](https://doi.org/10.1016/j.radcr.2018.08.002).

REFERENCES

- [1] Parker C, Panter S. PMO-209 Incidence of stroke following endoscopy in a district general hospital. *Gut* 2012;61(Suppl 2):A159–9.
- [2] Oatis K, Agarwal A, Bruce-Tagoe C. Acute stroke from air embolism to the middle cerebral artery following upper gastrointestinal endoscopy. *Radiol Case Rep* 2010;5(1):359–365.
- [3] López JC, Pérez X, Esteve F. Cerebral air embolism during upper endoscopy. *Endoscopy* 2010;42(S 02):p41 Suppl 2.
- [4] Truyols C. Fatal air embolism after upper endoscopy in a 48-year-old man. *Endoscopy* 2012;44(S 02):p282 Suppl 2 UCTN.
- [5] Donepudi S, Chavalitdhamrong D, Pu L, Draganov PV. Air embolism complicating gastrointestinal endoscopy: a systematic review. *World J Gastrointest Endosc* 2013;5(8):p359–65.
- [6] Chorost MI, Wu JT, Webb H, Ghosh BC. Vertebral venous air embolism: an unusual complication following colonoscopy. *Dis Colon Rectum* 2003;46(8):p1138–40.
- [7] Kaichi Y, Kakeda S, Korogi Y, Nezu T, Aoki S, Matsumoto M, et al. Changes over time in intracranial air in patients with cerebral air embolism: radiological study in two cases. *Case Rep Neurol Med. Hindawi* 2015;2015(1):1–5.
- [8] Bisceglia M, Simeone A, Forlano R, Andriulli A, Pilotto A. Fatal systemic venous air embolism during endoscopic retrograde cholangiopancreatography. *Adv Anat Pathol* 2009;16(4):p255–62.
- [9] Zampeli E, Tsagalou E, Kanakakis I, Giannopoulos C, Tzanetaki A, Vemos K, et al. Fatal cerebral air embolism complicating esophageal dilation. *Endoscopy* 2013;45(S 02):p358 Suppl 2 UCTN-8.
- [10] Spanuchart I, Tamura A, Matsuda B, Leo QJN, Sung H. Cerebral venous air embolism secondary to mesenteric infarction. *Hawai J Med Public Health* 2016;75(5):p133–759.
- [11] Nedelmann M, Pittermann P, Gast KK, Mueller-Forell W, Dieterich M. Involvement of jugular valve insufficiency in cerebral venous air embolism. *J Neuroimaging*. 2007;17(3):p258–60 Wiley/Blackwell (10.1111).