

UCLA

UCLA Previously Published Works

Title

Altered glomerular extracellular matrix synthesis in experimental membranous nephropathy

Permalink

<https://escholarship.org/uc/item/0mp3q052>

Journal

Kidney International, 42(3)

ISSN

0085-2538

Authors

Floege, Jürgen
Johnson, Richard J
Gordon, Katherine
et al.

Publication Date

1992-09-01

DOI

10.1038/ki.1992.321

Peer reviewed

Altered glomerular extracellular matrix synthesis in experimental membranous nephropathy

JÜRGEN FLOEGE, RICHARD J. JOHNSON, KATHERINE GORDON, ASHIO YOSHIMURA, CARYL CAMPBELL, LUISA IRUELA-ARISPE, CHARLES E. ALPERS, and WILLIAM G. COUSER

Division of Nephrology, Department of Medicine, Department of Biological Structure, and Department of Pathology, University of Washington, Seattle, Washington, USA

Altered glomerular extracellular matrix synthesis in experimental membranous nephropathy. Chronic progressive membranous nephropathy (MN) in humans is characterized by thickening of the glomerular basement membrane (GBM) with formation of spikes which contain laminin and other extracellular matrix (ECM) proteins. We have utilized two models of MN in the rat (active and passive Heymann nephritis, AICN, PHN) to define the sequential changes in composition of GBM as they relate to changes in glomerular gene expression for ECM components, altered permeability and morphological changes. Renal biopsies obtained during the course of AICN and PHN were immunostained for various ECM proteins and total glomerular RNA was hybridized with cDNA probes specific for laminin B₂-chain, s-laminin, and types I and IV collagen. In addition, the ability of anti-glomerular epithelial cell (GEC) antibody and complement on rat GEC in culture to induce laminin release or laminin and s-laminin mRNA expression was determined. The results demonstrate that at weeks 12, 16, and 20 of AICN, immunostaining for laminin, s-laminin, fibronectin, entactin, and heparan sulfate proteoglycan increased in the GBM in a spike-like pattern. Concomitantly, glomerular mRNA levels of laminin B₂-chain and of s-laminin increased. Type IV collagen protein and gene expression remained unchanged or decreased. No glomerular immunostaining for type I collagen occurred during AICN despite increased expression of mRNA for this collagen type. In contrast to AICN, in PHN no pronounced changes of the glomerular ECM occurred, except for transient expression of type I collagen mRNA in whole glomerular RNA and type I collagen protein the GEC cytoplasm. Stimulation of GEC in culture with anti-GEC antibody and complement also failed to induce transcription of laminin or s-laminin mRNA or the release of laminin protein. These findings suggest that the polyantigenic expansion of GBM which occurs in chronic experimental MN may be stimulated by factors different from the C5b-9 mediated processes that cause the initial proteinuria.

Membranous nephropathy (MN) is the most common cause of idiopathic nephrotic syndrome in adults [1]. In about 50% of cases the lesion is a progressive one leading to renal failure [1]. MN is induced by the formation of immune deposits in an exclusively subepithelial distribution accompanied by deposits of the complement components C3 and C5b-9 [reviewed in 2-5]. In early MN, glomerular morphology by light microscopy is

essentially normal. However, as the disease progresses, it is characterized by increased thickness of the glomerular capillary wall due to expansion of the glomerular basement membrane (GBM). This expansion appears to result primarily from increased deposition of extracellular matrix (ECM) along the outer surface of the GBM, usually in the form of spike-like protrusions of the GBM between glomerular epithelial cells (GEC) [5-9]. Some studies have suggested that laminin is a principal component of the expanded GBM [10, 11] whereas others have revealed a more heterogeneous composition of the spikes [12, 13]. This thickened GBM exhibits persistent abnormal permeability to serum proteins and may lose ultrafiltration properties as well [14, 15].

The pathogenesis of MN has been extensively studied in the Heymann nephritis models in rats which bear striking similarities in morphology, immunopathology and clinical features to the human disease. In these models MN results from deposition of antibody (anti-Fx1A) to antigen(s) on the visceral GEC membrane, and altered GBM permeability is the consequence of insertion of C5b-9 into the GEC membrane [reviewed in 4, 5]. Like the human disease, chronic Heymann nephritis (autologous immune complex nephritis, AICN) exhibits progressive GBM thickening and spike formation [6]. The purpose of the present study was to evaluate the contribution of distinctive components of the normal ECM to the increased GBM thickness in chronic experimental MN, to assess sequential changes in glomerular ECM gene expression as they relate to functional and structural glomerular changes in this model and to evaluate the possible role of C5b-9 attack on the GEC in vivo and in vitro in inducing these changes. Since it is impossible to maintain complement depletion for extended periods in vivo, and since no rats genetically deficient in terminal complement components exist, the latter studies were carried out in the short term, passive Heymann nephritis (PHN) model as well as in rat GEC in culture. Our findings demonstrate that a polyantigenic expansion of the GBM occurs in AICN and that laminin and a recently described analogue of the laminin B₁-chain, s-laminin [16], are prominent ECM proteins contributing to this expansion. Furthermore, the data show that GBM thickening is preceded by increased laminin and s-laminin gene expression in AICN, but not in PHN, and that sublytic C5b-9 attack has no demonstrable effect on GEC release of laminin and laminin or

Received for publication February 18, 1992
and in revised form April 22, 1992
Accepted for publication April 24, 1992

© 1992 by the International Society of Nephrology

s-laminin gene expression. These results suggest that the mechanism(s) responsible for progressive glomerular disease in MN may differ from those which mediate proteinuria acutely.

Methods

Experimental design

In vivo studies. AICN was induced in 30 Lewis rats (see below). Twenty-four-hour urine protein excretion was determined at weeks 0, 4, 6, 12, 16 and 20. Urine protein excretion was measured by a method utilizing sulfosalicylic acid [17] with a whole serum standard (Lab Trol, Dade Diagnostics, Aquado, Puerto Rico, USA). Following the urine collection, renal biopsies were obtained from four randomly selected rats at each time point.

PHN was induced in 24 Sprague Dawley rats (see below). Six normal rats and six rats that were depleted of complement with cobra venom factor (CVF) prior to induction of PHN were studied as controls. Twenty-four-hour urinary protein excretion was determined in the six normal rats, in six randomly selected PHN rats each at days 2 through 3, 4 through 5, 9 through 10 and 14 through 15, as well as in the PHN/CVF rats at days 4 through 5. After the urine collections rats were sacrificed and renal biopsies were obtained.

Following the renal biopsies glomeruli were isolated from the remaining kidney tissue using a differential sieving procedure [18]. Two (AICN) or three (PHN) separate glomerular preparations were performed at each time point. The isolated glomeruli contained less than 5% tubular contamination at any time point and were used for the extraction of total RNA for Northern analysis.

The glomerular morphology was analyzed in PAS and silver methenamine stained sections of the renal biopsies. Furthermore, the renal biopsies were analyzed immunohistochemically for the glomerular distribution of IgG, C3, C5b-9 as well as the ECM proteins laminin, s-laminin, type I and IV collagen, fibronectin, entactin/nidogen, and heparan sulfate proteoglycan. Northern blots were probed using cDNAs specific for laminin B₂-chain, s-laminin, type I and IV collagen, and 28S rRNA.

In vitro studies. Using cultured rat GECs, studies were performed to investigate the effect of anti-Fx1A or normal sheep IgG plus complement on the cellular release of laminin. Laminin released into the cell culture medium was measured using a specific enzyme-linked immunosorbent assay (ELISA; see below). Expression of laminin B₂-chain and s-laminin mRNA was analyzed in total cellular RNA obtained from non-stimulated GEC or GEC subjected to sublytic antibody and complement exposure.

Induction of passive Heymann nephritis and autologous immune complex nephritis

AICN was induced by immunizing male Lewis rats (Simonson, Gilroy, California, USA), weighing 180 to 220 g, in the rear foot pads with 5 mg freshly prepared Fx1A emulsified in complete Freund's adjuvant (Difco Laboratories, Detroit, Michigan, USA) as described previously [19].

PHN was induced in male Sprague-Dawley rats (Tyler Laboratories, Bellevue, Washington, USA) weighing 190 to 210 g,

by i.v. injection of 1 ml sheep antibody to Fx1A prepared as described in detail elsewhere [20].

Complement depletion

Rats were depleted of complement with CVF (*Naja naja kaouthia*, Diamedix Corporation, Miami, Florida, USA) [21]. Serum C3 levels, obtained daily, were measured by radial immunodiffusion [21] and maintained at <10% of baseline values throughout the study period.

Renal morphology

Tissue for light microscopy and immunoperoxidase staining was fixed in methyl Carnoy's solution [18] and embedded in paraffin. Four μm sections were stained with the periodic acid Schiff (PAS) reagent and counterstained with hematoxylin. Sections were also stained with silver methenamine to assess glomerular ECM changes.

Immunoperoxidase staining

Four μm sections of methyl Carnoy's fixed biopsy tissue were processed by a direct or indirect immunoperoxidase technique as previously described [18]. Primary antibodies included:

- an IgG fraction of polyclonal rabbit anti-rat laminin (Chemicon, Temecula, California, USA). Alternatively a biotinylated [22] IgG fraction of this antibody was used.

- D18, a monoclonal murine antibody specific for the laminin B₂-chain (gift of J. Sanes, St. Louis, Missouri, USA) [23].

- D5, a monoclonal mouse anti-rat s-laminin antibody (gift of J. Sanes) [16].

- an IgG fraction of polyclonal guinea pig anti-rat type I collagen [24].

- a biotinylated [22] IgG fraction of polyclonal goat anti-mouse type IV collagen (Southern Biotech, Birmingham, Alabama, USA).

- an affinity-purified IgG fraction of a polyclonal rabbit anti-rat fibronectin (Chemicon).

- an IgG fraction of polyclonal rabbit anti-mouse entactin/nidogen (gift of A.E. Chung, Pittsburgh, Pennsylvania, USA) [25].

- an IgG fraction of a polyclonal rabbit antibody to mouse core protein of heparan sulfate proteoglycan (gift of J.R. Couchman, Birmingham, Alabama, USA) [26].

For all biopsies, negative controls consisted of substitution of the primary antibody with equivalent concentrations of an irrelevant murine monoclonal antibody or normal rabbit IgG.

For each biopsy over 20 cross sections of consecutive cortical glomeruli containing more than 20 discrete capillary segments each were evaluated by an observer, who was unaware of the origin of the slides. Glomerular staining for type I collagen was quantitatively assessed by counting the cells located in the periphery of the capillary loop which exhibited

positive cytoplasmic staining and expressed as positive cells/glomerular cross section.

Immunofluorescence staining for glomerular rat IgG, C3, C5b-9, and type I collagen

Immunofluorescence detection of rat IgG, C3, C5b-9, and type I collagen in glomeruli was carried out on 4 μm sections of frozen, ether/ethanol fixed kidney tissue using a direct (rat IgG, C3) or indirect (C5b-9, type I collagen) immunofluorescence procedure, as described elsewhere [19, 27]. Sections were studied with fluorescein-conjugated IgG fractions of monospecific antisera to rat IgG, and rat C3 (Cappel Laboratories, Cochranville, Pennsylvania, USA) and biotinylated [22] 2A1, a murine monoclonal antibody to a neoantigen of C5b-9 [28], followed by fluorescein-conjugated streptavidin (Amersham, Arlington Heights, Illinois, USA).

Electron microscopy

Tissue for electron microscopy was fixed, processed and examined as described previously [29]. Ultrastructural studies were performed on three specimens each obtained at week 4, 8, 12, 16, and 20 (3 to 6 glomeruli were evaluated in each specimen).

Rat GEC culture

Rat GEC were established in culture from isolated glomeruli as described previously [30]. Morphological and immunofluorescent characterization of the cells demonstrated a polygonal shape with cobblestone appearance upon confluency, positive immunostaining with anti-Fx1A, and anti-cytokeratin, but no staining with anti-factor VIII or anti-Thy 1.1 [30]. Furthermore, in contrast to a recent report [31] on the characterization of cells obtained from glomerular outgrowths, the cultured GEC used for this study also stained positive for podocalyxin, a marker of visceral GEC [30]. Finally, puromycin aminonucleoside exhibited toxic effects on the cells [30].

GEC were maintained in 100 mm tissue culture dishes (Becton Dickinson, Lincoln Park, New Jersey, USA), coated with a bovine dermal collagen matrix (Vitrogen[®], Collagen Corporation, Palo Alto, California, USA). The cell culture medium consisted of K1 medium [32]. Cells were passaged with collagenase and trypsin/EDTA as described [30].

GEC release of laminin following antibody and complement mediated injury

GEC (passages 12 to 21) were seeded into 24-well tissue culture dishes (Corning Glass Works, Corning, New York, USA) and allowed to reach subconfluency in K1 medium. Following washing with cold veronal buffered saline [33], the cells were incubated with anti-Fx1A or normal sheep IgG (4 mg/ml) for 15 minutes on ice to allow binding of antibody to the cells without patching and capping of the antigen-antibody complexes [34–36]. This concentration of antibody was selected on the basis of pilot studies which demonstrated it provided the maximal amount of antibody IgG binding to GEC in culture without inducing cytotoxicity as assessed by lactate dehydrogenase (LDH) release (see below). After duplicate washing with veronal buffered saline, 2% pooled normal, fresh frozen human serum or heat-inactivated serum (30 min at 56°C) in veronal

buffered saline was added as a complement source. This serum concentration was selected as the highest concentration that cells sensitized with maximal sublytic antibody concentrations could be exposed to without any cytotoxicity as assessed by LDH release (see below). Cells were then incubated at 37°C for 90 minutes. Thereafter, the supernatant was removed and the LDH concentration was determined (see below). The cells were washed twice with Hank's balanced salt solution (Irvine Scientific, Santa Ana, California, USA) and then incubated for 72 hours in K1 medium at 37°C, 5% CO₂ and 100% humidity. Further controls included non-stimulated cells and cells stimulated for 72 hours with 5×10^{-7} M/ml phorbol 12-myristate 13-acetate (PMA; Sigma, St. Louis, Missouri, USA). In some studies the effects of differences in times and temperature of both antibody and complement exposure were tested as were variations in incubation times after antibody and complement exposure. At the end of the incubation period the supernatants were collected and stored at -70°C for laminin determination. Laminin concentrations per experiment represent the mean of 3 to 6 individual measurements. Each individual laminin measurement was normalized for cell numbers as measured by the DNA content (see below) of the corresponding cell layer.

For the determination of the cellular DNA content, the cell layers were harvested by removing the Vitrogen gel into a microfuge tube. Following an incubation at 65°C for three minutes to liquify the gel, the tubes were centrifuged (11,000 g, 5 minutes) and the pellet was then resuspended in 10 mM Tris buffer, pH 7.4 and stored at -70°C. The DNA content of the resuspended pellets was determined using a colorimetric diphenylamine assay [37].

The cellular release of LDH into the medium was determined at 90 minutes (see above) and at the end of the incubation period (72 hr) to ensure that the experiments had been carried out under conditions that did not cause any direct cytotoxicity. LDH was measured using a colorimetric test kit (LDH-LD; Sigma).

Laminin ELISA

A laminin ELISA was established using principles described previously [28]. Briefly, wells of microtitration plates (Nunc, Roskilde, Denmark) were coated with 15 ng of the primary antibody (an IgG fraction of a polyclonal rabbit anti-rat laminin antibody, Chemicon). After blocking of the wells with 0.2% casein (Sigma), the samples were added. The samples were followed by 0.15 μg /well secondary antibody (=biotinylated [22] primary antibody). Bound secondary antibody was detected with streptavidin-peroxidase (Vector, Burlingame, California, USA) and subsequent color development using acinodi-[3-ethylbenzthiazolinsulphonate (6)] (ABTS; Boehringer, Mannheim, Germany). Purified murine laminin (Gibco, Gaithersburg, Maryland, USA) served as a standard. The assay gave linear readings at laminin concentrations between 1.5 and 100 ng/ml. The detection limit of the ELISA was 1.0 ng/ml laminin and the intra-assay coefficient of variation was <1%. The ELISA failed to detect 100 ng/ml of rat type I and III collagen (a gift of H. Sage, Seattle, Washington, USA), murine type IV collagen (Collaborative Research, Bedford, Massachusetts, USA), rat fibronectin (Chemicon), or K1 medium.

Preparation of GEC and glomerular RNA and Northern analysis

Total RNA was extracted from GEC's or isolated glomeruli with RNazol B® following the manufacturer's instructions (Cinna/Biotecx Laboratories, Friendswood, Texas, USA) and further purified by a LiCl precipitation as described elsewhere [38]. For Northern analysis the RNA was denatured and 15 µg/lane were electrophoresed through a formaldehyde/agarose gel and transferred to a nylon filter (Hybond N, Amersham) as described elsewhere [39]. The cDNA probes used for Northern analysis were as follows:

(1) *Laminin B₂ chain*. A 1.7 kb ECO RI/Xba I fragment of mouse laminin B2 cDNA isolated from plasmid p1298 was used to detect the 8 kb laminin B2 transcript [40]. The probe was a gift of Y. Yamada, Bethesda, Maryland, USA.

(2) *s-Laminin*. A 2.5 kb ECO RI fragment from cDNA clone RK65-6 from a rat kidney library was used to detect the 5.7 kb s-laminin mRNA transcript [16]. The probe was a gift of J. Sanes.

(3) *Type I collagen*. An ECO RI/Hind III fragment of mouse $\alpha 1(I)$ collagen from cDNA clone Ma1(I)3'UTR of 2.3 kb was used to detect the 5.7 and 4.7 kb transcripts of type I collagen [41]. The probe was a gift of M. Chu, Piscataway, New Jersey and J. Slack, Seattle, Washington, USA.

(4) *Type IV collagen*. A 1.8 kb ECO RI/Hind III fragment of mouse $\alpha 1(IV)$ collagen cDNA from plasmid pPE123 was used for the detection of the 6.2 and 6.8 type IV collagen transcripts [42]. The probe was a gift of M. Kurkinen, Piscataway, New Jersey, USA.

(5) *28S ribosomal RNA*. A bovine 280 bp cDNA probe was used to detect 28S ribosomal RNA [43].

All probes were labeled with [α -³²P]-deoxycytidine 5-triphosphate (3000 Ci/mmol, New England Nuclear, Boston, Massachusetts, USA) by random primer extension. In preliminary experiments all of these probes have been shown to crosshybridize with the respective rat mRNAs. Positive controls included total RNA isolated from BALB/c 3T3 fibroblasts (type I collagen), mouse F9 cells (type IV collagen and laminin B2 chain) and rat aortic smooth muscle cells (s-laminin).

Membranes were prehybridized and hybridized as described [39] and autoradiograms were obtained and read by linear densitometry [39]. Some membranes were rehybridized with additional probes (up to a maximum of 4×) [39].

Quantitation of mRNA

Glomerular mRNA levels were quantified by slot blot analysis prepared with 2, 1 and 0.5 µg of each RNA sample and control RNAs as described [38]. Densitometry readings were normalized for equivalent amounts of 28S ribosomal RNA per lane [39]. Values are expressed as optical density units relative to the specific mRNA level observed in RNA from normal glomeruli or non-stimulated GEC.

Statistical analysis

All values are expressed as mean \pm SD unless stated otherwise. Statistical significance (defined as $P < 0.05$) was evaluated using the Student's *t*-test or one way analysis of variance with modified *t*-tests performed using the Bonferroni correction [44].

Results

Immunostaining for ECM proteins in normal rats

In normal Lewis or Sprague Dawley rats, laminin, type IV collagen, and fibronectin were detected in the mesangium in a focal manner (Fig. 1a,g,i). Although the glomerular and tubular basement membranes showed either weak or non-detectable staining (Fig. 1a,g,i), all of these antibodies showed reactivity with the GBM when used on cryostat sections with an immunofluorescent method. We have previously shown that immunofluorescent staining of cryostat sections is more sensitive than the immunoperoxidase method in detecting antigens in the GBM [45]. However, the intense staining of GBM by immunofluorescence for a number of antigens, including type IV collagen, laminin and fibronectin, prevented the reproducible analysis of small variations. Immunoperoxidase staining was therefore utilized in the present study. Immunostaining for s-laminin resulted in minimal mesangial staining although it could be frequently detected in the hilus of the glomerular tuft (Fig. 1c). As in the case of laminin, immunofluorescent staining for s-laminin showed bright positivity in the GBM [45]. Staining for type I collagen was confined to the interstitium and vessel walls and was absent in normal glomeruli (Fig. 1e). Staining for entactin/nidogen was confined to vessel walls with minimal or absent mesangial staining [45] (data not shown). Mesangial staining for heparan sulfate proteoglycan was variable, and positive staining of the GBMs was observed in most glomeruli using the immunoperoxidase method (Fig. 1k).

Development of AICN

An increase in urine protein excretion was first detectable in some AICN rats at week 6, although this was not significantly different from controls (30 ± 28 mg/24 hrs vs. 4 ± 3 mg/24 hrs in normal Lewis rats). Thereafter, significant proteinuria ($P < 0.05$ vs. controls) persisted with values of 291 ± 119 mg/24 hours at week 12 and 263 ± 186 mg/24 hours at week 20. As previously described [27], all proteinuric AICN rats exhibited typical subepithelial immune deposits of rat IgG, C3 and C5b-9. By light microscopy there was no significant abnormalities in glomerular morphology until week 12. Progressive silver methenamine staining of an irregularly widened GBM showing "spikes" was noted at weeks 12 and 20 (data not shown). Furthermore, at weeks 12 and 20 enlargement of the glomerular tuft areas was observed (Fig. 1b,d,f,h). Electron microscopy demonstrated areas of new basement membrane accumulation around immune deposits in biopsies obtained as early as eight weeks after disease induction (Fig. 2a). Accumulation of new basement membrane matrix, including organization into distinct "spikes", was progressive by twenty weeks (Fig. 2b). This accumulated GBM matrix frequently surrounded and appeared to incorporate the subepithelial immune deposits into the underlying GBM (Fig. 2b).

ECM protein immunostaining in glomeruli of rats with AICN

Glomerular and, in particular, GBM immunostaining for both laminin and s-laminin did not show significant changes from the normal staining pattern prior to week 12. A progressive increase in immunostaining for both laminin and s-laminin in the widened GBM was observed in rats with AICN at weeks 12, 16 and 20 (Fig. 1b, 1d). Increased laminin staining of the GBM was

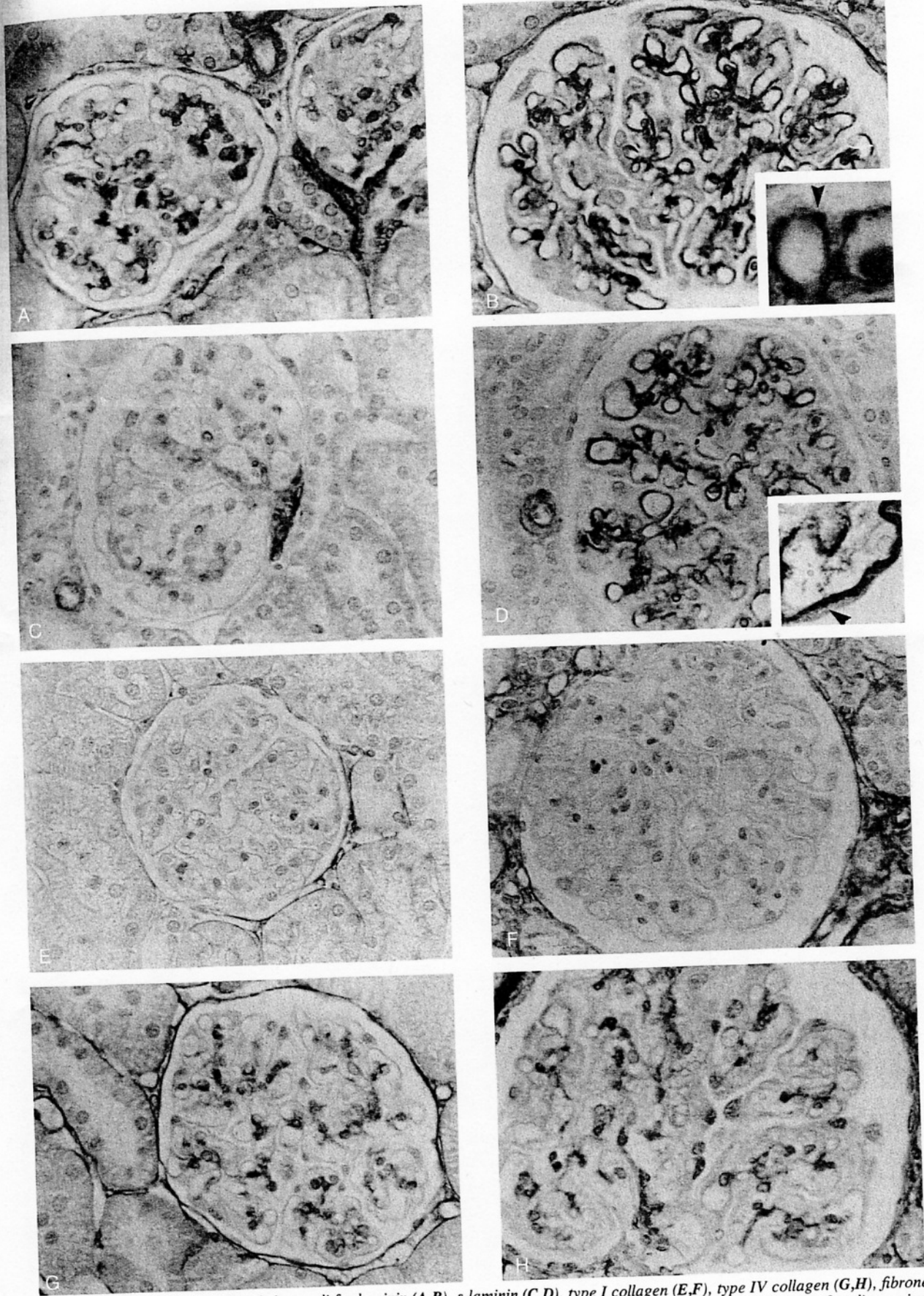
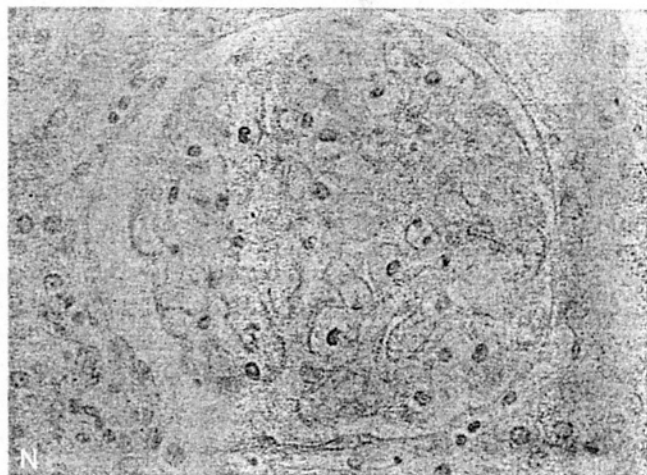
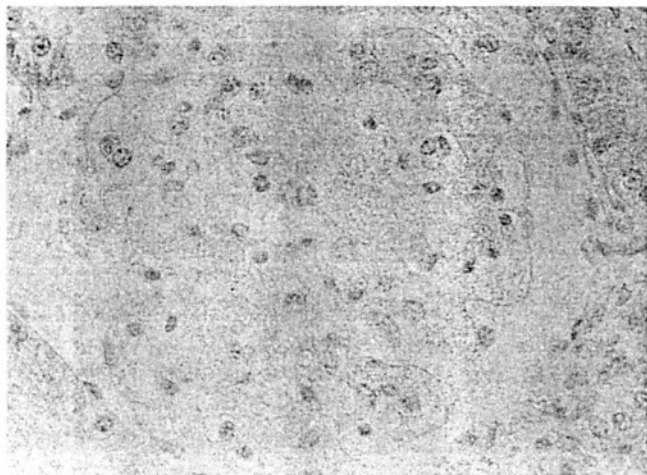
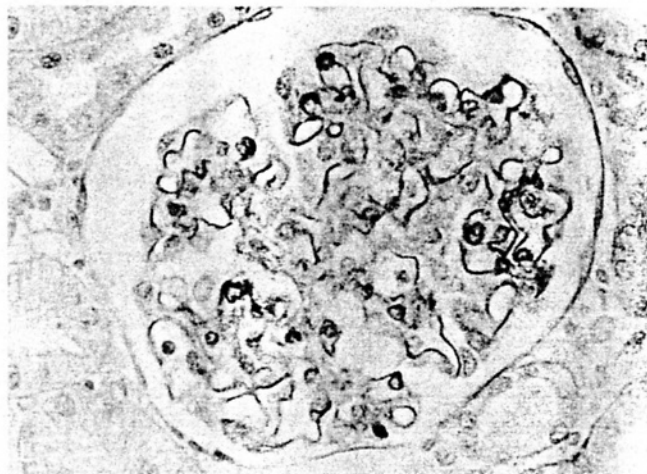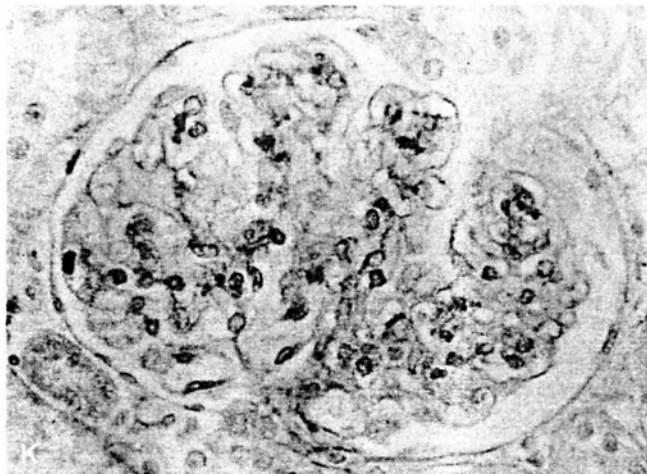
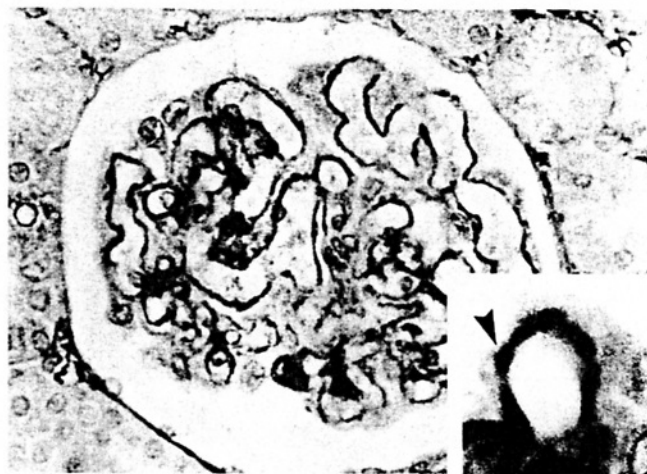
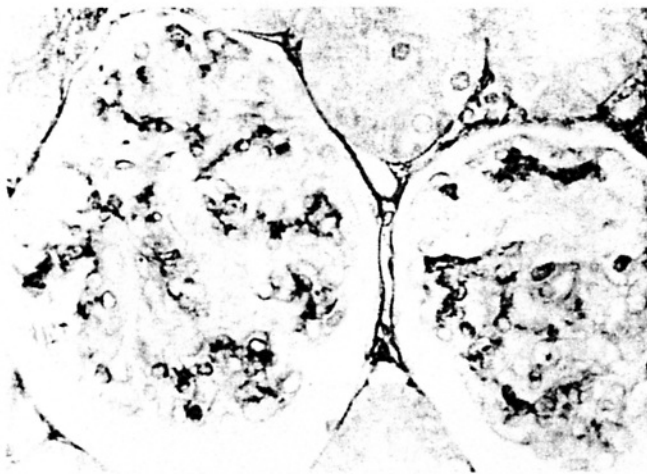


Fig. 1. Immunohistochemical staining of glomeruli for laminin (A,B), s-laminin (C,D), type I collagen (E,F), type IV collagen (G,H), fibronectin (I,J), and heparan sulfate proteoglycan (K,L) in normal Lewis rats (A,C,E,G,I,K) and in rats with AICN at week 20 (B,D,F,H,J,L) after disease induction. In rats with AICN there is increased staining of the GBM in a "spike-like" pattern (B,D,J; arrows) for laminin, s-laminin, fibronectin, and heparan sulfate proteoglycan (B,D,J,L). In addition, there is increased mesangial staining and GEC staining for fibronectin in AICN (J). No significant glomerular staining is observed at AICN week 20 if the primary monoclonal antibody is omitted (M) or the primary polyclonal antibody replaced by normal rabbit IgG (N). Immunoperoxidase with methyl green counterstain, $\times 400$. Insert in Fig. 1D: $\times 1000$, inserts in Fig. 1B and J: $\times 1500$.



observed in a similar fashion with both the polyclonal anti-laminin antibody (Fig. 1b) and with the monoclonal antibody specific for the laminin B₂ chain (data not shown). Basement membrane staining frequently occurred in an irregular, spike-like fashion (Fig. 1b,d,j and insert in Fig. 1d). Increased glomerular immunostaining for s-laminin was not due to the detection of rat IgG deposits along the GBM by the secondary

antibody (biotinylated horse anti-mouse IgG) as no glomerular staining was observed at AICN week 20, when the primary s-laminin antibody was omitted (Fig. 1m).

No glomerular expression of type I collagen was observed throughout the course of AICN, although some periglomerular fibrosis developed (Fig. 1f). Similarly, the glomerular staining pattern for type IV collagen did not appear different from

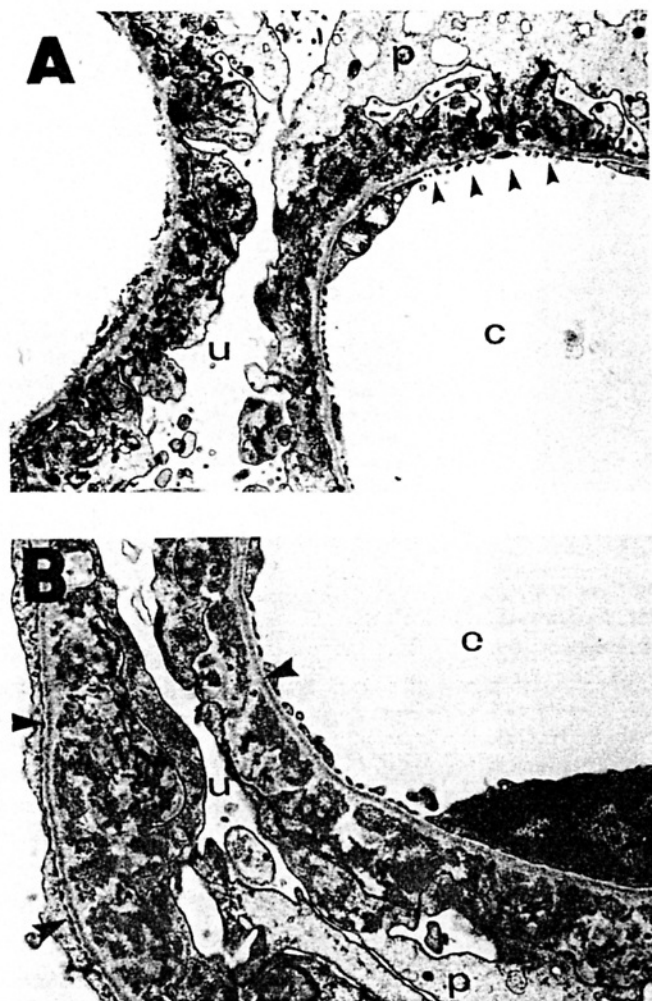


Fig. 2. Glomerular ultrastructure in rats with AICN at week 8 (A) and at week 20 (B). At week 8 there are spike-like projections of the GBM (arrows) interspersed between subepithelial immune complexes. Podocyte ("p") foot processes are distorted and fused (A). At week 20 the spike-like projections of the GBM are more prominent and frequently surround the subepithelial immune complexes (arrows). Abbreviations are: u, urinary space; c, capillary lumen. A $\times 6000$, B $\times 9000$.

normal controls when examined either by immunoperoxidase staining (Fig. 1h) or by the more sensitive immunofluorescent staining method (data not shown).

Glomerular staining for fibronectin was not altered prior to week 12. At weeks 12, 16, and 20, there were focal increases of staining in a widened GBM (Fig. 1j). Basement membrane staining occurred in an irregular, spike-like pattern (Fig. 1j). Furthermore, after week 12, mesangial staining increased in a diffuse pattern (Fig. 1j). Faint staining of the GBM for entactin/nidogen was noted at weeks 12, 16 and 20, while the remainder of the glomerular tuft showed no abnormal staining (data not shown). Heparan sulfate proteoglycan immunostaining showed focal, irregular increases in the GBM at weeks 12, 16 and 20 (Fig. 1i).

Matrix protein gene expression in glomeruli of rats with AICN

As described elsewhere [45] and confirmed in this study, the cDNAs for the various ECM proteins detected bands of the

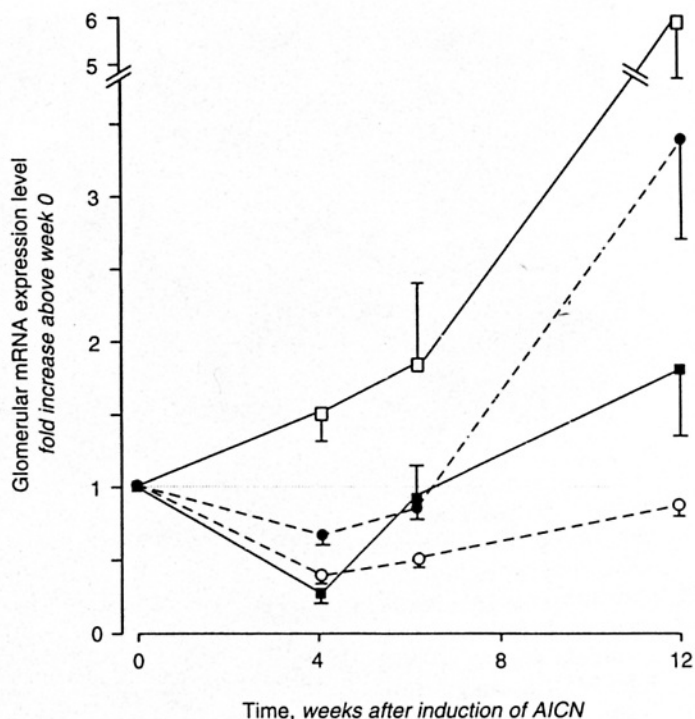


Fig. 3. Glomerular gene expression of laminin B₂-chain (■), s-laminin (●), type I (□) and type IV (○) collagen in rats at various stages of AICN. Results are mean \pm SD (N = 3) of slot blot readings and are given as densitometry readings compared to that observed with glomerular RNA from normal rats. Prior to this all readings were normalized for equivalent 28S ribosomal RNA which was measured using a specific 28S cDNA probe (Methods).

predicted sizes in total glomerular RNA during Northern analysis (data not shown). Figure 3 depicts the results of slot blot analysis of glomerular RNA obtained from rats with AICN for the expression of the various ECM protein mRNA's. In the case of laminin B₂ chain and s-laminin mRNA, an initial decrease at week 4 was followed by increased glomerular expression at week 12. A very weak transcript of type I collagen mRNA (likely to be derived from extraglomerular tissue) was detected upon slot blot analysis of normal glomerular RNA, allowing for the normalization of glomerular mRNA levels measured at later time points of the disease. Type I collagen mRNA was found to be increased at all time points examined, peaking at week 12 (Fig. 3). In contrast, no increase of the expression of glomerular type IV collagen mRNA was observed at any time point (Fig. 3).

ECM protein immunostaining in glomeruli of rats with PHN

In order to assess whether any of the alterations in ECM component gene or protein expression found in AICN were mediated by complement, the studies of protein deposition and glomerular gene expression were repeated in rats with PHN with and without complement depletion by CVF. Unlike AICN, no significant alterations in glomerular morphology or GBM expansion were seen in PHN during the study period. Marked proteinuria was present at day 5 (163 ± 70 mg/24 hrs) and persisted thereafter.

No significant changes from the normal glomerular staining

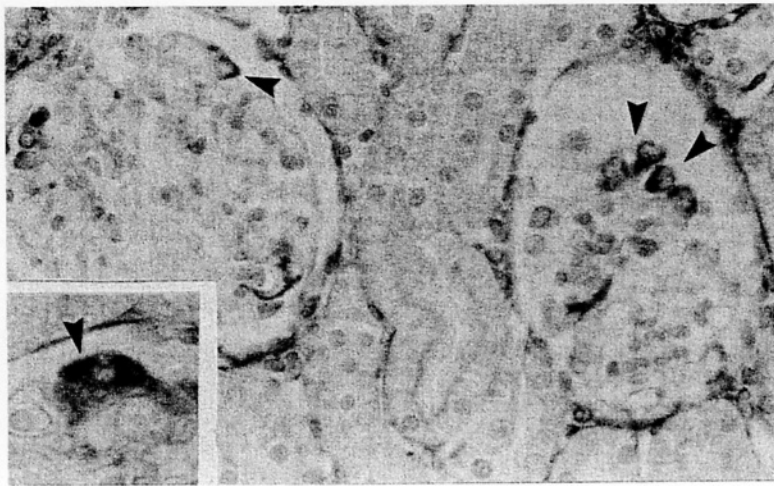

Fig. 4. Immunohistochemical glomerular staining for type I collagen in rats with PHN at day 5, showing positive staining in several cells in GEC positions (arrows). Positive staining is confined to the cytoplasm of GECs (insert; arrow). Immunoperoxidase with methyl green counterstain. $\times 400$, insert $\times 1000$.

pattern for laminin were observed in PHN prior to day 15. At day 15 there was increased cytoplasmic laminin staining in rare GEC, but no change of GBM staining was observed. S-laminin immunostaining remained unchanged in PHN at all time points examined. Furthermore, no changes of glomerular laminin and s-laminin staining were observed in complement depleted rats with PHN at day 5.

Staining for type I collagen in PHN became positive in the glomerulus as early as day 3. Type I collagen staining appeared to be confined to the cytoplasm of cells and no definite mesangial matrix staining could be demonstrated (Fig. 4). Neither immunoperoxidase (Fig. 4) nor immunofluorescent (data not shown) staining revealed the presence of type I collagen in the GBM. Most of the positive cells appeared to be GEC, as suggested by their location at the periphery of the capillary loops (Fig. 4). The number of positive cells at the edge of the glomerular tuft showed a significant ($P < 0.05$) increase in PHN at day 3 (1.9 ± 1.1 cells/glomerular cross section vs. 0.0 ± 0.0 in controls), peaked at days 5 (4.4 ± 1.7 cells) and 10 (4.5 ± 2.3 cells), and decreased at day 15 (0.7 ± 0.5 cells). Complement depletion prior to disease induction prevented the changes observed at day 5 (0.2 ± 0.2 cells). In contrast to type I collagen, no discernible alterations of the immunostaining for type IV collagen were observed during the course of PHN or in complement depleted rats with PHN.

With fibronectin and entactin/nidogen, no changes of the glomerular staining pattern were noted. In later stages of PHN (days 10 and 15) a minor decrease of the GBM staining intensity for heparan sulfate proteoglycan was observed (data not shown). No changes in glomerular fibronectin, entactin/nidogen and heparan sulfate proteoglycan staining were observed in complement depleted rats with PHN at day 5.

Matrix protein gene expression in glomeruli of rats with PHN

As shown in Figure 5A, the glomerular expression of mRNA for laminin and s-laminin increased to a minor degree at day 3 and 5 (s-laminin), while it remained unchanged or decreased at the remaining time points. None of the changes reached the level of statistical significance. Similarly, the glomerular expression of type IV collagen mRNA remained unchanged or decreased throughout the course of PHN (Fig. 5A). In contrast,

de novo expression of glomerular type I collagen mRNA was noted at days 3, 5 and 10 after disease induction (Fig. 5B). In complement depleted rats, studied at day 5 after induction of PHN, the glomerular mRNA levels for laminin, s-laminin, and type IV collagen uniformly decreased compared to control rats with PHN (Fig. 5A). Furthermore, in complement-depleted PHN rats the expression of type I collagen mRNA in glomeruli was reduced, although not completely abolished, in comparison to rats with PHN at day 5 (Fig. 5B).

Release of laminin from GEC following sublytic antibody- and complement-mediated injury

Because the increase in laminin and s-laminin deposition and gene expression observed in AICN did not occur acutely in PHN where complement effects could be studied, we also examined the effects of C5b-9 on laminin synthesis and gene expression by GEC in culture.

Table 1 shows that neither anti-Fx1a and complement mediated GEC injury nor incubation of GEC with normal sheep IgG and/or complement resulted in an increased release of laminin into the cell culture medium. These results remained unchanged when times and temperature of both antibody and complement exposure were varied or when the incubation time after antibody stimulation was changed (data not shown). In contrast, after stimulation of the GEC with PMA, laminin release was enhanced 1.6-fold. These results remained unchanged when protease inhibitors (10 mM n-ethylmaleimide, 1 mM phenylmethyl-sulfonyl fluoride, 2.5 mM EDTA, 10 $\mu\text{g}/\text{ml}$ pepstatin; final concentrations; all obtained from Sigma) were added to the medium prior to freezing (data not shown). The lack of detectable laminin release after stimulation of the GEC with antibody and complement was not due to lethal cell injury, as no increased LDH release into the medium was detectable after 90 minutes or 72 hours of stimulation. Furthermore, no differences of the DNA content per well could be detected after 72 hours of incubation under the various conditions.

Immunofluorescent staining of cultured GEC for cellular laminin showed positive cytoplasmic staining (Fig. 6), similar to that reported by others in rat mesangial cells [46]. Antibody and C5b-9 attack did not alter GEC laminin staining. Attempts to

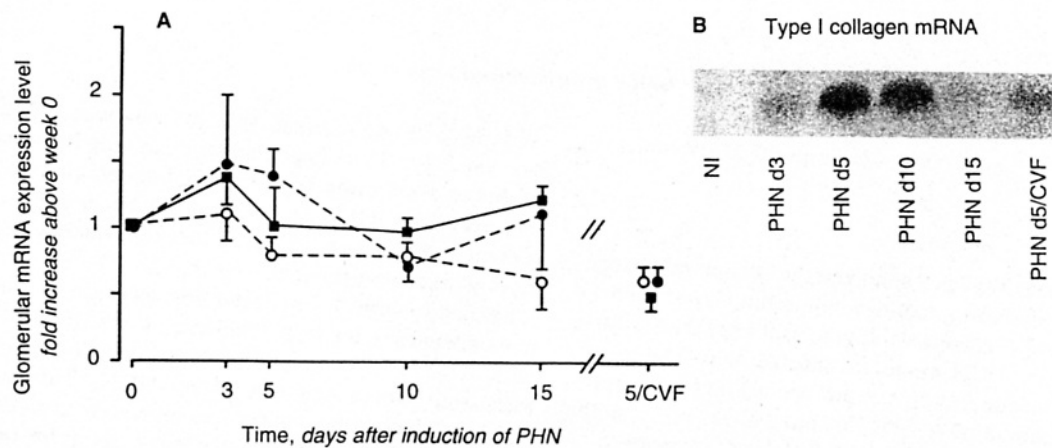


Fig. 5. Glomerular gene expression of laminin B₂-chain (■), s-laminin (●), and type IV collagen (○) (A) and type I collagen (B) in rats at various stages of PHN. Results are mean ± SD (N = 3) of Northern analyses and are given as densitometry reading compared to that observed with glomerular RNA from normal rats. Prior to this all readings were normalized for equivalent 28S ribosomal RNA which was measured using a specific 28S cDNA probe (Methods). "5/CVF"-complement depleted rats at day 5 of PHN. Relative levels of type I collagen mRNA are not depicted in A because the absence of detectable glomerular type I collagen mRNA in normals precluded normalization of the results.

Table 1. Laminin concentration in the cell supernatant and cellular expression of laminin B₂ chain mRNA 72 hours after stimulation of GEC with antibody (anti-Fx1A or normal sheep IgG) and complement (non-heated or heat inactivated) or PMA (positive control)

	Condition					PMA
	Medium	Anti-Fx1A + compl.	Anti-Fx1A + inact. compl.	Normal sheep IgG + compl.	Normal sheep IgG + inact. compl.	
Laminin in GEC supernatant % of medium	100	95 ± 24	95 ± 20	100 ± 13	100	157 ± 18
N =	8	8	8	6	2	3
P vs. medium	—	ND	ND	ND	ND	<0.05
Laminin B ₂ mRNA in GEC % of medium ^a	100	95 ± 67	91 ± 50	85 ± 43	90 ± 74	138 ± 19
N =	6	6	6	6	6	3
P vs. medium ^b	—	ND	ND	ND	ND	—
s-Laminin mRNA in GEC % of medium ^a	100	48 ± 16	49 ± 12	57 ± 13	49 ± 16	144 ± 14
N = ^b	3	3	3	3	3	3

Data are mean ± SD. Abbreviation is: ND, not determined. Absolute concentration of laminin in the culture medium of non-stimulated GEC's was 1.65 ± 1.03 ng/μg DNA at 72 hours.

^a Results are given as densitometry readings of slot blots compared with those obtained in unstimulated GEC RNA. Prior to this all readings were normalized for equivalent 28S ribosomal RNA which was measured using a specific 28S cDNA probe (see Methods).

^b Bonferroni *t*-tests. In cases of 3 observations only no statistical significance was calculated.

measure laminin in cellular extracts or in the cell layer using a variety of extraction methods yielded inconsistent results and usually the laminin content in the extract was below the detection threshold of the laminin ELISA (data not shown).

Laminin B₂-chain mRNA in GEC's after sublytic antibody- and complement-mediated injury

Both laminin B₂-chain and s-laminin mRNA were detectable in RNA isolated from non-stimulated GEC (Table 1). However, neither the cellular expression of laminin B₂-chain nor of s-laminin mRNA increased after GEC injury with anti-Fx1A and complement, but rather decreased in the case of s-laminin mRNA (Table 1). Similarly, no increase was observed after GEC stimulation with normal sheep IgG and complement. In contrast, stimulation of GEC with PMA resulted in a 1.4-fold

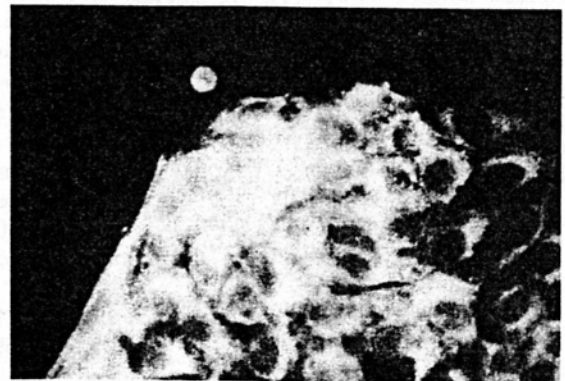


Fig. 6. Immunofluorescent staining of cultured rat GEC for laminin showing positive cytoplasmic staining. ×400.

increase of laminin B₂-chain and s-laminin mRNA expression (Table 1).

Discussion

In the present study we have analyzed the sequential changes of ECM proteins, including laminin, s-laminin, type I and IV collagen, fibronectin, entactin/nidogen, and heparan sulfate proteoglycan, in the AICN model of chronic MN. The results show that several of the proteins examined accumulated in the GBM during the course of AICN. For most ECM proteins the staining pattern in the expanded GBM was suggestive of preferential accumulation in "spikes".

On the basis of observations in human MN [11–13, 47–49] and in experimental autoimmune glomerulonephritis in mice [10], it has been suggested that GBM thickening in MN reflects in part laminin accumulation along the outer surface of the GBM and that laminin may be a major constituent of the subepithelial "spikes" [10, 11]. However, no previous studies have addressed this issue in AICN which is generally regarded as the experimental model most analogous to human MN. Our finding of a marked increase in laminin immunostaining in the GBM of AICN rats is consistent with the findings in humans and other models with subepithelial immune complex deposits. The parallel rise in glomerular laminin B₂-chain mRNA levels during AICN suggests that the increase in laminin protein was at least partially due to augmented synthesis. In contrast to laminin, little is currently known about the recently described s-laminin, which is restricted to glomerular and vascular basement membranes [16] and which is of uncertain cellular origin in the glomerulus. Our findings show that in comparison to laminin, an even more pronounced increase of s-laminin protein and gene expression occurred in glomeruli of AICN rats. The observation of a spike-like accumulation of s-laminin on the outer surface of the GBM suggests that GEC's are the likely source of the increased s-laminin synthesis. Furthermore, the cell culture data of the present study demonstrate that GEC's have the capability to produce s-laminin mRNA. In analogy to the greater increase of s-laminin than laminin synthesis in AICN, previous data obtained by Koide and Horikoshi [50] are of interest. These investigators raised monoclonal antibodies against laminin, one of which (Lam3) reacted exclusively with mesangial but not with GBM laminin in the normal human kidney. In patients with MN, however, Lam3 also stained the GBM and the authors concluded that a conformational change of the laminin deposited in pathological basement membrane had occurred [50].

In the present study neither the glomerular protein nor gene expression of type IV collagen increased during the course of AICN. Data on the immunohistochemical staining for type IV collagen in both human and murine MN are conflicting: while some authors reported an increase of this collagen type in the GBM [13], others have not been able to confirm this [10, 11]. An explanation for these apparently contradictory findings has recently been provided by Kim et al [12], who observed a selective increase of novel chains of type IV collagen [$\alpha 3(IV)NC$, $\alpha 4(IV)NC$ and Alport antigen] in the "spikes" of patients with intermediate stages of MN, while an increase of traditional type IV collagen [$\alpha 1(IV)_2$, $\alpha 2(IV)_1$] was confined to late disease stages and to the subendothelial region of the GBM. These latter findings suggest that despite the capability of

cultured GEC to produce type IV collagen [47, 51, 52], the increased type IV collagen immunostaining in human MN may be due to production by glomerular endothelial cells. Whether this occurs in AICN as well cannot be determined from the present study, since only early and intermediate stages of the disease were investigated.

Similar to type IV collagen, no increase of the glomerular immunostaining for interstitial type I collagen occurred in rats with AICN. In contrast, mRNA levels for type I collagen increased sixfold at week 12 of AICN. This increase may, however, have been falsely exaggerated compared to other matrix components by the very weak signal for type I collagen mRNA obtained in normal glomerular RNA, which was used as a denominator during the normalization of the densitometry readings. Consequently, the absolute increase in type I collagen transcript numbers is likely to be small. The relevance of the increased expression of glomerular type I collagen mRNA during AICN is therefore unclear. One possibility is that the mRNA analyzed is not entirely of glomerular origin. However, we have also observed *de novo* expression of type I collagen in GEC from remnant kidneys [53] and Salant et al have previously reported similar findings in the PHN model of MN by both Northern analysis and *in situ* hybridization [54]. Others have demonstrated occasional banded collagen fibrils, indicative of interstitial collagen fibrils, in the subepithelial space of AICN rats after 12 to 24 weeks [6]. *In situ* hybridization for type I collagen mRNA will be necessary to establish the presence or absence of this mRNA species in AICN. In contrast to AICN, in the PHN model we observed not only an increase in glomerular mRNA for type I collagen but also a complement dependent increase of the protein in GEC cytoplasm, further supporting the notion that these cells are capable of synthesizing interstitial type collagens *in vivo*. The relevance of the transient intracellular GEC expression of type I collagen to either proteinuria or ECM accumulation in PHN, however, remains unclear, as we have not been able to demonstrate conclusively the occurrence of type I collagen in the GBM or the glomerular ECM. Although interstitial types of collagen (types I or III) can be expressed in glomeruli of various progressive renal diseases [13, 55–57], so far only one study has reported the appearance of interstitial collagen (type III) in glomeruli during MN [55], while other studies were negative [13, 57]. The study demonstrating an accumulation of interstitial collagen [55] showed one of two MN patients with very rare deposits of type III collagen, which were confined to the mesangium. Thus, it seems unlikely that interstitial type collagens play a significant role in the pathogenesis of MN. Rather the appearance of glomerular type I or type III collagen in MN appears to be limited to advanced stages where mesangial sclerosis has developed.

Analogous to our findings in AICN, increased staining of the GBM for fibronectin has been observed in human MN [13], although others [10, 12] have been unable to confirm this. As in the case of the fibronectin present in normal GBM, the origin of the increased fibronectin in the basement membrane of AICN rats remains speculative. Thus, GBM fibronectin might be derived either from local synthesis by mesangial or endothelial cells [52, 58] or it may originate from circulating fibronectin, which is trapped in the basement membrane [59, 60].

GBM staining for entactin/nidogen also increased during

AICN, although to a lesser degree than for laminin, s-laminin or fibronectin. Increased entactin staining in AICN may in part reflect the fact that entactin and the laminin B₂-chain are known to co-localize in the kidney [61], probably due to stable complex formation between these two molecules [60]. Similar to our experimental data, entactin immunostaining has been observed to increase in the "spikes" of human MN as well [12, 61].

The final ECM protein investigated in AICN, heparan sulfate proteoglycan, also showed a marked increase in the GBM of AICN rats, a finding in agreement with observations in human MN [13]. Cell culture data obtained in human GEC have shown that these cells can produce three distinct types of heparan sulfate proteoglycans [62]. Our finding of an increased expression of heparan sulfate proteoglycan in the GBM of AICN rats is consistent with physiologic studies in human MN, which suggests that altered glomerular permeability in this disease is primarily a consequence of large pore defects in the size-selective barrier to protein filtration rather than a charge defect [14]. This finding is in contrast to the results reported in aminonucleoside nephrosis where a decrease in heparan sulfate proteoglycan content and mRNA has been reported [63, 64].

It is now well established that the initial increase in glomerular permeability to protein which occurs in experimental MN is mediated by insertion of the complement membrane attack complex, C5b-9, into the GEC membranes [reviewed in 4, 5]. With regard to altered GBM permeability induced by passive administration of anti-GEC antibody (anti-Fx1A), C5b-9 has been implicated as the principal mediator in the intact animal [65], the isolated perfused kidney [66], and in isolated glomeruli exposed to anti-Fx1A and complement *in vitro* [67]. In AICN induced by active immunization with Fx1A, the close similarity of immunopathological features to those in PHN [6, 19], similar properties of the deposited antibodies [68, 69] and unique excretion of C5b-9 in the urine [27, 28] all suggest that the initial alteration in glomerular permeability in this model is also C5b-9 mediated. However, to assess the role of complement in producing the ECM changes observed in chronic AICN, it was necessary to study the PHN model where the onset of proteinuria is much more rapid and selective complement depletion studies can be carried out. Unfortunately, we have been unable to document any substantial changes in ECM composition in PHN acutely. These data confirm recent findings of Fogel et al [70], who reported that glomerular laminin, type IV collagen and fibronectin protein and mRNA levels remained unchanged in rats with PHN at 1, 3 or 12 weeks. The absence of a demonstrable increase in ECM deposition in early PHN does not exclude an effect of C5b-9 on ECM component gene expression which might translate into increased matrix deposition chronically. However, studies of ECM gene expression in PHN revealed a decrease rather than increase in most matrix component mRNA levels in the early C5b-9 mediated phase of this disease. This may reflect an early severe phase of GEC injury induced by a single large dose of anti-GEC antibody with some accompanying GEC lysis and detachment that is not seen in the more insidious AICN model.

Sublytic C5b-9 attack on cultured glomerular cells can be a potent stimulus for cell activation including production of oxidants by mesangial cells and prostaglandins by mesangial and epithelial cells [71-73]. Torbohm et al [51] reported a 16-fold increase in type IV collagen production by both human

and rat GEC *in vitro* following direct, sublytic C5b-9 attack but did not study antibody-induced complement activation or laminin production. We therefore tested the effect of sublytic C5b-9 attack induced by anti-Fx1A antibody, a mechanism presumably analogous to what occurs *in vivo*, on production of laminin by GEC in culture. However, our findings did not suggest any measurable effect of C5b-9 on laminin or s-laminin gene expression or laminin protein release by the rat GEC. In preliminary experiments we have also failed to detect an effect of C5b-9 on type IV collagen mRNA expression by the GEC (W.G. Couser, unpublished data). Differences between this study and that of Torbohm et al [51] with respect to the mechanism of complement activation and the amount of C5b-9 generated preclude any meaningful comparison of these results. However, our findings in GEC cultures are consistent with our *in vivo* data and those of Fogel et al [70] that suggest no effect of C5b-9 on GEC expression of genes for ECM proteins that are overexpressed in MN.

Our findings also suggest that alterations in ECM component synthesis and gene expression follow, rather than precede, proteinuria. Thus, proteinuria was apparent at five days in PHN whereas detectable alterations in ECM staining and mRNA levels were not seen. This finding suggests that the defect in glomerular barrier function induced by C5b-9 is not a consequence of any alteration in GBM matrix component synthesis, a conclusion which accords with the observation that altered GBM permeability can be induced by C5b-9 within minutes of activation [67]. This sequence of altered permeability occurring prior to, and independent of, any change in the synthesis of ECM components also provides evidence that the stimuli which lead to changes in GEC ECM component synthesis may be different from those which result in proteinuria. However, we cannot exclude the possibilities that more chronic exposure to C5b-9 than we studied in PHN and cultured GEC may contribute to the changes described after several weeks in AICN and human MN or that ECM changes too small to be detected by our techniques precede proteinuria. Another mechanism that could be involved in the occurrence of a small but rapid change of the GBM composition is the release of a recently described gelatinase from GEC [30]. Studies by Watanabe et al [74] have shown a substantial upregulation of an apparently similar gelatinase in glomeruli obtained early in PHN. Thus, C5b-9 induced release of a GBM degrading proteinase might result in altered permeability due to a degradation rather than decreased synthesis of normal matrix components.

In summary, our studies document an increase in GBM content of several ECM components in chronic experimental MN (AICN), particularly laminin and s-laminin but also including fibronectin, entactin/nidogen and heparan sulfate proteoglycan. Glomerular mRNA was also more abundant for laminin and s-laminin and also for type I collagen, which was not found in increased quantity. In the more acute PHN model of MN, type I collagen was the only ECM component with increased mRNA levels and accompanied a transient increase in type I collagen staining in GEC cytoplasm. Antibody induced C5b-9 attack on cultured GEC did not increase laminin or s-laminin mRNA or laminin release into the culture medium. These findings suggest that the mechanisms which lead to ECM accumulation in the GBM in chronic MN may be different from

the C5b-9 mediated process which causes proteinuria and initiates the disease.

Acknowledgments

This study was supported by U.S. Public Health Service grants DK 39068, DK 43422, DK 34198, DK 07467, DK 40802, a grant from the Northwest Kidney Foundation, a grant from the American Heart Association (Washington Affiliate 91-WA-103) to L. Iruela-Arispe, and by a post-doctoral stipend of the Deutsche Forschungsgemeinschaft to J. Floege.

Reprint requests to J. Floege, M.D., Division of Nephrology RM-11, University of Washington, Seattle, Washington 98195, USA.

References

1. COUSER WG, ABRASS CK: Pathogenesis of membranous nephropathy. *Ann Rev Med* 39:517-530, 1988
2. COUSER WG, BAKER PJ, ADLER S: Complement and the direct mediation of immune glomerular injury: A new perspective. *Kidney Int* 28:879-890, 1985
3. CYBULSKY AV, QUIGG RJ, SALANT DJ: Role of the complement membrane attack complex in glomerular injury, in *Contemporary Issues in Nephrology* (vol 18), edited by WILSON CB, BRENNER BM, STEIN J, New York, Churchill Livingstone, 1988, pp. 57-86
4. KERJASCHKI D: The pathogenesis of membranous glomerulonephritis: From morphology to molecules. *Virchows Archiv B Cell Pathol* 58:253-271, 1990
5. COUSER WG: Mediation of immune glomerular injury. *J Am Soc Nephrol* 1:13-29, 1990
6. EHRENREICH T, CHURG J: Pathology of membranous nephropathy. *Pathol Ann* 3:145-186, 1986
7. ROSEN S: Membranous nephropathy: Current status. *Hum Pathol* 2:209-241, 1971
8. HABIB R, KLEINKNECHT C: Idiopathic extramembranous glomerulonephritis in children, in *Glomerulonephritis, Morphology, Natural History and Treatment*, edited by KINCAID-SMITH P, MATHEW TH, BECKER EL, New York, Wiley, 1973, p. 449
9. ALOUSI MA, POST RS, HEYMANN W: Experimental autoimmune nephrosis in rats. *Am J Pathol* 54:47-71, 1969
10. MATSUO S, BRENTJENS JR, ANDRES G, FOIDART JM, MARTIN GR, MARTINEZ-HERNANDEZ A: Distribution of basement membrane antigens in glomeruli of mice with autoimmune glomerulonephritis. *Am J Pathol* 122:36-49, 1986
11. FUKATSU A, MATSUO S, KILLEN PD, MARTIN GR, ANDRES GA, BRENTJENS JR: The glomerular distribution of type IV collagen and laminin in human membranous glomerulonephritis. *Hum Pathol* 19:64-68, 1988
12. KIM Y, BUTKOWSKI R, BURKE B, KLEPPEL MM, CROSSON J, KATZ A, MICHAEL AF: Differential expression of basement membrane collagen in membranous nephropathy. *Am J Pathol* 139:1381-1388, 1991
13. OOMURA A, NAKAMURA T, ARAKAWA M, OOSHIMA A, ISEMURA M: Alterations in the extracellular matrix components in human glomerular diseases. *Virchows Archiv A* 415:151-159, 1989
14. SHEMESH O, ROSS JC, DEEN WM, GRANT GW, MYERS BD: Nature of the glomerular capillary injury in human membranous glomerulopathy. *J Clin Invest* 77:868-877, 1986
15. SCHNEEBERGER EE, O'BRIEN A, GRUPE WE: Altered glomerular permeability in Munich-Wistar rats with autologous immune complex nephritis. *Lab Invest* 40:227-235, 1979
16. HUNTER D, SHAH V, MERLIE J, SANES J: A laminin-like adhesive protein concentrated in the synaptic cleft of the neuromuscular junction. *Nature* 338:229-233, 1989
17. BRADLEY GM, BENSON ES: Examination of the urine, in *Todd-Sanford Clinical Diagnosis by Laboratory Methods*, edited by DAVIDSON I, HENRY JB, Philadelphia, WB Saunders, 1974, p. 74
18. JOHNSON RJ, GARCIA RL, PRITZL P, ALPERS CE: Platelets mediate glomerular cell proliferation in immune complex nephritis induced by anti-mesangial cell antibodies in the rat. *Am J Pathol* 136:369-374, 1990
19. COUSER WG, STILMANT MM, DARBY C: Autologous immune complex nephritis. I. Sequential study of immune complex deposition, ultrastructural changes, proteinuria and alterations in glomerular sialoprotein. *Lab Invest* 34:23-30, 1976
20. SALANT DJ, DARBY C, COUSER WG: Experimental membranous glomerulonephritis in rats. Quantitative studies of glomerular immune deposit formation in isolated glomeruli and whole animals. *J Clin Invest* 66:71-81, 1980
21. JOHNSON RJ, PRITZL P, IIDA H, ALPERS CE: Platelet-complement interactions in mesangial proliferative nephritis in the rat. *Am J Pathol* 138:313-321, 1991
22. BIEBER F: Biotinylierung monoklonaler Antikörper, in *Monoklonale Antikörper, Herstellung und Charakterisierung*, edited by PETERS H, Berlin, Springer, 1985, pp. 209-212
23. SANES JR, ENGVALL E, BUTKOWSKI R, HUNTER DD: Molecular heterogeneity of basal laminae: Isoforms of laminin and collagen IV at the neuromuscular junction and elsewhere. *J Cell Biol* 111:1685-1699, 1990
24. FOUSER L, IRUELA-ARISPE L, BORNSTEIN P, SAGE EH: Transcriptional activity of the $\alpha_1(I)$ -collagen promoter is correlated with the formation of capillary-like structures by endothelial cells in vitro. *J Biol Chem* 266:18345-18351, 1991
25. CARLIN B, JAFFE R, BENDER B, CHUNG AE: Entactin, a novel basal lamina-associated sulfated glycoprotein. *J Biol Chem* 256:5209-5214, 1981
26. COUCHMAN JR: Heterogeneous distribution of a basement membrane heparan sulfate proteoglycan in rat tissues. *J Cell Biol* 105:1901-1916, 1987
27. PRUCHNO CJ, BURNS MW, SCHULZE M, JOHNSON RJ, BAKER PJ, ALPERS CE, COUSER WG: Urinary excretion of the C5b-9 membrane attack complex of complement is a marker of immune disease activity in autologous immune complex nephritis. *Am J Pathol* 138:203-211, 1991
28. SCHULZE M, BAKER PJ, PERKINSON DT, JOHNSON RJ, OCHI RF, STAHL RAK, COUSER WG: Increased urinary excretion of C5b-9 distinguishes passive Heymann nephritis in the rat. *Kidney Int* 1989;35:60-68
29. JOHNSON RJ, IIDA H, ALPERS CE, MAJESKY MW, SCHWARTZ SM, PRITZL P, GORDON K, GOWN AM: Expression of smooth muscle cell phenotype by rat mesangial cells in immune complex nephritis. *J Clin Invest* 87:847-858, 1991
30. JOHNSON RJ, YAMABE H, CHEN YP, CAMPBELL C, GORDON K, BAKER P, LOVETT DH, COUSER WG: Glomerular epithelial cells secrete a glomerular basement membrane-degrading metalloproteinase. *J Am Soc Nephrol* (in press)
31. HOLTHÖFER H, SAINIO K, MIETTINEN A: Glomerular cells do not express podocytic markers when cultured in vitro. *Lab Invest* 65:548-557, 1991
32. HARPER PA, ROBINSON JM, HOOVER RL, WRIGHT TC, KARNOVSKY MJ: Improved methods for culturing rat glomerular cells. *Kidney Int* 26:875-880, 1984
33. MAYER MM, OSLER AG, BIER OG, HEIDELBERGER M: The activating effect of magnesium and other cations on the hemolytic function of complement. *J Exp Med* 84:535-540, 1946
34. CAMUSSI G, BRENTJENS JR, NOBLE B, KERJASCHKI D, MALAVASI F, ROHOLT OA, FARQUHAR MG, ANDRES G: Antibody-induced redistribution of Heymann antigen on the surface of cultured glomerular visceral epithelial cells: Possible role in the pathogenesis of Heymann glomerulonephritis. *J Immunol* 135:2409-2416, 1985
35. CAMUSSI G, NOBLE B, VAN LIEW J, BRENTJENS JR, ANDRES G: Pathogenesis of passive Heymann nephritis glomerulonephritis: Chlorpromazine inhibits antibody-mediated redistribution of cell surface antigens and prevents development of the disease. *J Immunol* 136:2127-35, 1986
36. CYBULSKY AV, QUIGG RJ, BADALMENTI J, SALANT DJ: Anti-Fx1A induces association of Heymann nephritis antigens with microfilaments of cultured glomerular visceral epithelial cells. *Am J Pathol* 129:373-84, 1987
37. LEYVA A, KELLEY WN: Measurement of DNA in cultured human cells. *Anal Biochem* 62:173-179, 1974
38. FLOEGE J, BURNS MW, ALPERS CE, YOSHIMURA A, PRITZL P, GORDON K, SEIFERT RA, BOWEN-POPE DF, COUSER WG,

- JOHNSON RJ: Glomerular cell proliferation and PDGF expression precede glomerulosclerosis in the remnant kidney model. *Kidney Int* 41:297-309, 1992
39. IIDA H, SEIFERT R, ALPERS CE, GRONWALD RGK, PHILLIPS PE, PRITZL P, GORDON K, GOWN AM, ROSS R, BOWEN-POPE DF, JOHNSON RJ: Platelet-derived growth factor (PDGF) and PDGF receptor are induced in mesangial proliferative nephritis in the rat. *Proc Natl Acad Sci USA* 88:6560-6564, 1991
 40. SASAKI M, YAMADA Y: The laminin B2 chain has a multidomain structure homologous to the B1 chain. *J Biol Chem* 262:17111-17117, 1987
 41. CHU M, MEYERS J, BERNARD M, DING J, RAMIREZ F: Cloning and characterization of five overlapping cDNAs specific for the human pro α 1(I)collagen chain. *Nucl Acids Res* 10:5925-5934, 1982
 42. KURKINEN M, CONDON M, BLUMBERG B, BARLOW D, QUINONES S, SAUS J, PIHLAJANIEMI T: Extensive homology between the carboxyl-terminal peptides of mouse α 1(IV) and α 2(IV) collagen. *J Biol Chem* 262:8496-8499, 1987
 43. IRUELA-ARISPE ML, DIGLIO CA, SAGE EH: Proteins synthesized by endothelial cells undergoing angiogenesis in vitro. *Atherosclerosis Thrombosis* 11:805-815, 1991
 44. WALLENSTEIN S, ZUCKER CL, FLEISS JL: Some statistical methods useful in circulation research. *Circ Res* 47:1-9, 1980
 45. FLOEGE J, JOHNSON RJ, GORDON K, IIDA H, PRITZL P, YOSHIMURA A, CAMPBELL C, ALPERS CE, COUSER WG: Increased synthesis of extracellular matrix in mesangial proliferative nephritis. *Kidney Int* 40:477-488, 1991
 46. ISHIMURA E, STERZEL RB, BUDDE K, KASHGARIAN M: Formation of extracellular matrix by cultured rat mesangial cells. *Am J Pathol* 134:843-855, 1989
 47. KILLEN PD, MELCION C, BONADIO JF, MOREL-MAROGER L, STRIKER GE: Glomerular response to immunologic injury. Studies on progression. *Springer Semin Immunopathol* 5:297-320, 1982
 48. SCHEINMAN JI, FISH AJ, MICHAEL AF: The immunohistopathology of glomerular antigens. The glomerular basement membrane, collagen, and actomyosin antigens in normal and diseased kidneys. *J Clin Invest* 54:1144-1154, 1974
 49. HARA M, MASE D, INABA S, HIGUCHI A, TANIZAWA T, YAMANAKA N, SUGISAKI Y, SADO Y, OKADA T: Immunohistochemical localization of glomerular basement membrane antigens in various renal diseases. *Virchows Arch* 408:403-419, 1986
 50. KOIDE H, HORIKOSHI S: Distribution of monoclonal antibodies against laminin in human glomerulonephritis, in *Basement Membranes*, edited by SHIBATA S, Dordrecht, Elsevier Science Publishers B.V., 1985, pp. 239-247
 51. TORBOHM I, SCHÖNERMARK M, WINGEN AM, BERGER B, ROTHER K, HÄNSCH GM: C5b-8 and C5b-9 modulate the collagen release of human glomerular epithelial cells. *Kidney Int* 37:1098-1104, 1990
 52. FOIDART JM, FOIDART JB, MAHIEU PR: Synthesis of collagen and fibronectin by glomerular cells in culture. *Renal Physiol* (Basel) 3:183-192, 1980
 53. FLOEGE J, ALPERS CE, BURNS MW, PRITZL P, GORDON K, COUSER WG, JOHNSON RJ: Glomerular cells, extracellular matrix accumulation, and the development of glomerulosclerosis in the remnant kidney model. *Lab Invest* (in press)
 54. SALANT DJ, FOGEL MA, NATORI Y, MINTO AW, O'MEARA YM: Expression of type I collagen mRNA in glomeruli of rats with passive Heymann nephritis. (abstract) *J Am Soc Nephrol* 1:554, 1990
 55. YOSHIOKA K, TAKEMURA T, TOHDA M, AKANO N, MIYAMOTO H, OOSHIMA A, MAKI S: Glomerular localization of type III collagen in human kidney disease. *Kidney Int* 35:1203-1211, 1989
 56. ABRASS CK, PETERSON CV, RAUGI GJ: Phenotypic expression of collagen types in mesangial matrix of diabetic and nondiabetic rats. *Diabetes* 37:1695-1702, 1988
 57. ADLER S, STRIKER LJ, STRIKER GE, PERKINSON DT, HIBBERT J, COUSER WG: Studies of progressive glomerular sclerosis in the rat. *Am J Pathol* 123:553-562, 1986
 58. SAGE H, PRITZL P, BORNSTEIN P: Secretory phenotypes of endothelial cells in culture: Comparison of aortic, venous, capillary, and corneal endothelium. *Arteriosclerosis* 1:427-442, 1981
 59. MARTINEZ-HERNANDEZ A, AMENTA PS: The basement membrane in pathology. *Lab Invest* 48:656-677, 1983
 60. TIMPL R: Recent advances in the biochemistry of glomerular basement membrane. *Kidney Int* 30:293-298, 1986
 61. KATZ A, FISH AJ, KLEPPEL MM, HAGEN SG, MICHAEL AF, BUTKOWSKI RJ: Renal entactin (nidogen): Isolation, characterization and tissue distribution. *Kidney Int* 40:643-652, 1991
 62. THOMAS GJ, JENNER L, MASON RM, DAVIES M: Human glomerular epithelial cell proteoglycans. *Arch Biochem Biophys* 278:11-20, 1990
 63. NAKAMURA T, EBIHARA I, SHIRATO I, TOMINO Y, KOIDE H: Modulation of basement membrane component gene expression in glomeruli of aminonucleoside nephrosis. *Lab Invest* 64:640-647, 1991
 64. MYNDERSE LA, HASSEL JR, KLEINMAN HK, MARTIN GR, MARTINEZ-HERNANDEZ A: Loss of heparan sulfate proteoglycan from glomerular basement membrane of nephrotic rats. *Lab Invest* 48:292-302, 1983
 65. BAKER PJ, OCHI RF, SCHULZE M, JOHNSON RJ, CAMPBELL C, COUSER WG: Depletion of C6 prevents development of proteinuria in experimental membranous nephropathy in rats. *Am J Pathol* 135:185-194, 1989
 66. CYBULSKY AV, QUIGG RJ, SALANT DJ: The membrane attack complex in complement mediated glomerular epithelial cell injury: Formation and stability of C5b-9 and C5b-7 in rat membranous nephropathy. *J Immunol* 137:1511-1516, 1986
 67. SAVIN VJ, JOHNSON RJ, COUSER WG: Antibody induced complement activation increases albumin permeability of isolated rat glomeruli. (abstract) *Kidney Int* 37:430, 1990
 68. NEALE TJ, WILSON CB: Glomerular antigens in Heymann nephritis: Reactivity of eluted and circulating antibody. *J Immunol* 128:323-330, 1982
 69. MADAIO MP, SALANT DJ, COHEN AJ, ADLER S, COUSER WG: Comparative study of in situ immune deposit formation in active and passive Heymann nephritis. *Kidney Int* 23:498-505, 1983
 70. FOGEL MA, BOYD CD, LEARDKAMOLKARN V, ABRAHAMSON DR, MINTO AWM, SALANT DJ: Glomerular basement membrane expansion in passive Heymann nephritis. *Am J Pathol* 138:465-475, 1991
 71. LOVETT DH, HAENSCH GM, GOPPELT M, RESCH K, GEMSA D: Activation of glomerular mesangial cells by the terminal membrane attack complex of complement. *J Immunol* 138:2473-2480, 1987
 72. HAENSCH GM, BETZ M, GÜNTHER J, ROTHER K, STERZEL RB: The complement membrane attack complex stimulates the prostanoic production of cultured glomerular epithelial cells. *Int Arch Allergy Appl Immunol* 85:87-93, 1988
 73. ADLER S, BAKER PJ, JOHNSON RJ, OCHI RF, PRITZL P, COUSER WG: Complement membrane attack complex stimulates production of reactive oxygen metabolites by cultured rat mesangial cells. *J Clin Invest* 77:762-770, 1986
 74. WATANABE K, KINOSHITA S, NAKAGAWA H: Gelatinase secretion by glomerular epithelial cells. *Nephron* 56:405-409, 1990