

# UC San Diego

## UC San Diego Previously Published Works

### Title

Invasive pulmonary aspergillosis complicating COVID-19 in the ICU - A case report

### Permalink

<https://escholarship.org/uc/item/0m49c2zi>

### Authors

Prattes, Juergen  
Valentin, Thomas  
Hoenigl, Martin  
et al.

### Publication Date

2021-03-01

### DOI

10.1016/j.mmcr.2020.05.001

Peer reviewed




Since January 2020 Elsevier has created a COVID-19 resource centre with free information in English and Mandarin on the novel coronavirus COVID-19. The COVID-19 resource centre is hosted on Elsevier Connect, the company's public news and information website.

Elsevier hereby grants permission to make all its COVID-19-related research that is available on the COVID-19 resource centre - including this research content - immediately available in PubMed Central and other publicly funded repositories, such as the WHO COVID database with rights for unrestricted research re-use and analyses in any form or by any means with acknowledgement of the original source. These permissions are granted for free by Elsevier for as long as the COVID-19 resource centre remains active.

# Journal Pre-proof

Invasive pulmonary aspergillosis complicating COVID-19 in the ICU - A case report

Juergen Prattes, Thomas Valentin, Martin Hoenigl, Emina Talacic, Alexander C. Reisinger, Philipp Eller



PII: S2211-7539(20)30030-0

DOI: <https://doi.org/10.1016/j.mmcr.2020.05.001>

Reference: MMCR 435

To appear in: *Medical Mycology Case Reports*

Received Date: 21 April 2020

Revised Date: 1 May 2020

Accepted Date: 3 May 2020

Please cite this article as: J. Prattes, T. Valentin, M. Hoenigl, E. Talacic, A.C. Reisinger, P. Eller, Invasive pulmonary aspergillosis complicating COVID-19 in the ICU - A case report, *Medical Mycology Case Reports* (2020), doi: <https://doi.org/10.1016/j.mmcr.2020.05.001>.

This is a PDF file of an article that has undergone enhancements after acceptance, such as the addition of a cover page and metadata, and formatting for readability, but it is not yet the definitive version of record. This version will undergo additional copyediting, typesetting and review before it is published in its final form, but we are providing this version to give early visibility of the article. Please note that, during the production process, errors may be discovered which could affect the content, and all legal disclaimers that apply to the journal pertain.

© 2020 Published by Elsevier B.V. on behalf of International Society for Human and Animal Mycology.

## **Invasive Pulmonary Aspergillosis Complicating COVID-19 in the ICU - A case report**

Running Title:

Aspergillosis in COVID-19

Juergen Prattes<sup>1\*</sup>, Thomas Valentin<sup>1</sup>, Martin Hoenigl<sup>1,2</sup>, Emina Talakic<sup>3</sup>, Alexander C. Reisinger<sup>4</sup>, Philipp Eller<sup>4</sup>

<sup>1</sup> Department of Internal Medicine, Section of Infectious Diseases and Tropical Medicine, Medical University of Graz, Graz, Austria

<sup>2</sup> Division of Infectious Diseases and Global Public Health, University of California San Diego, San Diego, USA

<sup>3</sup> Department of Radiology, Division of General Radiology, Medical University of Graz, Graz, Austria

<sup>4</sup> Department of Internal Medicine, Intensive Care Unit, Medical University of Graz, Graz, Austria

\*Corresponding author:

Juergen Prattes, M.D., FECMM

Medical University of Graz

Department of Internal Medicine

Section of Infectious Diseases and Tropical Medicine

Auenbruggerplatz 15

8036 – Graz

Austria

E-Mail: juergen.prattes@medunigraz.at

Key words: aspergillosis, COVID-19, ICU

**Abstract**

It is not yet known, if critically ill COVID-19 patients are prone to fungal infections. We report a 69-year-old patient without typical risk factors for invasive pulmonary aspergillosis (IPA), who developed IPA two weeks after onset of symptoms. Our report shows that IPA may occur in critically ill COVID-19 patients.

Journal Pre-proof

## Introduction

*Aspergillus* is an opportunistic fungal pathogen that may cause devastating disease in immunocompromised hosts, including those with hematological malignancies. *Aspergillus* is an airborne pathogen, bringing the lungs in the frontline for defense. Recently, severe viral pulmonary infections have shown to be associated with an increased risk for invasive pulmonary aspergillosis (IPA). Severe influenza in critically ill patients for example, is complicated by IPA in 7-23% of cases and associated with a case fatality rate of more than 50% (1). Similar to influenza, the newly emerged severe acute respiratory syndrome coronavirus 2 (SARS-CoV-2) may cause severe lower respiratory tract infections leading to acute respiratory distress syndrome (ARDS). The proportion of patients with coronavirus disease 2019 (COVID-19) who develop severe disease with ARDS is considerably high (2). Consequently, there is a large number of patients in need for intensive care unit (ICU) admission. It is not yet known, if patients with severe COVID-19 are at similar risk for IPA development as patients with severe influenza.

**Case**

Here we report a 70-year-old male who was diagnosed with COVID-19 in March 2020. Underlying diseases included chronic obstructive pulmonary disease (COPD) GOLD grade 2, obstructive sleep apnea syndrome, insulin-dependent type 2 diabetes with end-organ damage [retinopathy, nephropathy (CKD 3b according to the KDIGO classification at first presentation), polyneuropathy], arterial hypertension, coronary heart disease and obesity (body mass index: 38 kg/m<sup>2</sup>). Past medical history included proximal deep vein thrombosis four months prior to presentation. His medication consisted of a long-acting beta agonist/long-acting muscarinic antagonist combination, inhaled glucocorticoid (400 µg budesonide per day), valsartan, spironolactone, ivabradine, atorvastatin, metformin, liraglutide, insulin glargine and enoxaparin.

The patient presented with productive cough, dyspnea and intermittent fever (>38.5°C) for one week (figure 1). Arterial pO<sub>2</sub> was 67mmHg while breathing ambient air. White blood cell count was within the normal limits and C-reactive protein (CRP) was slightly elevated (33 mg/dl; upper limit of norm 5 mg/dl). D-dimer was within the normal range. Chest X-ray revealed bilateral basal coarse reticular opacities (figure 2a and 2b). Real-time polymerase chain reaction (PCR) from oropharyngeal swab was positive for SARS-CoV-2. However, the patient refused to be hospitalized due to personal reasons and was discharged home with oral doxycycline 200 mg q.d. One week later, the patient returned to the emergency department because of clinical deterioration and hypoxemia (arterial pO<sub>2</sub> 46 mmHg while breathing ambient air). Chest CT-scan was performed and showed multiple bilateral ground-glass opacities with a crazy paving appearance (figure 2c). In addition, a reversed halo sign was described (figure 2d). White blood-cell count was slightly elevated (11.65 x 10<sup>9</sup> per L), neutrophils were elevated (9.7 x 10<sup>9</sup> per L), CRP level was 144 mg/dl, interleukin-6 was 396 pg/ml and ferritin 465 ng/ml. Creatinine levels increased from 1.85 mg/dl (first presentation) to 3.26 mg/dl. Lymphocytes were within the normal range. The patient was admitted to ICU with moderate ARDS (oxygenation index 154) and received meropenem 1 g b.i.d., azithromycin 500mg once q.d., and

hydroxychloroquine 200mg b.i.d. He was intubated and mechanically ventilated. Chest X-ray revealed a progression of the bilateral infiltrates on day 2 after ICU admission concordant with significant pulmonary deterioration (oxygenation index <100). On day 3 of ICU stay (day 14 after onset of symptoms) endotracheal aspiration was obtained. Culture grew *Aspergillus fumigatus* (voriconazole minimal inhibitory concentration 0.125 mg/L), without bacterial growth. *Aspergillus* lateral-flow device (LFD) (3), detecting an *Aspergillus* specific antigen secreted during active growth of *Aspergillus* and not during colonization, was performed from the endotracheal aspirate and revealed a positive result. Due to low sample volume, galactomannan could not be performed from this respiratory specimen. Serum fungal biomarkers (galactomannan and 1,3- $\beta$ -D-glucan) remained negative. Based on progression of pulmonary infiltrates, recovery of *Aspergillus fumigatus* in endotracheal aspirate, positive LFD in endotracheal aspirate and the clinical deterioration the patient was diagnosed with putative invasive pulmonary aspergillosis according to Blot et al. (4) and intravenous voriconazole (6 mg/kg b.i.d followed by 4 mg/kg b.i.d.) was initiated on day 4 of ICU stay. Despite treatment of ICU and addition of voriconazole, the patient deceases 3 days after initiation of antifungal treatment due to multiorgan failure. Autopsy was not performed.



## Discussion

From early reports from Wuhan, we know that patients with COVID-19 may develop complicating fungal infections (5). However, galactomannan testing and other fungal diagnostics for further differentiating these infections are rarely available in the Wuhan region and China in general (6).

Here we report a case of putative invasive aspergillosis in a patient with COVID-19 associated ARDS, with growth of *Aspergillus fumigatus* and a positive *Aspergillus*-Ag test in endotracheal aspirate. The patient presented in this report had a two-week history of symptoms before he was admitted to the ICU. On ICU admission, a CT scan revealed a reversed halo sign that is usually suspicious for the presence of mucormycosis (7) but may also be found in other mold infections, particularly IPA (8). Chest CT scans are a valuable tool for COVID-19 diagnosis and management. Ground-glass opacities with or without consolidations are observed in the majority of COVID-19 cases (9, 10) but a reversed halo may be observed in some patients (9). Similar to patients with severe influenza a halo or reversed halo sign may be indicative for presence of a pulmonary mold infection (11) and should therefore trigger further diagnostic steps to confirm or rule out IPA.

For further diagnostic workup, endotracheal aspiration was performed and yielded growth of *Aspergillus fumigatus*. To further discriminate between colonization and infection we tested the *Aspergillus* specific LFD, a CE-certified point of care assay, specific for *Aspergillus*. This test detects actively growing hyphae during invasive infection and remains negative in case of *Aspergillus* colonization of the airways. The LFD was recently given an BII recommendation for diagnosis of invasive aspergillosis in the ESCMID/ECMM/ERS guidelines (12).

While serum galactomannan generally lacks sensitivity in non-neutropenic patients (13), and also turned out negative in this patient, further studies are needed to evaluate the benefit of serum GM screening in COVID-19 patients where bronchoalveolar lavage fluid sampling for culture and biomarker testing is often avoided due to the risk of aerosol spreading and health care worker infections. This seems to be of special interest as based on the data from a recently published trial,

showing that GM in serum is indeed elevated in the majority of patients with severe influenza (14) on ICU and the fact that a significant amount of IPA cases on ICU are still diagnosed post-mortem only, serum GM screening may be an important tool for early recognition of IPA in critically ill COVID-19 patients.

Diagnosis of IPA in ICU patients without classical risk factors for IPA remains challenging. The well-established criteria of the European Organization for Research and Treatment of Cancer/Mycoses Study Group (EORTC/MSG) (14) are not applicable for many of the ICU patients due to a missing host factor. Thus, new diagnostic criteria for ICU patients were established to overcome these limitations (4). This criteria base on clinical signs and symptoms compatible with IPA, abnormal chest imaging of the lungs and microbiological evidence of presence of *Aspergillus*. This criteria turned out to be superior to the EORCT/MSG criteria in the ICU setting (4). Also the patient reported in this case report would not have been classified as IPA according to the EORTC/MSG criteria from 2008 due to a missing host factor. Recently, in the influenza and aspergillosis trial, GM in serum and bronchoalveolar lavage fluid was added to the ICU criteria as an additional mycological criterium to overcome the limitation of imperfect culture sensitivity for aspergillosis (15).

The patient reported here had no classical risk factors for IPA, but it is well known, that viral infections like influenza or cytomegalovirus infections increase the risk for IPA. The pathogenetic mechanisms rendering patients susceptible for IPA during such viral infections are not completely understood at the moment but probable include viral induced overexpression of anti-inflammatory cytokines, dysregulation of T-helper cell differentiation and impaired cell-mediated immune response (16, 17). It is likely, that during SARS-CoV-2 infections similar impairment are present putting the patients at risk for complicating mold infections as seen in our patient.

Our case report highlights that IPA may occur in in critically ill COVID-19 patients. Screening studies are needed to evaluate the prevalence of IPA in COVID-19 patients admitted to ICU.

**Funding**

There was no funding for this manuscript.

**Conflicts of interest**

All authors declare that they have no conflicts of interest regarding this manuscript.

Journal Pre-proof

## References

1. Schwartz IS, Friedman DZP, Zapernick L, Dingle TC, Lee N, Sligl W, et al. High rates of influenza-associated invasive pulmonary aspergillosis may not be universal: a retrospective cohort study from Alberta, Canada. *Clinical infectious diseases : an official publication of the Infectious Diseases Society of America*. 2020.
2. Wu Z, McGoogan JM. Characteristics of and Important Lessons From the Coronavirus Disease 2019 (COVID-19) Outbreak in China: Summary of a Report of 72314 Cases From the Chinese Center for Disease Control and Prevention. *JAMA : the journal of the American Medical Association*. 2020.
3. Prattes J, Flick H, Pruller F, Koidl C, Raggam RB, Palfner M, et al. Novel tests for diagnosis of invasive aspergillosis in patients with underlying respiratory diseases. *American journal of respiratory and critical care medicine*. 2014;190(8):922-9.
4. Blot SI, Taccone FS, Van den Abeele AM, Bulpa P, Meersseman W, Brusselaers N, et al. A clinical algorithm to diagnose invasive pulmonary aspergillosis in critically ill patients. *American journal of respiratory and critical care medicine*. 2012;186(1):56-64.
5. Chen N, Zhou M, Dong X, Qu J, Gong F, Han Y, et al. Epidemiological and clinical characteristics of 99 cases of 2019 novel coronavirus pneumonia in Wuhan, China: a descriptive study. *Lancet*. 2020;395(10223):507-13.
6. Chindamporn A, Chakrabarti A, Li R, Sun P-L, Tan B-H, Chua M, et al. Survey of laboratory practices for diagnosis of fungal infection in seven Asian countries: An Asia Fungal Working Group (AFWG) initiative. *Medical mycology*. 2018;56(4):416-25.
7. Cornely OA, Alastruey-Izquierdo A, Arenz D, Chen SCA, Dannaoui E, Hochhegger B, et al. Global guideline for the diagnosis and management of mucormycosis: an initiative of the European Confederation of Medical Mycology in cooperation with the Mycoses Study Group Education and Research Consortium. *The Lancet infectious diseases*. 2019;19(12):e405-e21.
8. Godoy MC, Viswanathan C, Marchiori E, Truong MT, Benveniste MF, Rossi S, et al. The reversed halo sign: update and differential diagnosis. *Br J Radiol*. 2012;85(1017):1226-35.
9. Li Y, Xia L. Coronavirus Disease 2019 (COVID-19): Role of Chest CT in Diagnosis and Management. *AJR Am J Roentgenol*. 2020:1-7.
10. Zhou F, Yu T, Du R, Fan G, Liu Y, Liu Z, et al. Clinical course and risk factors for mortality of adult inpatients with COVID-19 in Wuhan, China: a retrospective cohort study. *Lancet*. 2020.
11. Huang L, Zhang N, Huang X, Xiong S, Feng Y, Zhang Y, et al. Invasive pulmonary aspergillosis in patients with influenza infection: A retrospective study and review of the literature. *Clin Respir J*. 2019;13(4):202-11.
12. Ullmann AJ, Aguado JM, Arikan-Akdagli S, Denning DW, Groll AH, Lagrou K, et al. Diagnosis and management of Aspergillus diseases: executive summary of the 2017 ESCMID-ECMM-ERS guideline. *Clinical microbiology and infection : the official publication of the European Society of Clinical Microbiology and Infectious Diseases*. 2018;24 Suppl 1:e1-e38.
13. Jenks JD, Mehta SR, Taplitz R, Aslam S, Reed SL, Hoenigl M. Point-of-care diagnosis of invasive aspergillosis in non-neutropenic patients: Aspergillus Galactomannan Lateral Flow Assay versus Aspergillus-specific Lateral Flow Device test in bronchoalveolar lavage. *Mycoses*. 2019;62(3):230-6.
14. De Pauw B, Walsh TJ, Donnelly JP, Stevens DA, Edwards JE, Calandra T, et al. Revised definitions of invasive fungal disease from the European Organization for Research and

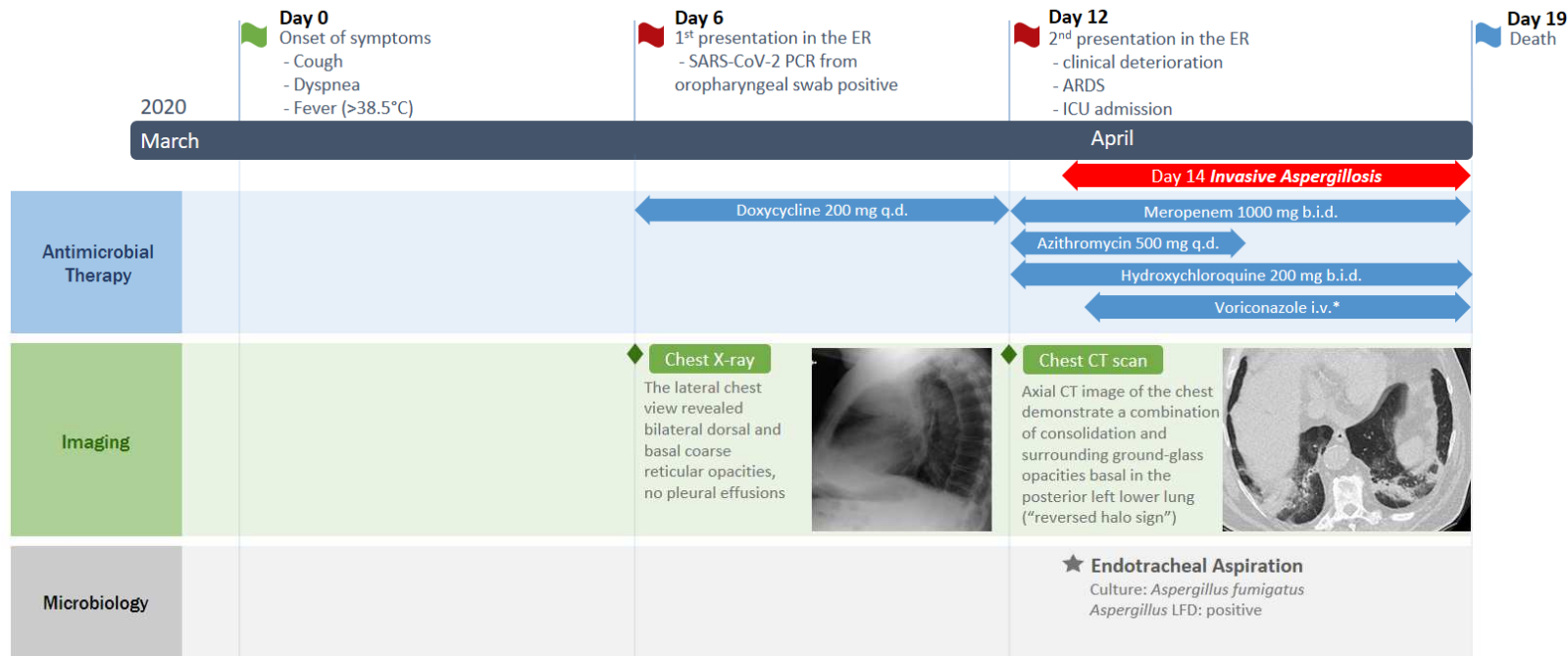
Treatment of Cancer/Invasive Fungal Infections Cooperative Group and the National Institute of Allergy and Infectious Diseases Mycoses Study Group (EORTC/MSG) Consensus Group. *Clinical infectious diseases : an official publication of the Infectious Diseases Society of America*. 2008;46(12):1813-21.

15. Schauwvlieghe A, Rijnders BJA, Philips N, Verwijs R, Vanderbeke L, Van Tienen C, et al. Invasive aspergillosis in patients admitted to the intensive care unit with severe influenza: a retrospective cohort study. *Lancet Respir Med*. 2018;6(10):782-92.

16. McCullers JA. The co-pathogenesis of influenza viruses with bacteria in the lung. *Nat Rev Microbiol*. 2014;12(4):252-62.

17. Cunha C, Goncalves SM, Duarte-Oliveira C, Leite L, Lagrou K, Marques A, et al. IL-10 overexpression predisposes to invasive aspergillosis by suppressing antifungal immunity. *J Allergy Clin Immunol*. 2017;140(3):867-70 e9.

Journal Pre-proof

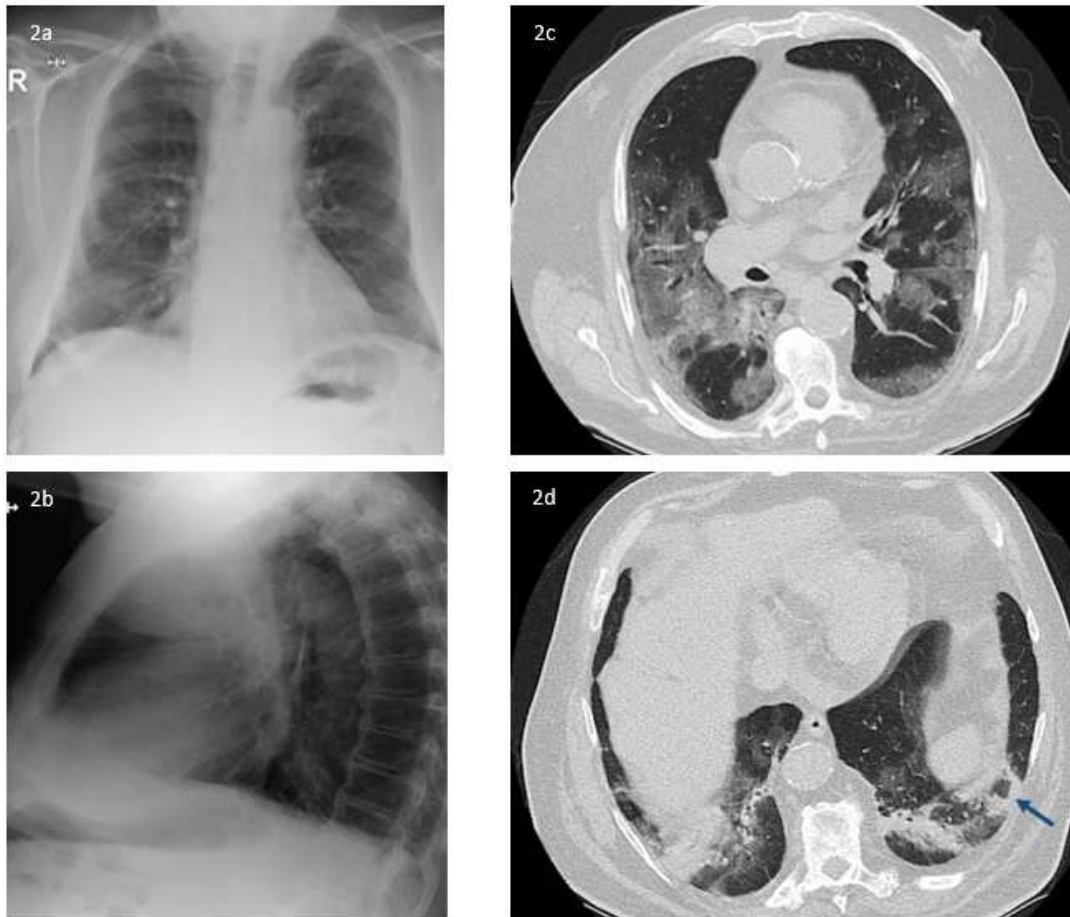**Figure 1** Timeline representing the course of COVID-19 in the reported patient

Abbreviations: q.d. = once daily; b.i.d. = twice daily, i.v. = intravenous; LFD = lateral-flow device; ER = emergency room; ARDS = acute respiratory distress syndrome; ICU = intensive care unit; SARS-CoV-2 = Severe acute respiratory syndrome coronavirus 2, CT = computed tomography

\* Voriconazole dosage: 6 mg/kg twice daily on day 1, followed by 4 mg/kg twice daily

Chest imagings displayed here are also displayed in more detail in Figure 2.

**Figure 2** Figure 2a and 2b representing findings on chest X-ray performed on day 6 of symptom onset. The lateral chest view revealed bilateral dorsal and basal coarse reticular opacities, no pleural effusions. Figure 2c and 2d representing chest CT scans on day 12 of symptom onset. Axial CT image of the chest demonstrate extensive-ground glass opacities with bilateral and multi-lobar distribution (2c) and a combination of consolidation and surrounding ground-glass opacities basal in the posterior left lower lung (“reversed halo sign” - shown by the arrow) (2d)



Highlights:

- 1.) Invasive pulmonary aspergillosis may complicate severe Covid-19
- 2.) Physicians should be aware for aspergillosis in critically ill Covid-19 patients
- 3.) Screening for aspergillosis may be indicated in these patients

Journal Pre-proof



*Journal Pre-proof*  
**Medical Mycology Case Reports**  
**ETHICAL FORM**

Manuscript number (if applicable):

Author name: **Juergen Prattes**

*Medical Mycology Case Reports* requires full disclosure of all sources of funding and potential conflicts of interest. The journal also requires a declaration that the author(s) have obtained written and signed consent to publish the case report from the patient or legal guardian(s).

**If you have nothing to declare in any of these categories then this should be stated.**

**Funding Source**

All sources of funding should be acknowledged and you should declare any extra funding you have received for academic research of this work. If there are none state 'there are none'.

**Please state any sources of funding for your research**

There are none

**Conflict of Interest**

Please declare any financial or personal interests that might be potentially viewed to influence the work presented. Interests could include consultancies, honoraria, patent ownership or other. If there are none state 'there are none'.

**Please state any competing interests**

There are none

**Consent**

Please declare that you have obtained written and signed consent to publish the case report from the patient or legal guardian(s).

**Please state that consent has been obtained from the patient or legal guardian(s)**

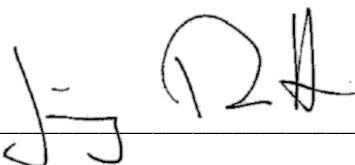
~~Written informed consent was obtained from the patient or legal guardian(s) for publication of this case report and accompanying images. A copy of the written consent is available for review by the Editor-in-Chief of this journal on request.~~

Written informed consent could not be obtained as the patient deceased and we failed to contact legal guardians. The case is reported in a anonymized fashion. No potential identifiable data were used in this case report.

**As corresponding author, I hereby declare that I sign this document on behalf of all the authors of the above mentioned manuscript.**

**Signature** (a scanned signature is acceptable)

**Print name**

  
\_\_\_\_\_

Juergen Prattes  
\_\_\_\_\_