

UCLA

UCLA Previously Published Works

Title

Resolution of metabolic dysfunction-associated steatohepatitis with estradiol in a transgender female: A case report.

Permalink

<https://escholarship.org/uc/item/0jb2z75t>

Authors

Steiger, Athreya

VanderVeen, Nathan

Kang, Esther

et al.

Publication Date

2024-05-01

DOI

10.1002/jpr3.12054

Copyright Information

This work is made available under the terms of a Creative Commons Attribution-NonCommercial-NoDerivatives License, available at

<https://creativecommons.org/licenses/by-nc-nd/4.0/>

Peer reviewed

CASE REPORT

Hepatology

Resolution of metabolic dysfunction-associated steatohepatitis with estradiol in a transgender female: A case report

Athreya Steiger¹  | Nathan T. VanderVeen^{1,2}  | Esther H. Kang^{1,2} | Amy K. Weimer^{1,2}

¹David Geffen School of Medicine at UCLA, Los Angeles, California, USA

²Department of Internal Medicine, Division of Internal Medicine & Pediatrics, UCLA Health, Los Angeles, California, USA

Correspondence

Nathan T. VanderVeen, Department of Internal Medicine, Division of Internal Medicine & Pediatrics, UCLA Health, 757 Westwood Plaza Suite 7236, Los Angeles, CA 90095-7417, USA.

Email: nathan.vanderveen@gmail.com

Funding information

None

Abstract

A 16-year-old trans female patient presented to our Gender Health Program for gender-affirming care. Her intake evaluation revealed signs of hepatocellular injury and fibrosis concerning for metabolic dysfunction-associated steatohepatitis (MASH) and she was referred to a Pediatric Hepatologist. Subsequent delays in initiating hormone therapy caused a decline in her mental health, and she began experiencing suicidal ideations. Gender-affirming hormone therapy has been shown to significantly reduce depressive symptoms and suicidal ideations in transgender and gender diverse youth, and studies in animal models suggest improvement in hepatic steatosis in response to estrogen. A multidisciplinary meeting with Gender Health, Psychiatry, and Hepatology appropriately weighed the benefits of life-saving hormone therapy and the possibility of an improvement in her comorbid liver condition with the risk of further liver damage from estrogen therapy. The teams and the patient agreed to start estradiol with subsequent resolution of laboratory and radiographic evidence of MASH.

KEYWORDS

gender-affirming hormone therapy (GAHT), metabolic dysfunction-associated steatotic liver disease (MASLD), nonalcoholic fatty liver disease (NAFLD), nonalcoholic steatohepatitis (NASH), transgender and gender-diverse youth (TGD)

1 | INTRODUCTION

Metabolic dysfunction-associated steatotic liver disease (MASLD; formerly nonalcoholic fatty liver disease or NAFLD) encompasses a spectrum of conditions characterized by fat accumulation in the liver with an incidence of 7.6%–9.6% among young people. The global prevalence of MASLD in youth has increased drastically—from 19 million children in 1990 to 29 million in 2017.¹ This is especially alarming considering the paucity of FDA-approved therapeutic interventions for MASLD at this time. Metabolic dysfunction-associated steatohepatitis (MASH; formerly nonalcoholic steatohepatitis or NASH),

fibrosis, and cirrhosis represent the most devastating complications of MASLD and are predicted to be the leading cause of liver transplantation in the United States in the next decade.² Although no data on the incidence of MASLD in transgender and gender-diverse (TGD) youth exists, one multicenter analysis reported TGD youth experience metabolic syndrome at higher rates (odds ratio: 1.9) than non-TGD peers,³ and thus it is likely that rates of MASLD are also higher in TGD youth.

Standard of care gender-affirming treatment in pediatric patients can include pubertal suppression and gender-affirming hormone therapy (GAHT).⁴ Pubertal suppression is typically achieved

This is an open access article under the terms of the [Creative Commons Attribution-NonCommercial-NoDerivs](https://creativecommons.org/licenses/by-nc-nd/4.0/) License, which permits use and distribution in any medium, provided the original work is properly cited, the use is non-commercial and no modifications or adaptations are made.

© 2024 The Authors. *JPGN Reports* published by Wiley Periodicals LLC on behalf of The European Society for Pediatric Gastroenterology, Hepatology, and Nutrition and the North American Society for Pediatric Gastroenterology, Hepatology, and Nutrition.

using continuous GnRH agonism to suppress the hypothalamic–pituitary–gonadal axis and decrease sex hormones to prepubertal levels. These “puberty blockers” are safe and reversible therapies that prevent the development of discordant secondary sex characteristics and may be initiated during Tanner stage 2 through 4 of development. GAHT involves testosterone or estradiol to promote physical changes that align with the patient's gender identity.

For TGD youth, there are no data on the safety of estrogen-based GAHT (GAHT-E) in existing liver disease. Concerned about the risk of estrogen-based therapies exacerbating a patient's cirrhosis or causing cholestatic disease, providers may hesitate to prescribe GAHT-E in TGD patients with liver abnormalities. Reassuringly, one longitudinal study of transgender patients on GAHT-E showed no difference in pre- and post-estrogen liver enzyme (AST/ALT) levels in patients without known liver disease,⁵ and in postmenopausal patients with type 2 diabetes mellitus, estrogen therapy actually reduced liver enzyme levels in the blood.⁶ Evidence in cisgender men demonstrates that increased estrogen levels protect against MASLD.⁷ Moreover, a review of multiple studies in rodents indicates that estradiol reverses hepatic steatosis through multiple mechanisms, including by increasing fat breakdown through beta-oxidation, increasing very low-density lipoprotein synthesis with stimulation of reverse cholesterol transport from the liver, and decreasing de novo lipogenesis through the estrogen receptor alpha signaling.⁸ In vivo rat models of estrogen-deficient animals following bilateral oophorectomy show that estrogen therapy reduces liver steatosis and diet-related weight gain while increasing insulin sensitivity in estrogen-deficient rats.⁸

Depression is common in TGD youth, and one retrospective study reports prior suicidal ideation in 56% of TGD youth compared to 20% of non-TGD youth.⁴ Importantly, GAHT is associated with a decrease in depressive symptoms (adjusted odds ratio [aOR] = 0.73) and suicidal ideation (aOR = 0.74) compared to TGD youth who desired but were unable to receive GAHT.⁹

We present a case of a transgender girl with MASH who experienced significant depression with suicidal ideations due to delayed access to GAHT-E.

2 | CASE REPORT

A 16-year-old adolescent assigned male at birth presented to our gender health program for gender incongruence. The patient identified as a girl early in childhood and began her social transition at age 13. Medical history included class I obesity and anxiety/depression managed with aripiprazole. At presentation, she expressed interest in initiating GAHT-E.

On physical examination, body mass index (BMI) was over the 99th percentile for her age (BMI: 31). She declined a genital examination due to dysphoria and was instructed to use an orchidometer with self-reported testicular size consistent with Tanner stage 3.

Laboratory studies revealed a hepatocellular pattern of liver injury (Table 1; R-factor 31). Thus, our team deferred GAHT-E, began pubertal suppression therapy with leuprolide injections, and substituted aripiprazole with sertraline given concern for hepatotoxicity. The patient was not taking any other medications or supplements with a known risk of hepatotoxicity.

Per consultation with hepatology, transient elastography revealed moderate-to-severe hepatic fibrosis with MetaVir stages F2–F3 and a liver stiffness score of 10.9 kilopascals (kPA). Liver biopsy demonstrated steatosis involving >85% of the liver parenchyma with minimal portal and scattered lobular inflammation consistent with MASH (Figure 1). No cholestasis, bile duct injury, or eosinophilia concerning for drug-induced liver injury was noted. Expressing concern for eliciting drug-induced liver injury, our hepatology colleagues advised against GAHT-E initiation and instead recommended weight loss.

Unfortunately, delaying GAHT-E significantly worsened the patient's comorbid mood disorders. She found it challenging to engage in lifestyle modifications and began experiencing new suicidal ideations. Her weight, hemoglobin A1c, and liver enzymes subsequently increased (Figure 2).

Given the patient's clinical decompensation, an interdisciplinary meeting was held involving the Gender Health, Psychiatry, and Hepatology teams. A comprehensive literature review yielded no data on the safety of GAHT-E in TGD patients with MASLD; the team thus reviewed literature in other human and rodent populations, as summarized in the introduction above, which suggest estrogen may reduce the severity of MASLD.⁷

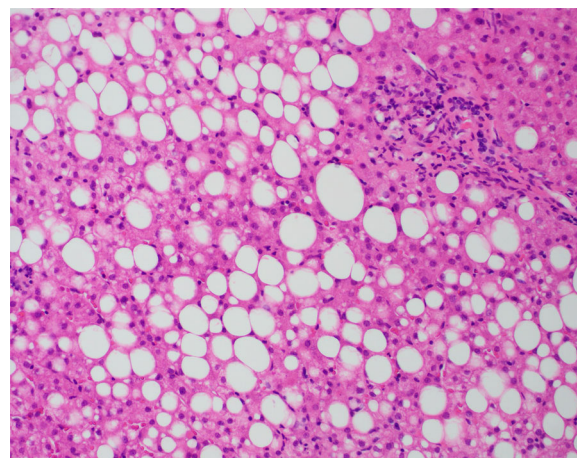
The team weighed the uncertain risk of GAHT-E in MASLD against the patient's worsening mental health and suicide risk, and together with the patient and her mother it was decided to initiate GAHT-E using transdermal estradiol to bypass hepatic first-pass metabolism.^{8,9} Upon initiation of GAHT-E, her liver enzymes began to improve. However, patch adhesion became an increasing challenge and resulted in subtherapeutic estradiol levels. This period was also marked by a 14-lb weight gain due to dietary indiscretion, resulting in a transient increase in her AST/ALT (Figure 2). The patient was switched to estradiol cypionate weekly subcutaneous injections, as parenteral estradiol also limits hepatic first-pass metabolism.⁹ Metformin was also initiated for increasing weight and hemoglobin A1c. The patient subsequently maintained a consistent diet and exercise regimen, and her weight stabilized.

TABLE 1 Laboratory studies for the patient upon initial evaluation for liver disease.

		Normal range ^a
Liver enzymes	AST: 121 U/L	<33 U/L
	ALT: 303 U/L	<19 U/L
	ALKP: 171 U/L	82–331 U/L
Infectious studies	Hep A IgM: nonreactive	Nonreactive
	Hep A total Ab: nonreactive	Nonreactive
	HBsAb: 12 IU/L	>10 IU/L
	HBsAg: nonreactive	Nonreactive
	HCV Ab: nonreactive	Nonreactive
	EBV: negative	Negative
Autoimmune studies	ANA: <1:40	<1:40
	ASMA: 1:80	<1:20
	Celiac panel: negative	Negative
	IgG: 1230 mg/dL	650–1500 mg/dL
	IgA: 238 mg/dL	60–310 mg/dL
	LKM: <1:20	<1:20
Other studies	Vitamin D,25-Hydroxy: 25 ng/mL	20–50 ng/mL
	Total Protein: 8.5 g/dL	6.3–7.8 g/dL
	Albumin: 5.3 g/dL	3.9–5.0 g/dL
	Total Bilirubin: 0.3 mg/dL	<0.8 mg/dL
	Direct Bilirubin: <0.2 mg/dL	≤0.3 mg/dL
	INR: 0.9	
	HbA1c: 5.6%	<5.7%
	Amylase: 48 U/L	31–124 U/L
	Ceruloplasmin: 27 mg/dL	17–48 mg/dL
	Ferritin: 216 ng/mL	8–350 ng/mL
	Alpha-1 antitrypsin: 141	90–200 mg/dL
	AFP: 2.5 ng/mL	0–6.7 ng/mL
	CK: 124 U/L	63–473 U/L

Abbreviations: AFP, alpha-fetoprotein; ALKP, alkaline phosphatase; ALT, alanine aminotransferase; ANA, antinuclear antibody; ASMA, anti-smooth muscle antibody; AST, aspartate aminotransferase; CK, creatinine kinase; EBV, Epstein Barr virus; HbA1c, hemoglobin A1c; HBsAb, hepatitis B surface antibody; HBsAg, hepatitis B surface antigen; HCV, hepatitis C virus; Hep A, hepatitis A; INR, international normalized ratio; LKM, liver kidney microsomal.

^aNormal ranges as provided in our health system's electronic medical record. Abnormal values in bold.

**FIGURE 1** 200× magnification of a representative section of liver biopsy stained with hematoxylin and eosin (H&E) featuring steatosis involving >85% of the liver parenchyma with minimal portal and scattered lobular inflammation consistent with MASH.

The patient's liver enzymes progressively normalized, her mood improved, and suicidal ideation resolved. Follow-up elastography demonstrated less than 10% hepatic steatosis and a nonfibrotic-to-mildly fibrotic liver staged F0–F1 with a stiffness score of 6.9 kPa.

3 | DISCUSSION

Although data involving estradiol therapy in TGD youth with MASLD is limited, GAHT-E has not been shown to increase AST/ALT levels in healthy patients.⁵ Further, in postmenopausal patients and estrogen-deficient rats, estradiol has been shown to decrease liver enzymes and steatosis.^{6,8} In the case above, initiation of GAHT-E preceded dramatic improvement of our patient's liver enzymes, and after the eventual transition to subcutaneous estradiol with concomitant addition of metformin, this patient exhibited resolution of liver enzyme abnormalities as well as hepatic fibrosis on elastography. And while metformin has shown promise in in vitro models of liver steatosis, a meta-analysis from 2021 concluded that in vivo use of metformin failed to show significant improvement in liver steatosis despite a few encouraging trials.¹⁰ In the case of our patient as demonstrated by Figure 2, significant improvement in this patient's markers for hepatocellular injury began before the addition of metformin, suggesting a possible role for estrogen therapy in TGD youth and adults with comorbid MASLD who are interested in GAHT.

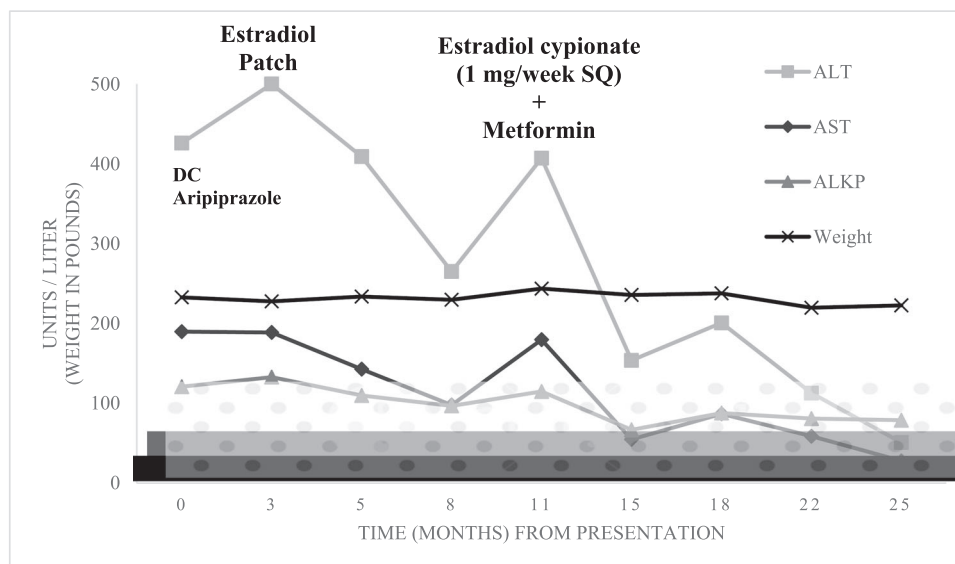


FIGURE 2 This graph shows the patient's liver enzyme and weight trends over time in response to the therapeutic interventions shown. Overlying boxes reflect normal reference ranges for aspartate aminotransferase (AST; solid black box), alanine aminotransferase (ALT; solid gray box), and alkaline phosphatase (ALKP; gray circles) in our electronic medical record for the patient's age. DC, discontinue; Mg, milligrams; SQ, subcutaneous.

GAHT has significant benefits in patients with gender incongruence with comorbid metabolic and psychiatric conditions. Ample evidence demonstrates GAHT-E improves anxiety and depression in TGD patients through gender affirmation.^{4,5,11} Further, GAHT-E may increase a patient's ability to engage in lifestyle modifications essential to manage metabolic dysregulation—another avenue by which GAHT-E may augment treatment of MASLD beyond the metabolic effects of estradiol.

For all patients, a risk-benefit analysis must weigh possible health risks of GAHT-E with the significant risk of mental health decline and suicide in patients unable to access GAHT-E. This case underscores the importance of shared decision-making and interdisciplinary care to consider risks of GAHT-E in the context of a patient's other medical concerns, including their mental health. Through this approach, the patient's goals of care were prioritized while safely and effectively treating her comorbid MASLD.

ACKNOWLEDGMENTS

This patient and her mother generously provided informed consent to share her gender journey with the goal of publication “so that any young person in my position won't have to go through the struggle I went through to validate my gender identity.” This study received no funding.

CONFLICT OF INTEREST STATEMENT

The authors declare no conflict of interest.

ORCID

Athreya Steiger  <https://orcid.org/0009-0009-7572-9887>

Nathan T. VanderVeen  <https://orcid.org/0000-0001-5773-0563>

REFERENCES

1. Le Garf S, Nègre V, Anty R, Gual P. Metabolic fatty liver disease in children: a growing public health problem. *Biomedicines*. 2021;9:1915.
2. Maurice J, Manousou P. Non-alcoholic fatty liver disease. *Clin Med*. 2018;18(3):245-250. doi:10.7861/clinmedicine.18-3-245
3. Valentine A, Davis S, Furniss A, et al. Multicenter analysis of cardiometabolic-related diagnoses in transgender and gender-diverse youth: a PEDSnet study. *J Clin Endocrinol Metab*. 2022;107(10):e4004-e4014. doi:10.1210/clinem/dgac469
4. Rafferty J, Committee on Psychosocial Aspects of Child and Family Health, Committee on Adolescence, Section on Lesbian, Gay, Bisexual, and Transgender Health And Wellness, et al. Ensuring comprehensive care and support for transgender and gender-diverse children and adolescents. *Pediatrics*. 2018;142(4):e20182162. doi:10.1542/peds.2018-2162
5. Hashemi L, Zhang Q, Getahun D, et al. Longitudinal changes in liver enzyme levels among transgender people receiving gender affirming hormone therapy. *J Sex Med*. 2021;18(9):1662-1675. doi:10.1016/j.jsxm.2021.06.011
6. McKenzie J, Fisher BM, Jaap AJ, Stanley A, Paterson K, Sattar N. Effects of HRT on liver enzyme levels in women with type 2 diabetes: a randomized placebo-controlled trial. *Clin Endocrinol*. 2006;65(1):40-44. doi:10.1111/j.1365-2265.2006.02543.x
7. Tian GX, Sun Y, Pang CJ, et al. Oestradiol is a protective factor for non-alcoholic fatty liver disease in healthy men. *Obes Rev*. 2012;13(4):381-387. doi:10.1111/j.1467-789X.2011.00978.x

8. Palmisano BT, Zhu L, Stafford JM. Role of estrogens in the regulation of liver lipid metabolism. *Adv Exp Med Biol.* 2017;1043:227-256. doi:10.1007/978-3-319-70178-3_12
9. Tangpricha V, Den Heijer M. Oestrogen and anti-androgen therapy for transgender women. *Lancet Diabetes Endocrinol.* 2017;5(4):291-300. doi:10.1016/S2213-8587(16)30319-9
10. Pinyopornpanish K, Leerapun A, Pinyopornpanish K, Chattipakorn N. Effects of metformin on hepatic steatosis in adults with nonalcoholic fatty liver disease and diabetes: insights from the cellular to patient levels. *Gut Liver.* 2021;15(6): 827-840. doi:10.5009/gnl20367
11. Green AE, DeChants JP, Price MN, Davis CK. Association of gender-affirming hormone therapy with depression, thoughts of suicide, and attempted suicide among transgender and

nonbinary youth. *J Adolesc Health.* 2022;70(4):643-649. doi:10.1016/j.jadohealth.2021.10.036

How to cite this article: Steiger A, VanderVeen NT, Kang EH, Weimer AK. Resolution of metabolic dysfunction-associated steatohepatitis with estradiol in a transgender female: a case report. *JPGN Rep.* 2024;5:223-227. doi:10.1002/jpr3.12054