

UC Irvine

UC Irvine Previously Published Works

Title

Mapping of neural activity produced by thermal pain in the healthy human spinal cord and brain stem: a functional magnetic resonance imaging study

Permalink

<https://escholarship.org/uc/item/0hz9z618>

Journal

Magnetic Resonance Imaging, 29(3)

ISSN

0730-725X

Authors

Cahill, Catherine M

Stroman, Patrick W

Publication Date

2011-04-01

DOI

10.1016/j.mri.2010.10.007

Copyright Information

This work is made available under the terms of a Creative Commons Attribution License, available at <https://creativecommons.org/licenses/by/4.0/>

Peer reviewed

Mapping of neural activity produced by thermal pain in the healthy human spinal cord and brain stem: a functional magnetic resonance imaging study

Catherine M. Cahill^{a,d,e}, Patrick W. Stroman^{b,c,d,*}

^aDepartment of Pharmacology & Toxicology, Queen's University, Kingston, Ontario, Canada K7L 3N6

^bDepartment of Diagnostic Radiology, Queen's University, Kingston, Ontario, Canada K7L 3N6

^cDepartment of Physics, Queen's University, Kingston, Ontario, Canada K7L 3N6

^dCentre for Neuroscience Studies, Queen's University, Kingston, Ontario, Canada K7L 3N6

^eDepartment of Anesthesiology, Kingston General Hospital, and Queen's University, Kingston, Ontario, Canada K7L 2V7

Received 17 March 2010; revised 7 September 2010; accepted 23 October 2010

Abstract

Functional magnetic resonance imaging (fMRI) has greatly advanced our current understanding of pain, although most studies to date have focused on imaging of cortical structures. In the present study, we have used fMRI at 3 T to investigate the neural activity evoked by thermal sensation and pain (42°C and 46°C) throughout the entire lower neuroaxis from the first synapse in the spinal cord rostral to the thalamus in healthy subjects. The results demonstrate that noxious thermal stimulation (46°C) produces consistent activity within various structures known to be involved in the pain matrix including the dorsal spinal cord, reticular formation, periaqueductal gray and rostral ventral medulla. However, additional areas of activity were evident that are not considered to be part of the pain matrix, including the olivary nucleus. Thermal stimulation (42°C) reported as either not painful or mildly painful produced quantitative, but not qualitative, differences in neuronal activity depending on the order of experiments. Activity was greater in the spinal cord and brain stem in earlier experiments, compared with repeated experiments after the more noxious (46°C) stimulus had been applied. This study provides significant insight into how the lower neuroaxis integrates and responds to pain in humans.

© 2011 Elsevier Inc. All rights reserved.

Keywords: Spinal cord; Brainstem; Human; Pain; Sensation

1. Introduction

Pain is described as an unpleasant sensory or emotional experience associated with actual or potential tissue damage, or described in terms of such damage (International Association for the Study of Pain). It is an evolutionary adaptive mechanism that functions to warn of impending danger in the environment and is a fundamental component of many disease and injury states. In addition to the somatosensory pain experience that provides information of location and intensity of the pain, danger signals incur psychological, emotional and autonomic responses, which

serve to deter dangerous behavior and promote avoidance of harmful stimuli. Hence, pain is a multidimensional and highly subjective experience that is absolutely necessary for survival of the organism. Considering the complex nature of pain, it is not surprising that our understanding of how this complex interplay of sensory, emotional and cognitive processes integrates remains elusive.

The development of neuroimaging techniques, such as functional magnetic resonance imaging (fMRI), has dramatically progressed our understanding of not only the structures important in processing acute and chronic pain but also how the brain is altered by pain (reviewed in [1,2]). Owing to the high spatial resolution provided by fMRI, and by demonstrating only changes in neural activity between contrasted conditions, fMRI has enabled characterization and dissociation of individual components of the pain matrix in humans. Indeed, within the last decade, fMRI studies have provided invaluable insight by demonstrating how pain is a complex,

* Corresponding author. Departments of Diagnostic Radiology and Physics, c/o Centre for Neuroscience Studies, 228 Botterell Hall, Queen's University, Kingston, Ontario, Canada, K7L 2V7. Tel.: +1 613 533 3245; fax: +1 613 533 6840.

E-mail address: stromanp@queensu.ca (P.W. Stroman).

multidimensional phenomenon that influences a wide variety of nervous system functions. We now know that parallel processing systems consisting of sensory–discriminative, affective–emotional, and cognitive–evaluative dimensions integrate to contribute to the subjective experience of pain (for review, see [3]). Various studies have now reported how factors such as empathy, arousal, anxiety, depression, attention and expectation influence pain and neural activity within the central nervous system (CNS) [4,5]. Indeed, a variety of pain modulatory systems exist including contextual and/or cognitive manipulation (for review, see [6]).

In contrast to higher brain structures, less is known about the pain matrix in human midbrain, brain stem and spinal cord. Although excellent histological and anatomical atlases of the human CNS exist detailing nociceptive pathways (which are commonly used for CNS mapping), functional studies are required to understand how CNS neural activity is altered in various disease states, including chronic pain conditions. Recent fMRI studies have identified some brain stem structures (periaqueductal gray [PAG], reticular formation) in both central sensitization produced by capsaicin-induced secondary hyperalgesia [7] and in anticipatory neural response to noxious thermal stimulation [8]. To date, though, relatively few studies have mapped functional activity that extends into the spinal cord. This paucity is most likely, in part, due to considerable challenges of acquiring MR images of the spinal cord, in addition to the usual challenges of obtaining high-quality fMRI data [9]. These challenges include the small physical dimensions of the spinal cord, poor magnetic field homogeneity in the cord due to magnetic susceptibility differences and motion of the spinal cord and cerebral spinal fluid motion. However, such challenges have now been overcome or reduced, with the development of novel techniques by our laboratory and others [9–15].

In the present study, the neuronal activity corresponding to nonnoxious and noxious thermal stimulation of the hand was mapped in caudal brain structures and the spinal cord of healthy subjects spanning from the cervical spinal cord to the thalamus by means of fMRI with a 3T MRI system. The results obtained demonstrated highly sensitive maps of activity, indicating specific regions known to be involved with the “pain matrix” and differences in the responses in these regions with different stimulus intensities, and with the order of experiments. The uniqueness of this study is the ability to correlate regions of activity associated with acute transient pain throughout the entire lower neuroaxis and provides a foundation for comparison and interpretation of future studies aimed at understanding chronic, persistent pain.

2. Methods

2.1. Study participants

Eight healthy individuals (right handed, 2 men and 6 women) aged 26.8 ± 3.4 (mean \pm S.E.M.) years participated in the study. Subjects were fully briefed on the experimental

procedure and underwent comprehensive verbal screening to ensure that they did not meet any of the exclusion criteria for MRI which included any neurological disorders, previous injury to the brain or spinal cord, any peripheral injury that affects the sensitivity of their hands to touch or having any MRI safety risks (e.g., pacemaker, neurostimulator etc.). Written informed consent was obtained from each volunteer prior to participating, and the study was reviewed and approved by the institutional Research Ethics Board.

2.2. Thermal stimulation

Thermal stimuli (42°C and 46°C) were applied to the glabrous skin on the palm of the right hand to evoke neuronal activity in the cervical spinal cord and brain stem, by means of a Medoc TSA-II thermal sensory analyzer. Three experiments were performed, and in each experiment the same stimulus was applied three times, separated by periods at the baseline temperature (32°C). For each experiment, the protocol consisted of the following: (a) thermal stimulation (32°C) applied for 84 s (to obtain the baseline image intensity), (b) ramping the temperature (over 4 s) to either 42°C or 46°C and holding constant for 52 s and (c) returning the temperature to 32°C (2 s ramp) and holding for 140 s. The latter two ramping protocols were repeated twice more for a total of three stimulation periods. This protocol constitutes one thermal stimulation experiment. All subjects received a 42°C thermal stimulation experiment followed by a 46°C experiment and then another experiment at 42°C.

2.3. Pain assessment

Immediately after each experiment, subjects were asked to rate the intensity of the pain they experienced on an 11-point numerical analog scale, where 0=no pain at all and 10=worst possible pain imaginable. This evaluation was used to assess the perceived intensity of pain by the subjects.

2.4. fMRI data acquisition

Each subject attended one scanning session of approximately 90-min duration. Functional MRI studies of the spinal cord were carried out in a 3T Siemens Magnetom Trio using a phased-array spine receiver coil with subjects lying supine. Initial localizer images were acquired in 3 planes as a reference for slice positioning for subsequent fMRI studies. Functional image data were acquired for each study with a half-Fourier single-shot fast spin-echo sequence (HASTE) with an echo time of 38 ms and a repetition time of 1 s per slice to obtain predominantly proton-density-weighted images. Signal intensity changes observed upon a change in neuronal activity were the result of signal enhancement by extravascular water protons (SEEP), as well as a contribution from the BOLD effect, as described previously [14–16]. Sagittal image slices were acquired to span a range that included the C7/T1 disc to the superior edge of the thalamus, with a 20-cm \times 10-cm FOV and a 192 \times 96 matrix, in 14 contiguous sagittal slices, each 2 mm thick. The resulting

voxel size was 1 mm×1 mm×2 mm. Spatial suppression pulses were employed to eliminate signal from anterior to the spine to eliminate motion artifacts from the heart etc., and flow-compensation gradients were applied in the rostral–caudal direction to reduce artifacts from flowing cerebrospinal fluid. The peripheral pulse and respiration were recorded continuously throughout each study using the physiological monitoring equipment that is incorporated into the Siemens MRI system. The acquisition of each image slice was triggered with an external trigger generated by a National Instruments data acquisition board (DAQpad-6020E) controlled by custom software written in MatLab (The MathWorks Inc., Natick, MA, USA). This external trigger signal was recorded synchronously with the physiological traces and provided a time reference for each image acquisition relative to the physiological traces.

At the end of all experiments, a set of images was acquired to demonstrate the anatomical detail, with a T₁-weighted inversion-recovery fast spin-echo sequence (TI = 70 ms, TE = 22, TR = 2 s, 5 lines of image data acquired per excitation, with 1-mm×1-mm×2-mm resolution).

2.5. Image data analysis

The resulting three-dimensional functional image data were analyzed with custom-made software written in MatLab. A reference line was drawn along the anterior edge of the spinal cord in a midline slice. This line was extended along the entire brain stem up to the anterior edge of the thalamus and was used as a guide to spatially smooth the data (three-pixel-wide box-car smoothing kernel) only parallel to the long axis of the cord. Subsequent to the analysis, this reference line was also used to spatially normalize the results as described below. Sagittal-slice data were analyzed as described previously [14,17–19] using a General Linear Model (GLM). The basis functions for the GLM included the peripheral pulse trace sampled at the time of acquisition of each slice to account for confounding effects arising from cardiac motion [18]. Areas of activity were identified visually with the anatomical localizer using specific anatomical landmarks to identify areas of activity including the colliculus, the cerebral aqueduct and the midline. A human stereotaxic atlas was used to help identify location in relation to the anatomical landmarks mentioned above. Smoothing was applied only parallel to the long axis of the cord and brain stem.

The spatial normalization procedure aligns the data with a 3D coordinate system with one dimension parallel to the long axis of the cord and the other two running anterior/posterior and left/right. The procedure consists of interpolating the image data to 1-mm cubic voxels and reslicing the volume into axial sections every 1 mm along a manually defined reference line (mentioned above) along the anterior edge of the spinal cord in a midline sagittal slice. The point where the reference line passes through each resulting axial section is positioned at the center of each axial image, producing an apparently straight spinal cord in sagittal views. Two reference points; the caudal edge of the pons (the

pontomedullary junction) and the intervertebral disc between the C7 and T1 vertebrae, were then used to linearly shift and scale the volume to a normalized coordinate system with axes along the long axis of the cord, right-left and anterior-posterior, relative to the spinal cord anatomy. This method has been shown to align the spinal cord and brain stem anatomy from different people to within 2 mm or less in 93% of the voxels and to have a mean accuracy of 0.3 mm [19]. The span of 140 mm between the two reference points was based on typical dimensions observed in data from a sample of human subjects. A normalized reference volume spanning the brain stem and cervical spinal cord was then constructed. The data from each individual subject were aligned with this reference volume by means of rigid-body left/right and anterior/posterior shifts at each rostral/caudal position, thus fine-tuning the normalization.

The normalization procedure was applied to the results of the GLM analysis and to the time-series data only for the purposes of the partial-least-squares (PLS) analysis described below. Consistent group areas of activity were then determined from the normalized GLM result. The consistent activity across the group was represented by the number of participants that exceeded a significance level (*T*-value) of 2.5 in the individual (first-level) analysis at each voxel, as described previously [9,20]. The group activity expressed in the manner is similar to that produced by a random-effects analysis, but makes more allowance for the fact that not all variation between studies can be considered to be errors, but can reflect true physiological variation because the neural activity in the spinal cord and brain stem can depend on emotional factors such as anticipation, anxiety and attention [17,21]. While we tried to control these variables by providing complete information prior to the study and verbal reassurance between periods of fMRI data acquisition, complete control is not possible.

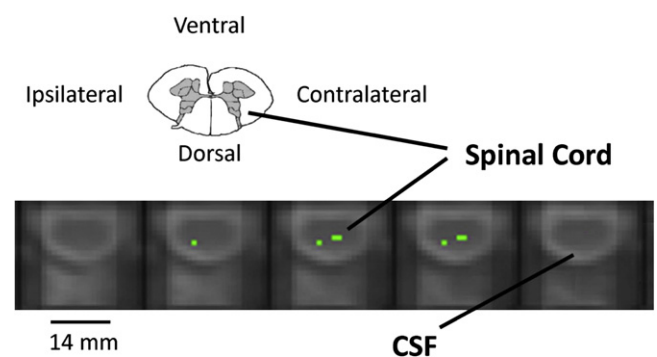


Fig. 1. Combined results of activity observed with the first 42°C stimulus from eight healthy volunteers at the sixth cervical (C6) level of the spinal cord, shown in selected transverse slices. Colors represent the number of participants with activity in each voxel or an immediate neighbor: green-5, yellow-6, orange-7, red-8, as in later figures. Note that all activity observed within the spinal cord appears in areas consistent with gray matter. Sides of the spinal cord ipsilateral and contralateral to the thermal stimulus are indicated (images are in radiological orientation).

2.6. PLS analysis

In addition to the GLM analysis described above, group analyses were also carried out with the coaligned and normalized data by means of the PLS method [21,22]. The PLS analysis demonstrates the significance of the differences in the responses to different stimuli, on a voxel-by-voxel basis. In very brief terms, the data from each experiment were averaged over the 3 stimulation periods to generate a single mean response of length t , equal to 192 s (the duration of one 52-s stimulation period followed by a 140-s baseline period). The responses to the 46°C stimulus were compared to those of the two 42°C stimuli, and the two 42°C stimuli (first and third experiments in each volunteer) were compared, by computing the average difference between the responses. The significance of the voxel saliences was determined with a bootstrap method, in which the original data were resampled by substitution, without changing the order of the experi-

ments for each volunteer. For example, the data for volunteer 2 would be replaced with those from volunteer 1 in one permutation. A total of 164 such permutations were analyzed, and the standard error of the saliences was determined. The ratio of the salience to its standard error is termed the *bootstrap ratio* and provides an estimate of its significance. An absolute bootstrap ratio value of 4, or greater, was selected for this study to indicate significant differences between the contrasted values. This analysis constitutes a single statistical test, and so corrections for multiple comparisons are not required [23].

3. Results

3.1. Psychophysical testing

Following application of the first 42°C stimulus (comprised of three blocks of stimulation in one fMRI

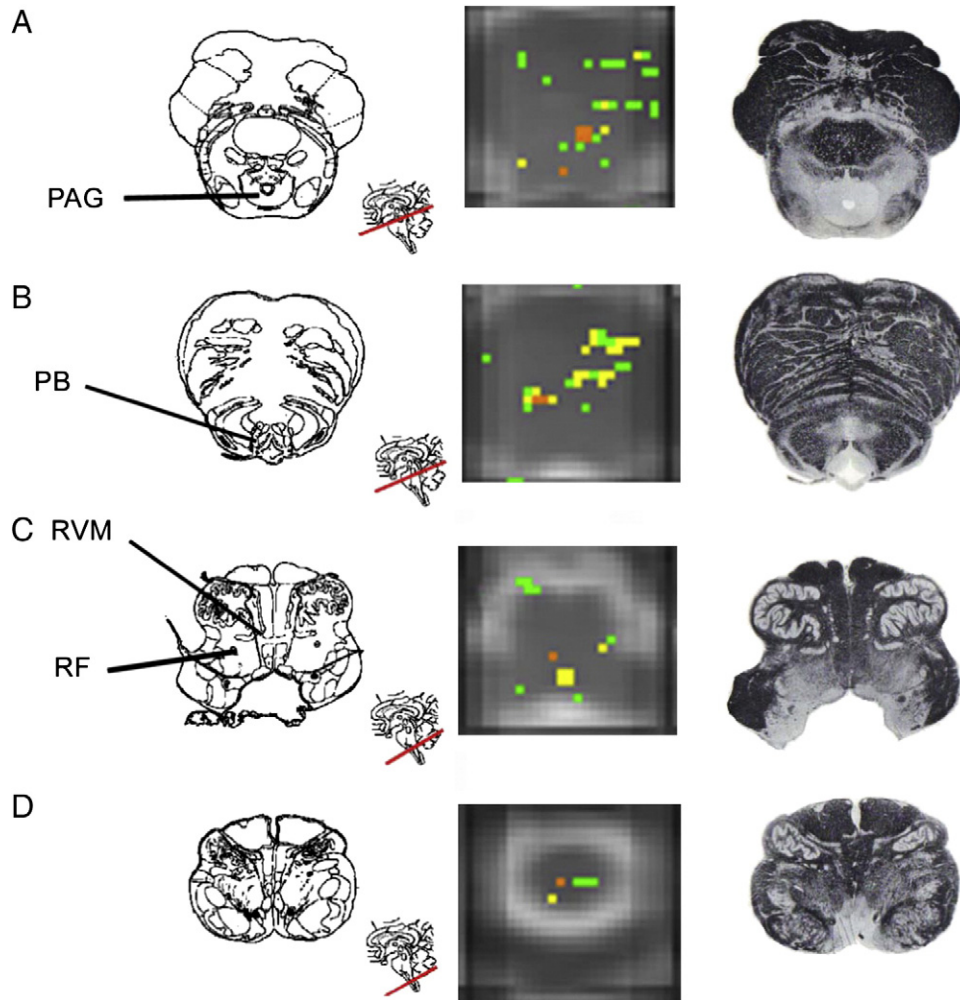


Fig. 2. Combined results of activity observed with the first 42°C stimulus from eight healthy volunteers in selected transverse regions of the brain stem. Colors represent the number of participants with activity in each voxel or an immediate neighbor: green-5, yellow-6, orange-7, red-8. (A) Caudal midbrain, (B) caudal pons, (C) rostral medulla, (D) caudal medulla. Note that neural activity within each brain stem and midbrain region occurs both ipsilateral and contralateral to the thermal stimulus. The left side of the images is ipsilateral to the thermal stimulus (i.e., right side of the body, in radiological orientation). PAG: periaqueductal gray matter, RVM: rostral ventral medulla, RF: reticular formation, PB: parabrachial nucleus.

experiment), subjects were not consistent in their reporting of the sensation in the context of pain intensity. Some subjects described the stimulus as being painful and burning, rating it at 4–5 on a numerical 11-point analog scale, while other subjects reported that the stimulus was not painful (rating of 0). The average rating was 2.3 ± 1.7 (mean \pm S.D.). All subjects reported the 46°C thermal stimulation to be painful, giving it a numerical rating of 5.0 ± 2.0 (range: 3–8). Importantly, all subjects reported

the second 42°C stimulus as less painful than the first one at 42°C , with the second receiving an average rating of 1.3 ± 1.4 . The ratings obtained for all three stimuli are significantly different at $P < 10^{-6}$.

3.2. Imaging results

3.2.1. Experiment 1: first 42°C stimulus

The first application of a thermal stimulus (42°C) to glabrous skin of the right hand resulted in activity in the

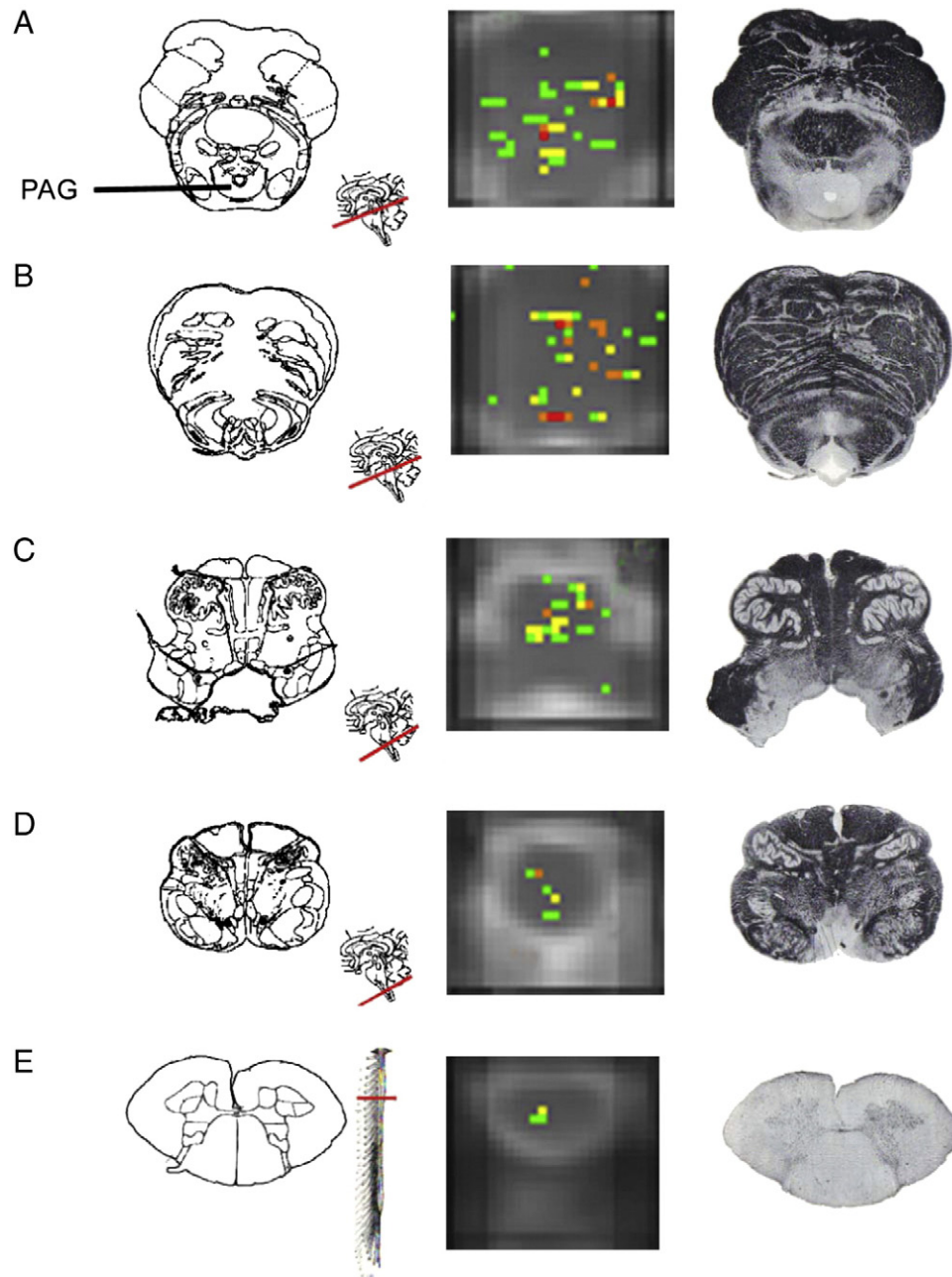


Fig. 3. Combined results of activity observed with the 46°C stimulus from eight healthy volunteers in selected transverse regions of the brain stem and cervical spinal cord. Colors represent the number of participants with activity in each voxel or an immediate neighbor: green-5, yellow-6, orange-7, red-8. (A) Caudal midbrain, (B) caudal pons, (C) rostral medulla, (D) caudal medulla, (E) C6 region of the spinal cord. Note that neural activity within each brain stem and midbrain region occurs both ipsilateral and contralateral to the thermal stimulus. The left side of the images is ipsilateral to the thermal stimulus (i.e., right side of the body, in radiological orientation). PAG: periaqueductal gray matter.

ipsilateral dorsal spinal cord (Fig. 1). The neural activity was well localized around the sixth cervical spinal cord segment (C6) and was present in the same anatomical location, on a voxel-by-voxel basis, in at least five of the eight subjects. Neural activity also appeared in areas consistent with contralateral deep dorsal horn. Specificity of the neural activity within the spinal cord is highlighted by the absence of activity in adjacent regions.

Neural activity was identified throughout the mesencephalon both ipsilateral and contralateral to the stimulus, although activity was significantly greater in the contralateral regions (Fig. 2). This activity extended along the rostral–caudal axis of the medulla, pons, midbrain and thalamus. The regions of activity are consistent with the location of the cuneate nucleus and medial lemniscus pathway (Fig. 2D), reticular formation (Fig. 2C), pyramidal tracts or pontine nuclei (Fig. 2B) and the PAG (Fig. 2A) according to that

described in *Atlas of the Human Brain Second Edition* (Mai, Paxinos and Assheuer, 2004). Finally, neural activity was primarily confined to regions consistent with the location of contralateral thalamic nuclei (data not shown).

3.2.2. Experiment 2: 46°C stimulus

The pattern of neural activity for the experiments involving a 46°C thermal stimulus was similar to the first 42°C experiment with the exception that the higher-temperature stimulus produced greater activity within the neuroaxis. Group analyses by means of the PLS method yielded differential neural activity maps within the spinal cord and brain stem nuclei as shown in Fig. 3. Greater neural activity was present in areas consistent with the location of the ipsilateral dorsal spinal cord gray matter, the contralateral reticular formation in the medulla and pons, the PAG and the medial thalamus. There did not appear to

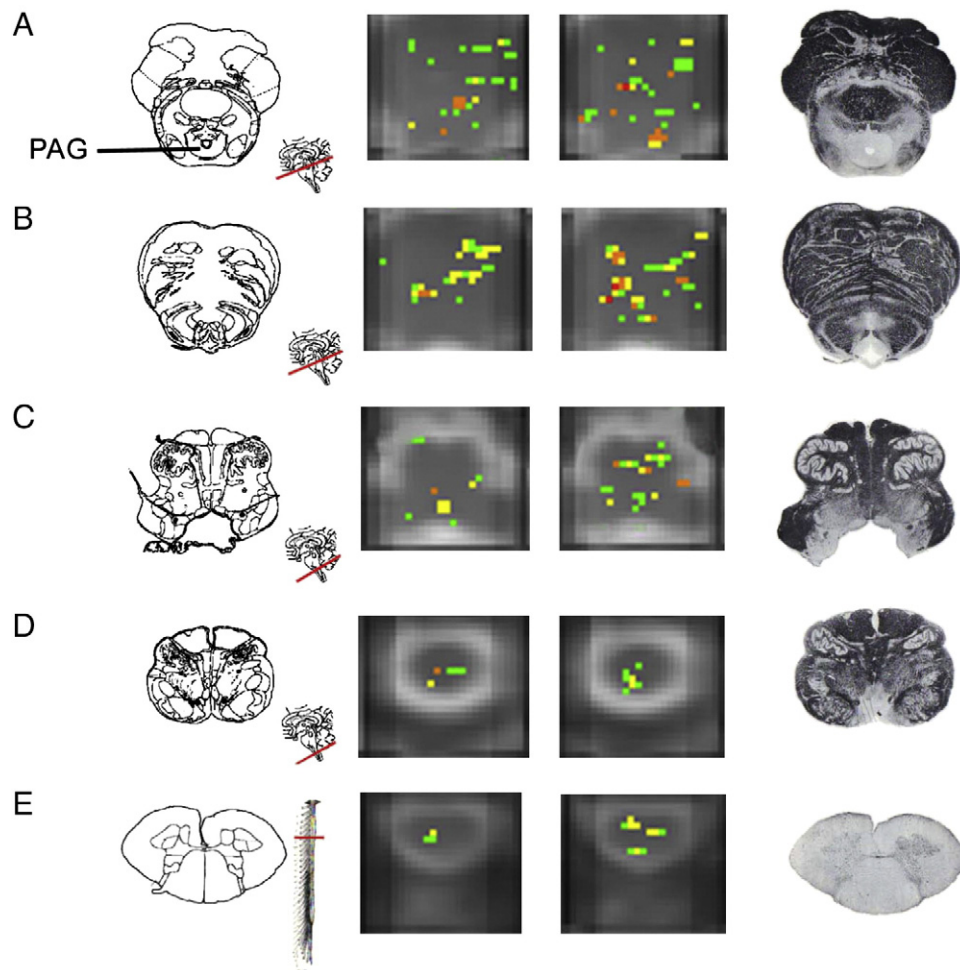
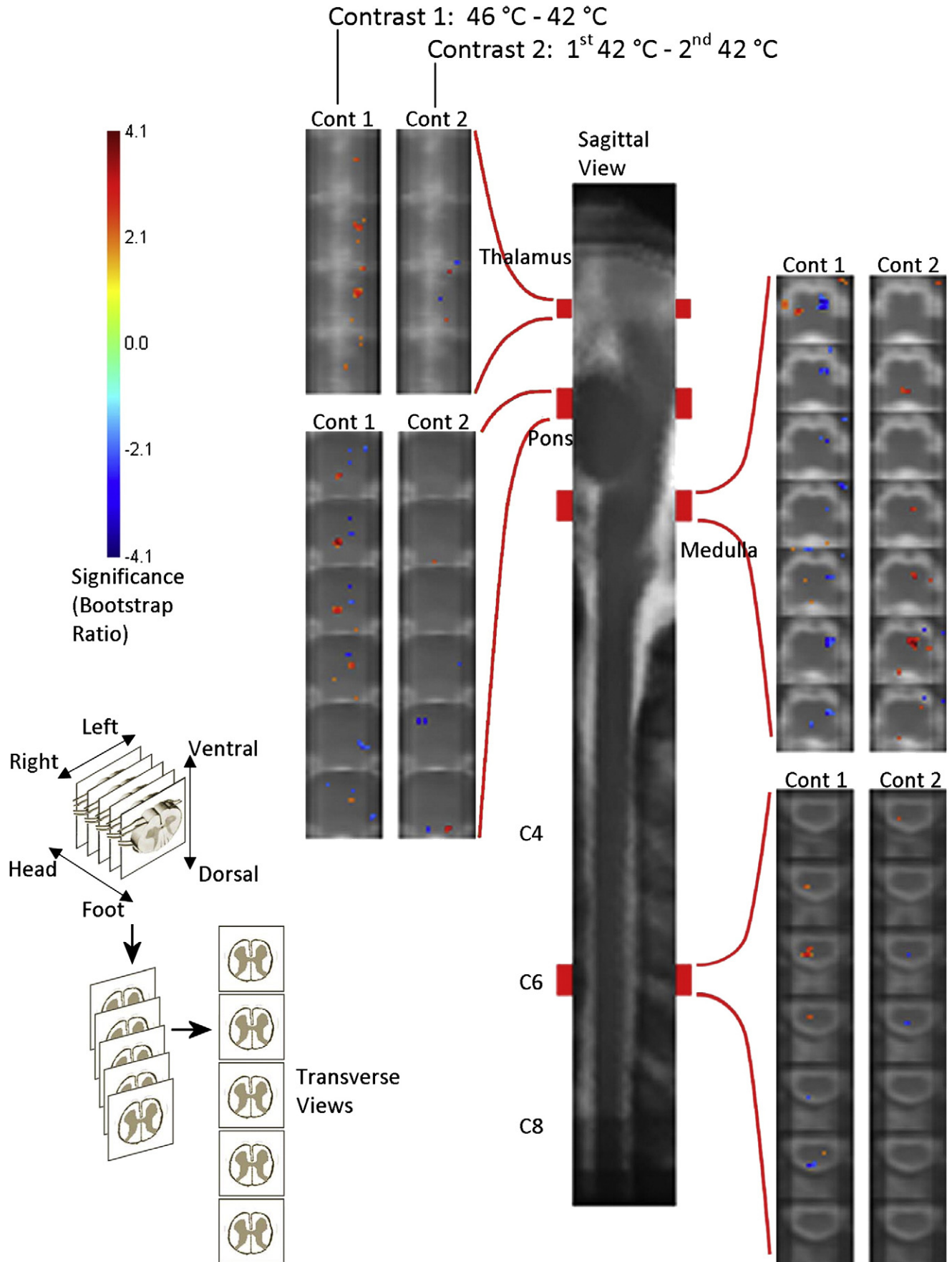


Fig. 4. Side-by-side comparison of the combined results of activity observed with the two experiments with 42°C stimuli from eight healthy volunteers in selected transverse regions of the brain stem and cervical spinal cord. The left column contains results from the first of the two experiments, whereas the right column represents the second experiment with stimulation at 42°C, which in every participant was carried out after the experiment with stimulation at 46°C. Colors represent the number of participants with activity in each voxel or an immediate neighbor: green-5, yellow-6, orange-7, red-8. (A) Caudal midbrain, (B) caudal pons, (C) rostral medulla, (D) caudal medulla, (E) C6 region of the spinal cord. Note that neural activity within each brain stem and midbrain region occurs both ipsilateral and contralateral to the thermal stimulus. The left side of the images is ipsilateral to the thermal stimulus (i.e., right side of the body, in radiological orientation). PAG: periaqueductal gray matter.



be many areas of neural activity uniquely related to the 46°C stimulus as compared to the initial 42°C experiment, although there was activity in regions consistent with the olivary nucleus (Fig. 3C).

3.2.3. Experiment 3: second 42°C stimulus

The areas of activity observed in response to the third experiment, in which we again applied a stimulus of 42°C, were similar, but not identical, to those seen in the first experiment (Fig. 4); rather, there were similarities to both experiments 1 and 2. Contrasting the first and third experiments with identical 42°C stimuli by means of PLS showed greater activity in various regions with the second 42°C stimulus as compared to the first time the same intensity stimulus was applied (Fig. 5), even though pain scores were lower for the second of these two studies. This activity was localized to regions consistent with olivary nucleus, rostral ventral medulla, locus coeruleus and PAG, whereas less activity was noted in the ipsilateral locus coeruleus. Both positive and negative differences were present in the lateral and medial thalamus, as shown in Fig. 5.

3.3. Comparisons of results across experiments

Fig. 5 demonstrates the contrast between the activity detected with stimulation at 46°C and both experiments with stimulation at 42°C. The dominant differences are greater activity in the ipsilateral dorsal horn at C6, the midbrain in the area of the ipsilateral PAG and contralateral medial thalamus, and significantly lower activity in the contralateral olivary nucleus or the rostral ventral medulla. The predominant areas of contrast between the responses to different stimuli are also summarized in Table 1.

Comparisons between subjective pain ratings provided by each volunteer at the time of the study and signal intensity changes in active voxels, averaged across specific regions of the cervical spinal cord and brain stem, are summarized in Table 2. The ratings from each volunteer are plotted against the magnitudes of signal changes in active voxels in Fig. 6. The values are plotted only for selected regions with the highest correlation values.

It is notable that the active voxels in ipsilateral (right) dorsal gray matter, in spinal cord segments C6 to C8, do not appear to be correlated with subjective ratings when the 42°C stimulation was applied. However, with the 46°C stimulus, the signal changes were strongly negatively correlated with the ratings in this region. Activity in the left dorsal gray matter was also strongly negatively correlated with subjective ratings, but only for the second and third experiments, with stimulation at 46°C and 42°C, respectively. Regions of the brain stem in the midbrain, pons

and medulla also contained activity that was correlated with subjective ratings, some positive and some negative, depending on the stimulus temperature, and also on the order of the experiments for the two with the same stimulus temperature at 42°C.

4. Discussion

In the present study, we demonstrate the neuronal activity generated by thermal stimuli throughout the neuroaxis spanning caudally from the lower cervical spinal cord to as far rostrally as the thalamus in healthy volunteers. Results demonstrate that a noxious thermal stimulus at 46°C produces greater neuronal activity than a lower intensity thermal stimulus at 42°C, which is expected to be less noxious, but there were no obvious differences in anatomical locations where neuronal activity was detected. Results also demonstrate that application of identical thermal stimuli (42°C) produced different neuronal activity patterns depending on whether the experiments preceded or succeeded the experiment with 46°C stimulation. Finally, subjective pain ratings were highly correlated with the magnitudes of signal changes in active regions in response to thermal stimuli in both spinal cord and midbrain regions.

There are several ascending pathways that relay pain transmission from the spinal cord to supraspinal sites (see [24]) and a descending bulbospinal pathway through the dorsolateral funiculus that must be considered to correctly interpret the results of this study. Spinal projections responsible for transmission of noxious information originate from dorsal horn laminae and make up two major pathways: spinothalamic and spinobulbar tracts. Descending pain modulation is then provided via the bulbospinal pathway and involves neurons in the midbrain PAG and periventricular gray matter that make excitatory connections to the nucleus raphe magnus and the adjacent nucleus reticularis paragigantocellularis, which are both located in the rostral ventromedial medulla. Descending excitatory input is also provided to the locus coeruleus, among other nuclei. Neurons from these regions, especially the nucleus raphe magnus and adjacent reticular formation, then make inhibitory connections in the dorsal spinal cord. Together, these pathways participate in the emotional, behavioral and autonomic responses to pain.

The present study demonstrates that both mild and moderate types of thermal pain produce activity in the dorsal spinal cord and in regions consistent with the PAG and rostral ventral medulla. While these results confirm known anatomical pathways of acute transient pain transmission, they also demonstrate that we reliably detect

Fig. 5. Contrasted group responses between stimulation at 46°C and 42°C, and between the two experiments with stimulation at 42°C, by means of PLS. The significance (bootstrap ratio) of the differential responses at each voxel is indicated by the colors, corresponding to the color bar on the left. The significant differences are shown for selected regions in 1-mm transverse slices, corresponding to the levels indicated on the spatially normalized sagittal view of the brain stem and cervical spinal cord, shown in the center. The schematic on the lower left demonstrates how the transverse slice views relate to the sagittal view and the anatomy of the brain stem and spinal cord.

Table 1
Contrasted responses in selected regions, determined by means of PLS analysis

PLS	Thal. L	Midbrain R	Midbrain L	Pons R	Pons L	Medulla R	Medulla L	C2–C5 L	C6–C8 RD	C6–C8 LD
46 vs. 42	+++	++ (PAG)	–	0	++ and –	++	–	0	+++ and –	0
1st 42 vs. 2nd 42	+ and –	– (LC)	++ (LC)	–	0	++	+++	–	–	0

Plus (+) and minus (–) signs are used to indicate positive or negative differences, respectively, with larger areas and/or larger differences indicated with more symbols. A single + or – symbol is used to indicate that the area was highly localized.

activity in regions of the brain stem and spinal cord that are relevant to sensory transmission. The interpretation of the results is supported by a previous study of a range of innocuous cold thermal stimuli, and the effects of the order of experiments, implicating emotional and attentional factors [21]. In this latter study, it was observed that activity in locus coeruleus and ventral spinal cord depended on order of experiments, with higher signal changes detected in the earlier of the five sequential studies, between baseline stimulation at 32°C and innocuous cold stimulation. It was also observed that dorsal spinal cord had two types of responses, one being highly localized and another more distributed in the rostral/caudal direction. The localized activity had higher signal changes with colder (more intense) stimuli, but the larger area had the opposite trend.

Contrasting the results of the present study between the two experiments at 42°C, by means of PLS analysis, demonstrated significantly higher signal changes in the left locus coeruleus and the rostral medulla with the first study, and lower signal changes in the right spinal dorsal gray matter. Based on the previous study of innocuous cold stimuli, this implies that the locus coeruleus and rostral medulla received greater input during the first of the two studies at 42°C and consequently provided less input to the dorsal spinal cord. This is consistent with altered emotional responses to the stimulus between the two studies, arising from the order of experiments or the intervening experiment with a more intense (46°C) stimulus.

With stimulation at 46°C, compared to 42°C, activity was greater in regions of the thalamus, locus coeruleus and dorsal spinal cord, again consistent with the trends observed with more intense stimuli in the previous study [21]. In addition, significantly greater activity was detected with 46°C stimulation in the vicinity of the PAG, consistent with greater involvement of the descending analgesia system. These findings are consistent with previous studies of cortical areas involved with the pain response. For example, the entorhinal cortex of the hippocampal formation has been

shown to respond differentially to identical noxious stimuli depending on whether the perceived pain intensity was enhanced by pain-relevant anxiety [25]. Additionally, Villemure and Bushnell [26] recently reported that pain-related activity within the anterior cingulate, medial thalamus and primary and secondary somatosensory cortices was correlated with mood, whereas the effects of attentional state altered activity in anterior insular cortex. The group results from the present study therefore complement these previous studies and demonstrate details of the pain matrix including the ascending pathways, the affective components of the response and the descending modulation of the response in subcortical regions.

The variation of activity across participants in each anatomical region is shown to be a consequence of different perceived sensations, by means of the comparisons of subjective pain ratings to signal intensity responses in active voxels, shown in Fig. 6. This correspondence is important because it demonstrates that a significant component of the variance of the results is attributable to physiological differences between individuals. The results can therefore be considered to be sensitive and reliable indicators of neural function in the brain stem and spinal cord within each individual that was studied. Areas of activity in the midbrain were positively correlated with ratings with lower temperature stimuli, but were negatively correlated with ratings when the thermal stimulus was noxious (46°C). This suggests the possibility of different roles of various midbrain nuclei in response to innocuous and noxious responses; however, it must be recognized that, while the 42°C stimulus is considered innocuous, there were subjects who reported this stimulus to be moderately painful. However, the PLS analysis demonstrated significantly greater signal intensity changes in the PAG specifically with the noxious 46°C stimulus, consistent with this stimulus producing a painful response, compared to the stimulation at 42°C. Interestingly, there was also a negative correlation between neuronal activity in the spinal cord and subjective pain ratings

Table 2
Correlation values, *R*, between subjective ratings and fMRI signal changes in active voxels, averaged over selected regions of the cervical spinal cord and brain stem

	Midbrain R	Midbrain L	Pons R	Medulla R	C2–C5 L	C6–C8 RD	C6–C8 LD
1st 42°C	0.58	0.43	0.24	–0.31	–0.20	–0.02	0.02
46°C	–0.53	0.01	–0.08	–0.53	–0.52	–0.64	–0.57
2nd 42°C	0.46	0.57	0.51	0.53	–0.25	–0.23	–0.60

The regions shown are only those with absolute correlation values exceeding 0.5 in any part of the study.

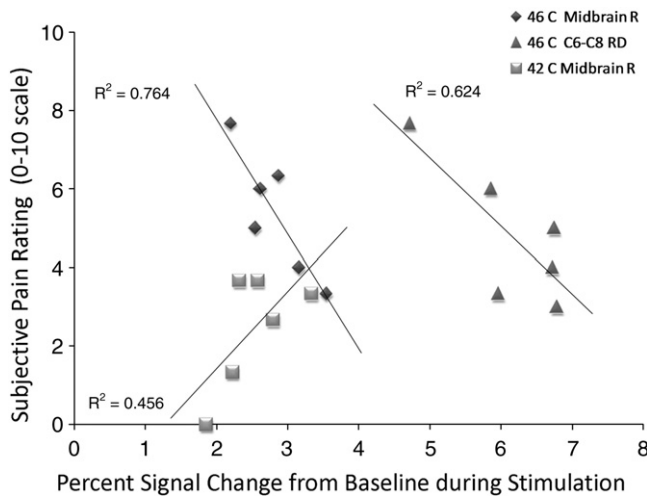


Fig. 6. Plot of the correspondence between subjective ratings provided by each of the eight individuals studied, and the magnitude of the signal changes detected in the cervical spinal cord and the vicinity of the PAG. The diamond shapes and the squares indicate the signal changes detected in the right midbrain (near the PAG) in relation to the ratings reported with stimulation at 46°C and 42°C, respectively. The triangle shapes indicate the signal changes detected in the vicinity of the right dorsal horn of the sixth cervical spinal cord segment (C6) in response to stimulation at 46°C. Signal changes in this C6 region were not observed to be correlated with ratings in response to stimulation at 42°C and so are not shown. The correlation (R^2) values are indicated for a linear regression between the signal changes and subjective ratings in each case.

produced by the 46°C stimulus (Fig. 5). Although this result may seem counterintuitive, it is consistent with the results of our previous study [21]. Given that the activity detected with fMRI is expected to reflect predominantly neural input (whether inhibitory or excitatory) and local processing [14,27], we interpret this as a reduction of the tonic input to the spinal dorsal gray matter with the higher temperature in order to modulate the pain response.

Areas of activity not considered to be part of the pain matrix were also generated by thermal stimuli in the present study. For example, in all experiments, activity was noted in regions consistent with the location of the cuneate nucleus. This area is responsible for conveying the sensation of touch from the upper body (above T6, excepting the face) to the thalamus and cerebellum via the medial lemniscus. In the more rostral medulla, activation was also evident in the vicinity of the left olivary nucleus. The PLS analysis showed that the signal changes detected in this region were significantly greater with the first of the two experiments with stimulation at 42°C and were also consistently greater with stimulation at 42°C than at 46°C. The inferior olivary nucleus is mainly involved in cerebellar motor-learning and function, whereas the superior olivary nucleus is a part of the auditory system, aiding the perception of sound. The sounds generated by the MRI system were constant throughout all fMRI studies and cannot account for this activity during times when the thermal stimuli were applied. Instead, effort by the participants to remain motionless and to not respond

in any way to the warm or hot thermal stimulation on the hand may explain the activity observed in this region, based on the expectation that it is related to motor function. Although the functional correlate of this activity cannot be confirmed with the present results, it is of interest for future studies investigating thermal or pain responses in the brain stem and spinal cord as it may reveal some previously unexpected component of the response.

5. Conclusions

In this study, we demonstrate that two intensities of noxious thermal stimulation induce signal changes in various anatomical areas known to be involved in pain transmission. This activation was reliably reproduced between subjects but could be modulated by anticipation and/or anxiety as illustrated by the differences in signal intensity generated by the two experiments of 42°C stimulation. While multiple studies have demonstrated such phenomenon in higher cortical structures, it is now evident from this study that apprehension and anxiety also affect nociceptive processing in the neuroaxis as low as the spinal cord. This study also provides evidence that signal intensity positively correlates with psychophysical outcomes. It is expected that this study will provide the framework for understanding how pain-induced activity is modified in persistent and chronic pain states.

Acknowledgments

The authors would like to thank Ms. Sharon David for her technical support. This research was supported by the Canada Research Chairs program (C.M.C., P.W.S.), the International Spinal Research Trust and the Botterell Foundation, Queen's University.

References

- [1] Apkarian AV, Bushnell MC, Treede RD, Zubieta JK. Human brain mechanisms of pain perception and regulation in health and disease. *Eur J Pain* 2005;9(4):463–84.
- [2] Tracey I, Bushnell MC. How neuroimaging studies have challenged us to rethink: is chronic pain a disease? *J Pain* 2009;10(11):1113–20.
- [3] Brooks J, Tracey I. From nociception to pain perception: imaging the spinal and supraspinal pathways. *J Anat* 2005;207(1):19–33.
- [4] Singer T, Seymour B, O'Doherty J, Kaube H, Dolan RJ, Frith CD. Empathy for pain involves the affective but not sensory components of pain. *Science* 2004;303(5661):1157–62.
- [5] Wager TD, Jonides J, Reading S. Neuroimaging studies of shifting attention: a meta-analysis. *Neuroimage* 2004;22(4):1679–93.
- [6] Villemure C, Bushnell MC. Cognitive modulation of pain: how do attention and emotion influence pain processing? *Pain* 2002;95(3):195–9.
- [7] Zambreanu L, Wise RG, Brooks JC, Iannetti GD, Tracey I. A role for the brainstem in central sensitisation in humans. Evidence from functional magnetic resonance imaging. *Pain* 2005;114(3):397–407.

- [8] Fairhurst M, Wiech K, Dunckley P, Tracey I. Anticipatory brainstem activity predicts neural processing of pain in humans. *Pain* 2007;128(1–2):101–10.
- [9] Stroman PW. Discrimination of errors from neuronal activity in functional MRI of the human spinal cord by means of general linear model analysis. *Magn Reson Med* 2006;56(2):452–6.
- [10] Agosta F, Valsasina P, Caputo D, Stroman PW, Filippi M. Tactile-associated recruitment of the cervical cord is altered in patients with multiple sclerosis. *Neuroimage* 2008;39(4):1542–8.
- [11] Agosta F, Valsasina P, Caputo D, Rocca MA, Filippi M. Tactile-associated fMRI recruitment of the cervical cord in healthy subjects. *Hum Brain Mapp* 2007.
- [12] Valsasina P, Agosta F, Caputo D, Stroman PW, Filippi M. Spinal fMRI during proprioceptive and tactile tasks in healthy subjects: activity detected using cross-correlation, general linear model and independent component analysis. *Neuroradiology* 2008;50:895–902.
- [13] Stroman PW. Magnetic resonance imaging of neuronal function in the spinal cord: spinal fMRI. *Clin Med Res* 2005;3(3):146–56.
- [14] Stroman PW, Kornelsen J, Lawrence J, Maliszka KL. Functional magnetic resonance imaging based on SEEP contrast: response function and anatomical specificity. *Magn Reson Imaging* 2005;23(8):843–50.
- [15] Leitch JK, Figley CR, Stroman PW. Applying functional MRI to the spinal cord and brainstem. *Magn Reson Imaging* 2010.
- [16] Stroman PW, Tomanek B, Krause V, Frankenstein UN, Maliszka KL. Mapping of neuronal function in the healthy and injured human spinal cord with spinal fMRI. *Neuroimage* 2002;17(4):1854–60.
- [17] Stroman PW, Coe BC, Munoz DP. Influence of attention focus on neural activity involved with thermal sensations in the human spinal cord. *Magn Reson Imaging* 2011;29:9–18.
- [18] Figley CR, Stroman PW. Development and validation of retrospective spinal cord motion time-course estimates (RESPITE) for spin-echo spinal fMRI: improved sensitivity and specificity by means of a motion-compensating general linear model analysis. *Neuroimage* 2009;44(2):421–7.
- [19] Stroman PW, Figley CR, Cahill CM. Spatial normalization, bulk motion correction and coregistration for functional magnetic resonance imaging of the human cervical spinal cord and brainstem. *Magn Reson Imaging* 2008;26:809–14.
- [20] Stroman PW, Kornelsen J, Bergman A, Krause V, Ethans K, Maliszka KL, et al. Noninvasive assessment of the injured human spinal cord by means of functional magnetic resonance imaging. *Spinal Cord* 2004;42(2):59–66.
- [21] Stroman PW. Spinal fMRI investigation of human spinal cord function over a range of innocuous thermal sensory stimuli and study-related emotional influences. *Magn Reson Imaging* 2009;27:1333–46.
- [22] McIntosh AR, Lobaugh NJ. Partial least squares analysis of neuroimaging data: applications and advances. *Neuroimage* 2004;23(Suppl 1):S250–63.
- [23] McIntosh AR, Bookstein FL, Haxby JV, Grady CL. Spatial pattern analysis of functional brain images using partial least squares. *Neuroimage* 1996;3(3 Pt 1):143–57.
- [24] Dostrovsky JO, Craig AD. Cooling-specific spinothalamic neurons in the monkey. *J Neurophysiol* 1996;76(6):3656–65.
- [25] Ploghaus A, Narain C, Beckmann CF, Clare S, Bantick S, Wise R, et al. Exacerbation of pain by anxiety is associated with activity in a hippocampal network. *J Neurosci* 2001;21(24):9896–903.
- [26] Villemure C, Bushnell MC. Mood influences supraspinal pain processing separately from attention. *J Neurosci* 2009;29(3):705–15.
- [27] Logothetis NK, Pauls J, Augath M, Trinath T, Oeltermann A. Neurophysiological investigation of the basis of the fMRI signal. *Nature* 2001;412(6843):150–7.