

UC Davis

Dermatology Online Journal

Title

Periocular Demodex folliculorum folliculitis

Permalink

<https://escholarship.org/uc/item/0hs897p2>

Journal

Dermatology Online Journal, 29(3)

Authors

Chiriac, Anca
Wollina, Uwe

Publication Date

2023

DOI

10.5070/D329361441

Copyright Information

Copyright 2023 by the author(s). This work is made available under the terms of a Creative Commons Attribution-NonCommercial-NoDerivatives License, available at <https://creativecommons.org/licenses/by-nc-nd/4.0/>

Peer reviewed

Periocular *Demodex folliculorum* folliculitis

Anca Chiriac¹⁻³, Uwe Wollina⁴

Affiliations: ¹Department of Dermatology, Nicolina Medical Center, Iasi, Romania, ²Apollonia University, Iasi, Romania, ³P. Poni Institute of Macromolecular Chemistry, Romanian Academy, ⁴Department of Dermatology and Allergology, Städtisches Klinikum Dresden, Academic Teaching Hospital, Dresden, Germany

Corresponding Author: Anca Chiriac, 2 Strada Hatman Sendrea, Iasi, 700613, Romania, Tel 40-721234999, Email: ncachiriac@yahoo.com

Keywords: *Demodex*, folliculitis, periocular

To the Editor:

A 48-year-old healthy patient was seen in Dermatology for numerous papules and pustules, grouped in plaques, located bilaterally, exclusively around the inferior eyelid (**Figure 1**). He was sent from the ophthalmology department for further investigations. He had been treated for the previous three months for eyelid dermatitis with antihistamines, potent topical corticosteroids, topical erythromycin, and emollients. Patch and prick tests, repeated ophthalmologic examinations, bacteriologic and mycologic directed tests and cultures were all within normal limits. He was in good health with no history of drug intake. Skin lesions were associated with pruritus, burning sensations, and pain around the eyes but with no ocular symptoms. Dermatologic examination failed to reveal other skin pathological signs. The patient was very anxious with poor quality of life and a negative impact on his social and professional life.

Skin scrapings, taken from both areas were examined for *Demodex* spp, which was present in very high numbers. Also, a tape test proved to be positive. Parasites were seen under microscopy after application of an adhesive tape on the lesions (**Figure 2A**). A 4mm punch biopsy was taken and clearly identified small fragments of the mites (**Figure 2B**).

Discontinuation of topical therapy was recommended and metronidazole 500mg twice per day for two months was started, followed by a two-

month treatment with doxycycline 100mg/day. Slow recovery was obtained in four months; the patient was closely followed up for the next two months.

Concerning treatment of *Demodex* associated inflammatory skin conditions, a number of topical treatments are available but several of the efficacious drugs can cause skin irritation and no long-term evaluation is available [1]. Metronidazole is effective against the mite and has an anti-inflammatory activity. Oral ivermectin in combination with oral metronidazole has shown better efficacy than metronidazole alone but oral ivermectin is off-label [2]. We have chosen oral metronidazole to reduce the mites followed by oral doxycycline to further reduce the inflammation.

Apart from presenting the case to raise the attention about frequently misdiagnosed skin lesions around the eyes, we would like to draw attention to the name of this skin disease. Is it rosacea, demodectosis or *Demodex* spp. Folliculitis, or do all three names describe the same disease?

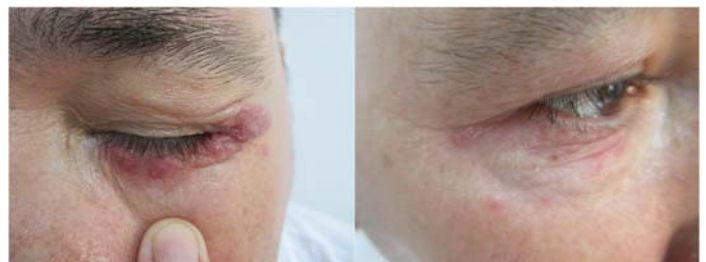

Figure 1. Numerous papules and pustules located bilaterally around the inferior lid.

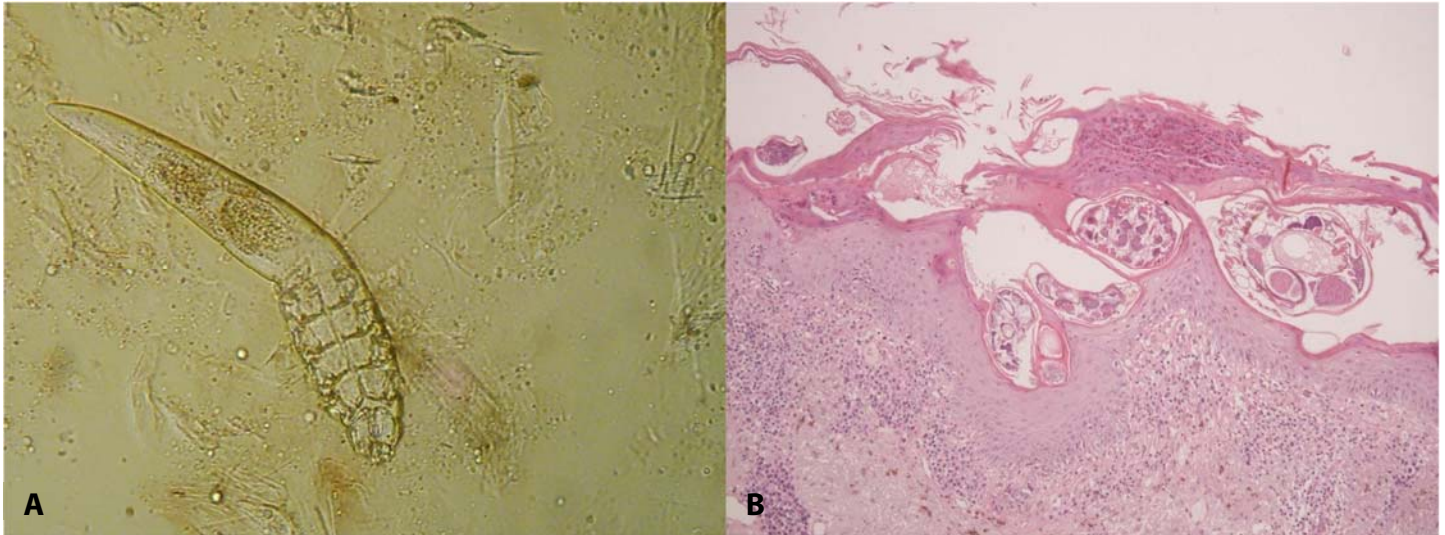


Figure 2. A) *Demodex* evident from a tape lift. B) H&E histopathology showing *Demodex folliculorum* within the ostium, 10x.

Our present case suggests the diagnosis of periocular *Demodex folliculorum* folliculitis that is not, in our opinion, a clinical form either of rosacea or demodecidosis. Although there were papules and pustules on an erythematous base, not all criteria for ocular or cutaneous rosacea were present.

The National Rosacea Society Expert Committee has recently established a clinical diagnostic guideline for rosacea [3]. The presence of fixed centrofacial erythema or phymatous anomalies are sufficient for diagnosis as unique clinical criteria. Two of the following criteria make the diagnosis, such as papules and pustules localized on the face, flushing, and telangiectasia [3]. The present case does not fulfill criteria for diagnosis of cutaneous rosacea accordingly to the latest guideline.

The diagnosis of ocular rosacea is based on the presence of lid telangiectasia associated with ophthalmic lesions [3]. Our patient had inflammatory papules and pustules around the inferior lid, but no telangiectasia and no ocular alterations.

Demodex spp. are ectoparasites that populate hair follicles (*D. folliculorum*) and sebaceous glands (*D.*

brevis), especially on the face in predisposed patients; the condition is frequently completely asymptomatic.

Demodecidosis (demodicosis) is an infection of pilosebaceous units caused by *Demodex* mites, affecting skin and eyelids. Demodicosis of the eyelid is associated with variable clinical manifestations, mainly chronic blepharitis, lid keratinization, meibomian hyperplasia, and chalazia [4]. High numbers of mites were observed in skin scrapings of the patient, but not at the base or around the eyelids. Therefore, we cannot consider this to be demodicosis of the eyelid. A similar case was recently described by Veraldi et al, but with unilateral involvement [5]. We consider that the diagnosis of periocular *Demodex folliculorum* folliculitis is the most precise in our patient.

Potential conflicts of interest

The authors declare no conflicts of interest

References

1. Jacob S, VanDaele MA, Brown JN. Treatment of Demodex-associated inflammatory skin conditions: A systematic review. *Dermatol Ther.* 2019;32:e13103. [PMID: 31583801].
2. Salem DA, El-Shazly A, Nabih N, El-Bayoumy Y, Saleh S. Evaluation of the efficacy of oral ivermectin in comparison with ivermectin-metronidazole combined therapy in the treatment of ocular and skin lesions of *Demodex folliculorum*. *Int J Infect Dis.* 2013;17:e343-7. [PMID: 23294870].
3. Thiboutot D, Anderson R, Cook-Bolden F, Draelos Z, Gallo RL, Granstein RD, Kang S, Macsai M, Gold LS, Tan J. Standard management options for rosacea: The 2019 update by the National Rosacea Society Expert Committee. *J Am Acad Dermatol.*

- 2020;82:1501-10. [PMID: 32035944].
4. Helm CJ. Treatment of ocular *Demodex* infestation with topical ivermectin cream. *Am J Ophthalmol Case Rep.* 2022;26:101551. [PMID: 35509284].
 5. Veraldi S, Pisapia A, Nazzaro G, Boneschi V. Unilateral rosacea, unilateral demodicidosis, unilateral *Demodex sp.* folliculitis: Three names for the same disease. *J Cosmet Dermatol.* 2023;22:335-6. [PMID: 35181988].