

# UC Davis

## Dermatology Online Journal

### Title

Congenital liquified subcutaneous fat necrosis in a newborn: an unusual case

### Permalink

<https://escholarship.org/uc/item/0gt361tg>

### Journal

Dermatology Online Journal, 30(1)

### Authors

Regaieg, Chiraz  
Thabet, Afef Ben  
Kolsi, Nadia  
[et al.](#)

### Publication Date

2024

### DOI

10.5070/D330163295

### Copyright Information

Copyright 2024 by the author(s). This work is made available under the terms of a Creative Commons Attribution-NonCommercial-NoDerivatives License, available at <https://creativecommons.org/licenses/by-nc-nd/4.0/>

Peer reviewed

# Congenital liquified subcutaneous fat necrosis in a newborn: an unusual case

Chiraz Regaieg<sup>1,3</sup> MD, Afef Ben Thabet<sup>1,3</sup> MD, Nadia Kolsi<sup>1,3</sup> MD, Khadija Sellami<sup>2,3</sup> MD, Hamida Turki<sup>2,3</sup> PR, Manel Charfi<sup>1,3</sup> MD, Nedja Hmida<sup>1,3</sup> PR

Affiliations: <sup>1</sup>Department of Neonatology, Hedi Chaker University Hospital, Sfax University, Sfax, Tunisia, <sup>2</sup>Department of Dermatology, Hedi Chaker University Hospital, Sfax University, Sfax, Tunisia, <sup>3</sup>University of Medicine of Sfax, Sfax, Tunisia

Corresponding Author: Chiraz Regaieg, Department of Neonatology, Hedi Chaker University Hospital, University of Medicine of Sfax, Sfax, Tunisia, Tel: 216-29147484; Email: [chirazregaieghentati@gmail.com](mailto:chirazregaieghentati@gmail.com)

## Abstract

Subcutaneous fat necrosis of the newborn is a self-limited disorder of the panniculus that arises in the first six weeks of life. Some differential diagnoses may be difficult such as bacterial cellulitis or erysipelas. The prognosis is usually favorable but there are serious complications for which the patient must be regularly monitored, especially hypercalcemia. We report a case of a full-term newborn with a liquified area of subcutaneous fat necrosis. A surgical incision was performed because of the discomfort and the lack of regression. Hypercalcemia and nephrocalcinosis appeared afterward. A set of clinical, biological, and histological arguments allows the diagnosis of subcutaneous fat necrosis. Follow-up to early detection and to manage such complications is necessary.

*Keywords: fat necrosis, hypercalcemia, newborn, subcutaneous surgery*

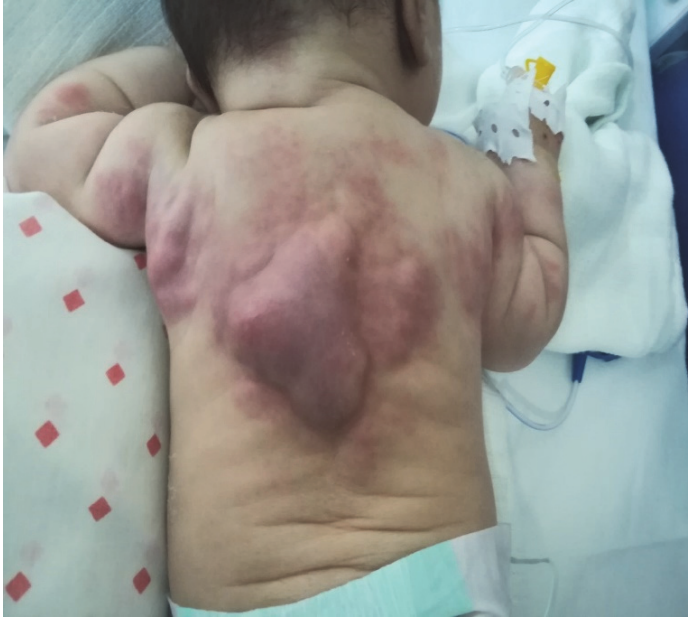## Introduction

Subcutaneous fat necrosis of the newborn (SCFN) presents as erythematous nodules and indurated plaques over bony prominences such as the back, arms, buttocks, thighs, and cheeks. Diagnosis is essentially clinical [1]. Some entities in the differential diagnosis may be difficult to exclude initially, or include cellulitis and sclerema neonatorum [2]. We describe a case of a newborn with subcutaneous fat necrosis who developed a

liquefaction, for whom a surgical incision was performed.

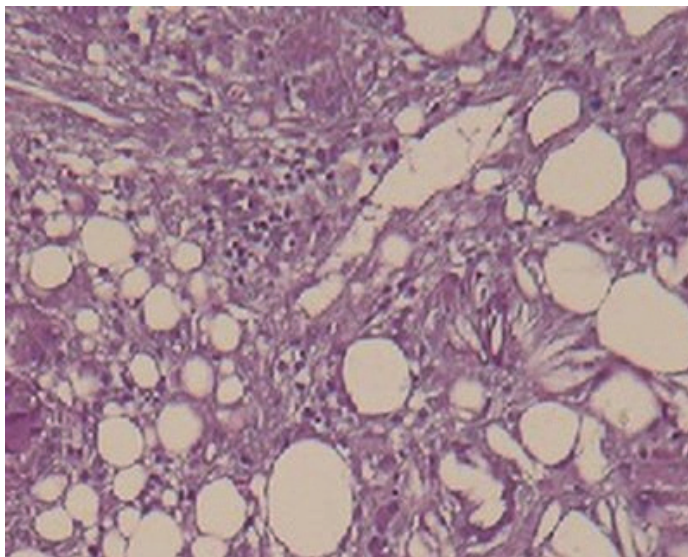
## Case Synopsis

A full-term boy, weighing 4050g was born at 38 weeks gestation. The pregnancy was complicated by pre-eclampsia. The delivery was vaginal with shoulder dystocia. At birth, the APGAR scores were 5 and 7 at one minute and 5 minutes of life, respectively. The amniotic liquid was meconial. The newborn manifested immediate severe respiratory distress due to a meconial aspiration syndrome and was transferred to our neonatal intensive care unit for assisted ventilation for 72 hours. Physical examination on day 5 of life revealed 3cm to 10cm-hard nodules covered by erythematous skin localized on the back and shoulders, suggestive of subcutaneous fat necrosis. On the ninth day of life, the newborn developed liquefaction of the median plaque on the back (6cm×10cm in size) and it did not spontaneously fistulize (**Figure 1**). Laboratory analysis showed an increased C-reactive protein level at 47mg/dL (normal <10mg/dL), thrombocytopenia with an average of 46,000 cells/mm<sup>3</sup>, and moderate hypocalcemia with an average of 1.9mmol/L (normal 2.02-2.55mmol/L). An ultrasound scan showed the presence of fluid collection. The diagnosis of cellulitis was considered. Broad-spectrum antibiotics were commenced after performing a blood culture. On the fourteenth day of life, a surgical incision was performed because of the



**Figure 1.** A large liquefied component of one plaque on the back, 6cm×10cm in size.

discomfort and the lack of regression of the very large plaque. It allowed the draining of about 20 ml of thick liquid. Samples of the fluid were sent to the laboratory of bacteriology and anatomic pathology. Blood cultures were sterile. On the seventeenth day of life, biological monitoring revealed persistent thrombocytopenia and hypercalcemia with a serum level reaching 2.85mmol/L. It was treated with low calcium and vitamin D intake and hyperhydration. The triglyceride level was normal at 2.1mmol/L. The

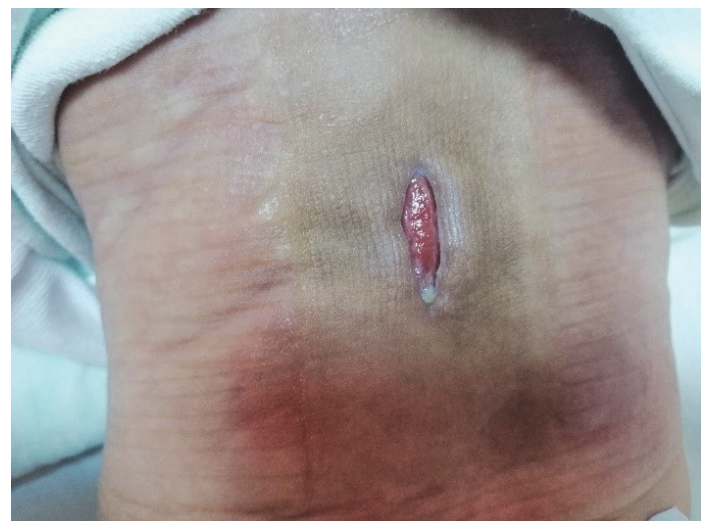

**Figure 2.** H&E histologic examination showed fat cell necrosis with a dense inflammatory infiltrate composed of lymphocytes, histiocytes, and multinucleated giant cells.

diagnosis of subcutaneous fat necrosis was strongly suspected and it was confirmed by histology that showed fat cell necrosis with a dense inflammatory infiltrate composed of lymphocytes, histiocytes, and multinucleated giant cells (**Figure 2**). Nephrocalcinosis was detected on the renal ultrasound performed on day 30 of life. The skin lesions regressed and complete healing of fat necrosis occurred within 8 weeks (**Figure 3**). After three months of follow-up, we noted a normalization of serum calcium level, as well as renal ultrasound.

### Case Discussion

Subcutaneous fat necrosis of the newborn is a panniculitis with a benign course that typically appears during the first 2–3 weeks of life in full-term or post-term neonates [1]. Risk factors include birth trauma, hypothermia, macrosomia, or other perinatal stress such as meconium aspiration, birth asphyxia, and maternal causes including pre-eclampsia and diabetes. Typical forms of SCFN are characterized by purplish-erythematous subcutaneous nodules and indurated plaques [1]. Lesions are mostly located on the posterior trunk, thighs, proximal extremities, and cheeks. Spontaneous resolution without sequelae is the rule; it may take weeks to months [1,2]. Unusually, we can have liquefaction or ulceration of nodules [3]. Some



**Figure 3.** Clinical aspect after incision of the liquefied component of the median fat necrosis nodule.

differential diagnoses include cellulitis, erysipelas, sclerema neonatorum, and clod panniculitis [2,3]. In our case, the association of thrombocytopenia, a positive C-reactive protein, and loculated collection in the ultrasound referred us to the diagnosis of bacterial cellulitis or neonatal sepsis for the first time.

Ultrasonography can help diagnosis of SCFN which shows high echo signal with or without calcifications and increased blood flow [3]. The skin biopsy is useful in case of clinical doubt [2,3]. Histology in SCFN reveals necrosis of adipocytes and a chronic inflammatory infiltrate with foreign body giant cells. Foci of calcification may be noted scattered throughout the necrotic fat. Fine needle aspiration of the subcutaneous lesions has also been reported as a possible alternative to skin biopsy for diagnosis.

Our patient had presented a liquefaction of one lesion that had not spontaneously fistulized. Although not conventional, a surgical incision and drainage were performed. Surgical excision can be proposed in the case of ulcerated lesions or the issue of lack of regression of lesions. Beuzeboc et al. [4] demonstrate that aspiration and drainage can help minimize the size of voluminous fat necrosis nodules.

Subcutaneous fat necrosis of the newborn may be complicated by severe hypercalcemia. Beuzeboc et

al. [4] noted that surgery can expose the patient to the risk of hypercalcemia. However, the large size and number of subcutaneous calcifications, in this case, explains probably the nonresorption and the risk of hypercalcemia. Because of the large size and patient discomfort, drainage was performed in our case. Persistent hypercalcemia can be responsible for nephrocalcinosis leading to chronic kidney disease. Monitoring blood calcium levels is recommended. It was suggested to perform weekly monitoring during the first month and then monthly monitoring until 6 months of life [1,2]. Therapeutic alternatives include intravenous hyperhydration, intravenous furosemide, and systemic steroids. Calcium and vitamin D intake should be lowered [2].

## Conclusion

Subcutaneous fat necrosis of the newborn is an important entity in the differential diagnosis of neonates with subcutaneous nodules and plaques. A set of clinical, biological, and histological features allows the diagnosis of SCFN. Monitoring blood calcium levels is recommended.

## Potential conflicts of interest

The authors declare no conflicts of interest.

## References

1. Siegel LH, Fraile Alonso C, Tuazon CFR, Mancini AJ, et al. Subcutaneous fat necrosis of the newborn: A retrospective study of 32 infants and care algorithm. *Pediatr Dermatol.* 2023;40:413-421. [PMID: 36544364].
2. Chan D, Salas-Walinsundin WM, Yap FKP, Koh MJA. Calcium management challenges in a macrosomic child with subcutaneous fat necrosis. *BMJ Case Rep.* 2019;12: e227141. [PMID: 30787024].
3. Dhanawade SS, Kinikar US. Subcutaneous Fat Necrosis of Newborn: An Atypical Presentation. *Indian J Dermatol.* 2022;67:194-196. [PMID: 36092212].
4. Beuzeboc Gérard M, Aillet S, Bertheuil N, Dellièrè V, et al. Surgical management of subcutaneous fat necrosis of the newborn required due to a lack of improvement: a very rare case. *Br J Dermatol.* 2014 171:183-5. [PMID: 24359190].