

# UC Irvine

## UC Irvine Previously Published Works

### Title

A Case of Melanoma-Associated Retinopathy, Uveitis, and Optic Neuritis Associated With Pembrolizumab, Managed With Topical, Intravitreal, and Intravenous Steroids.

### Permalink

<https://escholarship.org/uc/item/0fb499gg>

### Journal

Journal of VitreoRetinal Diseases, 4(3)

### Authors

Xie, Kate  
Kong, Christina  
Mehta, Mitul

### Publication Date

2020-06-01

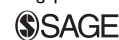### DOI

10.1177/2474126419886154

Peer reviewed

# A Case of Melanoma-Associated Retinopathy, Uveitis, and Optic Neuritis Associated With Pembrolizumab, Managed With Topical, Intravitreal, and Intravenous Steroids

Journal of VitreoRetinal Diseases  
2020, Vol. 4(3) 220-226  
© The Author(s) 2019  
Article reuse guidelines:  
sagepub.com/journals-permissions  
DOI: 10.1177/2474126419886154  
jvrd.sagepub.com



Kate Xie, MD<sup>1</sup>, Christina Kong, BS<sup>2</sup>, and Mitul C. Mehta, MD, MS<sup>1</sup>

## Abstract

**Purpose:** We report a case of advanced metastatic cutaneous melanoma with melanoma-associated retinopathy and pembrolizumab-related panuveitis and optic neuritis. **Methods:** The patient's condition was managed by systemic, topical, and intravitreal corticosteroids without discontinuing pembrolizumab. **Results:** After initiation of systemic and topical steroid treatment, optic nerve edema improved. He developed chronic uveitis with cystoid macular edema with improvement in symptoms with intravitreal dexamethasone implants. The patient demonstrated a decrease in all metastatic lesions and improvement in melanoma-associated retinopathy. **Conclusions:** The new checkpoint inhibitor class including pembrolizumab shows promise as a therapy for advanced metastatic melanoma in patients resistant to all other forms of chemotherapy. In general, immune-related adverse effects are responsive to steroid therapy. The trend for treatment of posterior uveitis due to pembrolizumab is to discontinue pembrolizumab. Our case suggests that even severe cases of uveitis may be sufficiently ameliorated by concurrent systemic, intravitreal, and topical therapy to allow continuation of treatment.

## Keywords

immunotherapy, melanoma-associated retinopathy, optic neuritis, panuveitis, pembrolizumab, posterior uveitis

## Introduction

Pembrolizumab is a new member of the checkpoint inhibitor class of chemotherapy medications that has been approved since September 2014 for the treatment of advanced melanoma. There are growing reports of ocular and orbital inflammation due to immune-related adverse events (IRAEs) that occur as a consequence of the drug's immunomodulatory mechanism of action. There are no formal guidelines regarding the management of ocular IRAEs. We present a case of pembrolizumab-related panuveitis and optic neuritis with concurrent melanoma-associated retinopathy (MAR) that was successfully treated with an extended course of systemic, topical, and intravitreal steroid therapy.

## Methods

### Case Report

A 66-year-old man with metastatic cutaneous melanoma of 2 years' duration presented to the ophthalmology clinic with night blindness and acute onset of blurry vision with decreased peripheral vision. His vision began to worsen after his second infusion of pembrolizumab, after which his chemotherapy was

discontinued until he was seen by Ophthalmology. In the 8 weeks until his initial presentation, he noted gradual improvements in his central vision but continued night blindness and decreased peripheral vision.

During his first visit, his best-corrected visual acuity was 20/40 in the right eye and 20/60 in the left eye. Color vision and confrontation visual field were moderately diminished in the right eye, with near complete loss of color recognition in the left eye. Both eyes had grade one optic disc edema, peripheral salt-and-pepper retinal pigmented epithelial changes, and no anterior chamber or vitreous inflammation. Fundus autofluorescence indicated patchy parafoveal hypofluorescent rings in both eyes (Figure 1). Visual field testing showed a generalized

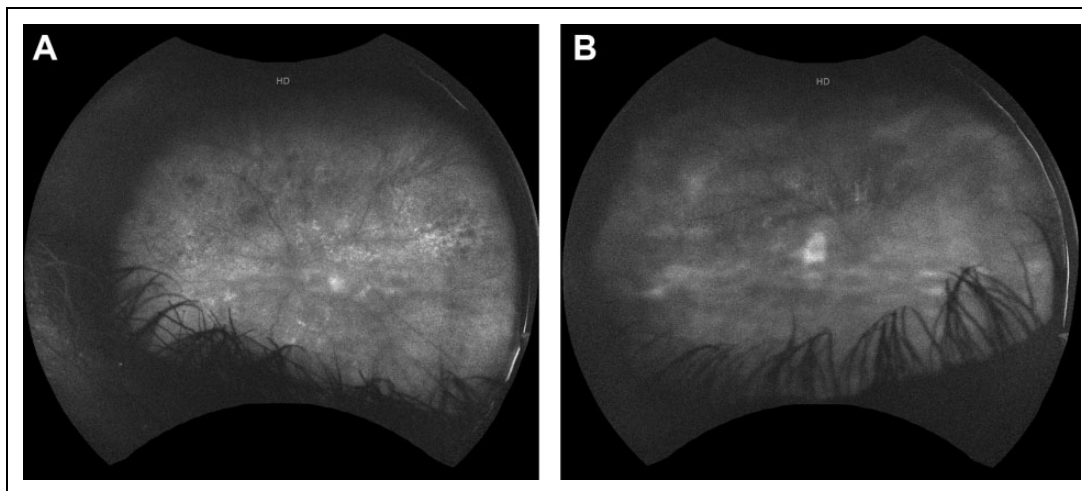
<sup>1</sup> Department of Ophthalmology, Gavin Herbert Eye Institute, University of California-Irvine, Irvine, CA, USA

<sup>2</sup> School of Medicine, University of California-Irvine, Irvine, CA, USA

### Corresponding Author:

Mitul C. Mehta, MD, MS, Department of Ophthalmology, Gavin Herbert Eye Institute, University of California-Irvine, 850 Health Sciences Rd, Irvine, CA 92697, USA.

Email: mmehta@uci.edu



**Figure 1.** Fundus autofluorescence photos of right and left eyes. (A) At time of presentation, a patchy parafoveal hypofluorescent ring is present in both eyes. There is vitritis in both eyes, left greater than right, responsible for the media opacity. Optic nerve edema is visible in the right eye. (B) Twelve months after presentation, repeat photos show improvement in vitritis, resolution of optic nerve edema, and persistent patchy parafoveal hypofluorescence in both eyes.

depression of the right eye and a paracentral ring scotoma in the left eye (Figure 2). Electroretinography demonstrated attenuated a-wave and b-wave amplitudes on full-field recordings with diminished and delayed cone flicker response (Figure 3) with visual evoked potential confirming delayed optic nerve conduction in both eyes. Magnetic resonance imaging of the brain and orbits was unremarkable. When the patient followed up 3 weeks later, he was found to have significant vitreous haze in both eyes and new-onset cystoid macular edema of the left eye.

## Results

Considering these findings, the patient was diagnosed with pembrolizumab-associated panuveitis and optic neuritis. In addition, the diagnosis of concomitant MAR was made by the presence of salt-and-pepper retinopathy with retinal atrophy at time of initial presentation, which would be more consistent with an ongoing, chronic autoimmune retinopathy.<sup>1</sup> This diagnosis was made 11 weeks after his first pembrolizumab infusion.

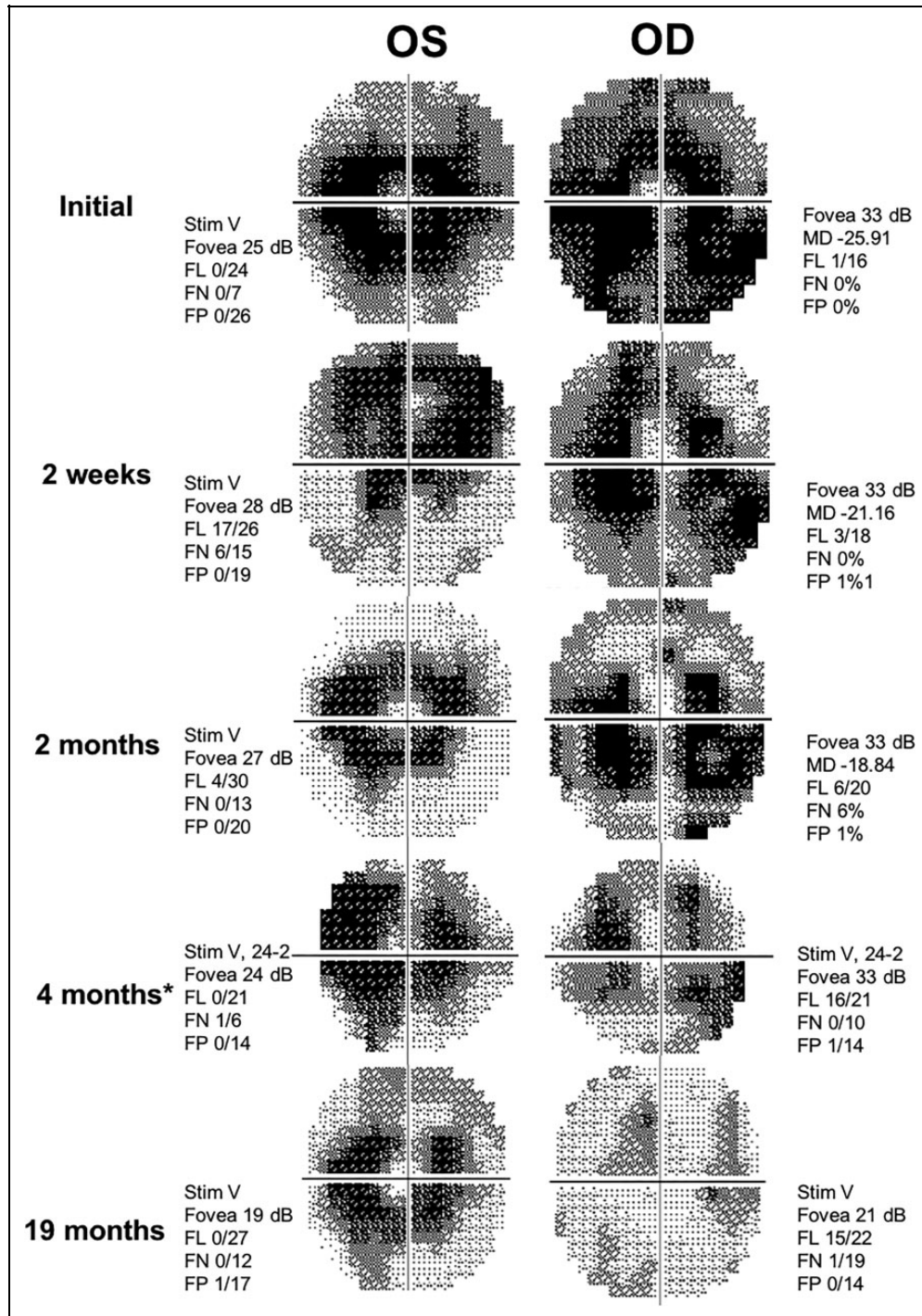
Given the patient's extensive metastatic disease with multi-organ involvement, a joint decision was made between Ophthalmology and Hematology/Oncology to restart his pembrolizumab infusions with the addition of same-day 1 g solumedrol infusions. In addition, 60 mg of oral prednisone would be taken for 2 days after chemotherapy and a 1-month-long topical prednisolone acetate taper after each infusion as well. Nine weeks after discontinuing pembrolizumab, the patient was started on his first combined solumedrol/pembrolizumab (S/P) infusion. The patient's full clinical course is described in Figure 4.

The patient reported subjective improvement in his vision lasting for 5 days after each combined infusion, then gradual deterioration until his next infusion appointment. Six months

after starting the combined infusions, repeat examination showed improving panuveitis and optic nerve edema (Figure 1). Automated perimetry indicated improved visual fields, especially in the left eye (Figure 2), and repeat electroretinogram (ERG) testing showed mild improvement in cone responses but unchanged, nearly absent rod responses (Figure 5). The patient was able to continue on combined oral, topical, and systemic corticosteroids for a total of 9 months and 12 S/P infusions, during which time his metastatic lesions continued to shrink.

The patient developed epiretinal membranes, subretinal deposits, and severe cystoid macular edema (Figure 6). He declined vitrectomy with membrane peel given his advanced melanoma with unclear prognosis. Instead, he opted to continue combined steroid therapy with the addition of intravitreal dexamethasone implants (Ozurdex; Allergan) administered every 3 months. He developed visually significant cataracts and underwent cataract surgery in both eyes approximately 4 months after initiating dexamethasone. Owing to progression of his melanoma, his chemotherapy regimen was changed to ipilimumab/nivolumab. Ultimately, he transitioned to palliative care and died 4 years after his initial diagnosis.

Checkpoint inhibitors are immune system regulators that affect T-cell-mediated responses involved in autoimmunity. Pembrolizumab is an antibody against programmed death-1 (PD-1), a receptor found on T cells. Normally, PD-1 binds PD-1 ligand (PD-L1), found on native host cells, to prevent autoimmunity. Melanoma cells upregulate PD-L1 and as such, escape detection by the host immune system. Pembrolizumab interferes with this mechanism and therefore targets melanoma cells via upregulation of the host immune response. As a consequence of their mechanism of action, checkpoint inhibitors are known to result in IRAEs, which are systemic autoimmune phenomena related to the breakdown of peripheral tolerance.



**Figure 2.** Serial Humphrey visual field examinations showing some improvement in peripheral vision of both eyes. \*Note that Humphrey visual field examination at 4 months was a 24-2 examination, whereas all others were 30-2. FL indicates fixation loss; FN, false negative; FP, false positive; MD, mean deviation.

Most commonly these include symptoms such as diarrhea and skin depigmentation, and they respond well to steroids.<sup>2</sup>

There are growing reports of ophthalmic IRAEs, including both orbital and ocular inflammation, which occur in less than 1% of patients who receive checkpoint inhibitor therapy.<sup>3</sup> Several case reports describe panuveitis occurring weeks to months

after starting pembrolizumab (Table 1). In most of these cases, patients experienced complete recovery after cessation of pembrolizumab and initiation of topical and systemic steroids.<sup>7,8</sup> The overall trend has been to discontinue pembrolizumab treatment in the setting of panuveitis or posterior uveitis.<sup>3</sup> However, in one case reported by Aaberg and Aaberg, pembrolizumab

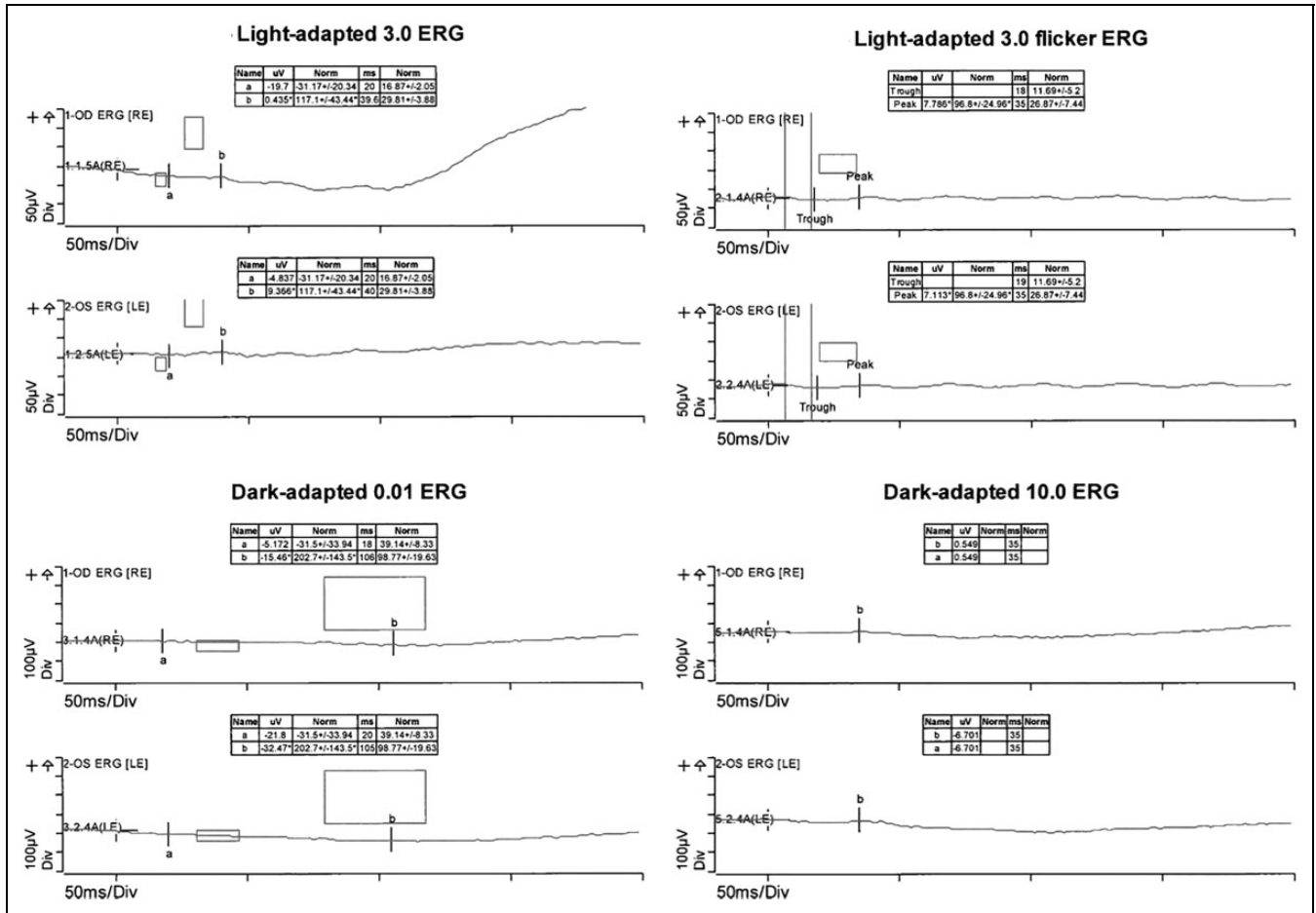


Figure 3. Electroretinogram (ERG) at initial presentation showing depressed rod and cone responses. LE indicates left eye; RE, right eye.

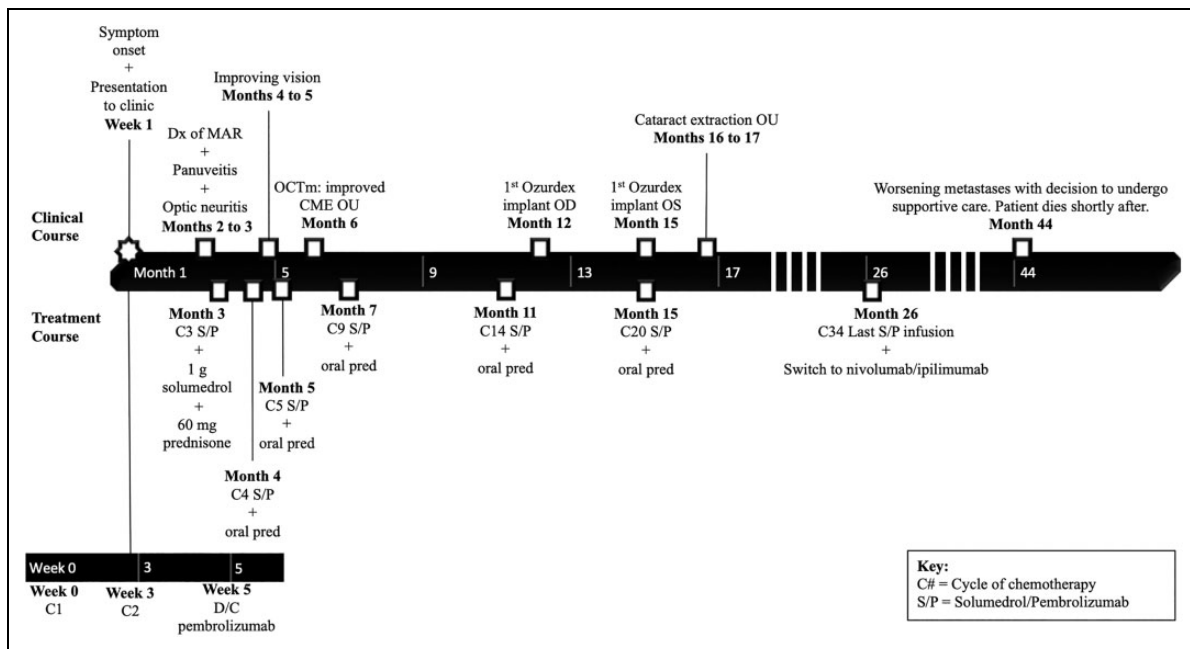
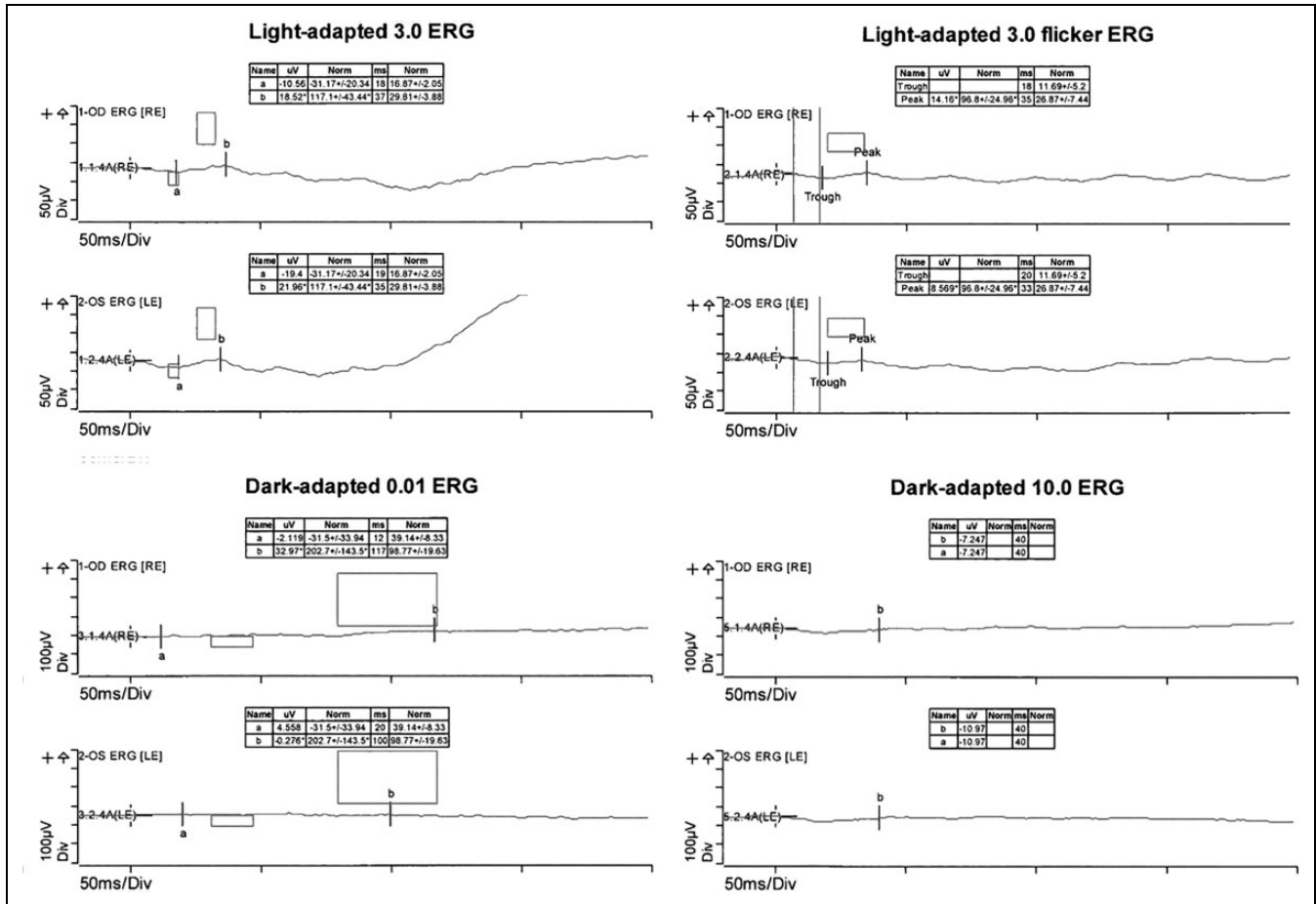
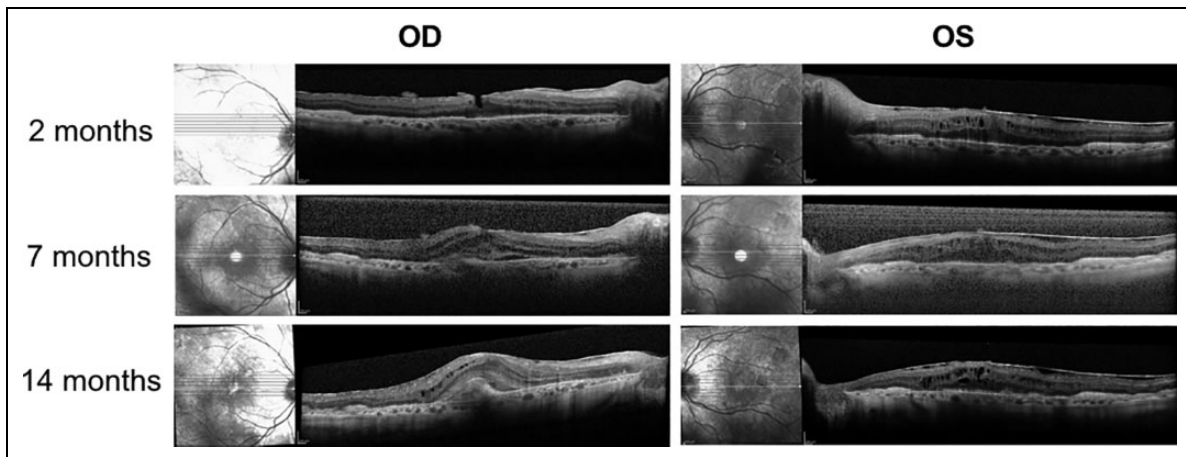


Figure 4. A timeline demonstrating the periodicity of steroid therapy and visual changes during this time. CME indicates cystoid macular edema; D/C, discontinues; Dx, diagnosis; OCTm, optical coherence tomography of the macula.



**Figure 5.** Electroretinogram (ERG) at 1 year showing improvement in cone response and unchanged depression of rod response. LE indicates left eye; RE, right eye.



**Figure 6.** Serial optical coherence tomography (OCT) macula studies over time. (A) First OCT macula images obtained for this patient 2 months after initial presentation. (B) Significant worsening of cystoid macular edema and epiretinal membranes in both eyes at 9 months. The patient declined membrane peeling surgery at this time because of poor overall condition. (C) OCT macula images at 14 months, after bilateral intravitreal dexamethasone implants.

was continued and uveitis recurred but improved with intravitreal dexamethasone implants.<sup>5</sup> Like Aaberg and Aaberg, we found that a combination of systemic, intravitreal, and topical

steroids sufficiently ameliorated the side effects of therapy to allow the patient to remain on pembrolizumab therapy for more than 1 year.

**Table 1.** Summary of Existing Reports of Uveitis Associated With Pembrolizumab.

Author, Year	Signs and Symptoms	Onset of Symptoms	Treatment	Checkpoint Inhibitors Discontinued	Outcome
Manusow et al <sup>4</sup>	Anterior uveitis, retinal vasculitis	After third infusion	Topical steroids, eventual vitrectomy	No	Resolution of anterior uveitis with topical steroids; resolution of vasculitis following vitrectomy. Malignant cells identified in vitreous
Aaberg and Aaberg <sup>5</sup>	Nongranulomatous panuveitis, retinal vasculitis	After fourth infusion	Dexamethasone sustained-release implant	No	One relapse with resolution with repeat dexamethasone injection
Roberts et al <sup>6</sup>	Melanoma-associated retinopathy, chorioretinal scars	Vision changes prior to pembrolizumab initiation; fundus findings 5 months after pembrolizumab initiation	Observation	No	Stable best-corrected visual acuity, no change in size of chorioretinal lesion, gradual loss of pigmentation
Hanna <sup>7</sup>	Panuveitis with serous choroidal effusions and ciliary body failure	After third infusion	1 g intravitreal methylprednisolone for 3 days subtenon triamcinolone, 60 mg oral prednisone daily for 2 weeks	Yes	Resolution of uveitis
Abu Samra et al <sup>8</sup>	Bilateral severe anterior uveitis and papillitis	Two months after initiation	Topical and systemic steroids	Yes	Complete resolution with steroids and discontinuation of pembrolizumab. Recurrence of uveitis with retreatment of pembrolizumab with concomitant hydrocortisone 40 mg daily
Taylor et al <sup>9</sup>	Panuveitis	Three days after initiation	Oral prednisone 40 mg daily, topical prednisolone acetate 4 times per day	Yes	Complete resolution Retreatment of pembrolizumab with concurrent topical prednisolone acetate resulted in retinal vasculitis and recurrence of panuveitis. Improvement but no resolution with oral steroids
Basilious and Lloyd <sup>10</sup>	Bilateral severe anterior uveitis with hypotony	Unclear	Topical steroids for 3 months, then topical prednisolone acetate and intravitreal triamcinolone	Yes	Initial worsening visual acuity, iritis, posterior subcapsular cataracts, cystoid macular edema. Eventual resolution of symptoms after discontinuation of pembrolizumab, cataract surgery, and intravitreal triamcinolone

We chose to initiate treatment with intravenous steroid infusion as opposed to dexamethasone implants to avoid invasive treatment and the complication of steroid-induced cataracts in our patient, who initially preferred to avoid intraocular surgery because of his overall poor systemic condition. Our patient was able to tolerate combined infusion therapy for 9 months this way before pursuing intravitreal dexamethasone implants and ultimately undergoing bilateral cataract surgery. To the best of our knowledge, this is the first reported case showing that combination systemic, pulsed steroids may prove a viable alternative to intravitreal steroid implants to allow extended chemotherapy.

The association of MAR and checkpoint inhibitors is rarely described. A few case reports have described new diagnoses of MAR in patients receiving checkpoint inhibitors such as

pembrolizumab or ipilimumab.<sup>6,11</sup> The rationale behind the occurrence of MAR in this setting is thought to be related to a sudden upregulation of autoimmunity owing to the drug's mechanism of action.

Current consensus regarding the pathogenesis of MAR is the production of autoantibodies against retinal ganglion or bipolar cells. Characteristically, a marked reduction of the b-wave response in the electroretinogram is seen, reflecting diminished ON-bipolar cell function in the setting of preserved photoreceptor function.<sup>12</sup> The visual prognosis of MAR is poor with variable response to steroid and intravenous immune globulin therapy. Currently, cytoreductive efforts to reduce tumor burden, and subsequently autoantibody production, are the mainstay of treatment for MAR.<sup>9</sup>

In the setting of checkpoint inhibitor therapy, there are 2 potential mechanisms by which MAR could occur: either as a consequence of the underlying melanoma, or related to an upregulation of autoimmunity triggered by checkpoint inhibitor therapy.

In our case, our patient was continued on pembrolizumab with concomitant steroid therapy with ultimate improvement in nyctalopia and in visual fields. We believe that our patient had preexisting MAR prior to the development of pembrolizumab-associated panuveitis. The presence of retinal pigmented epithelial changes and atrophy at the time of initial examination suggest a chronic retinopathy that started prior to initiation of pembrolizumab. During the initial period of pembrolizumab discontinuation before presentation to Ophthalmology, our patient reported improvement in central vision but persistent nyctalopia. This result suggests that his nyctalopia was not an adverse effect of pembrolizumab treatment but rather a reflection of underlying MAR. Furthermore, although checkpoint inhibitors may initially exacerbate MAR, this effect may be transient and its effects ameliorated by pulsed steroid therapy. Ultimately, we believe that continuation of therapy with the resulting decrease in tumor burden resulted in improvement in MAR in our case.

## Conclusions

We describe a case of uveitis, optic neuritis, and MAR in a patient receiving pembrolizumab infusions for advanced melanoma.

By initiating treatment with combined S/P infusions, we were able to delay intravitreal dexamethasone implantation for 9 months and thus delay the ophthalmic complications of local steroid therapy. In patients with advanced metastatic disease who are averse to invasive treatments such as intravitreal implants or intraocular surgeries, combined steroid infusions may be a good initial treatment option.

Our patient was continued on pembrolizumab therapy with the addition of high-dose steroid therapy with subsequent improvement in ocular inflammation and MAR for 4 years after his diagnosis. In the majority of cases of ocular adverse events related to checkpoint inhibition, the offending agent was discontinued. Our case provides evidence that chemotherapy does not necessarily need to be discontinued.

## Ethical Approval

This case was performed and manuscript written in accordance with the ethical standards established by the 1964 Declaration of Helsinki and its later amendments as well as other ethical counterparts.

## Declaration of Conflicting Interests

The author(s) declared no potential conflicts of interest with respect to the research, authorship, and/or publication of this article.

## Funding

The author(s) disclosed receipt of the following financial support for the research, authorship, and/or publication of this article: The authors acknowledge departmental support from a Research to Prevent Blindness unrestricted grant.

## References

1. Lu Y, Jia L, He S, et al. Melanoma-associated retinopathy: a paraneoplastic autoimmune complication. *Arch Ophthalmol*. 2009;127(12):1572-1580. doi:10.1001/archophthol.2009.311
2. Martin-Liberal J, Kordbacheh T, Larkin J. Safety of pembrolizumab for the treatment of melanoma. *Expert Opin Drug Saf*. 2015;14(6):957-964. doi:10.1517/14740338.2015.1021774
3. Antoun J, Titah C, Cochereau I. Ocular and orbital side-effects of checkpoint inhibitors. *Curr Opin Oncol*. 2016;28(4):288-294. doi:10.1097/CCO.0000000000000296
4. Manusow JS, Khoja L, Pesin N, Joshua AM, Mandelcorn ED. Retinal vasculitis and ocular vitreous metastasis following complete response to PD-1 inhibition in a patient with metastatic cutaneous melanoma. *J Immunother Cancer*. 2014;2(1):41. doi:10.1186/s40425-014-0041-1
5. Aaberg MT, Aaberg TM Jr. Pembrolizumab administration associated with posterior uveitis. *Retin Cases Brief Rep*. 2017;11(4):348-351. doi:10.1097/ICB.0000000000000368
6. Roberts P, Fishman GA, Joshi K, Jampol LM. Chorioretinal lesions in a case of melanoma-associated retinopathy treated with pembrolizumab. *JAMA Ophthalmol*. 2016;134(10):1184-1188. doi:10.1001/jamaophthol.2016.2944
7. Hanna KS. A rare case of pembrolizumab-induced uveitis in a patient with metastatic melanoma. *Pharmacotherapy*. 2016;36(11):e183-e188. doi:10.1002/phar.1839
8. Abu Samra K, Aldes-Navarro M, Lee S, Swan R, Foster CS, Anesi SD. A case of bilateral uveitis and papillitis in a patient treated with pembrolizumab. *Eur J Ophthalmol*. 2016;26(3):193-282. doi:10.5301/ejo.5000724
9. Taylor SC, Hrisomalos F, Linette GP, Rao PK. A case of recurrent bilateral uveitis independently associated with dabrafenib and pembrolizumab therapy. *Am J Ophthalmol Case Rep*. 2016;2:23-25. doi:10.1016/j.ajoc.2016.04.004
10. Basilious A, Lloyd JC. Posterior subcapsular cataracts and hypotony secondary to severe pembrolizumab induced uveitis: case report. *Can J Ophthalmol*. 2016;51(1):e4-e6. doi:10.1016/j.jcjo.2015.09.008
11. Audemard A, de Raucourt S, Miocque S, et al. Melanoma-associated retinopathy treated with ipilimumab therapy. *Dermatology*. 2013;227(2):146-149. doi:10.1159/000353408
12. Grewal DS, Fishman GA, Jampol LM. Autoimmune retinopathy and antiretinal antibodies: a review. *Retina*. 2014;34(5):827-845. doi:10.1097/IAE.0000000000000119